

EARLY REHABILITATION IN A CASE OF PLURIMALFORMATIVE SYNDROME WITH DELETIONS OF CHROMOSOMES 13 AND 18

Mariana CEVEI*, Dorina STOICANESCU**, Carmen AVRAM*

* University of Oradea, Faculty of Medicine and Pharmacy, Medical Rehabilitation Clinical Hospital Felix Spa, Oradea, Romania

**University of Medicine and Pharmacy "Victor Babeş", Department of Medical Genetics, Timişoara, Romania

Corresponding author: Mariana Cevei, Medical Rehabilitation Clinical Hospital Felix Spa, 417500 Felix, Romania, tel. 0040359407858, e-mail: cevei_mariana@yahoo.com

Abstract. Deletion of long arm of chromosome 13 is characterized by malformations of the craniofacial region, skeletal abnormalities, other physical abnormalities and intellectual disability. Deletion of the long arm of chromosome 18 is a rare chromosomal disorder with a phenotype that may vary considerably in range and severity, depending on the type of deletion and location of the breakpoint. Subjects have characteristic features including short stature, mental retardation, hypotonia, malformations of the hands and feet, craniofacial abnormalities and numerous neurologic deficiencies with a high incidence of dysmyelination. In this paper we report the case of a female infant with multiple congenital abnormalities, craniofacial dysmorphism, severe mental retardation and severe hypotonia, who was found to have deletions of the long arm of chromosomes 13 and 18. We included her in a rehabilitation program from the age of eleven months. Rehabilitation programs aimed improving hypotonia as well as stimulating the development of motor skills. We observed the case for a period of one year, periodic monitoring of muscle tone and performance, along with the neurological status, showing significant motor and mental improvement. Conclusions: Rehabilitation treatment is effective and must be an early intervention.

Keywords: chromosomal abnormality, hypotonia, rehabilitation.

INTRODUCTION

Congenital anomalies represent one of the priority problems in pathology. The etiology and pathogenetic mechanisms remain to be clarified for most birth defects. Many congenital anomalies are assumed to be caused by the interaction of gene mutations and environmental factors, about 10-13% have a purely environmental cause and about 12-25% of anomalies have genetic causes. Of these, the majority are chromosomal anomalies [12]. Since the description of the first chromosome aberration, trisomy 21, the number of detectable chromosomal abnormalities has increased to several thousands [15].

The incidence of congenital defects has increased in the past decades as a consequence of the increasingly number of teratogenic and mutagenic agents from the environment. The classical clinical picture of a chromosomal aberration consists of multiple minor and major anomalies, mental and growth retardation. Many chromosomal abnormalities can be clinically recognized on the basis of their pattern of minor and major anomalies. Growth is often delayed both during prenatal and postnatal life. Hypotonia and mental retardation are also characteristic for autosomal aberrations.

Regarding karyotype-phenotype correlations it was noticed that for most chromosomal regions, deletions have a more adverse impact on the phenotype than duplications. The number of possible aberrations and combinations is almost unlimited [4, 16]. Deletion of long arm of chromosome 13 is characterized by malformations of the craniofacial region, skeletal abnormalities, other physical abnormalities and intellectual disability [8]. Deletion of the long arm of chromosome 18 is a rare chromosomal disorder with a phenotype that may vary considerably in range and severity, depending on the type of deletion and location of the breakpoint [14]. Subjects have characteristic features including short stature, mental retardation, hypotonia, malformations of the hands and feet,

craniofacial abnormalities and numerous neurologic deficiencies with a high incidence of dysmyelination [7, 10].

MATERIALS AND METHODS

We report the case of a 1 year 10 months old female, admitted in Medical Rehabilitation Hospital 1Mai Spa, because of severe motor and psychic retardation and delayed acquisitions. The history of the subject reveals that she is the first child, born at 38 weeks of pregnancy, after a toxic pregnancy, from non consanguineous parents. There was no family history of epilepsy. Her parents did not report any significant disease. At birth it was needed oxytocin for prolonged delivery and there was umbilical cord compression. In evolution it was noticed that motor development was delayed: head lifting at 6 months, rolling over at one year and four months, sitting with no support at one year and ten months. At 7 months was diagnosed with growth failure, heterotaxia, intestinal malposition, pilonidal sinus, parietofrontal cavernous hemangioma and craniofacial dysmorphism,. The tests for cytomegalovirus infection or toxoplasmosis during pregnancy were negative, thus these teratogenic embriofetopathies were excluded.

RESULTS

Clinical and functional evaluation revealed:

- *at 11 months:* constitutional pale skin, craniofacial dysmorphism, plagiocephaly, low-set ears, prominent antehelix, ogival palate, high, prominent forehead, cavernous parietofrontal hemangioma, plan occipital hemangioma, "rickety rosary," aspect of the ribs, ligamentous hyperlaxity, severe hypotonia, low weight for age, typical floppy infant appearance. Other clinical findings were: marked axial hypotonia, when lifting the child the head falls backward and forward, dorsolumbar kyphosis keeping the child in sitting position, upper limb hypotonia with mild amyotrophy,

thumb abnormal implantation with rare movements of opposition, leading to the aspect of simian like hand (Fig. 1A), severe prehension deficits, severe ability deficits, range of motion (ROM) over the normal range due to hypotonia, rare active movements. Regarding the lower limbs: abnormal implantation of the fourth toe (Fig. 1B), more obvious in the left foot, hypotonia, frog-leg position (Fig. 2), no active movements, muscular strength F0 were noticed. In vertical position did not bear own weight and was not able to stand without support (Fig. 3). She also showed psychic retardation – developmental level of 3-4 months.

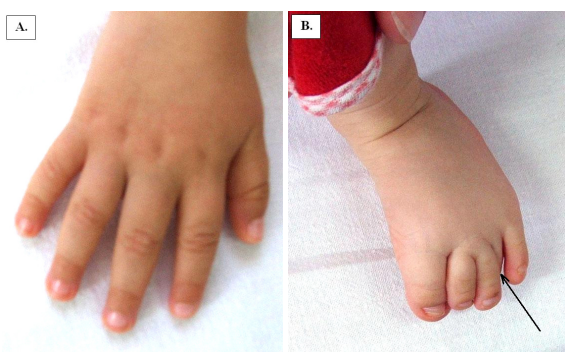


Figure 1. Abnormalities of fingers with thumb implantation in the same plan with the other fingers (1A) and abnormal implantation of the fourth toe (1B)

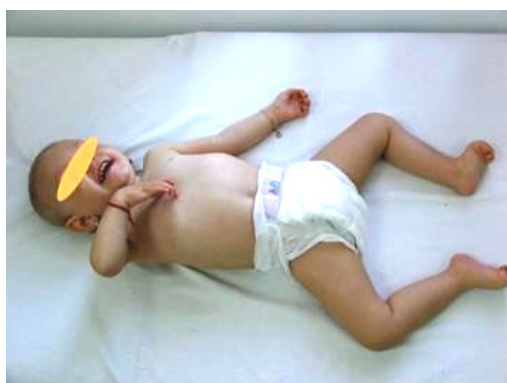

Figure 2. General aspect with frog-leg position of the lower extremities

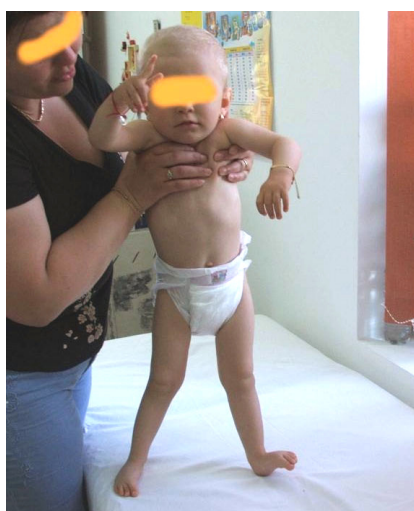


Figure 3. Hypotonia leading to impossibility of standing without support

- *at 1 year 10 months:* Several differences were noticed when compared with the initial evaluation. Thus, dorsolumbar kyphosis kept the child in sitting position, due to secundary axial hypotonia; regarding the upper limbs hypotonia was present, but with active movements, being able to catch objects, transfer objects from one hand to another, perform bye, bye hand movements at verbal command, communicate, but remained moderate impairment of fine motricity and prehension. An improvement for the lower limbs was also seen, with active movements in vertical plane, muscular strength F2+. In vertical position was able to sustain own weight, standing with help being also possible. Other acquisitions were rolling, independent sitting position (Fig. 4), maintaining orthostatic position with help. Psychic development level of 8 months was now established. The intestinal malformation led to weight deficit.

Paraclinical exams revealed: stomach in right hypochondriac region, antropiloric region and duodenum to the left, small intestine placed in the left side of abdomen, colon mostly to the right lumbar region and transverse colon in upper abdomen, intestinal malrotation. Head MRI was normal. EMG (electromyography) - in lower extremities is negative for a neurological lesion, suspicion of miogenic lesion. Cytogenetic analysis performed in Spain revealed an

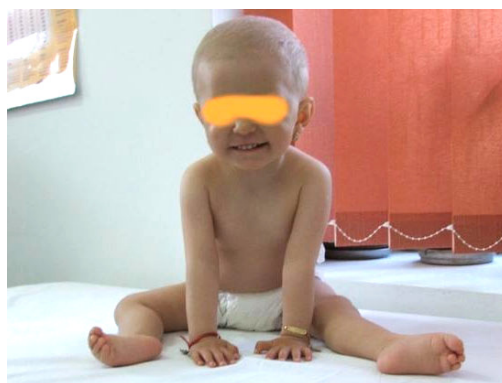

Figure 4. Independent sitting after rehabilitation program

abnormal karyotype, seemingly with 45 chromosomes, with the two X chromosomes present, but with deletions of the long arms of a chromosome 13 and a chromosome 18, with a translocation between the remaining parts.

A positive diagnosis of plurimalformative syndrome with cromosomopathy 13 and 18; tetraparesis with hypotonia; severe motor retardation; developmental delay; parietofrontal cavernous hemangioma; occipital plan hemangioma; heterotaxia with intestinal malpositioning was established.

The subject followed a rehabilitation program for over a year from the age of eleven months. Rehabilitation programs aimed improving hypotonia as well as stimulating the development of motor skills. We observed this case for a period of one year, periodic monitoring of muscle tone and performance, along with the neurological status, showing significant motor and mental improvement. At eleven months we

included her in a rehabilitation program, three weeks intensive program in the clinic, follow up at home with physical therapy for one month. The subject reentered the program every two months.

The objectives were:

- prevent muscle atrophy,
- maintain joint mobility,
- improve muscle tone in spine muscles, in order to obtain in short time head lifting, rolling and for long time to obtain orthostatic position. Meanwhile we stimulated the development of motor skills.

Intensive rehabilitation program consisted of:

- Hydrotherapy and aquatic therapy in thermal water, at the beginning of treatment three times a week, then daily. The exercise in water was performed for increasing muscle tone in arms, legs and spine.
- Electrotherapy consisted of ionogalvanization with CaCl₂ 5% in upper and lower extremities, electrical stimulation in cervical and dorsal muscles and in lower extremities.
- Magnetotherapy used an impulse program that had a biotrophic effect.

- General tonifiant with daily massage was also performed.

- Paraffin application on lower extremities every second day in order to increase local blood circulation and for trophic effect was used for three weeks only.

- Physical therapy was performed in two sessions of 30 minutes every day. The first session consisted of strengthening exercises for trunk stabilization aimed to increase muscle tone in spine muscles, abdominal muscles, upper and lower extremities muscles. The second session included elements from Bobath's method known as neurodevelopmental treatment. Physical therapy improved fine motor control and overall body strength.

- Occupational and speech-language therapy aimed to help breathing, speech and swallowing difficulties. Therapy also included sensory stimulation programs.

We evaluated the subject at every admission in clinic, showing significant improvement at every three months as seen in the table below.

Table 1: Evaluation results at admission, at 3 and 6 months after entering rehabilitation program

| Item | First admission | After 3 months | After 6 months |
|--------------------|----------------------|-----------------------------------|------------------------------------|
| Age | 11 months | 1year 2 months | 1year 8 months |
| Physical abilities | - | + | ++ |
| Head lifting | - | + | + |
| Rolling | - | - | + |
| Sitting | - | With help | Independent |
| Standing | - | - | Sustain body weight |
| Hand motor | Rare movements (F=0) | Antigravitational movements (F=2) | F=3 |
| Hand ability | - | Take and keep object | Transfer objects to the other hand |
| Prehension | - | Digitopalmar | Polidigital |
| Hypotonia | Severe | Moderate | Moderate/mild |
| Lower limb | No movement | Slight move horizontal (F2) | Lifting leg rare |
| | Frog-leg position | Frog-leg position | Frog-leg position |
| Archaic reflexes | - | + | + |
| Language | 3-4 months | 6 months | 8 months |
| Weight | Underweight (6800g) | Underweight (7600g) | Underweight (8700g) |

F- muscle force

Survival and life expectancy for this case is good, considering evolution under rehabilitation treatment. Case particularity: in this case the response to rehabilitation treatment improved muscle tone and motor skills, mental development. The absence of cardiac or other malformations (e.g. splenic), frequently mentioned in literature in heterotaxia syndrome, improve life expectancy [3].

DISCUSSION

Cases with deletion 18q can be missing up to 30 Mb of DNA, a region encompassing approximately 100 known genes. This region contains seven known genes, one of which encodes for myelin basic protein (MBP) [9]. MBP is a key structural protein of myelin in the central nervous system, thought to play a major role in myelin compaction; therefore, it is a logical candidate gene for the dysmyelination phenotype [11], although this has not yet been proved [1, 6].

Myelination indicated a delay in onset of myelin development and that myelination proceeds at a lower rate in 18q- cases than in typically developing ones. There are comparative studies of MRI in healthy subjects and those of individuals with 18q-, with low gray matter-white matter contrast, that is key diagnostic pattern of dysmyelination [2, 5]. This pattern can persist beyond their first decade. The dysmyelination pattern appears to be global, all brain regions having less than 50% the myelin water pool levels of healthy subjects [13]. Other studies reveal that although low gray matter-white matter contrast may be a diagnostic pattern of delayed or reduced myelin formation, no direct evidence has been reported to confirm this in vivo [9]. In this subject slow myelination can be the cause of severe hypotonia. Partial monosomy 13q is a rare chromosomal disorder that results when a piece of the long arm of chromosome 13 is deleted. These cases may have low birth weight, dysmorphisms of the craniofacial region,

skeletal abnormalities, especially of the hands and feet and other congenital defects. Mental retardation is characteristic. The range and severity of symptoms may vary greatly, depending upon the exact size and location of the deletion on 13q [8]. Affected subjects may also show delays in the acquisition of skills requiring the coordination of mental and muscular activity. Deletions limited to proximal bands (q13-q31) are characterized mainly by growth retardation but no major deformities, those involving band 32q are usually associated with numerous major malformations, and distal deletions are usually complicated by severe mental retardation with comparatively minor abnormalities.

Most hypotonic cases have delayed developmental milestones, but the severity of delay can vary widely [17]. Motor skills are particularly susceptible to be affected. They can be divided into two areas, gross motor skills and fine motor skills, both being affected. Cases with hypotonia are late in lifting the heads, rolling over, balancing, lifting themselves into a sitting position, remaining seated without falling over, crawling and walking. Fine motor skills delays occur in grasping a toy or finger, transferring a small object from hand to hand, pointing out objects, following movement with the eyes. Identifying the causes of congenital hypotonia is sometimes difficult, but abnormalities of the autosomes frequently lead to hypotonia. Assessment of cases with hypotonia is best accomplished by a multidisciplinary team including pediatricians, medical geneticists, neurologists and physical or occupational therapists. Treatment normally involves massive amounts of stimulation in order to improve muscle function and control.

REFERENCES

- [1] Barker, L.E., (1988): 18q-syndrome and white matter alterations [comment]. *Am. J. Neuroradiol.* 19: 399.
- [2] Barkovich, A.J., Kjos, B.O., Jackson, D.E. (1988): Normal maturation of the neonatal and infant brain: MR imaging at 1.5T. *Neuroradiology* 166: 173-180.
- [3] Choi, M., Borenstein, S.H., Hornberger, L., Langer, J.C. (2005): Heterotaxia syndrome: the role of screening for intestinal rotation abnormalities. *Arch. Dis. Child.* 90: 813-815.
- [4] De Gregori, M., Ciccone, R., Magini, P., Pramparo, T., Gimelli, S., Messa, J., Novara, F., Vetro, A., Rossi, E., Maraschio, P., Bonaglia, M.C., Anichini, C., Ferrero, G.B., Silengo, M., Fazzi, E., Zatterale, A., Fischetto, R., Previderé, C., Belli, S., Turci, A., Calabrese, G., Bernardi, F., Meneghelli, E., Riegel, M., Rocchi, M., Gueneri, S., Lalatta, F., Zelante, L., Romano, C., Fichera, M., Mattina, T., Arrigo, G., Zollino, M., Giglio, S., Lonardo, F., Bonfante, A., Ferlini, A., Cifuentes, F., Van Esch, H., Backx, L., Schinzel, A., Vermeesch, J.R., Zuffardi, O. (2007): Cryptic deletions are a common finding in "balanced" reciprocal and complex chromosome rearrangements: a study of 59 patients. *J. Med. Genet.* 12: 750-762.
- [5] Dietrich, R.B. (1999): Maturation, myelination, and dysmyelination. In: Stark DD, Bradley WG, eds. *Magnetic Resonance Imaging*, 3rd ed., St. Louis, Mosby-Year Book, 3: 1425-1447
- [6] Gabrielli, O., Coppa, G.V., Carloni, I., Salvolini, U. (1998): 18q- syndrome and white matter alterations [comment]. *Am. J. Neuroradiol.* 19: 398.
- [7] Gay CT, Hardies LJ, Rauch RA, Lancaster, J.L., Plaetke, R., Du Pont, B.R., Cody, J.D., Herndon, R.C., Ghidoni, P.D., Schiff, J.M., Kaye, C.I., Leach, R.J., Fox, P.T., (1997): Magnetic resonance imaging demonstrates incomplete myelination in 18q- syndrome: evidence for myelin basic protein haploinsufficiency. *Am. J. Med. Genet.* 74: 422-431.
- [8] Gilbert, F., (2000): F "Chromosome 13". *Genet Test.* 4(1): 85-94.
- [9] Lancaster, J.L., Cody, J.D., Andrews, T., Hardies, L.J., Hale, D.E., Fox, P.T., (2005): Myelination in Children with Partial Deletions of Chromosome 18q, *Am J Neuroradiol*, 26: 447-454.
- [10] Kamholz, J., Spielman, R., Gogolin, K., Modi, W., O'Brien, S., Lazzarini, R., (1987): The human myelin-basic-protein gene: Chromosomal localization and RFLP analysis. *Am. J. Hum. Genet.* 40: 365-373.
- [11] Kline, A.D., White, M.E., Wapner, R., Rojas, K., Biesecker, L.G., Kamholz, J., Zackai, E.H., Muenke, M., Scott, C.I. Jr., Overhauser, J. (1993): Molecular analysis of the 18q-syndrome: and correlation with phenotype. *Am. J. Hum. Genet.* 52: 895-906.
- [12] Kumar V., Abbas AK., Fausto N. (2005): Genetic disorders. pp. 473-475. In Robbins and Cotran Pathologic Basis of Disease ed. 7: Elsevier Saunders, Philadelphia.
- [13] Loevner, L.A., Shapiro, R.M., Grossman, R.I., Overhauser, J., Kamholz, J., (1996): White matter changes associated with the deletions of the long arm of chromosome 18 (18q- syndrome): a dysmyelinating disorder? *Am. J. Neuroradiol.* 17: 1843-1848.
- [14] Manolagos, E., Kosyakova, N., Thomaidis, L., Neroutsou, R., Weise, A., Mihalatos, M., Orru, S., Haris-Kokotas, H., Kitsos, G., Liehr, T., Petersen, M.B., (2008): Complex chromosome rearrangement in a child with microcephaly, dysmorphic facial features and mosaicism for a terminal deletion del (18) (q21.32-qter) investigated by FISH and array-CGH: Case report. *Mol. Cytogenet.* 1: 24.
- [15] Schinzel, A. (2001): Catalogue of Unbalanced Chromosome Aberrations In Man (2nd ed). Berlin & New York: Walter de Gruyter.
- [16] Shaw, C.J., Lupski, J.R., (2004): Implications of human genome architecture for rearrangement-based disorders: the genomic basis of disease. *Hum. Mol. Genet.* 13: 57-64
- [17] Souraty, N., Sanlaville, D., Chedid, R., Le Lorc'h, M., Maurin, M.L., Ghanem, L., Maalouf, S., Vekemans, M., Megarbane, A., (2007): Cytogenetic investigation of a child with a mosaic isochromosome 18q and ring 18q. *Eur. J. Med. Genet.* 50: 379-385.