

SHORT COMMUNICATION

Renal-Pulsed Wave Doppler Ultrasonographic Findings of Normal Turkish Angora Cats

Remzi Gonul*, Lora Koenhems, Alper Bayrakal, Taner Bahceci, M. Erman and Abdulkadir Uysal

Department of Internal Medicine, Faculty of Veterinary Science, Istanbul University, Avcilar-34320, Istanbul/Turkey,

*Corresponding Author: gonul@istanbul.edu.tr

ARTICLE HISTORY

Received: March 07, 2011
Revised: April 07, 2011
Accepted: April 20, 2011

Key words:

Doppler
Pulsatility index
Renal resistive index
Turkish angora cats

ABSTRACT

Both resistive index (RI) and pulsatility index (PI) estimate vascular resistance within an artery. But, there are only few studies reporting normal values of the renal RI and PI in healthy cats but no study could be found with regard to Turkish Angora breed of cats. So, we decided to determine the normal values of intra-renal RI and PI in non-sedated, non-hypertensive clinically normal Turkish Angora breed cats. For this purpose 20 each of mixed-breed and Turkish Angora breed, different ages and sex healthy cats constituted the study groups. At the result of the pulsed wave doppler ultrasonographic examinations mean values for RI and PI were 0.61 ± 0.04 and 0.97 ± 0.17 for mixed-breed cats; 0.60 ± 0.07 and 1.16 ± 0.34 for Turkish Angora breed cats were recorded, respectively. No significant differences were noted between the groups. At the result, we determined that, they were in normal limits as previously described in clinically healthy Turkish Angora breed of cats.

©2011 PVJ. All rights reserved

To Cite This Article: Gonul R, L Koenhems, A Bayrakal, T Bahceci, M Erman and A Uysal, 2011. Renal-pulsed wave doppler ultrasonographic findings of normal Turkish angora cats. *Pak Vet J*, 31(4): 369-370.

INTRODUCTION

Early identification of renal disease and the institution of therapy is critical (Brown *et al.*, 1997; Miyazaki *et al.*, 2007). Both resistive index (RI) and pulsatility index (PI) estimate vascular resistance within an artery (Petersen *et al.*, 1997; Hosotani *et al.*, 2002). But, only few studies can be found about the renal RI and PI in healthy and diseased dogs and cats, but there are not any studies about normal values for Turkish Angora breed of cats. So, we decided to determine the normal values for intra-renal RI and PI in non-sedated, non-hypertensive clinically normal Turkish Angora breed of cats.

MATERIALS AND METHODS

Twenty each of mixed-breed and Turkish Angora breed of cats aged between 1-7 years, including both males and female cats were included in the present study. All animals were found to be clinically normal and non-hypertensive. No sedation was offered to any of these animals included in the study.

Color Doppler ultrasonography was performed with a Terason 2000 ultrasound machine. A multi-frequency transducer was used to scan. After color Doppler visualization, pulse Doppler waves were obtained according to the technique for determining the renal RI

and PI (Novellas *et al.*, 2008). Student's t-test was used for the statistical analysis.

RESULTS AND DISCUSSION

At the pulsed wave doppler ultrasonographic examinations mean value for RI and PI were 0.61 ± 0.04 and 0.97 ± 0.17 for mixed-breed cats; 0.60 ± 0.07 and 1.16 ± 0.34 for Turkish Angora breed cats, respectively (Fig. 1-3).

The RI and the PI are related to chronic renal failure, urinary obstruction or vasoconstriction, hypertension and age (Sigirci *et al.*, 2006). Sedation or anesthesia may also modify these indices (Novellas *et al.*, 2007). Also, they are related with plasma norepinephrin, aldosteron and renin activity (Sigirci *et al.*, 2006; Novellas *et al.*, 2008). No animals in this study had tension or heart rate problems. On the other hand, the upper limits of RI and PI are important (Novellas *et al.*, 2007). So, Novellas *et al.* (2007) reported that upper value of RI was 0.70 for healthy cats. Similarly, in the present work we determined 0.72 for Turkish Angora breed of cats.

In this study, the upper limit for PI in Turkish Angora breed of cats was 1.23 and mean was 1.16 ± 0.34 . These values were same as previous reported (Novellas *et al.*, 2007) where the mean was 1.02 ± 0.12 and the upper limit was 1.29.

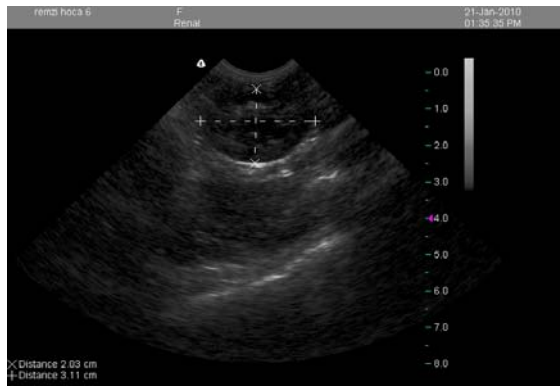


Fig. 1: B-mode ultrasonography of kidney in a cat.

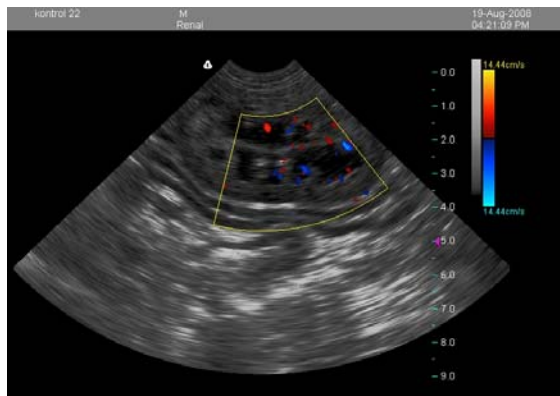


Fig. 2: Color Doppler visualization of renal vasculature in a cat.

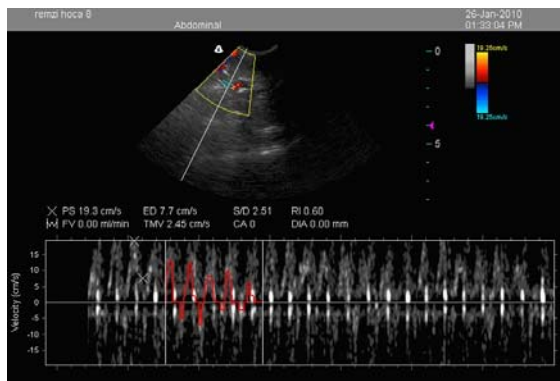


Fig. 3: Color Doppler visualization of renal vasculature and pulsed Doppler volume sample location in an interlobar artery in a cat.

In this study, normal values for intra-renal RI and PI in non-sedated, non-hypertensive clinically healthy Turkish Angora breed of cats were determined. At the result, we determined that, they were in normal limits as previously described.

Acknowledgement

The authors wish to acknowledge Research Fund of Istanbul University for supporting this research (Project number: UDP-6501/26032010).

REFERENCES

- Brown SA, WA Crowell, CA Brown, JA Barsanti and DR Finco, 1997. Pathophysiology and management of progressive renal disease. *Vet J*, 154: 93-109.
- Hosotani Y, N Takahashi, H Kiyomoto, K Ohmori, H Hitomi, H Fujioka, Y Aki, M Fukunaga, S Yuasa, K Mizhusige and M Kohno, 2002. A new method for evaluation of split renal cortical blood flow with contrast echocardiography. *Hypertens Res*, 25: 77-83.
- Miyazaki M, S Soeta, N Yamagisi, H Taira, A Suzuki and T Yamashita, 2007. Tubulointerstitial nephritis causes decreased renal expression and urinary excretion of cauxin, a major urinary protein of the domestic cat. *Res Vet Sci*, 82: 76-79.
- Novellas R, Y Espada and RR Gopegui, 2007. Doppler ultrasonographic estimation of renal and ocular resistive and pulsatility indices in normal dogs and cats. *Vet Radiol Ultrasound*, 48: 69-73.
- Novellas R; RR Gopegui and Y Espada, 2008. Increased renal vascular resistance in dogs with hepatic disease. *Vet J*, 178: 255-260.
- Petersen LJ, JR Petersen, U Talleruphuus, SD Ladefoged, J Mehlsen and HAE Jensen, 1997. The pulsatility index and resistive index in renal arteries. Associations with long-term progression in chronic renal failure. *Nephrol Dial Transplant*, 12: 1376-1380.
- Sigirci A, T Hallac, A Akinci, I Temel, H Gulcan, M Aslan, M Kocer, B Kahraman, A Alkan and R Kutlu, 2006. Renal interlobar artery parameters with duplex doppler sonography and correlations with age, plasma renin, and aldosterone levels in healthy children. *Am J Roentgen*, 186: 828-832.