

Food Deprivation Depletes Gastric Mucus Glycoprotein in Streptozotocin-Induced Diabetic Rats

Shigeki Igarashi, Eisuke Kume, Hiroshi Narita and Mine Kinoshita

Discovery Research Laboratory, Tanabe Seiyaku Co., Ltd., 2-2-50 Kawagishi, Toda-shi, Saitama 335-8505, Japan

Received December 6, 1999 Accepted June 30, 2000

ABSTRACT—Fasting causes gastric mucosal damage in streptozotocin (STZ)-induced diabetic rats, but its pathogenic mechanism remains to be elucidated. The aim of the present study was to investigate the alteration of gastric mucosal mucin, one of the gastric defensive factors against the development of such damage. Diabetes was induced in rats by intravenous injection of STZ (65 mg/kg). The experiments were performed using 4-week STZ-diabetic rats with blood glucose levels above 350 mg/dl. The amount of gastric mucus glycoprotein was determined by gel filtration, and the distribution of neutral and acidic mucins in the stomach epithelium was examined by histochemical analysis. In normal rats, 24-h fasting neither affected the gastric mucin content nor caused any macroscopic gastric mucosal injury. In contrast, starvation significantly reduced the amount of total gastric mucus glycoprotein prior to the formation of mucosal lesions in the STZ-diabetic rats. Nine hours after food deprivation, the gastric damage developed in about 70% of the diabetic rats, the amount of mucus glycoprotein markedly decreased, and both the neutral and acidic mucins diminished in the epithelium. Taken together, in STZ-diabetic rats, fasting by itself depletes gastric mucus glycoprotein, and this depletion may be involved in the pathogenic mechanism of the formation of gastric mucosal lesions.

Keywords: Fasting, Gastric lesion, Gastric mucus glycoprotein, Streptozotocin-induced diabetic rats

In normal rats, fasting for less than 24 h does not by itself cause gastric mucosal damage, but fasting in the presence of ulcerogenic stimuli such as NSAIDs, alcohol, hypersecretion of gastric acid, stress and hypothermia can cause hemorrhagic mucosal lesions (1–5). In contrast, overnight fasting by itself causes severe gastric damage in diabetic rats induced by streptozotocin (STZ) as well as pancreatectomy (6–8). Fasting-induced profound hypoglycemia and the depletion of gastric mucosal glutathione (GSH) were suggested to be associated with the formation of gastric lesions in this diabetic model (7, 8). However, the pathogenic alteration of gastric mucosal protective functions such as alkaline and mucus secretion and mucosal blood flow has been poorly understood.

Gastric mucosal lesions develop when there is an imbalance between the aggressive factors (acid and pepsin) and protective factors (mucus, bicarbonate secretion and mucosal blood flow). Mucin, a highly glycosylated glycoprotein, which is secreted from both gastric surface mucous cells and mucous neck cells, forms a viscous mucus gel that is adherent to the mucosal surface (9). This adherent mucus gel layer constitutes the first line of mucosal defense against the insults by a variety of exogenous and endogenous noxious agents (10). The viscous and gel-form-

ing properties of the mucus are dependent on the polymeric structure of the native high molecular weight glycoprotein (11). Reduction of the mucin content and/or degradation of the polymeric structure of mucin in the adherent gel layer appear to play a pathogenic role in the formation of gastric ulcer (12). In the present study, we examined the alteration of the amount of gastric mucus glycoprotein after food deprivation in STZ-diabetic rats.

MATERIALS AND METHODS

Animals and chemicals

Male Sprague-Dawley rats (Charles River Co., Kanagawa) weighing 136–174 g were used. The animals were fed standard rat food (CE-2; Clea, Tokyo) and supplied with tap water ad libitum. Streptozotocin, purchased from Sigma Chemicals (St. Louis, MO, USA), was dissolved in saline containing 12.5 mM citrate immediately before intravenous administration in the dosage volume of 2 ml/kg body weight. All other reagents were of analytical grade.

Induction of diabetes

Vehicle (saline containing 12.5 mM citrate) or STZ (65 mg/kg) was intravenously injected to rats after fasting for

24 h. After 4 weeks, rats with blood glucose levels above 350 mg/dl in the feeding condition were judged to be diabetic and used in the following experiments.

Assessment of gastric mucosal lesions

Control and diabetic rats were deprived of food at 8:00 a.m. but allowed free access to tap water, and they were individually housed in wide-mesh wire bottom cages to prevent the ingestion of hair and feces. After a designated time (control rats, 0 and 24 h; diabetic rats, 0, 3, 6, 9, 12 and 24 h after food deprivation), the stomach was excised under ether anesthesia. The stomach was inflated by injection of 10 ml of 1% formalin solution into the lumen to fix the gastric walls and opened along the greater curvature. The area of gastric mucosal lesions was measured under a dissecting microscope with a square grid.

Measurement of the amount of total gastric mucus glycoprotein

Control and diabetic rats were fasted and the stomachs were excised as mentioned above. The excised stomach was opened along the greater curvature and gently rinsed with ice-cold saline. The glandular portions of two stomachs were pooled and lyophilized. Gastric mucus glycoprotein was extracted and measured according to the method of Ohara et al. (13) as follows. The lyophilized samples were weighed and each suspended in 5 ml of 50 mM Tris-HCl buffer (pH 7.2) containing 2% Triton® X-100. After boiling (100°C, 3 min), the sample was homogenized with a Physcotron microhomogenizer (Niti-on, Chiba). The homogenate was incubated at 37°C for 1 h and centrifuged at $10,000 \times g$ at 4°C for 30 min, and the supernatant was saved. The Tris-HCl buffer containing 2% Triton® X-100 was added to the pellet, which was then re-homogenized, and this extraction procedure was repeated three times. A 2-ml aliquot of the pooled supernatant was applied to a HiPrep Sephacryl S-300 HR column (1.6 × 60 cm; Amersham Pharmacia Biotech, Tokyo), which had been pre-equilibrated with the Tris-HCl buffer containing 2% Triton® X-100, and the column was eluted with this buffer. The eluted fractions (5 ml each) were assayed by the phenol-sulfuric acid method using galactose as a standard (14). The amount of hexose in the void fraction was determined as gastric mucus glycoprotein. The amount of mucus glycoprotein was expressed as mg hexose per g of dry tissue.

Measurement of the amount of glycoprotein in the adherent gel layer

Control and diabetic rats were fasted as mentioned above, and the stomach was excised before and 9 h after food deprivation. The stomach was opened along the greater curvature and washed gently with ice-cold saline.

The adherent materials on the glandular portion of the stomach were gently scraped with a fine spatula. The scraped materials from three stomachs were pooled and lyophilized. Adherent gastric mucus glycoprotein was extracted from the lyophilized samples and measured as described above.

Histochemical study

Control and diabetic rats were fasted as mentioned above, and the stomach was excised after a designated time (control rats, 0 h; diabetic rats, 0 and 9 h after food deprivation). The stomach was opened along the greater curvature, pinned on a cork board, and immersed in Carnoy's fixative. After fixation, the stomach specimens were embedded in paraffin. Four-micron sections were prepared and stained with periodic acid Schiff (PAS) and alcian blue (AB) at pH 2.5, and then they were examined under a light microscope.

Statistical analysis

Data are presented as the mean ± S.E.M. Statistical analysis was performed by Student's *t*-test or by one-way analysis of variance (ANOVA) followed by a Bonferroni test. A *P* value less than 0.05 was considered to be statistically significant.

RESULTS

In control rats, 24-h fasting neither caused any macroscopic damage nor affected the amount of total gastric mucus glycoprotein (Fig. 1). In the STZ-diabetic rats, however, even 6-h fasting caused slight gastric damage in one-third of the rats. The area and incidence of the damage subsequently increased, and at 12 h after food deprivation, severe hemorrhagic lesions were observed in almost all the diabetic rats (Fig. 1A). The amount of total mucus glycoprotein in the STZ-diabetic rats significantly decreased 6 h after food deprivation and fell to near the nadir after 9-h fasting (Fig. 1B). Thus, fasting reduced the gastric mucus glycoprotein prior to the development of mucosal damage in the STZ-diabetic rats.

Nine hours after food deprivation, when the gastric damage was observed in over two-thirds of the STZ-diabetic rats, the amount of mucus glycoprotein in the adherent gel layer was determined. The content of mucus glycoprotein in the gel layer decreased to about 20% of the level before fasting (Fig. 2). In the histochemical study, there was no difference in the amounts of both the PAS-positive (neutral) and the AB-positive (acidic) mucins in control and STZ-diabetic rats before food deprivation (data not shown). In the STZ-diabetic rats, the hemorrhagic damage was observed scatteringly, both PAS-positive and AB-positive mucins apparently diminished in both the epithelium

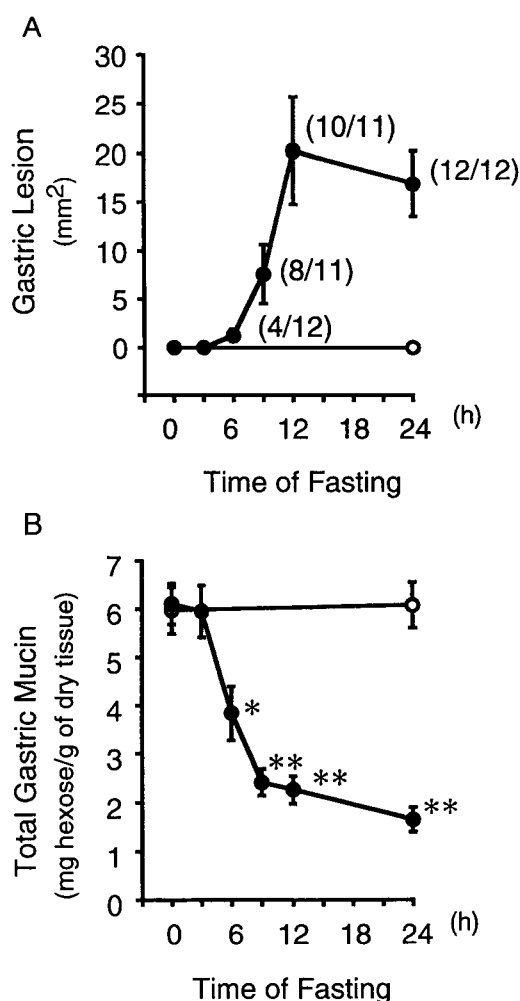


Fig. 1. The effect of fasting on the formation of gastric mucosal lesions and the amount of total gastric mucin in the control (open circles) and STZ-induced diabetic (closed circles) rats. A: Gastric lesions. Data represent the mean \pm S.E.M. of 11–12 rats. The number in parentheses indicates the incidence of gastric lesion development. B: Mucus glycoprotein. Data represent the mean \pm S.E.M. of 6–7 preparations. * and **: $P < 0.05$ and $P < 0.01$, respectively, compared with the value at 0 h.

and the adherent gel layer 9 h after food deprivation (Fig. 3).

DISCUSSION

In normal rats, fasting alone is not sufficiently ulcerogenic to the gastric mucosa unless other ulcerogenic stimuli coexist (1–5). However, overnight fasting has been reported to induce gastric mucosal damage in both diabetic rats induced by pancreatectomy and genetically diabetic mice (8, 15). In the present study, fasting for as short a period as 9 h caused gastric damage in more than two-thirds of the STZ-diabetic rats, and severe hemorrhagic lesions were ob-

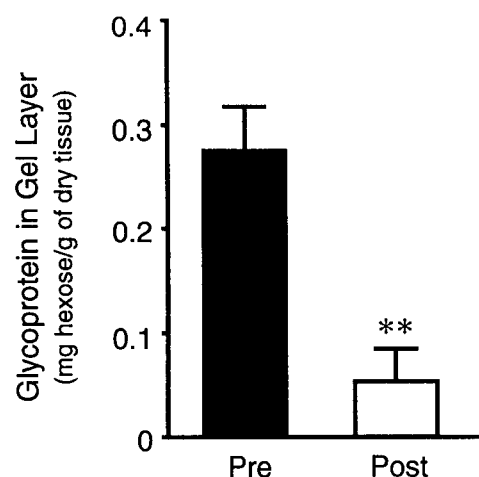


Fig. 2. The effect of 9-h fasting on the amount of gastric mucus glycoprotein in the adherent gel layer in the STZ-induced diabetic rats. Data represent the mean \pm S.E.M. of 6 preparations. **: $P < 0.01$, compared with the pre-value.

served in almost all the diabetic rats 12 h after food deprivation. Thus, under diabetic conditions, fasting for even less than 12 h by itself is likely to be an ulcerogenic factor on the gastric mucosa.

In the STZ-diabetic rats, the amount of total mucus glycoprotein in the gastric mucosa markedly decreased prior to the development of gastric damage after food deprivation, and the amount of mucin in the adherent gel layer diminished before the severe gastric damage developed. The mucus gel layer is recognized to protect the gastric mucosa from the damaging effects of acid, pepsin and bile acid through the polymeric structure of mucus glycoprotein (16). Takeuchi et al. has reported that fasting-induced gastric lesions were prevented by both the treatment with atropine and vagotomy, suggesting that the acid-back diffusion is involved in the formation of this hemorrhagic lesions in STZ-rats (7). Thus, the depletion of the mucus glycoprotein in the adherent gel layer and acid-back diffusion would be cooperatively involved in the formation of fasting-induced gastric lesions in STZ-rats.

Ohara et al. (17) has reported that the amount of gastric mucus glycoprotein increases with the duration of fasting in normal rats. In contrast, food deprivation rapidly reduced the gastric mucin content in the STZ-diabetic rats. The present histochemical study indicated that fasting reduced both the neutral and acidic glycoproteins, which are secreted from the epithelial mucous cells and mucous neck cells, respectively. This observation suggests the possibility that a common biosynthetic step which may exist between the neutral and acidic mucins, i.e., the uptake of glucose into both types of the mucous cells, core protein synthesis, or *O*-glycosylation of the core peptides might be

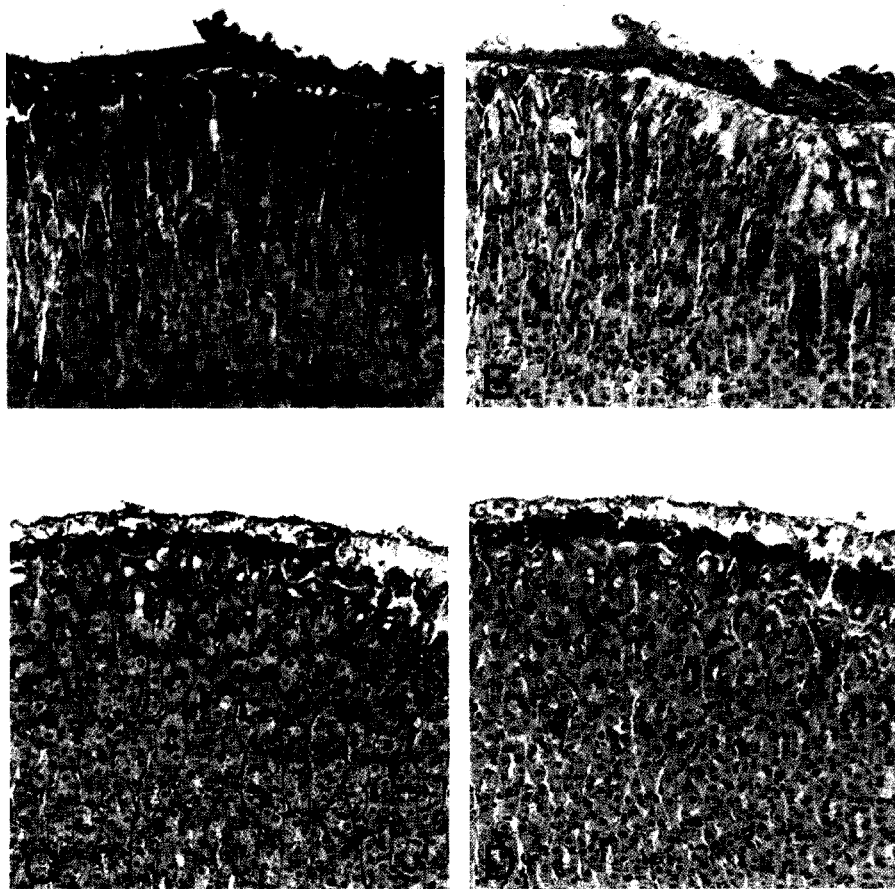


Fig. 3. Light micrographs of the gastric mucosa in the STZ-induced diabetic rats before and 9 h after food deprivation. A and B: Before fasting. The PAS-positive (violet) and the AB-positive (blue) mucins abundantly existed in both the epithelium and the adherent mucus gel layer. C and D: After 9-h fasting. The PAS-positive and the AB-positive mucins diminished in the epithelium and the adherent gel layer. A and C, PAS staining; B and D, AB staining at pH 2.5. Magnification, $\times 200$.

impaired in fasted STZ-diabetic rats. Further investigation, however, is required to clarify the exact mechanism(s) of starvation-evoked depletion of gastric mucus glycoprotein only in this diabetic model.

The present study revealed the contribution of depletion of gastric adherent mucin to the fasting-induced gastric lesion formation in the diabetic rats; however, alterations of other gastric defensive functions have not been thoroughly examined. Goldin et al. (8) reported that the gastric mucosal blood flow was not influenced by diabetes, ruling out the ischemic component as a pathogenic mechanism. They also reported that, in STZ-diabetic rats, food deprivation reduced the level of endogenous antioxidant GSH (8), which maintains the integrity of the gastric epithelial cells against various oxidative stresses (18, 19). These observations suggest that fasting impairs the luminal first line of the gastric defense system such as the adherent mucus gel layer and the integrity of the epithelial cells, resulting in the

development of gastric mucosal damage in STZ-diabetic rats.

Taken together, fasting alone is sufficient to deplete the gastric mucus glycoprotein level in STZ-diabetic rats, and this depletion may be involved in the pathogenic mechanism of the formation of gastric mucosal lesions.

Acknowledgments

We thank Ms. N. Saito and Mr. M. Jinbo for their excellent experimental technical assistance and Dr. S. Takeyama for his helpful advice on the manuscript.

REFERENCES

- 1 Ueki S, Takeuchi K and Okabe S: Gastric motility is an important factor in the pathogenesis of indomethacin-induced gastric mucosal lesions in rats. *Dig Dig Sci* 33, 209–216 (1988)
- 2 Qiu BS, Pfeiffer CJ and Cho CH: Effects of chronic nitric oxide synthase inhibition in cold-restraint and ethanol-induced gastric

- mucosal damage in rats. *Digestion* **57**, 60–66 (1996)
- 3 Shay H, Komarov SA, Fels SS, Meranze D, Gruenstien M and Siplet HA: A simple method for the uniform production of gastric ulceration in the rat. *Gastroenterology* **5**, 43–61 (1945)
 - 4 Hirota M, Inoue M, Ando Y, Hirayama K, Morino Y, Sakamoto K, Mori K and Akagi M: Inhibition of stress-induced gastric injury in the rat by glutathione. *Gastroenterology* **97**, 853–859 (1989)
 - 5 Niida H, Takeuchi K and Okabe S: Role of thyrotropin-releasing hormone in acid secretory response induced by lowering of body temperature in the rat. *Eur J Pharmacol* **198**, 137–142 (1991)
 - 6 Piyachaturawat P, Poprasit J, Glinsukon T and Wanichanon C: Gastric mucosal lesions in streptozotocin-diabetic rats. *Cell Biol Int Reports* **12**, 53–63 (1988)
 - 7 Takeuchi K, Ueshima K, Ohuchi T and Okabe S: Induction of gastric lesions and hypoglycemic response by food deprivation in streptozotocin-diabetic rats. *Dig Dig Sci* **39**, 626–634 (1994)
 - 8 Goldin E, Ardite E, Elizalde JI, Odriozola A, Panés J, Piqué JM and Fernández-Checa JC: Gastric mucosal damage in experimental diabetes in rats: role of endogenous glutathione. *Gastroenterology* **112**, 855–863 (1997)
 - 9 Neutra MR and Forstner JF: Gastrointestinal mucus: synthesis, secretion, and function. In *Physiology of the Gastrointestinal Tract*, 2nd ed, Edited by Leonard R and Johnson R, pp 975–1009, Raven Press, New York (1987)
 - 10 Allen A, Hunton DA, Leonard AJ, Person JP and Sellers LA: The role of mucus in the protection of the gastroduodenal mucosa. *Scand J Gastroenterol Suppl* **128**, 6–13 (1987)
 - 11 Pearson JP, Allen A and Venables CW: Gastric mucus: isolation and polymeric structure of the undegraded glycoprotein: its breakdown by pepsin. *Gastroenterology* **78**, 709–715 (1980)
 - 12 Younan F, Pearson J, Allen A and Venables C: Changes in the structure of the mucous gel on the mucosal surface of the stomach in association with peptic ulcer disease. *Gastroenterology* **82**, 827–831 (1982)
 - 13 Ohara S, Ishihara K, Kakei M, Azuumi Y and Hotta K: Distribution of macromolecular glycoproteins in rat stomach. *Comp Biochem Physiol* **72**, 309–311 (1982)
 - 14 Dubois M, Gilles KA, Hamilton JK, Robers PA and Smith F: Colorimetric method for determination of sugars and related substances. *Anal Chem* **28**, 350–356 (1956)
 - 15 Kinoshita M, Igarashi S, Kume E, Saito N and Arakawa K: Fasting cause impairment of the gastric mucosal integrity in non-insulin-dependent diabetic (db/db) mice. *Aliment Pharmacol Ther* **14**, 359–366 (2000)
 - 16 Allen A: Structure and function of gastro-intestinal mucus glycoproteins and viscous and gel forming properties of mucus. *Br Med Bull* **34**, 28–33 (1978)
 - 17 Ohara S, Kakei M, Ishihara K, Katsuyama T and Hotta K: Effects of fasting on mucus glycoprotein in rat stomach. *Comp Biochem Physiol* **79B**, 325–329 (1984)
 - 18 Olson CE: Glutathione modulated toxic oxygen metabolism injury of canine chief cell monolayers in primary culture. *Am J Physiol* **254**, G49–G56 (1988)
 - 19 Martensson J, Jain A and Meister A: Glutathione is required for intestinal function. *Proc Natl Acad Sci* **87**, 1715–1719 (1990)