

Value of distal base sural flap (interosseous flap) - A clinical study

Malkesh D. Shah *, Jagdish J. Patwa, Keyur B Patel, Aditya K Agarwal and Neel H Patel

Sumandeep Vidyapeeth University, Vadodara, India

***Correspondence Info:**

Dr. Malkesh D. Shah

Sumandeep Vidyapeeth University,

Vadodara, India

E-mail: shahmalkesh@yahoo.com

Abstract

Introduction: Distal Base Sural Flap is a very important flap to cover the posterior as well as weight bearing area of heel with single rotation flap. The indications include post traumatic defect with compound comminuted fracture calcaneum with partial or complete rupture of tendoachilles, squamous cell carcinoma over heel following non-healing ulcer, and non-healing ulcers over heel due to other causes.

Materials and Method: Skin and deep fascia of leg are incised from proximal to distal, sacrificing the sural nerve and the short saphenous vein. The flap medially follows the lateral border of the Achille's tendon, and laterally the fibula. When defect is on heel, the medial incision can reach the edge of the defect. The flap is then rotated at 180° to cover the defect. Functional and aesthetic outcomes are evaluated in terms of complete or partial flap survival, successful coverage of the recipient defect, healing of any underlying fracture proved radiographically, ease or difficulty in walking or wearing shoes, ambulatory status of the injured limb after six months and any concerns of the patient regarding the aesthetic appearance of the flap. Donor site healing and complications are also recorded.

Results: We have done 10 cases using this flap and got 8 excellent results, 1 good and 1 poor result. Our maximum follow up period is of 2yrs & minimum is of 6months.

Conclusion: Distally based sural flap is an excellent procedure in selected cases for covering the defect. Patients are back on his/her own feet within short time and able to put full weight without any complication in follow up period.

Keywords: Sural flap, Tendoachilles, STG

1. Introduction

Soft tissue management around the lower third of the leg and foot poses a considerable challenge to the reconstructive surgeon because of the composite tissue defects, inadequate and tight local tissues and poor circulation [8]. Tendons, bones or implants are frequently exposed because of the thinness of subcutaneous tissues, making skin grafting a poor option [1]. The possibilities of coverage of such defects are few, the flap chosen should be easy to excise quickly with minimal discomfort to the patient, and should provide durable coverage for the defects [12,13]. Anatomical studies of the blood supply to the skin, deep fascia, and the septo-cutaneous perforators have encouraged the harvesting of very large fasciocutaneous flaps in the leg. Poter in 1980 first described the concept of fasciocutaneous flaps of the lower limb. He had stressed on the advantage of fasciocutaneous flaps and their reliability and safety in lower leg reconstruction [16].

Our indications are:

- 1) Post traumatic defect with compound comminuted fracture calcaneum with partial rupture of tendoachilles.
- 2) Squamous cell carcinoma over heel following non-healing ulcer.
- 3) Non healing ulcer over heel due to other causes like diabetes.

2. Materials and Methods

Pre-operative Assessment: Preoperatively the age and sex of each patient, cause, size and site of the defect, time since injury, exposure of bone or tendons, presence of chronic osteomyelitis, and any co-morbid conditions were noted. All patients with exposed bones or fractures were radiographed.

Technique[4]:

Skin and deep fascia of the leg are incised from proximal to distal, sacrificing the sural nerve and the short saphenous vein. The mass of fat between

tibia and fibula extending to the medial border of the achilles tendon is included as it contains branches from the peroneal artery.

Basic Design: Flap can be of 15cms in length and 5-6cms wide, with pedicle of 3cms width (Fig. 1).

Landmarks for Flap: Medially follows the lateral border of the Achille's tendon, and laterally the fibula (Fig. 1). When defect is on heel, the medial incision can reach the edge of the defect (laterally up to the tip of lateral malleolus and medially upto the insertion of tendoachilles into the tuberosity of the calcaneum).

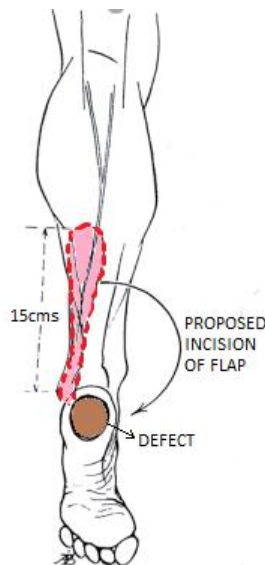


Figure 1: Proposed incision of flap and defect

After rotation it is important that the flap lies in the recipient site without tension, before the use of sutures, so as to avoid postoperative venous stasis. After rotation of the flap most of the donor site can be closed primarily, If needed donorsite also can be closed by STG and the small skin fold which is produced disappears spontaneously in several weeks (Fig. 2).

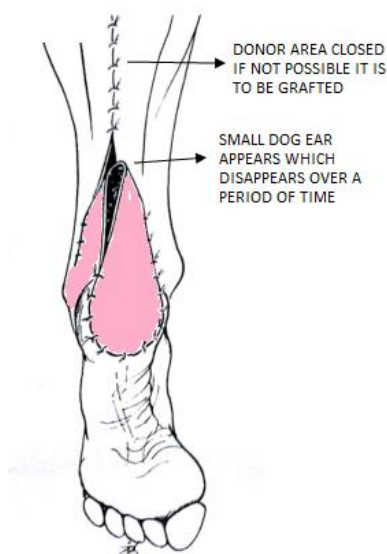


Figure 2: 180° Rotation of Flap to cover the defect over heel without any impairment of circulation

A sural based pedicled flap used to fill loss of substance of the lateral side of the calcaneum (Fig. 3). An additional small flap has been also raised to facilitate skin closure and the distal part of the original flap has been deepithelialised. The final appearance with the defect filled with a “rolled up” graft (Fig. 3).

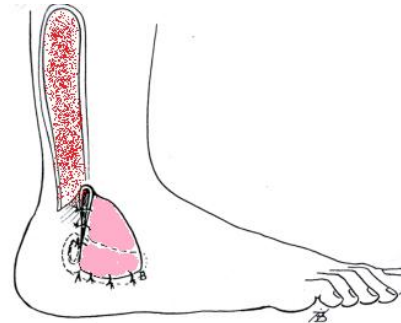


Figure 3: Small flap to cover lateral aspect of ankle and foot

Per operatively dimensions of the flap, level of proximal flap margin when designed on the leg (which would be the distal flap end when mobilised over the defect), island or paddled, tunnelling or exteriorising of the pedicle, capillary refill or any congestion at the end of the procedure were recorded.

Post-operative Care: In the immediate postoperative period the flap was monitored for any venous congestion or pallor.

Functional and aesthetic outcomes were evaluated in terms of complete or partial flap survival, successful coverage of the recipient defect, healing of any underlying fracture proved radiographically, ease or difficulty in walking or wearing shoes, ambulatory status of the injured limb after six months and any concerns of the patient regarding the aesthetic appearance of the flap. Donor site healing or any other complications were also recorded. The patients were questioned about any complications related to the loss of sensibility in the sural distribution area, i.e., the lateral side of the foot, painful neuromas, or concerns about the aesthetic disfigurement at the donor site. Pre- and postoperative photographs of each patient were taken and the surgical procedure was performed by one surgeon. Patients were discharged on the 3rd postoperative day in case of uneventful recovery and followed up on the 5th postoperative day to remove the graft dressing. They were followed for at least 6 months.

3. Results

Our study included 10 patients with average age of 48 ± 8 years. There were 8 males and 2 females in the study. There were 6 cases with degloving injury over distal ankle involving foot with 2 cases of open fractures of the calcaneum, 1 case of posterior malleolar fracture. The rest of the cases included the

patients with non healing ulcer due to diabetes, squamous cell carcinoma and neuropathic joint. The average duration between the injury and operation was of 5 ± 2 days for cases of degloving injuries and 2 months for non healing ulcer due to other causes. The average operative time was 95 minutes with minimal blood loss. The STG was done in 4 cases over the donor harvesting site and the rest were closed primarily. All cases had corrugated drain in the site of inset. One case with epidermal necrosis of the flap was also covered with STG.

The patients were followed for a period of 2 weeks, 4 weeks, 8 weeks, 12 weeks, 6 months and yearly thereafter. The patients were advised non weight bearing for 6 weeks, partial weight bearing for next 6 weeks and full weight bearing thereafter.

Table 1: Result

Excellent	8
Good	1(epidermal necrosis)
Poor	1(partial dead flap)
Total Cases	10

Eight flaps had complete success. Colour and viability of the flaps were good up to the tip of the flaps. One flaps developed epidermal necrosis, which was then treated with STG. One flap had complete necrosis, further managed by debridement of necrotic tissue and healing was achieved by secondary means within two to three weeks without the need for further skin grafts. No ulceration was found in either weight-bearing or non-weight-bearing flaps. Also, none of the patients complained of neuroma at the donor site.

In patients who underwent surgical delay, careful dissection of the nerve pedicle revealed a highly vascular pedicle with prominent peri-neural vessels.

Cases:

Case 1:

A 50 years female with non-healing ulcer over distal ankle and foot involving heel region showing pre and post-operative photographs with flap coverage.

Pre-operative

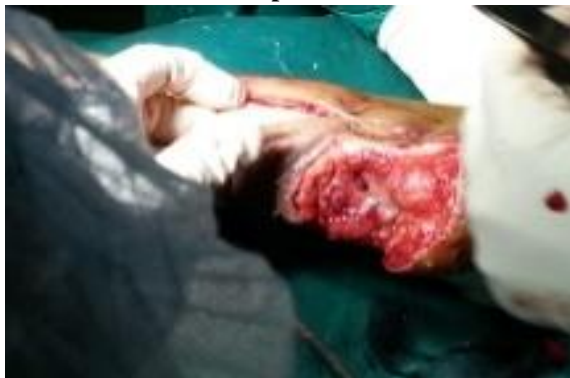

Figure 4a: Pre-operative photographs of non-healing ulcer over right heel.

Post-operative

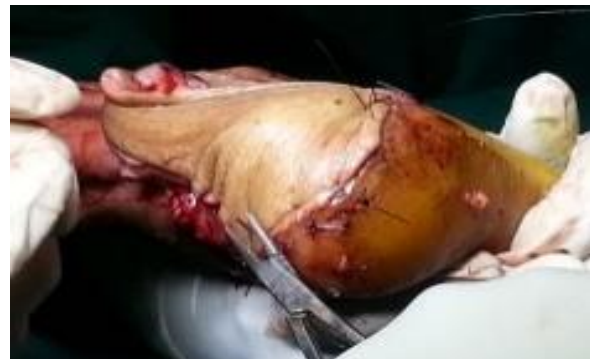

Figure 4b: Intra-operative photographs showing flap over recipient surface.

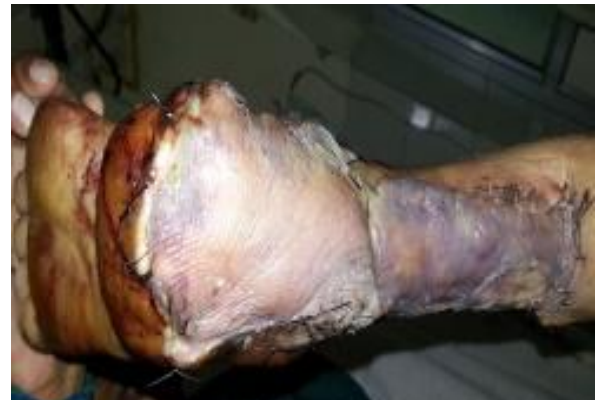

Figure 4c: Post-operative photographs showing flap over heel and posterior aspect.

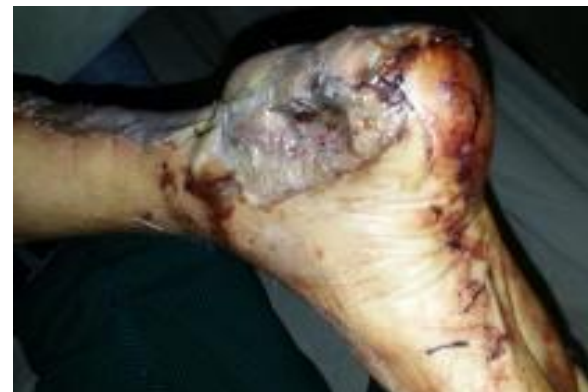

Figure 4d: Post-operative photograph with flap over right heel

Follow up



Figure 4e: Follow-up photographs showing well accepted flap.

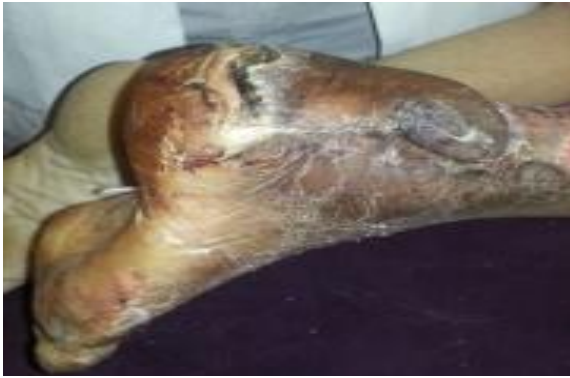

Figure 4f: Follow-up photographs showing well accepted flap.

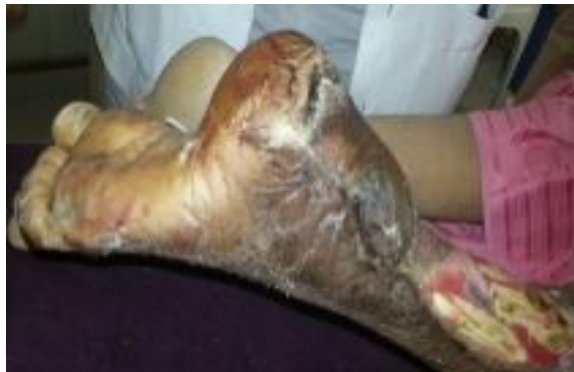

Figure 4g: Follow-up photographs showing well accepted flap.

Case 2:

Post operative photographs with final follow up of a case of 46 years male with acute degloving injury of the right distal ankle involving the lateral and posterior aspect of the foot. The flap has been accepted with satisfactory cosmetic and functional outcome

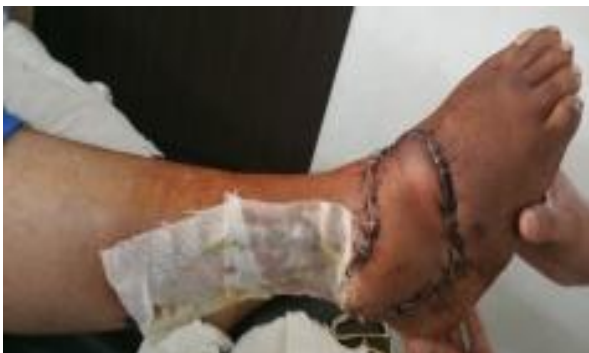

Figure 5a: Immediate post-operative photograph.

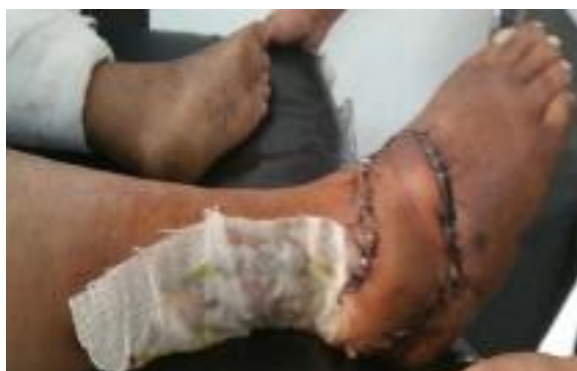

Figure 5b: Immediate post-operative photograph.

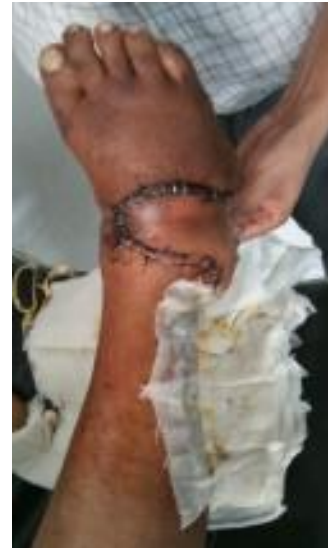

Figure 5c: Immediate post-operative photograph.

Follow-up

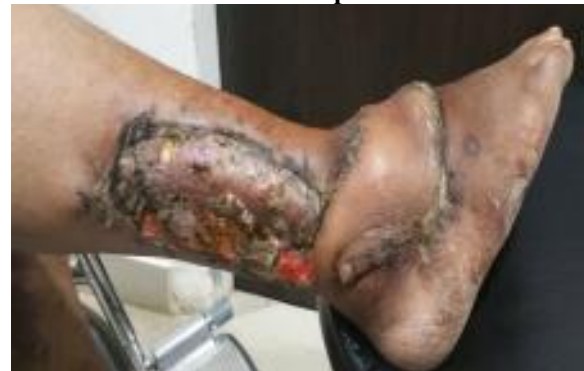

Figure 5d: Follow-up photograph showing well accepted Flap with cosmetic blemish.

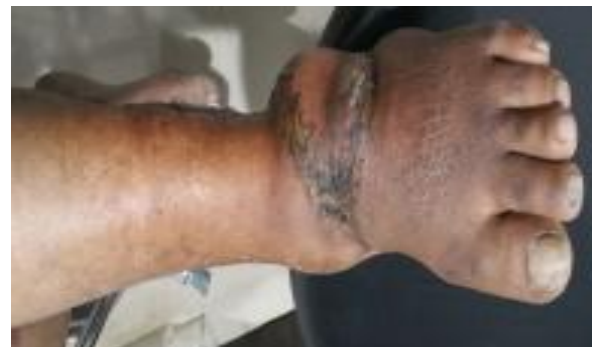

Figure 5e: Follow-up photograph showing well accepted Flap with cosmetic blemish

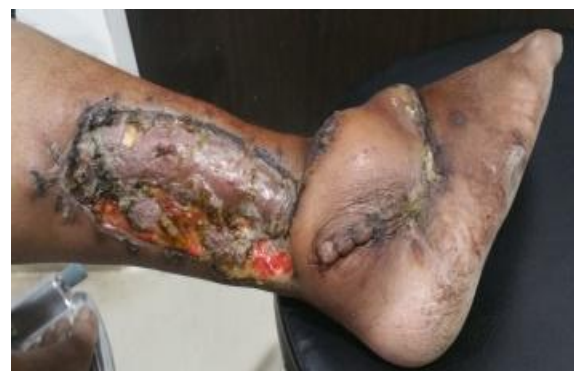

Figure 5f: Follow-up photograph showing well accepted Flap with cosmetic blemish

Case 3:

63 years male with non-healing ulcer over the right heel and neuropathic ankle joint operated with distal based sural flap showing pre and post-operative photographs. Weight bearing area is properly covered with flap and remaining area is grafted.

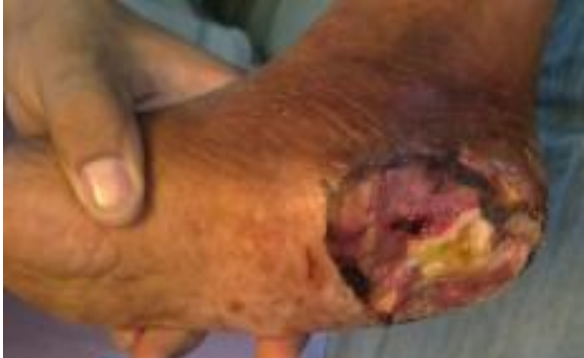

Figure 6a: Pre-operative photograph of non-healing ulcer

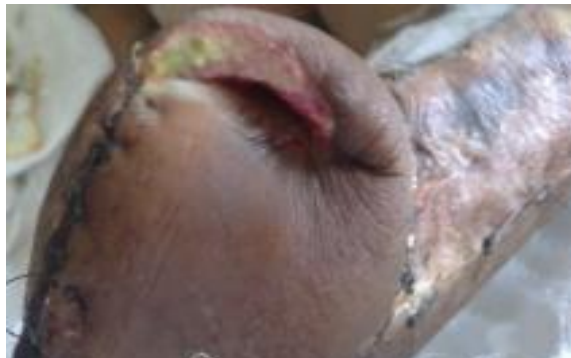

Figure 6b: Immediate post-operative photograph with dog ear over the flap.

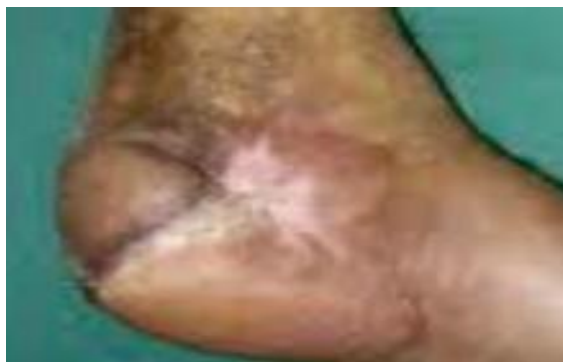

Figure 6c: follow-up photograph of well accepted Flap

4. Discussion

Reconstruction of the lower leg and foot continues to be one of the most challenging tasks for the reconstructive plastic surgeon. An unreliable lower limb subdermal plexus translates to notoriously poor wound healing using cutaneous flaps [9]. Following the developments in flap surgery, pedicled fasciocutaneous flaps and free flaps have been used. The introduction of distally based sural

fasciocutaneous flap provides reliable and effective method to cover the skin defects of distal leg, foot and ankle [12,14]. The defects reported in the literature that needed repair, include those resulting from road traffic accidents, non-healing skin wounds, chronic venous ulcers, chronic osteomyelitis in diabetes, contractures, gangrene, unstable scars, cancer resections, and electrical burns [6,15]. The major cause of defects in our patients included trauma due to road traffic accidents, similar to some other studies [1,17]. The lower leg and heel were the most frequently involved sites in our study. The flap can be used to cover exposed vessels, bones, tendons, and internal fixation of respective implants. It has been shown to be more reliable and a better choice than the lateral supramalleolar flap (another distally based fasciocutaneous flap used in the distal lower extremity). The flap has been shown to be successful in diabetic and medically compromised patient [11].

Anterior and posterior tibial vessels occlusion and varicose leg veins are not considered an absolute contraindication to the use of a distally based sural flap [5,10]. An occluded peroneal artery is however considered a contraindication. One of our patients had varicose veins of short and long saphenous systems. However, his flap showed no congestion in the postoperative period and survived completely. Similarly another patient was a non-insulindependent diabetic for the last 10 years. His flap used for anterior tibial coverage also survived completely with an uneventful recovery. We noted complete flap survival in 80% of our patients, partial flap loss due to epidermal necrosis in 10% and complete loss in 10%, being comparable to other studies. Successful coverage of the defect was achieved in our study in (90%) of patients: complete survival 80% and marginal epidermal necrosis 10% (the necrosed area was debrided, flap advanced and resutured to the defect). A meta-analysis of 50 articles that report the use of 720 distally based sural flaps, suggested 82% success rate of the flap. Complete flap necrosis was reported in 3.3%, and partial or marginal flap necrosis in 11% [7]. Similarly, a detailed retrospective analysis of sural flap complication rate was recently performed on a series of 70 consecutive flaps. The complication rate reported was 59% (41 of 70 flaps), partial necrosis was noted in 17% and complete necrosis in 19% flaps [2]. Akhtar¹ in his study of 84 patients observed flap survival in 78.5%, partial necrosis in 16.5% and complete necrosis in 9.5%. The flaps that showed marginal or partial necrosis showed postoperative congestion. One of these was used for anterior tibial defect while others were for heel and dorsum of foot defects.

The only flap that showed complete loss in our study was in a patient with extensive heel defect

due to a road traffic accident. We suspect that due to the shearing and avulsion of surrounding tissues the perforator 5 cm proximal to the lateral malleolus, which was the point where we pivoted the flap, might have been injured. Many studies have shown the usefulness of Doppler in such cases [7]. It is therefore recommended that in cases with extensive trauma, Doppler identification of the perforators be done before deciding on the pivot point. The pivot point is determined by the position of the perforator supplying the flap [3].

The advantages of the distally based sural flap are:

- 1) The flap can be used in cases of questionable vascularity of the distal ankle and foot where mid plantar flap have to be avoided [4].
- 2) The distal based sural flap is less morbid to the patient than compared to cross leg flap in terms of bed rest, hospitalization, infection, early mobilization and cosmesis.
- 3) This flap is large enough to cover the defect over distal ankle and foot. Thus the tunnelling of the flap and thereby necrosis is avoided [3].

The disadvantages and risk factors for the distally based sural flap are:

- 1) Damage to the peroneal vascular bundle and perforators over the lateral border of Achilles tendon and lateral malleoli by inadvertent raising of the fat pad may cause necrosis of the flap [4].
- 2) The dog ear and bulkiness of the flap may cause cosmetic blemish which may not be acceptable to the patient. However, the dog ear subsides on its own over a period of time [4].
- 3) The patient needs to carry non-weight bearing walking for around 2 months post-operatively.
- 4) Venous congestion is an area of considerable concern in this flap and can be considered as a major cause for the failure of the flap. Venous congestion causes back pressure build up that progressively impairs flow in the capillary bed, arterioles and eventually arterial inflow. Tissue ischemia sets up a vicious cycle that eventually results in tissue necrosis [3].
- 5) Other safety measures include the harvest of a long racket handle to facilitate the inseting [3].

The limitation of our study is small number of patients and shorter follow up due to which statistical analysis could not be done. Also, the Doppler ultrasound was not used pre-operatively to assess the distal vascular bundles and the perforators.

5. Conclusion

The distally-based sural fasciocutaneous flap is a reliable procedure to repair difficult wounds such as plantar heel and lateral calcaneal areas and is gaining acceptance as an alternative to free flaps for injuries of the lower third of the leg, ankle and heel. The main advantages of this flap are the reliable blood supply, maintenance of major arteries, easy elevation, and large arc of rotation and direct closure of donor areas for small flaps. The morbidity of this flap is negligible being limited to that arising from division of the sural nerve. This does not produce any serious problem, especially if the adjacent nerves, the superficial and deep peroneal nerves are intact.

References

- [1] Akhtar S, Hameed A. Versatility of the sural fasciocutaneous flap in the coverage of lower third leg and hind foot defects. *J Plast Reconstr Aesthet Surg* 2006; 59:839–45.
- [2] Baumeister SP, Spierer R, Erdmann D et al. A realistic complication analysis of 70 sural artery flaps in a multimorbid patient group. *Plast Reconstr Surg* 2003; 112:129–40.
- [3] Bien-Keem Tan, Jane Lim, Colin Song. Flaps – Techniques and Applications. EAZI Printing Pte Ltd. 2008.
- [4] Oberlin C., Bastian D., Greant P., Bhatia A., Pedicle Flaps for coverage of the Limbs- A practical Guide. Arihant Book House 1997.
- [5] Cavadas PC, Bonanand E. Reverse-flow sural island flap in the varicose leg. *Plast Reconstr Surg* 1996; 98:901–2.
- [6] Chen SL, Chen TM, Chou TD, Chang SC, Wang HJ. Distally based sural fasciocutaneous flap for chronic osteomyelitis in diabetic patients. *Ann Plast Surg* 2005; 54(1):44–8.
- [7] Follmar KE, Baccarani A, Steffen P, Baumeister L, Levin S, Erdmann D. The distally based sural flap. *Plast Reconstr Surg* 2007; 119:138–48.
- [8] Fracalvieri M, Bogetti P, Verna G, Carlucci S, Favi R, Bruschi S. Distally based fasciocutaneous sural flap for foot reconstruction: a retrospective review of 10 years' experience. *Foot Ankle Int* 2008; 29:191–8.
- [9] Hallock GG. Lower extremity muscle perforators flap for lower extremity reconstruction. *Plast reconstr Surg* 2004; 114:1123–30.
- [10] Hsieh CH, Liang CC, Kueh NS, Tsai HH, Jeng SF. Distally based sural island flap for the reconstruction of a large soft tissue defect in an open tibial fracture with occluded anterior and posterior tibial arteries-a case report. *Br J Plast Surg* 2005; 58:112–5.

- [11] Koladi J, Gang RK, Hamza AA et al. Versatility of the distally based superficial sural flap for reconstruction of lower leg and foot in children. *J Pediatr Orthop* 2003; 23:194–8.
- [12] Masquelet A.C., Romana M.C. and Wolf G.: Skin island flaps supplied by vascular axis of the sensitive superficial nerves: Anatomic study and clinical experience in the leg. *Plast. Reconstr. Surg.* 1992; 89: 1115.
- [13] Morris A.M. and Buchan A.C. The place of the crossleg flap in reconstructive surgery of the lower leg and foot: A review of 165 cases. *Br. J. Plast. Surg.* 1978; 31: 138.
- [14] Mozafari N, Moosavizadeh SM, Rasti M. The distally based neurocutaneous sural flap: a good choice for reconstruction of soft tissue defects of lower leg, foot and ankle due to fourth degree burn injury. *Burns* 2008; 34(3):406–11.
- [15] Pirwani MA, Samo S, Soomro YH. Distally based sural artery flap: A workhorse to cover the soft tissue defects of lower 1/3 tibia and foot. *Pak J Med Sci* 2007; 23:103–10.
- [16] Ponten B.: The fasciocutaneous flap: Its use in soft tissue defects of the lower leg. *Br. J. Plast. Surg.* 1981; 34: 215.
- [17] Raveendran SS, Perera D, Happuharachchi T, Yoganathan V. Superficial sural artery flap-a study in 40 cases. *J Plast Reconstr Aesthet* 2004; 57:266–9.