

Case Report

Genetic analysis in a true hermaphrodite: A case report

Debasis Bandopadhyay¹, Yogesh Rewari² and Arundhati Sharma^{*3}

¹Associate Professor, Department of Anatomy, Armed Forces Medical College, Pune

²Department of Endocrinology, Army Hospital (R&R), New Delhi

³Additional Professor, Department of Anatomy, Teaching Block, AIIMS, New Delhi –110029.

* Correspondence Info:

Dr. Arundhati Sharma

Additional Professor,

Department of Anatomy,

Teaching Block, AIIMS, New Delhi –110029, India

E mail: arundhatisharma1@gmail.com

Abstract

Background: True hermaphrodite is one of the rarest variety of disorders of sexual differentiation (DSD) and represents only 5% cases of all. True hermaphroditism is characterized by the development of ovarian and testicular tissue in the same individual. Müllerian and Wolffian structures are usually present, and external genitalia are often ambiguous. The most frequent karyotype is 46, XX or various forms of mosaicism. We report a 8yrs old child of a serving soldier reared as male. He underwent orchidectomy for right undescended testis at 18 months of age. The biopsy of the testis showed presence of granulosa cells. The external genitalia were clearly identified as male penis with hypospadias. The patient reported to us for cyto-molecular analysis.

Methods: 8ml of venous blood was collected, 5ml in heparin and 3ml in EDTA. The blood in heparin was processed for lymphocyte culture for 72h followed by Trypsin Giemsa banding of cells arrested in metaphase using standard protocol. Cytogenetic analysis of peripheral blood revealed mosaic karyotype with 90% 46, XX and 10% 47, XXY cell line. Genomic DNA was isolated from blood sample in EDTA and then subjected to PCR amplification of SRY gene which showed desired band at 500 bp (SRY gene).

Conclusion: An early gender assessment of true hermaphrodites is of utmost importance for proper psychosocial development of child. Though phallic size is the single most important criteria for gender assessment, a multidisciplinary team of specialists in consultation with parents must assign sex of the child on basis of genitalia, gonads and genetic factors.

Keywords: Disorders of sexual differentiation, Karyotype, Mosaicism, Müllerian, Orchidectomy, True hermaphrodite, Wolffian

1. Introduction

True hermaphrodite is one of the rarest varieties of disorders of sexual differentiation (DSD) and represents only 5% cases of all. True hermaphroditism is characterized by the development of ovarian and testicular tissue in the same individual. Müllerian and Wolffian structures are usually present, and external genitalia are often ambiguous. The most frequent karyotype is 46, XX or various forms of mosaicism like 46, XX/ 46, XY and 46, XX/ 47 XXY.¹ In this condition gonads are asymmetrical having both ovarian and testicular differentiation on either sides separately or combined as ovotestis. The final diagnosis is based on histological demonstration of presence of both types of gonadal epithelium.²

The most frequent karyotype of 46,XX/47,XXY has been attributed to tetragametic chimerism (fertilization of two ova by two sperm forming two zygotes, with subsequent fusion of the zygotes and the development of an individual with mosaic cell lines).³

As per 2006 consensus statement of the European Society of Pediatric Endocrinology (ESPE) the revised terminology of true hermaphrodite is Ovotesticular DSD (Table 1).

Table 1: Revised nomenclature of DSD by European Society of Paediatric Endocrinology

Previous	Revised
Female pseudohermaphrodite	46,XX DSD
Male pseudohermaphrodite	46,XY DSD
True hermaphrodite	Ovotesticular DSD
XX male	46,XX testicular DSD
XY sex reversal	46,XY complete gonadal dysgenesis

In our study we report an 8years old child, a known case of ovotesticular DSD being reared as male referred for genetic analysis to our lab. We planned to evaluate the patient using both conventional cytogenetic study (karyotype) and molecular based studies (Polymerase Chain Reaction). The PCR was performed to detect presence of SRY gene.

2. Case report

We report an 8yrs old child of a serving soldier reared as male. He underwent orchidectomy for right undescended testis at 18 months of age. The other testis was palpable within left scrotum. The biopsy of the removed testis showed presence of granulosa cells. The external genitalia was clearly identified as male penis with hypospadias. He underwent several urethroplasty surgeries for correction of the hypospadias. On Ultrasonography of the pelvis no Mullerian structures were noted. The patient reported to Cyto-molecular laboratory, dept of Anatomy, our hospital for cyto-molecular analysis.

At time of referral to our lab the child weighed 32kgs, 114cm in height and thin built. He was performing well in school and participated actively in all outdoor activity. The hormonal levels showed normal pre-pubertal serum gonadotropin levels with slightly low testosterone level of 5.5 ngm/dl (Normal range 7-130 ngm/dl). On physical examination there was no gynaecomastia and pubic hair (Tanner stage I). On surgical examination of external genitalia the labioscrotal differentiation was seen to be well established with phallic length of 3cms (Tanner stage II). The penoscrotal hypospadias appeared partially reconstructed with well healed scar. The scrotum on left side was normal with palpable testis without any signs of regression. There were no signs of inguinal hernia. Fresh ultrasonography of pelvis detected no mullerian derivatives on either side.

The cytogenetic evaluation was done by karyotype of peripheral blood and molecular analysis for presence of SRY gene was done by polymerase chain reaction (PCR).

First 8 ml of venous blood was collected; 5ml in a heparin for cytogenetic analysis and 3 ml in EDTA vials for DNA analysis after taking informed consent. The lymphocytes were cultured in RPMI 1640 and processed for Trypsin-Giemsa banding as described previously⁴ The slides were viewed under an Olympus BX61 bright field microscope. Almost 20 metaphase spreads were scored for the individual and analysis was done using the Applied spectral imaging (ASI) software (ASI, Israel).

Polymerase chain reaction (PCR) for SRY gene was also carried out in this case. Genomic DNA was isolated from the blood samples collected in EDTA by using standard protocol and then subjected to PCR amplification of SRY gene.⁵

The karyotype analysis detected approximately 90% of the cells with 46, XX (Fig 1 a) and 10% of the cells with 47, XXY karyotype (Fig 1 b).

Figure 1a: Karyotype 46, XX seen in 90%cells

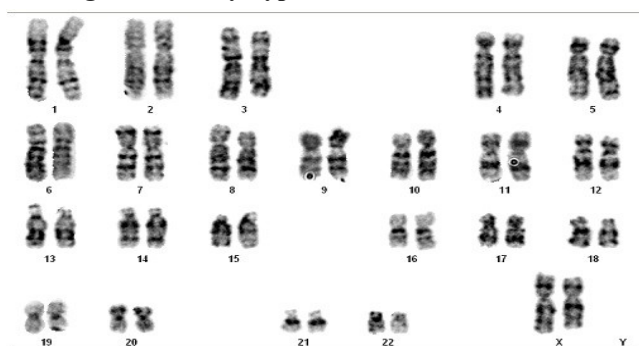
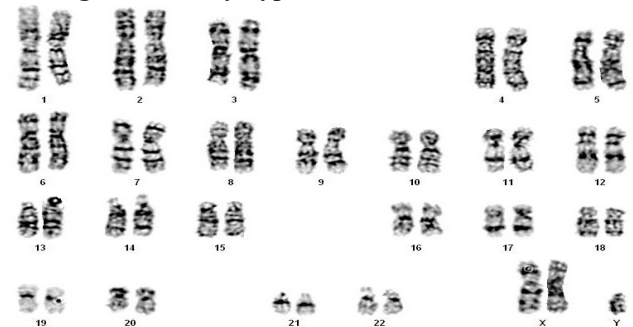
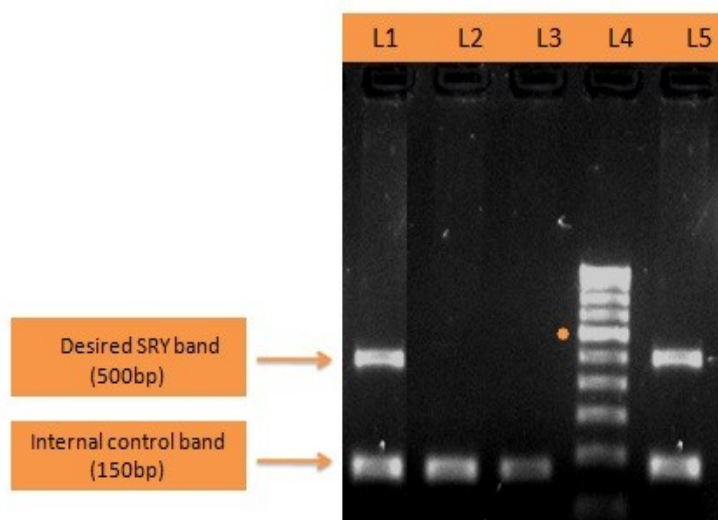


Figure 1b: Karyotype 47,XXY seen in 10%cells



The PCR amplification for the SRY gene was positive (Fig 2).

Figure 2: Gel picture showing presence of SRY gene (L5) in the patient with 46, XX (~90%)/ 47, XXY (~10%) Karyotype



L=lane

L1: Positive control, L2: Negative control 1, L3: Negative control 2, L4:100bp ladder, L5: Patient with positive SRY gene

3. Discussion

The disorders of sex development (DSD) is an uncommon disorder with an incidence of 1:4500 to 1:5000 live births of which true hermaphrodite (Ovotesticular DSD) is responsible for 4% to 10% of all cases of DSD.⁶ Proper gender assignment to a neonate born with DSD is very important for good psychosocial development of the child. The therapeutic success depends upon an early and appropriate gender assignment, proper medical therapy and meticulous surgical interventions wherever required.⁷

Our patient underwent an orchidectomy at an age of 18months for right sided undescended testis which on biopsy revealed presence of granulosa cells suggestive of ovarian histology. The left testis was normal within the scrotum. The USG of pelvis did not indicate presence of any Mullerian structures. A well identifiable penis was the key to gender assessment and the child was reared as male. The hypospadias was corrected by repeated urethroplasty surgeries. The patient was thereafter under the care of endocrinologist.

The patient reported to the lab of Cyto-Molecular Analysis, Dept of Anatomy at age of 8yrs for karyotype and molecular analysis for the presence of SRY gene. He was detected to have mosaic karyotype with 46, XX in approximately 90% cells and 47, XXY in approximately 10% cells. The PCR for SRY gene also showed amplification at desired 500bp band. Since the patient had adequate phallic size he was assigned the male gender. The presence of SRY gene in him brought about testis differentiation with complete regression of the mullerian derivatives. The endocrinologist further planned for Human chorionic gonadotropin stimulation test for testosterone adequacy so that testosterone supplements could be timely administered to ensure adequate development of secondary sexual characteristics.

Ovotesticular DSD may be of lateral type (an ovary on one side and a testis on other side) which is most frequent or may be of unilateral type (ovotestis on one side and ovary or testis on other side) or may be of bilateral type (ovotestis on both sides)⁸. In our patient the distribution of gonad was lateral type with ovarian tissue seen post gonadectomy on right side and well palpable testis felt within left scrotum.

Ovotesticular DSD is rarely associated with gonadal tumours, unlike in mixed gonadal dysgenesis, where the presence of a dysgenetic gonad predisposes to gonadal malignancy. However since few cases of gonadoblastoma and subsequent dysgerminoma has been reported in true hermaphrodites it is advisable to keep the patients on regular follow up for gonadal tumors. However prophylactic removal of gonads is not recommended at all.⁹

4. Conclusion

A full histological, cytogenetic and molecular investigation and hormonal assays with interdisciplinary approach is the key to early and appropriate gender assignment in all cases of DSDs which is essential for good psychosocial development of the child. In ovotesticular DSD the diagnosis is based on histology of the gonad. The gender assignment is based on phallic size. The presence of SRY gene can induce normal male sexual differentiation irrespective of chromosomal sex.

References

1. Krob G, Braun A, Kunhle U. True hermaphroditism: geographical distribution clinical findings, chromosomes and gonadal histology. *Eur J Pediatr*. 1994; 153: 2–7.
2. Fallat ME. Ambiguous genitalia and intersex anomalies. Ziegler MM, Aziz khan RG, Weber TR. Operative pediatric surgery. New York: McGraw-Hill Companies; 2003. pp. 839– 61.
3. Berger-Zaslav AL, Mehta L, Jacob J, Mercado T, Gadi I. Ovotesticular disorder of sexual development (true hermaphroditism). *Urology*. 2009 Feb;73(2):293-6. doi: 10.1016/j.urology.2008.08.428. Epub 2008 Sep 26.
4. Paliwal P, Sharma A, Birla S, Kriplani A, Khadgawat R, Sharma A. Identification of novel SRY mutations and SF1 (NR5A1) changes in patients with pure gonadal dysgenesis and 46, XY karyotype. *Mol Hum Reprod*. 2011; 17(6):372-8.
5. Sambrook J, Russel DW. Molecular cloning: a laboratory manual. 3rd edition. Cold Spring Harbor Laboratory Press 2001, New York.
6. Damiani D, Fellous M, McElreavey K, Barbaux S, Barreto ES, Dichtchekian V, et al. True hermaphroditism: Clinical aspects and molecular studies in 16 cases. *Eur J Endocrinol* 1997; 136:201-4.
7. Donaho PK, Schnitzer JJ. Evaluation of the infant who has ambiguous genitalia and principle of operative management. *Seminr-Pediatric-Surg*. 1996; 5: 30– 40.
8. Grumbach MM, Conte FA. Disorders of sex differentiation, Text book of endocrinology. Ed 6. Philadelphia: W B Saunders, Co. Chap. 9; pp. 198– 473.
9. Mc Donough PG, Rogers Byrd J, Phung TT. Gonadoblastoma in a true hermaphrodite with 46 XX karyotype. *Obstet Gynecol*. 1976; 47: 355– 8.