

PHOTOLETTER TO THE EDITOR

Response of linear porokeratosis to photodynamic therapy in an 11-year-old girl

Cristina Garrido-Colmenero¹, Ricardo Ruiz-Villaverde¹, Eliseo Martínez-García¹, José Aneiros-Fernández², Jesús Tercedor-Sánchez¹

1. Department of Dermatology, Virgen de las Nieves Hospital, Granada, Spain;

2. Pathology Department, Virgen de las Nieves Hospital. Granada, Spain.

Corresponding author:

Cristina Garrido Colmenero, Virgen de las Nieves Hospital, Avenida de las Fuerzas Armadas N°2. 18014 Granada, Spain.

E-mail: cristinagarrido86@gmail.com

Abstract

Porokeratoses are a group of different entities that belong to the skin keratinization disorders. From the histological point of view the main and common characteristic of these disorders is the presence of compact parakeratotic columns known as cornoid lamellae. All varieties should be carefully treated and followed-up because of the risk of developing malignant epithelial tumors. We report the successful response to photodynamic therapy (PDT) in a pediatric patient diagnosed with linear porokeratosis. (*J Dermatol Case Rep.* 2015; 9(4): 118-119)

Key words:

pathology, porokeratosis, treatment, child

Porokeratoses are a group of different entities that belong to the skin keratinization disorders. Different clinical forms have been described based upon the number and distribution of the lesions: porokeratosis of Mibelli, disseminated superficial actinic porokeratosis, linear porokeratosis, porokeratosis palmaris et plantaris disseminata, and punctate porokeratosis. From the histological point of view the main and common characteristic of all of them is the presence of a compact parakeratotic column known as a cornoid lamella. All varieties should be carefully treated and followed-up because of the risk to develop malignant epithelial tumors.¹ We report the successful response to photodynamic therapy (PDT) of a pediatric patient recently diagnosed of linear porokeratosis evaluated at our dermatological unit.

An 11-year-old girl with no relevant personal medical history attended our dermatology outpatient unit presenting red and brownish hyperkeratotic papules following a linear pattern on her left breast (Fig. 1A). No pain or itch was referred. No nail dystrophy was found. Histopathologic examination showed epidermal invagination with an eosinophilic pa-

rakeratotic column, also called cornoid lamellae (Fig. 1C) with no signs of cellular atypia. Routine laboratory investigations (complete blood count, urine analysis, and liver and kidney function tests) were normal. After completing two cycles of topical therapy with adapalene first and topical tacrolimus 0.1% ointment one daily application for 2 months no improvement of the lesions was observed. Photodynamic therapy was the proposed and accepted by the parents of our patient. Methyl aminolevulinate hydrochloride cream in a 160 mg/g concentration (Metvix cream, Galderma, S.A. Lausanne, Switzerland) was applied under occlusion on a previously cleaned surface of every single lesion for 2 hours. The lesions were subsequently illuminated with a dose of 37 J/cm² (Aklite, PhotoCure ASA, Oslo, Norway) for 8 minutes. A second session was performed three weeks later. Burning sensation was referred in every session but no complementary treatment was prescribed. Four months after the second PDT session, just a slightly erythematous few lesions could be appreciated on her breast (Fig. 1B). We consider that the therapy had a good result.

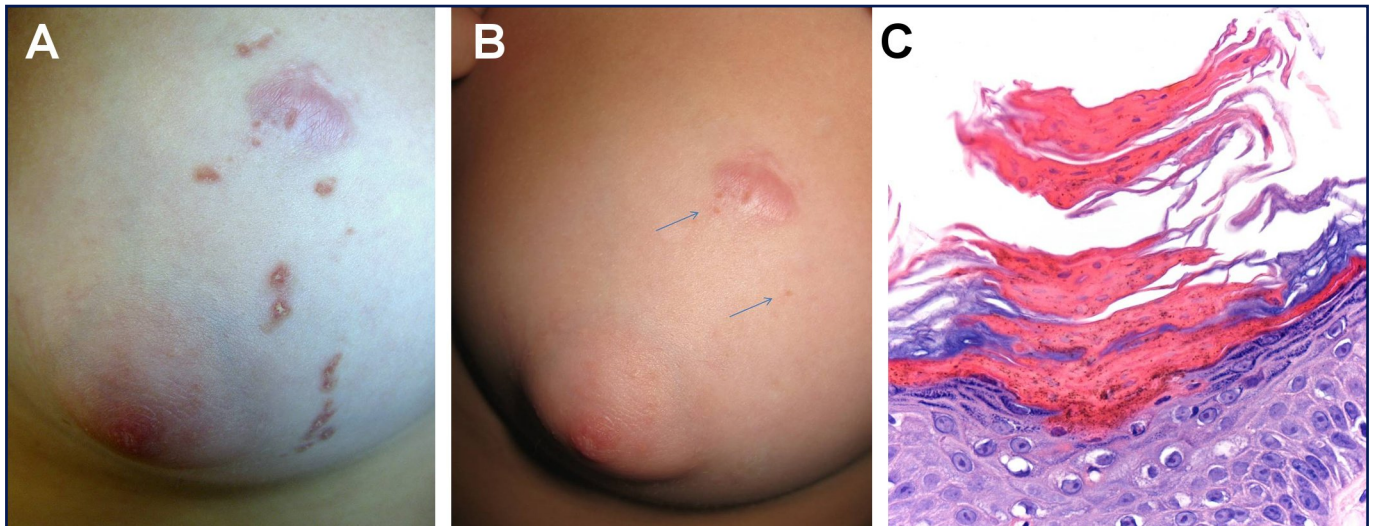


Figure 1

(A) Linear red-brownish papules on the left breast of our patient, (B) Residual lesions (->) 4 months after PDT, (C): HEx200: Cornoid lamellae,

Discussion

Linear porokeratosis is a clinical variant that usually arises in childhood. Extremities are commonly affected exhibiting red or brown hyperkeratotic papules or plaques following a linear distribution that usually matches with Blaschko lines. Nail dystrophy may be observed in some cases. Malignant transformation is associated with different external factors such as immunosuppression or continuous UV light sun exposure² and also factors regarding the clinical lesions (duration, size and exposed or not skin site). On childhood differential diagnosis includes lichen estriatus, linear lichen planus or lineal verrucous epidermal nevus, so skin biopsy is mandatory to rule out the proper diagnosis.

Management of porokeratosis includes the use of topical therapies (keratolytics, corticosteroids, retinoids, fluorouracil cream, imiquimod or calcipotriol cream), systemic therapies (oral retinoids) and invasive therapies with different devices (Q-switched ruby laser, fractional photothermolysis, cryotherapy, carbon dioxide laser ablation, curettage, or dermabrasion). PDT is approved for the treatment of actinic keratosis, superficial and nodular basal cell carcinoma, and Bowen disease. Its use on clinical porokeratosis may be considered as an off-label indication.³

PDT has been used on porokeratosis of Mibelli and disseminated superficial actinic porokeratosis with variable outcome.⁴ Combined therapy with topical treatments may be considered to get a better cosmetic result.⁵ After reviewing

properly the literature published and the therapy applied in our pediatric patient, we consider that PDT is a good therapeutic choice on linear porokeratosis, when using two suitably spaced sessions. It is a well tolerated and safe technique in pediatric patients associated with excellent cosmetic results and minimal adverse effects in the adolescent population, which is mainly affected by this entity.

References

1. Sasson M, Krain AD. Porokeratosis and cutaneous malignancy. A review. *Dermatol Surg*. 1996; 4: 339-342. PMID: 8624658.
2. García-Navarro X, Garcés JR, Baselga E, Alomar A. Linear porokeratosis: excellent response to photodynamic therapy. *Arch Dermatol*. 2009; 145: 526-527. PMID: 19451495.
3. Curkova AK, Hegyi J, Kozub P, Szep Z, D'Erme AM, Simaljakova M. A case of linear porokeratosis treated with photodynamic therapy with confocal microscopy surveillance. *Dermatol Ther*. 2014; 27: 144-147. PMID: 24119172.
4. Gutiérrez Paredes E, Bella Navarro R, Montesinos Villaescusa E, Jordá Cuevas E. Porokeratosis of Mibelli: a new indication for photodynamic therapy? *Actas Dermosifiliogr*. 2013; 104: 259-261. PMID: 23102435.
5. Levitt J, Emer JJ, Emanuel PO. Treatment of porokeratosis of mibelli with combined use of photodynamic therapy and Fluorouracil cream. *Arch Dermatol*. 2010; 146: 371-373. PMID: 20404225.