

Recent Advances in Tape Slings for Female Urinary Stress Incontinence

Red Alinsod, MD, FACOG, FACS

South Coast Urogynecology, Laguna Beach, CA

Sling therapy is the enhanced surgical support of the urethra. In this article, the history of the use of slings for the surgical treatment of female urinary stress incontinence is reviewed, and the usual surgical routes for retropubic (transvaginal) or transobturator tape passage are described. The latest innovation in sling therapy is the use of minislings, which are short tape mesh implants inserted through a single vaginal incision; these slings may be placed in an office setting. Outcomes data are either lacking or suggest a considerable decrement of effectiveness of unstabilized minislings over full-length slings; however, the short-term efficacy of a stabilized, adjustable minisling is 97%. These results suggest benchmark effectiveness associated with full-length slings in a less invasive device that also has the capability of short-term adjustability.

[Rev Obstet Gynecol. 2009;2(1):46-50]

© 2009 MedReviews®, LLC

Key words: Minisling • Urinary stress incontinence • Retropubic sling • Transvaginal tape • Subfascial or transobturator sling • Suburethral sling

Urodynamic stress incontinence (USI) is the leakage of urine through an incompetent urethra in the absence of a detrusor contraction.¹ The purest symptom of USI is urinary loss upon raising intra-abdominal pressure, as in coughing. Ten percent of middle-aged women report weekly incontinence,² although only 1 in 1000 women undergo curative surgery. USI may be complicated by intrinsic sphincter deficiency (ISD), detrusor overactivity or voiding disorder, or pelvic organ prolapse. USI is amenable to physical therapy and to surgery. Drug therapy to remedy a structural defect has been understandably disappointing. Bulking agents have a role in treating women with ISD, those who have

undergone repeat surgery, or those medically unfit for surgery.

Sling Therapy for USI

Sling therapy is the enhanced surgical support of the urethra, routinely performed by vaginal or abdominal (open or laparoscopic) routes, or, most recently, by access to the obturator foramen.

Kelly's 1913 anterior vaginal repair is probably the oldest described pro-

cedure for incontinence. The Marshall-Marchetti-Krantz urethropexy (1949) sought to elevate the proximal urethra directly in the same way that the Burch colposuspension (1961) did indirectly by using the vagina as a hammock.

Sling therapy is the enhanced surgical support of the urethra, routinely performed by vaginal or abdominal routes, or, most recently, by access to the obturator foramen.

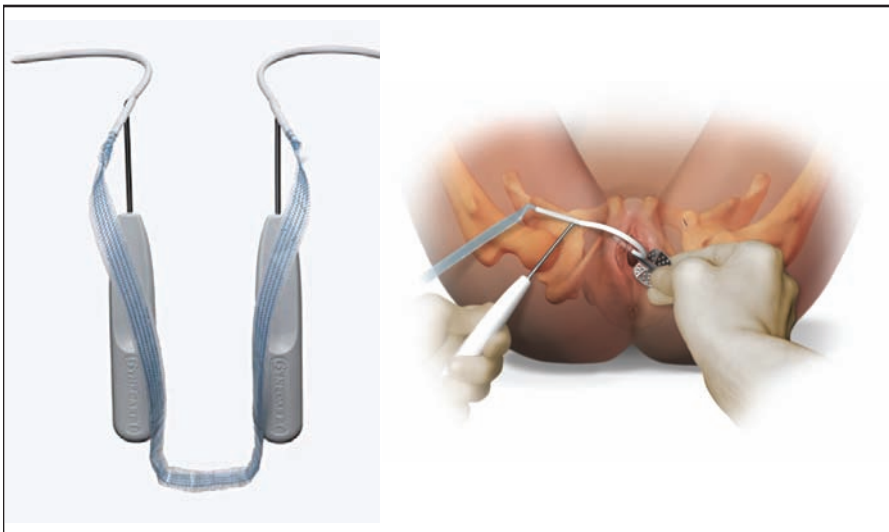
cedure for incontinence. The Marshall-Marchetti-Krantz urethropexy (1949) sought to elevate the proximal urethra directly in the same way that the Burch colposuspension (1961) did indirectly by using the vagina as a hammock.

Autologous fascial sling procedures³ were widely used in the late 20th century, and usually sought to elevate the bladder neck. These were successful procedures, but carried harvesting morbidity. Synthetic mate-

rial slings carried unacceptable erosion rates. Peyrera, Raz, and Stamey retropubic needle/suture bladder neck suspensions had low morbidity, but the long-term outcomes were poor.

Gynecare TVT® (Ethicon Women's Health & Urology, Somerville, NJ) was the first implantable dedicated mesh sling device for the treatment of female USI. It was composed of a polypropylene mesh tape that passed retropubically within polythene sleeves and was placed without tension under the midurethra (Figure 1).

Figure 1. Tension-Free Vaginal Type Obturator (Ethicon Women's Health & Urology, Somerville, NJ). Photo courtesy of Ethicon Women's Health & Urology. ©ETHICON, Inc. Reproduced with permission.

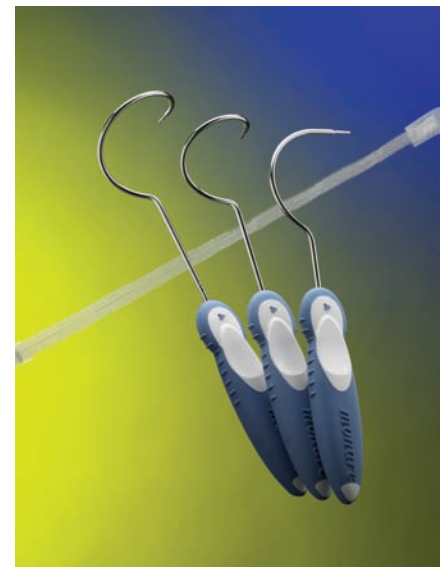


which could be passed through suprapubic incisions downward.

For a pure primary incontinent population, the cure/improvement rates were established at least at 84%⁵ for this type of tape procedure. Nevertheless, it was substantial surgery that carried a 7% bladder perforation rate⁶ and therefore demanded cystoscopy. Simple local analgesia was insufficient and an office procedure was not possible. For the high procedure efficacy, there appeared to be a trade-off of significantly revealed irritative symptoms, with overactive bladder and voiding disorder occurring in 8%.⁷

The next generation of slings placed a similar device under the urethra, but now exited much more laterally through the medial obturator foramen⁷ in the top of the leg. Out-in (Monarc™ Subfascial Hammock, American Medical Systems; Figure 2) and in-out (Tension-Free Vaginal Type Obturator [TVT-O], Ethicon Women's Health & Urology) versions of this procedure emerged. A near-zero bladder perforation rate obviated the

Figure 2. Monarc™ Subfascial Hammock. Photo courtesy of American Medical Systems®, Inc., Minnetonka, MN. www.AmericanMedicalSystems.com.



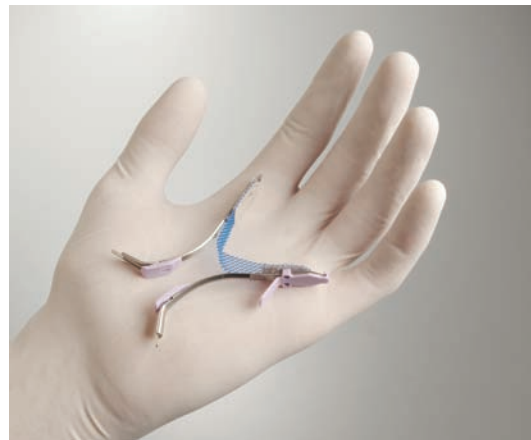need for check cystoscopy. A slight decrement in effectiveness compared with retropubic methods is believed by many, but this is countered by a lower rate of de novo overactivity and voiding disorder.

A new mechanism of curative action was suggested. A gentler subfascial hammock was created by transobturator tapes, rather than the creation of a pubourethral neoligament and restoration of intra-abdominal pressure transmission that was the hallmark of a retropubic sling.

Barber and colleagues⁸ recently suggested that transobturator tapes are “not inferior” to retropubic tapes at 18 months follow-up. Undoubtedly, subfascial or obturator techniques are now more commonly performed in the United States.

Full-length slings are effective, but require invasive surgeries with 3 incisions, extensive blind needle passages with attendant risk of vascular

Figure 3. Gynecare TVT SECUR[®] (Ethicon Women's Health & Urology, Somerville, NJ). Photo courtesy of Ethicon Women's Health & Urology. ©ETHICON, Inc. Reproduced with permission.



end. They require local analgesia and a single vaginal incision. They are inserted with a short needle introducer.

It is possible to deploy a minisling into the retropubic space (Gynecare TVT SECUR[®], Ethicon Women's Health & Urology) or by the hammock or subfascial route (Gynecare TVT SECUR, Ethicon Women's Health & Urology [Figure 3]; MiniArc[™] Single-

The routine use of minislings has therefore been questioned. MiniArc (American Medical Systems) is an easily deployed device, but there are no substantial long-term outcomes data available.

Minislings open up a tissue tunnel at placement, and fixation into good tissue can neither be guaranteed nor tested at time of surgery. It is therefore postulated that failure occurs very early. Conversely, if early anchor stabilization can be ensured, then this early failure would be overcome.

Full-length slings are effective, but require invasive surgeries with 3 incisions, extensive blind needle passages with attendant risk of vascular and visceral damage, major anesthesia, and inpatient surgery.

and visceral damage,⁹ major anesthesia, and inpatient surgery. Also, the overall rate of full-length sling-related complications is reported as 8.2%.¹⁰

Furthermore, there is a specific groin and lower limb neuropathy associated with full-length transobturator techniques. This may be as high as 15% to 24% initially, and a long-term rate of 4.75% has been described. It is suggested that this neuropathy occurs less with an out-in technique than with an in-out technique because needle passage is always more precise at entry than at exit.¹¹⁻¹⁵

Minislings

Minislings are short tape mesh slings (8-14 cm) with paired anchors at each

Incision Sling system, American Medical Systems [Figure 4]). In both cases, a push-fit technique is used and the fixation ends of the tape are often placed in indeterminate soft tissue.

The first minisling clinical series was undertaken by Smith and colleagues starting in 2002; 2-year follow-up data¹⁶ were presented at the 2008 International Urogynecological Association meeting. The data showed excellent tolerance of local analgesia, early return to normal, and low morbidity. This profile potentially allows for an in-office procedure.

Effectiveness of (unstabilized) minislings, however, shows a very significant decrement over full-length slings, with early efficacy of the TVT SECUR reported as low as 60%.¹⁷

Figure 4. MiniArc[™] Single-Incision Sling. Photo courtesy of American Medical Systems[®], Inc., Minnetonka, MN. www.AmericanMedicalSystems.com



A Stabilized and Adjustable Minisling

Minitape® (Mpathy Medical, Raynham, MA) is the first stabilized minisling (ie, a short mesh sling with stay sutures). A short, ultra-lightweight polypropylene mesh tape (12 cm if retropubic, 8 cm if subfascial) is implanted suburethrally through a vaginal incision. Absorbable 2/0 stay sutures are brought externally to paired suprapubic or medial obturator foramen skin exits using a fine carrying needle. The sutures are fixed for 3 to 10 postoperative days before being released and cut if adjustment is not required.

The underlying hypothesis for a stabilized minisling is that it can produce the effectiveness of a full-length sling with the benefits of a minisling. It is proposed that minisling failure is a consequence of early sling slippage because the fixation means or anchors are embedded in indeterminate

retropubically with a fine needle carrying the sutures from below upwards, or fetching from above. The 8-cm minisling similarly can be placed subfascially with either out-in or in-out needle passage.

Although a standard needle course is followed, the needle introducer used is narrow and passage requires little force. A 2/0 suture rather than an 11-mm mesh is passed laterally/high, which is less traumatic. This has a particular advantage if the bladder is perforated, as the bladder trauma from a suture passage is clearly less than that of a piece of mesh. A fine needle/suture exit does not require a formal skin incision but a needle puncture.

The minimization of foreign body load is desirable and in this minisling procedure is achieved by both a light and a short mesh. Long-term mesh complications such as translocation and erosions should be minimized

An initial observational series of 76 women undergoing the Minitape procedure demonstrated that 74 of 76 (97%) women were symptomatically dry at a mean of 21 weeks.¹⁸ Although this is a benchmark level expected from a full-length tape in a pure primary incontinent population, these data must be cautiously interpreted as the results are early and long-term follow-up is required.

Duckett and Tamilselvi¹⁹ followed a series of women whose procedures failed and who had prior urodynamically diagnosed detrusor overactivity and ISD, a group in whom adjustment is difficult and the failure rate is higher than for pure USI.

No urinary-specific contraindications were given for Minitape, a procedure indicated for all cases of USI and particularly more complex cases, such as ISD, and previous surgery as well as coexistent detrusor overactivity, mild voiding disorder, and concomitant prolapse. Of the 76 patients in the initial observational series, 22 patients had ISD.

The underlying hypothesis for a stabilized minisling is that it can produce the effectiveness of a full-length sling with the benefits of a minisling.

or poor tissue. By removing that possibility via stay suture stabilization for the critical 72 hours while early mesh invasion and fixation occur, position is maintained and good clinical outcomes ensue.

The Minitape implant has specific advantageous construction features (Figure 5). It is the lightest available polypropylene mesh at 19 g/m². No suburethral erosions are yet reported for this minisling, and large-area prolapse repairs using an ultra-lightweight mesh (Smartmesh™) at 19 g/m² have a near-zero erosion rate (data on file, Mpathy Medical). The closed knit construction keeps the Minitape sling both flat and inelastic under the urethra and avoids sharp edges or detaching polypropylene fragments. The 12-cm minisling can be placed

by this approach, which offers stabilization.

The particular problem of obturator neurologic sequelae should be avoided if there is no persistent material at or near the obturator foramen, as is the case for 8-cm minisling, in contradistinction to full-length obturator slings.

Finally, the presence of external sutures allows for early sling adjustability. This is feasible, but the consequence of adjustment was not studied and needs to be the subject of further investigation.

Conclusion

Tape slings have become the surgical treatment of choice for female USI. Despite generally good clinical outcomes and low complication rates, nagging inadequacies remain with available technologies. In particular, to correctly tension a tape sling is notoriously difficult. Women with ISD, mixed incontinence, voiding disorder, and previous surgery are clearly high risk and readjustment capability may be desirable for this group. It is further suggested that obese patients may constitute a

Figure 5. Minitape® (Mpathy Medical, Raynham, MA) 12-cm minisling. Photo courtesy of Mpathy Medical.



group in whom intraoperative adjustment may be difficult and therefore postoperative adjustment is beneficial.

On a broader scale, however, even women with pure primary incontinence may benefit from late readjustment capabilities. Of 100 pure primary incontinent women undergoing a full-length sling procedure,¹ only about 60 will be symptomatically cured without any residual leakage or voiding difficulties. By definition, about 40 will not. Of these women, some will be improved, some unchanged, and some left with a degree of voiding difficulty, especially in the short term. A new occult risk group is therefore defined that eludes preoperative identification. Adjustment capability is suggested as desirable for up to 40% of patients.

The first procedure is usually the most successful. Despite the good results of repeat TVT described by Rardin and associates,²⁰ the confounding factors in repeat surgeries are increased, so the importance of optimal first surgery is stressed. Whether the adjustable, stabilized minisling provides the solution to the inadequacies of current sling technologies remains to be determined by appropriately powered, randomized trials. Nonetheless, the theoretical advantages of the adjustable, stabilized minisling are compelling, and early

data suggest good results that warrant further investigation. ■

Dr. Alinsod is a consultant for Mpathy Medical.

References

1. Abrams P, Cardozo L, Fall M, et al; Standardisation Sub-committee of the International Continence Society. The standardisation of terminology of lower urinary tract dysfunction: report from the Standardization Sub-committee of the International Continence Society. *Neurourol Urodyn*. 2002;21:167-178.
2. Nygaard IE, Heit M. Stress urinary incontinence. *Obstet Gynecol*. 2004;104:607-620.
3. Aldridge AH. Transplantation of fascia for relief of urinary stress incontinence. *Am J Obstet Gynecol*. 1942;44:398-411.
4. Ward K, Hilton P; United Kingdom and Ireland Tension-free Vaginal Tape Trial Group. Prospective multicentre randomised trial of tension-free vaginal tape and colposuspension as a primary treatment for stress incontinence. *BMJ*. 2002;325:67.
5. Nilsson CG. The tensionfree vaginal tape procedure (TVT) for treatment of female urinary incontinence. A minimal invasive surgical procedure. *Acta Obstet Gynecol Scand Suppl*. 1998;168:34-37.
6. Monga A, Duval B, Espuna M, et al. The SPARC procedure for urodynamic stress incontinence: a multicentre prospective study with 1 year follow up [abstract 405]. Presented at: International Continence Society 33rd Annual Meeting; October 5-9, 2003; Florence, Italy.
7. Delorme E, Droupy S, de Teyrac R, Delmas V. Transobturator tape (Uratape): a new minimally-invasive procedure to treat female urinary incontinence. *Eur Urol*. 2004;45:203-207.
8. Barber MD, Kleeman S, Karram MM, et al. Trans-obturator tape compared with tension-free vaginal tape for the treatment of stress urinary incontinence: a randomized controlled trial. *Obstet Gynecol*. 2008;111:611-621.
9. Ward K, Hilton P. Minimally invasive synthetic suburethral slings: emerging complications. *Obstet Gynaecol (Lond)*. 2005;7:223-232.
10. Stanford EJ, Paraiso MF. A comprehensive review of suburethral sling complications. *J Minim Invasive Gynecol*. 2008;15:132-145.
11. Davila GW, Johnson JD, Serels S. Multicenter experience with the Monarc transobturator sling system to treat urinary stress incontinence. *Int Urogynecol J Pelvic Floor Dysfunct*. 2006;17:460-465.
12. Moore RD, Miklos JR, Cervigni M, et al. Transobturator sling: combined analysis of 1 year follow-up in 9 countries with 266 patients. *Int Urogynecol J Pelvic Floor Dysfunct*. 2006;17:S203.
13. Collinet PC, Ciofu CC, Cosson MC, Jacquetin BJ. Safety of in-out transobturator approach for SUI: multicentre prospective study of 944 patients, French TVT-O Registry. *Int Pelvic Floor Dysfunct*. 2006;17:S103.
14. Lim JL, Cornish A, Carey MP. Clinical and quality-of-life outcomes in women treated by the TVT-O procedure. *BJOG*. 2006;113:1315-1320.
15. Roth TM. Management of persistent groin pain after transobturator slings. *Int Urogynecol J*. 2007;18:1371-1373.
16. Smith ARB, Hilton P, et al. 2 year follow up of prospective cohort study of single incision, short segment, transvaginal tape inserted under local anaesthesia [oral poster 9]. Presented at: 33rd Annual International Urogynecological Association Meeting; September 13-17, 2008; Taipei, Taiwan.
17. Bacarat F, et al. Unfavorable immediate outcome of the TVT Secur sling in twenty consecutive women with stress urinary incontinence. Presented at: Annual Meeting of the American Urological Association; May 17-22, 2008; Orlando, FL.
18. Alinsod R, Safir M, Browning J. Initial outcomes of a stabilized adjustable minisling for female urinary stress incontinence. Abstract submitted to the 2009 International Continence Society meeting; San Francisco, CA.
19. Duckett JRA, Tamilselvi A. Effect of tension-free vaginal tape in women with a urodynamic diagnosis of idiopathic detrusor overactivity and stress incontinence. *BJOG*. 2006;113:30-33.
20. Rardin CR, Kohli N, Rosenblatt PL, et al. Tension-free vaginal tape: outcomes among women with primary versus recurrent stress incontinence. *Obstet Gynecol*. 2002;100:893-897.

Main Points

- The tension-free vaginal tape full-length retropubic sling set a benchmark of proven effectiveness in a randomized, controlled trial against Burch colposuspension.
- Transobturator tapes cause less bladder perforation, but groin and leg pain are problematic.
- Minislings are office capable and have a low complication profile, but limited longer-term evidence suggests markedly decreased effectiveness compared with full-length slings.
- A stabilized adjustable minisling appears to have the benchmark effectiveness of a full-length sling.
- Longer term follow-up and controlled trials are planned to further assess the stabilized adjustable minisling to determine whether postoperative adjustment can give sustained superior results.