

Colon adenocarcinoma metastasis to soft tissue of the wrist with heterotopic bone formation: a case study

Elizabeth Killiam^a, Robert Cicchino^b, Troy Foster^b and Jeffrey Stead^c

^aWest Virginia University, Eastern Division, Martinsburg, WV 25401, USA; ^bDepartment of Surgery, Eastern Division of the West Virginia University Hospital-East Program, Robert C. Byrd Health Sciences Center, 2500 Foundation Way, Martinsburg, WV 25401, USA; ^cDepartment of Pathology, West Virginia University Hospital-East, Berkeley Medical Center, 2500 Hospital Drive, Martinsburg, WV 25401, USA

Corresponding address: Elizabeth Killiam, West Virginia University, Eastern Division, Martinsburg, WV 25401, USA.

Email: ekilliam@osteo.wvsom.edu

Date accepted for publication 16 June 2014

Abstract

It is uncommon in clinical practice to discover cancer as either a metastasis within soft tissue or containing heterotopic bone formation. These rarities are documented primarily through case reports in the literature. This report describes a patient with colon cancer whose painful wrist lesion was proven to exhibit both of these unusual features. It is important to recognize soft tissue metastases, as these are managed differently than a carcinosarcoma, for instance. In addition, although heterotopic bone formation does not alter the prognosis or management of colon cancer, it can prove a valuable starting point for understanding carcinogenesis.

Keywords

Colon adenocarcinoma; metastasis; heterotopic bone formation; osseous metaplasia; soft tissue metastasis.

Introduction

Cancer rarely metastasizes to the soft tissue. In one robust prospective study of soft tissue masses, only 3% were metastatic lesions^[1]. Heterotopic bone formation is also an unusual finding. This case report presents a patient with a soft tissue lesion in the wrist, which was diagnosed as metastasis originating from a colon adenocarcinoma, with heterotopic bone formation. These unusual findings have been addressed in case reports and there is now more knowledge about which tumors are more likely to spread to soft tissue, and which mechanisms may underlie atypical heterotopic bone formation in some cancers^[2].

Case report

A 60-year-old, white, nonsmoking male with a medical history remarkable only for hypertension presented with rectal bleeding in 2006. Anterior resection and lymph node removal were performed and analysis on pathology demonstrated poorly differentiated adenocarcinoma of the sigmoid colon. An initial treatment with 12 cycles of FOLFOX6 for 6 months was completed. He did not follow up with oncology after treatment. Five years after chemotherapy, he had increased carcinoembryonic antigen (CEA) at 6.3 ng/ml. At this time, he was found to have metastatic lesions in his left adrenal gland, right hepatic lobe and lung (Fig. 1). Despite a 5-month course of irinotecan and erbitux, his CEA levels continued to increase, and the patient elected to discontinue chemotherapy.

A few months later, after 1 year of discomfort, the patient sought evaluation for a tender swollen lump in his right lateral wrist aggravated by supination and pronation. Examination revealed a freely moveable 3 × 4 cm mass thought to be a giant cell tendon, sarcoma, or metastatic mass by magnetic resonance imaging (MRI). An excisional biopsy with regional anesthesia was performed, during which a non-encapsulated 5 × 7 cm mass resembling an inclusion cyst was resected. Pathological analysis revealed metastasis consistent with a primary colon adenocarcinoma, as well as heterotopic bone formation (Figs. 2–4).

Discussion

Although skeletal muscle is highly vascular and comprises up to 50% of the body's mass, only a handful of case reports describe soft tissue metastases^[3,4]. Possible explanations for the rarity of cancer in these sites include turbulent blood flow hostile to tumor cells, high concentrations of

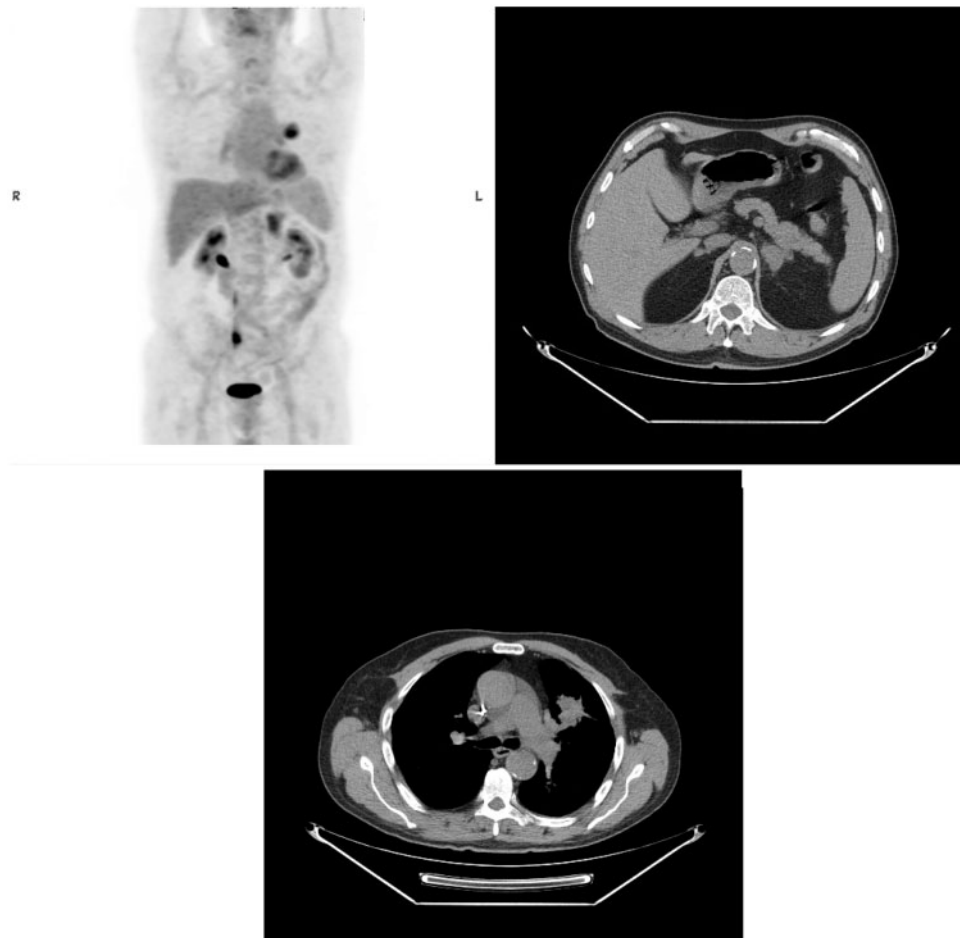


Fig. 1. Positron emission tomography/computed tomography scan demonstrates a hypermetabolic mass in the left upper lobe (2.5 × 4.2 cm), increased from 3.6 × 3.9 cm 4 months previously. A hypermetabolic mass measuring 2.7 × 4.2 cm is also visible on the left adrenal gland.

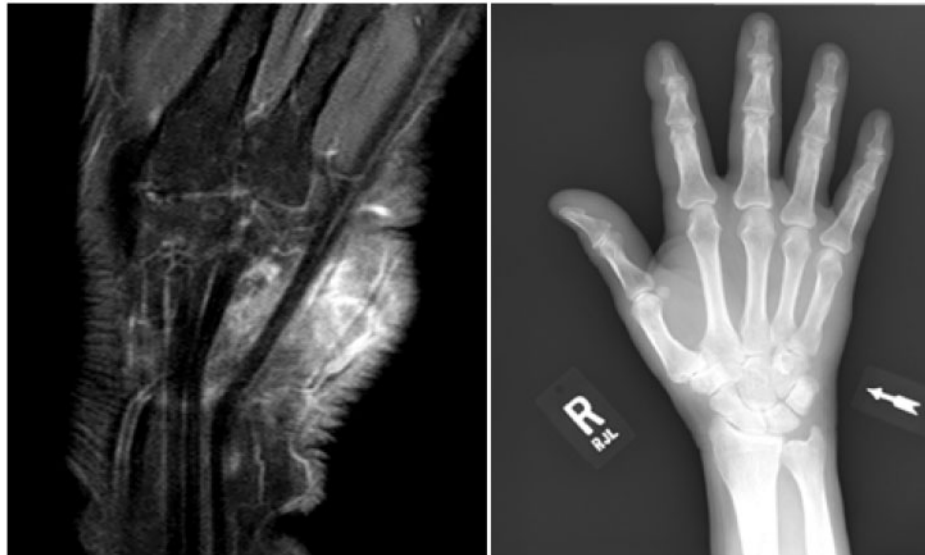

Fig. 2. Magnetic resonance imaging without contrast showing a mass on the right wrist measuring $4.2 \times 2.4 \times 3.8$ and located medial to the carpal tunnel and deep to the flexor carpi ulnaris tendon along the course of the abductor digiti minimi tendon.

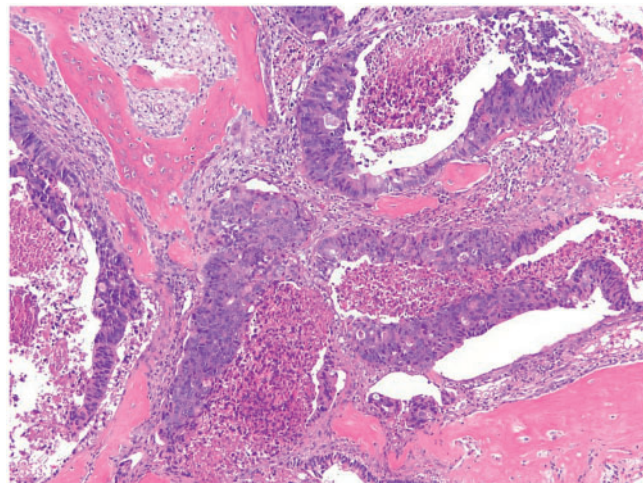


Fig. 3. Large neoplastic glands, some containing granular necrotic material. This dirty necrosis is often seen in metastatic colonic adenocarcinoma. Note heterotopic bone formation in stromal tissue.

lactic acid preventing growth of the tumor cells, and proteases deterring the invasion and growth of cells at these sites^[5]. It is also thought that low molecular weight factors produced by muscle inhibit proliferation of tumor cells^[6].

Due to nonspecific findings, soft tissue metastases are particularly challenging to diagnose. Patients may be asymptomatic or may complain of discomfort, inflammation, and or erythema mimicking soft tissue sarcomas^[3,7-10]. Furthermore, imaging with MRI has been shown to detect skeletal muscle metastatic lesions that are sometimes missed with computed tomography, but does not always enable clinicians to distinguish a soft tissue tumor from inflammation^[4,11-13]. Positron emission tomography imaging has been successful in detecting occult cancers and metastases, and is a recommended resource in these cases^[14,15].

Heterotopic bone formation is an even less expected finding in cancer. Although this phenomenon is not currently associated with a change in patient management or prognosis, it is of academic interest. Recent findings in the literature suggest that fibroblasts, alkaline phosphatase, and extravasation of mucin can lead to ossification^[2,16]. Various factors are thought to induce osteoblast-like cells and osteoclast-like cells, which cause bone-like tissue to form^[17].

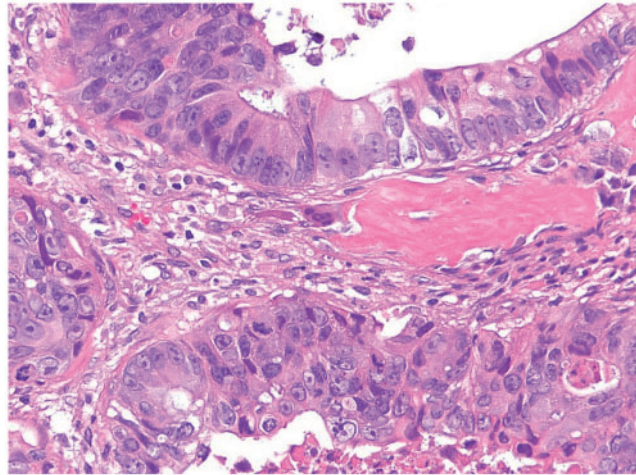


Fig. 4. Columnar cells with pleomorphic darkly staining nuclei and scattered mitotic figures.

Specific bone morphogenic proteins have been found to play a role in this process, and one of these is stimulated by Gli2^[14,18–20].

Teaching points

- It is important to keep in mind the differential diagnoses of a soft tissue mass, because early diagnosis of a metastatic lesion could improve patient outcomes. Furthermore, heterotopic bone formation is worth noting in future cases, as exploration of this uncommon phenomenon is leading to improved understanding of the mechanism of carcinogenesis.

References

1. Glockner JF, White LM, Sundaram M, White LM, Sundaram M, McDonald DJ. Unsuspected metastases presenting as solitary soft tissue lesions: a fourteen-year review. *Skeletal Radiol* 2000; 29: 270–274. PMID:10883446.
2. Kypson AP, Morphew E, Jones R, Gottfried MR, Seigler HF. Heterotopic ossification in rectal cancer: rare finding with a novel proposed mechanism. *J Surg Oncol* 2003; 82: 132–136. PMID:12561070.
3. Surov A, Hainz M, Holzhausen HJ, *et al.* Skeletal muscle metastases: primary tumours, prevalence, and radiological features. *Eur Radiol* 2010; 20: 649–658. doi:10.1007/s00330-009-1577-1. PMID:19707767.
4. Hasegawa S, Sakurai Y, Imazu H, *et al.* Metastasis to the forearm skeletal muscle from an adenocarcinoma of the colon: report of a case. *Surg Today* 2000; 30: 1118–1123. PMID:11193747.
5. Çetin B, Büyükberber S, Yüksel M, Coşkun U, Yıldız R, Benekli M. Metastasis of rectal cancer to soft tissue of the hand: an unusual case. *Turk J Gastroenterol* 2011; 22: 229–230.
6. Djaldetti M, Sredni B, Zigelman R, Verber M, Fishman P. Muscle cells produce a low molecular weight factor with anti-cancer activity. *Clin Exp Metastasis* 1996; 14: 189–196. PMID:8674272.
7. Damron TA, Heiner J. Distant soft tissue metastases: a series of 30 new patients and 91 cases from the literature. *Ann Surg Oncol* 2000; 7: 526–534. PMID:10947022.
8. Ozcanli H, Ozdemir H, Ozenci M, Soyuncu Y, Aydin AT. Metastatic tumors of the hand in three cases. *Acta Orthop Traumatol Turc* 2005; 39: 445–448. PMID:16531705.
9. Wu KK, Guise ER. Metastatic tumors of the hand: a report of six cases. *J Hand Surg Am* 1978; 3: 271–276. PMID:275346.
10. Araki K, Kobayashi M, Ogata T, Takuma K. Colorectal carcinoma metastatic to skeletal muscle. *Hepatogastroenterology* 1994; 41: 405–408. PMID:7851845.
11. Demas B, Heelan R, Lane J, Marcove R, Hajdu S, Brennan M. Soft-tissue sarcomas of the extremities: comparison of MR and CT in determining the extent of disease. *Am J Roentgenol* 1988; 150: 615–620.

12. Chang A, Matory Y, Dwyer A, *et al.* Magnetic resonance imaging versus computed tomography in the evaluation of soft tissue tumors of the extremities. *Ann Surg* 1987; 205: 340-348. PMID:3032120.
13. Moulton JS, Blebea JS, Dunco DM, Braley SE, Bisset GS, Emery KH. MR imaging of soft-tissue masses: diagnostic efficacy and value of distinguishing between benign and malignant lesions. *AJR Am J Roentgenol* 1995; 164: 1191-1199. PMID:7717231.
14. Huang RSP, Brown RE, Buryanek J. Heterotopic ossification in metastatic colorectal carcinoma: case report with morphoproteomic insights into the histogenesis. *Ann Clin Lab Sci* 2014; 44: 99-103. PMID:24695482.
15. Jiang L, Gao Y, Sheng S, Xu M, Liyan L, Lu H. A first described chest wall metastasis from colon cancer demonstrated with (18)F-FDG PET/CT. *Hellenic J Nucl Med* 2011; 14: 316-317.
16. Rhone DP, Horowitz RN. Heterotopic ossification in the pulmonary metastases of gastric adenocarcinoma: report of a case and review of the literature. *Cancer* 1976; 38: 1773-1780. PMID:825218.
17. Yasmin M, Shubhangi V, Sameer A, Bharat G. Osseous metaplasia in rectal and appendicular carcinoma: a diagnostic dilemma?. *Oncol Gastroenterol Hepatol Rep* 2013; 2: 13-14.
18. Agnihotri S, Sarma NH, Jeebun N, Srivastava R. Osseous metaplasia in adenocarcinoma of the rectum: a case report. *Internet J Gastroenterol* 2008; 7: 1. doi:10.5580/479.
19. Alpler M, Akyürek N, Patiroglu TE, Yüksel O, Belenli O. Heterotopic bone formation in two cases of colon carcinoma. *Scand J Gastroenterol* 2000; 35: 556-558.
20. Yang RH, Chu YK, Li WY. Unusual site of metastasis detected with FDG PET/CT in a case of recurrent rectosigmoid cancer. *Clin Nucl Med* 2014; 39: 355-357. doi:10.1097/RLU.0000000000000293. PMID:24300344.