

# Unusual presentation of a primary recurrent hydatid cyst

Halil Koray Sezer<sup>a</sup>, Muharrem Oztas<sup>b</sup>, Ismail Hakki Ozerhan<sup>b</sup>, Ramazan Yildiz<sup>b</sup> and Mehmet Fatih Can<sup>b</sup>

<sup>a</sup>Balikesir Military Hospital, Balikesir, Turkey; <sup>b</sup>Gulhane School of Medicine, Ankara, Turkey

Corresponding address: Halil Koray Sezer, Balikesir Military Hospital, General Surgery Department, Balikesir, Turkey.

Email: ksezer2002@yahoo.com

Date accepted for publication 2 March 2013

## Abstract

We present a case of primary recurrent hydatid cyst of the tibialis posterior in a 55-year-old woman with complaints of leg pain. Hydatid cyst was diagnosed by ultrasonography and serological tests. The patient underwent surgical excision of the lesion with perioperative prophylaxis with albendazole.

## Keywords

Hydatid cyst; tibialis posterior; radiology; surgical excision.

## Introduction

Hydatid cyst disease is a parasitic infection caused by the cestode *Echinococcus*. Even though it is common worldwide, it is especially endemic in the Middle East, central Europe, Australia and South America where intermediate hosts such as sheep and cattle are more common. The liver (50–75%) and lung (10–30%) are the primary organs involved. Involvement of the heart, kidney, spleen, brain, thyroid and other organs such as muscles is quite rare (10–20%). It is less commonly involved in the musculoskeletal system with only 1–4% of all cases. Voluntary muscles are a very rare site of infection, counting for less than 1% of the total<sup>[1]</sup>. It has been hypothesized that the presence of lactic acid does not permit the larvae to grow into cysts in the muscles<sup>[2]</sup>. However, in the literature, hydatid cyst localized at various sites have been reported, i.e. between the internal and external oblique muscles, psoas, sternocleidomastoid, biceps brachii, intercostal, pectoralis major muscles and the diaphragm, tongue, and leg muscles<sup>[3–6]</sup>. In the filtration system of the liver and in lung muscle, cyst growth is hampered by muscle contraction and lactic acid<sup>[7–9]</sup>. Primary skeletal muscle hydatidiosis without lung and liver involvement is extremely rare.

## Case report

In 1999, a 55-year-old woman with complaints of leg pain was admitted to another hospital. She was a farmer and was rearing sheep and cows. On physical examination, a soft, slightly tender, fixed, mass measuring 3 cm × 5 cm was detected on her left leg. There were no complaints of any other symptoms or other clinical findings. Routine laboratory tests were normal and the indirect

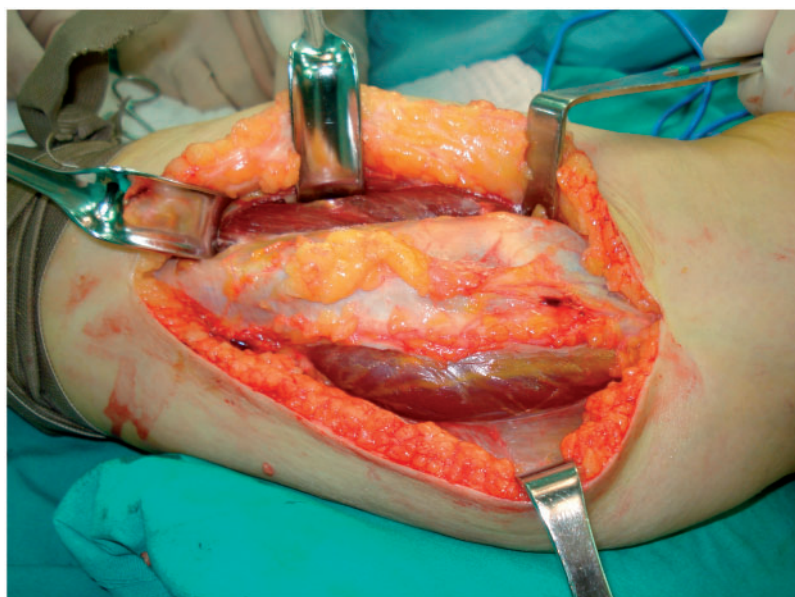


Fig. 1. Intraoperative cystic mass.

haemagglutination test was found to be positive. Plain radiographs showed only soft tissue swelling in the medial region. A cyst-like ovular mass was detected with ultrasonography. Hydatid cyst disease was diagnosed with serological tests and anamnesis. The patient underwent excision of the cyst while receiving chemoprophylaxis with albendazole 400 mg twice a day. Ten days after the operation, the perioperative prophylaxis was stopped.

In 2002, due to recurrence of disease, the patient underwent re-operated and repeated the chemoprophylaxis of albendazole for 13 weeks.

In 2008, the patient's complaints recurred again. On the laboratory examinations, the more specific serological test, specific IgG for hydatid diseases, was positive. The following characteristics were detected with soft tissue ultrasonography in the left cruris: anterolaterally into 2 components, 8 cm long and 8 mm thick, anterior, lateral and inferior daki 3 cm long and 7 mm wide, heterogeneous, hypoechoic, solid character, type 4 lesions compatible with a hydatid cyst. Hepatic and thorax involvement were not observed on abdominal ultrasonography or abdominal and thorax computed tomography (CT). In March 2009, due to recurrence of symptoms, the patient agreed to surgery. She underwent complete excision of the diseased area with surrounding healthy tissue (Figs. 1-3) and was placed on albendazole treatment for 13 weeks.

The patient underwent follow-up visits for 2 years without any further complaints or relapse or post-surgery complications.

## Discussion

Intramuscular lesions with the absence of liver, lung or bone manifestations sometimes pose diagnostic dilemmas. Hydatid cyst can occur in the form of multiple cystic masses in the muscle. However, solid-looking soft tissue cysts may be misinterpreted for hydatid cyst if there is debris or infection within. Hydatid cyst may mimic soft tissue tumours, haematoma, abscess, aneurysm; patients should be evaluated using the medical history, clinical symptoms and radiological findings<sup>[4-6,11,12]</sup>.

Especially in endemic areas, radiological imaging should be performed before invasive procedures such as biopsy. Ultrasonography is the most commonly used imaging method throughout the world. It is easy and inexpensive and staging can also be performed. A simple cyst is surrounded by a cyst membrane with buddings. Protoscolices and daughter cysts are produced by the inner layer and they fill the inside of the cyst. In the presence of daughter vesicles, the rosette sign can be discernible. The amorphous substances that lead to an erroneous diagnosis can be located inside the cysts. The presence of calcification in the wall of cyst is a diagnostic factor for hydatid cyst<sup>[10]</sup>. Ultrasonographic findings are similar to CT and magnetic resonance imaging (MRI). Abdominal MRI may be useful to evaluate the pericyst, cyst matrix, and daughter

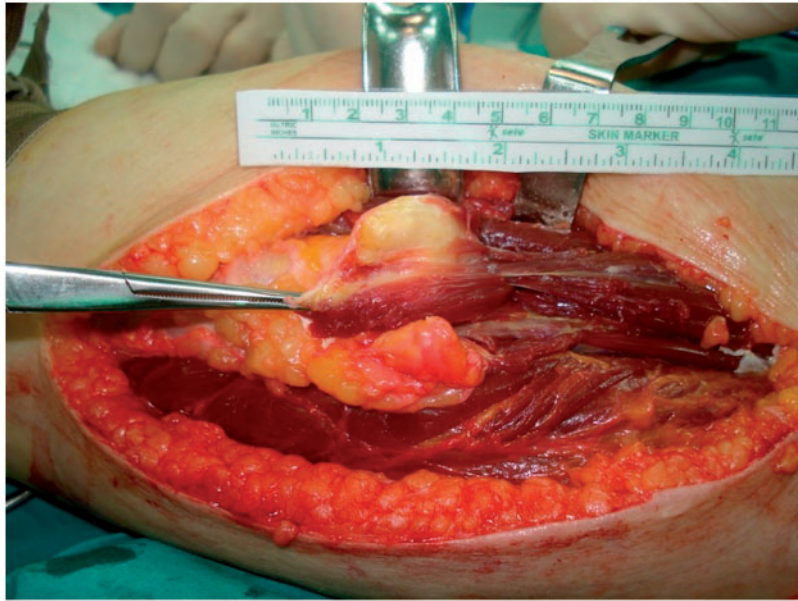


Fig. 2. Intraoperative cystic mass.

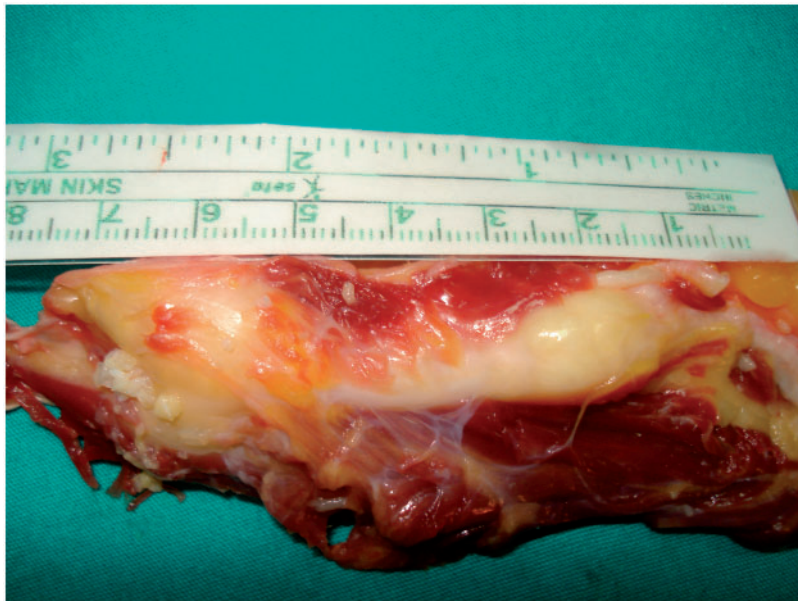


Fig. 3. Cystic mass after complete excision.

cyst characteristics<sup>[13]</sup>. However, typical ultrasonographic findings of musculoskeletal hydatid disease do not exist. Calcifications are not always revealed. Absence of calcification should not be preclude hydatid cyst disease, especially in endemic areas.

According to the information in the literature, detection of calcification varies. Booz et al.<sup>[14]</sup> showed 38% calcification using plain radiography, but 2 of them proved to be calcification. In another study, calcification was found in only 1 of 8 patients<sup>[15]</sup>. In our case, typical appearance of hydatid cyst (multiloculated cysts with internal echoes and septations between the muscles) was present and these findings were confirmed by serological tests.

Surgery is the primary treatment of hydatid cyst disease. For most cysts, surgical resection involving laparoscopic or open complete cyst removal with instillation of a scolicidal agent is

preferred and is usually curative. In general, all cysts are treated surgically, but conservative treatment can be applied in elderly patients with small, asymptomatic, and intensive calcified cysts. The postsurgical recurrent rate is from 1% to 20%, but it is  $\leq 5\%$  in experienced centres<sup>[16]</sup>. The success rate with medical therapy alone is 50%<sup>[13]</sup>. The cysts do not completely disappear, but preoperative medical treatment can shrink them before surgery and prevent the spread of daughter vesicles<sup>[16]</sup>.

Medical therapy alone without surgical drainage is recommended in patients at risk for surgical resection or with disseminated disease<sup>[13]</sup>. The study of Alvarez et al.<sup>[15]</sup> included 13 patients with muscular hydatid cyst; surgery was done in 9 patients but could not be done in 4 patients due to localization. Patients who have undergone medical treatment only did not achieve cure. In our case, recurrence was seen in conjunction with surgical and medical treatment.

We believe that in patients with a cystic mass, regardless of localization, especially in countries where hydatid cyst is endemic such as in our country, hydatid cyst should be considered in the differential diagnosis. Ultrasonography and CT are the preferred methods for imaging diagnosis; MRI should be done if necessary. When relapse occurs in patients who have undergone medical treatment alone, surgical excision should be performed with medical treatment.

## References

1. Merkle EM, Schulte M, Vogel J, *et al.* Musculoskeletal involvement in cystic echinococcosis: report of eight cases and review of the literature. *AJR Am J Roentgenol* 1997; 168: 1531-1534. doi:10.2214/ajr.168.6.9168719. PMID:9168719.
2. Duncan GJ, Tooke SM. Echinococcus infestation of the biceps brachii. A case report. *Clin Orthop Relat Res* 1990; 261: 247-250.
3. Yörükoglu Y, Zengin M, Dolgun A, *et al.* Primary hydatid cyst causing arterial insufficiency. *Angiology* 1993; 5: 399-401.
4. Martin J, Marco V, Zidan A, Marco C. Hydatid disease of the soft of the lower limb: findings in three cases. *Skeletal Radiol* 1993; 22: 501-514.
5. Pabuscu Y, Tasar M, Gezen F, Ustunsoz B, Bulakbası N, Poca S. [Spinal korda basi yapan paravertebral hidatik kist]. *GATA Bulteni* 1995; 37: 357-360.
6. Chevalier X, Rhamouni A, Bretogne S, Martigny J, Larget-Piet B. Hydatid cyst of the subcutaneous tissue without other involvement MR imaging features. *AJR Am J Roentgenol* 1994; 163: 645-646. doi:10.2214/ajr.163.3.8079861. PMID:8079861.
7. Beggs I. The radiology of hydatid disease. *AJR Am J Roentgenol* 1995; 145: 639-648. doi:10.2214/ajr.145.3.639. PMID:3895873.
8. Sperry CW, Corr PD. CT evaluation of orbital hydatid disease: a review of 10 cases. *Clin Radiol* 1994; 49: 703-704. doi:10.1016/S0009-9260(05)82664-9. PMID:7955833.
9. Sinner WN, Stridbeck H. Hydatid disease of the spleen. Ultrasonography, CT and MR imaging. *Acta Radiol* 1992; 33: 459-461.
10. Vicidomini S, Cancrini G, Gabrielli S, Naspetti R, Bartoloni A. Muscular cystic hydatidosis: case report. *BMC Infect Dis* 2007; 7: 23. doi:10.1186/1471-2334-7-23. PMID:17397535.
11. Acunaş B, Rozanes I, Acunaş G. Case report: retroperitoneal hydatid cyst presenting as a thigh mass: computed tomographic findings. *Clin Radiol* 1991; 44: 285-286.
12. Ergin G, Odabasi S. [Nadir lokalizasyonlarda kist hidatik olguları]. *Türk Radyoloji Dergisi* 1995; 2: 150-155.
13. D'Angelica M, Fong Y. The liver. In: Courtney M, Townsend CM, Beauchamp RD, Evers BM, Mattox K, editors. *Sabiston textbook of surgery. The biological basis of modern surgical practice*. 18th ed. New York: Elsevier; 2008, p. 1494-1496.
14. Merkle EM, Schulte M, Vogel J, *et al.* Musculoskeletal involvement in cystic echinococcosis: report of eight cases and review of the literature. *AJR Am J Roentgenol* 1997; 168: 1531-1534. doi:10.2214/ajr.168.6.9168719. PMID:9168719.
15. García-Alvarez F, Torcal J, Salinas JC, *et al.* Musculoskeletal hydatid disease: a report of 13 cases. *Acta Orthop Scand* 2002; 73: 227-231.
16. Vasilevska V, Zafirovski G, Kirjas N, *et al.* Imaging diagnosis of musculoskeletal hydatid disease. *Prilozi* 2007; 28: 199-209. PMID:18356790.