

Single-stage subtotal colon resection in Chilaiditi syndrome: report of a case

S.N. Potemin^a and S.E. Gumenyk^b

^aRegional Oncological Centre, Krasnodar, Russia; ^bDepartment of Surgery, State Medical University, Krasnodar, Russia

Corresponding address: Sergey Potemin, MD, PhD, 146 Dimitrov Street, Krasnodar, 350040, Russia.

Email: spotemin@hotmail.com

Date accepted for publication 24 May 2011

Abstract

Chilaiditi syndrome is rare, often challenging to diagnose and difficult to treat. In general, patients have a long history of symptoms from early childhood. Emergency surgery is usually performed in the case of volvulus or obstruction. Detorsion, colopexy or partial colonic resection have been proposed. However, these methods may lead to a recurrence of the disease. In this article we present a patient with Chilaiditi syndrome who had a single-stage subtotal colectomy and anastomosis. A 20-year-old man was referred to hospital in February, 2004. He had a long medical history but no surgical history. Episodes with emergency visits were documented over the previous 3 years. Chilaiditi sign was seen on the upright abdominal radiograph as free air under the right diaphragm caused by the interposition of the transverse colon between the liver and the diaphragm. The patient underwent a subtotal colectomy with an anastomosis between the ascending colon and the rectum. To our knowledge, this is the only reported case of a single-stage subtotal colon resection associated with Chilaiditi syndrome.

Keywords

Chilaiditi syndrome; chronic constipation; subtotal colectomy.

Introduction

Chilaiditi syndrome is rare, often challenging to diagnose and difficult to treat. Patients have a long history of symptoms from early childhood. Surgery is usually performed for emergency reasons, such as volvulus or an obstruction. Detorsion, colopexy or partial colon resection has been proposed. These methods may result in a recurrence of the disease. In this article, we present the case of a patient with Chilaiditi syndrome who had single-stage subtotal colon resection and anastomosis.

Case report

A 20-year-old man was referred to our hospital in February 2004 with signs of marked abdominal distension but there was no peritonitis. The accompanying symptoms were abdominal pain, distension, vomiting, and constipation. He had a long history of such symptoms from early

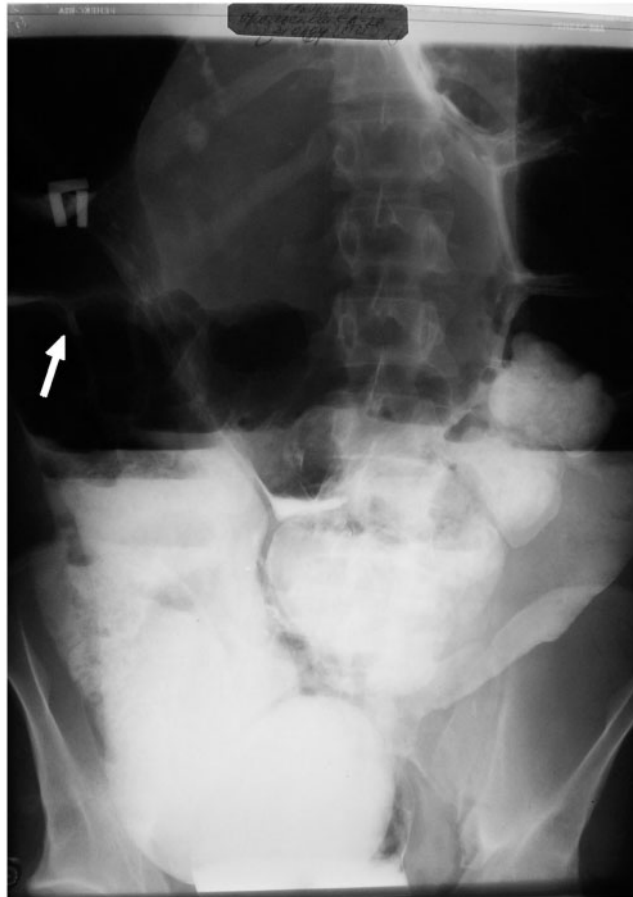

Fig. 1. Upright abdominal radiograph. Dilated and distended bowel loop located beneath the right hemidiaphragm. Chilaiditi sign.

childhood. During his medical history, 3 episodes of emergency hospital admission occurred, in which the patient experienced severe abdominal pain. The condition of the patient worsened over time; pains and bloating became more evident and weight loss over the previous 3 years had been 30 kg.

Diagnostic procedures

Physical examination revealed that the patient had lost weight, was asthenic and pale. The abdomen was bloated and painful. The blood tests showed moderate leucocytosis. An erect abdominal radiograph revealed a dilated and distended bowel loop that was located beneath the right hemidiaphragm (Fig. 1). These findings suggested Chilaiditi syndrome. Signs of atrophic colitis were seen at colonoscopy. A further barium enema showed a distended colon, which was nearly 14 cm in diameter. The rectal sphincter tone was normal. Anorectal manometry was performed to exclude Hirschsprung disease. Internal and external sphincter function was normal. Before surgery, the patient received fluids to correct electrolyte disturbances. Preoperative bowel preparation and antibiotics were used.

Surgery

At surgery, a long midline laparotomy was performed for access. There were no signs of a sigmoid volvulus but an extremely distended sigmoid colon up to 14 cm was identified (Fig. 2). The transverse colon was massively dilated. After complete mobilization of the colon, a subtotal colon resection was performed^[1], rotating the ileocaecal junction through 180 degrees and carrying out end-to-end anastomosis to the upper rectum using interrupted 4/0 PDS sutures (Fig. 3). The operating time was 3.5 h. The length of the resected specimen was 95 cm.

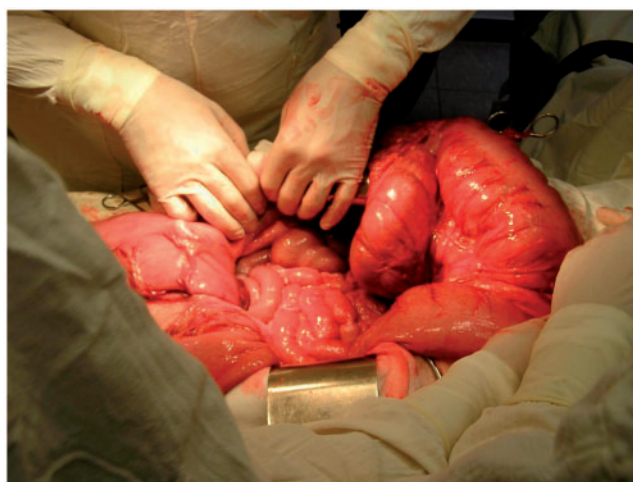

Fig. 2. Distended sigmoid and transverse colon.

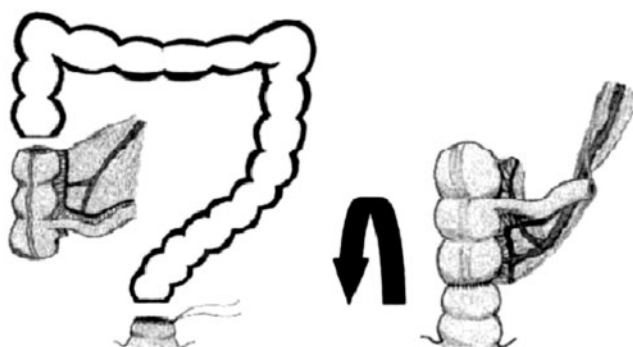


Fig. 3. Design of the operation. Subtotal colon resection with 180-degree ileocaecal junction rotation and ascendo-rectal end-to-end anastomosis^[1].

Macroscopic examination revealed a 95-cm length of colon dilated to a diameter of 14 cm with a 5-cm mesentery. The serosa was smooth, and the colonic wall was 3–4 mm thick.

Microscopic examination revealed a normal mucosa with signs of hyperplasia. The submucous layer was thickened with an increased number of Cajal cells, and there was thick, high-density collagen IV and alpha-actin. The muscular layers were hypertrophic and the vessels were significantly ectatic. The normal architecture of the myenteric and submucosal plexi was verified by immunohistochemical investigation. The mesentery contained lymph nodes with haemorrhagic maculation and ectatic sinuses.

Outcome

The patient's postoperative recovery was uneventful. He received intravenous fluids, resumed oral food intake on the fourth postoperative day, and opened his bowels on the fourth postoperative day. He was discharged home after 10 days. At 6-year follow-up he remained in good health. Three months after the operation, his mean bowel frequency was 5 daily, with a semi-liquid stool consistency. After 2 years, the mean bowel frequency was down to 2 daily, with a semi-solid stool consistency. He has gained 35 kg and is actively working. There is occasional abdominal pain and bloating but this is mostly dependent on diet. The patient reported a good quality of life and was satisfied with the results.

Discussion

Chilaiditi sign describes an anomalous anatomic position of the hepatic flexure of the colon between the liver and the right diaphragm. When a patient exhibits this anatomic anomaly and

has associated gastrointestinal symptoms, the condition is called Chilaiditi syndrome^[2]. The management of Chilaiditi syndrome remains controversial. Surgery is usually performed for emergency conditions such as volvulus and colonic obstruction. Detorsion, colopexy or partial resection of the colon has been offered as remedies in some papers. However, these methods may lead to recurrence of the disease. The aim of this study was to evaluate the feasibility of treating a patient with Chilaiditi syndrome and chronic obstruction who did not respond to medical therapy, with a single-stage subtotal colon resection and anastomosis. An excessive colon length and laxity of the colonic suspensory ligaments in Chilaiditi syndrome are the principal predisposing factors^[3]. Nonresective procedures have been used in patients with a viable colon, although high recurrence rates have been reported in such cases^[3,4]. Creation of a colostomy or primary anastomosis is dependent on local conditions. If the bowel is viable, detorsion with a colopexy, resection of the excessive colon or simple reduction of the volvulus is usually recommended but all these measures leave a potential for recurrence^[4]. Presently, no reported cases of single-stage subtotal colon resection and anastomosis in Chilaiditi syndrome can be found in the literature.

Conclusion

We proposed a single-stage subtotal colon resection and anastomosis for recurrence-free treatment in Chilaiditi syndrome. In our case there was no postoperative mortality, low morbidity and a high level of patient satisfaction with the results.

Teaching points

- Chilaiditi syndrome is rare
- Conservative surgery tends to lead to recurrence
- Subtotal colectomy with primary anastomosis may be the treatment of choice

References

1. Deloyers L. Suspension of the right colon permits without exception preservation of the anal sphincter after extensive colectomy of the transverse and left colon (including rectum). *Technic -indications- immediate and late results.* *Lyon Chir* 1964; 60: 404-13.
2. Saber AA, Boros MJ. Chilaiditi's syndrome: what should every surgeon know? *Am Surg* 2005; 71: 261-3.
3. Orangio GR, Fazio VW, Winkelman E, McGonagle BA. The Chilaiditi syndrome and associated volvulus of the transverse colon. An indication for surgical therapy. *Dis Colon Rectum* 1986; 29: 653-6. doi:10.1007/BF02560330.
4. Matsushima K, Suzuki Y. Transverse colon volvulus and associated Chilaiditi's syndrome. *Am J Surg* 2006; 192: 203-4. doi:10.1016/j.amjsurg.2006.01.015.