

Persistent haemarthrosis following total knee arthroplasty caused by unrecognised arterial injury

Paul Whittingham-Jones^a, Irshad Baloch^a, Jonathan Miles^b and Barry Ferris^a

^aDepartment of Orthopaedics, Barnet Hospital, Barnet, Herts, UK; ^bRoyal National Orthopaedic Hospital, Stanmore, Middlesex, UK

Corresponding address: Paul Whittingham-Jones, 14, Raydean Road, Barnet, Herts, EN5 1AN, UK.

Email: drpaulwj@hotmail.com

Date accepted for publication 4 May 2010

Abstract

Arterial injury is a rare complication of knee replacement. We present a delayed presentation which was proven with arteriography and successfully treated with embolisation rather than open surgery. In atypical clinical pictures of swelling and equivocal inflammatory markers, clinicians should consider the differential diagnosis of persistent arterial bleeding.

Keywords

Total knee replacement; arterial injury.

Case report

An 83-year-old man with diabetes with a painful, osteoarthritic knee underwent an uneventful press fit condylar cruciate retaining total knee replacement (TKR) (DePuy, Johnson and Johnson, Langhorne, PA, USA) via a medial parapatellar approach. Twenty-five days later he represented with sudden onset, significant and painful swelling of this knee. He had no pyrexia and inflammatory markers were equivocal for infection. Arthroscopy revealed a tense haemarthrosis and no evidence of infection; this was confirmed on microbiological cultures. The patient was discharged but presented with similar symptoms twice more, 4 and 6 weeks after the TKR. On the second occasion an open washout was performed of a further, large haematoma. A computed tomography (CT) angiogram revealed a solitary bleeding site from the lateral inferior geniculate artery (Fig. 1). This vessel was selectively catheterised and embolised using four 2 × 2 embolisation microcoils via a Renegade catheter (Boston Scientific, Massachusetts, USA) (Fig. 2). Following this there was no further swelling and the patient made a full recovery.

Discussion

The differential diagnosis of a painful, swollen knee following TKR is a common clinical problem. This case was treated initially as a presumed infection against a background of diabetes.

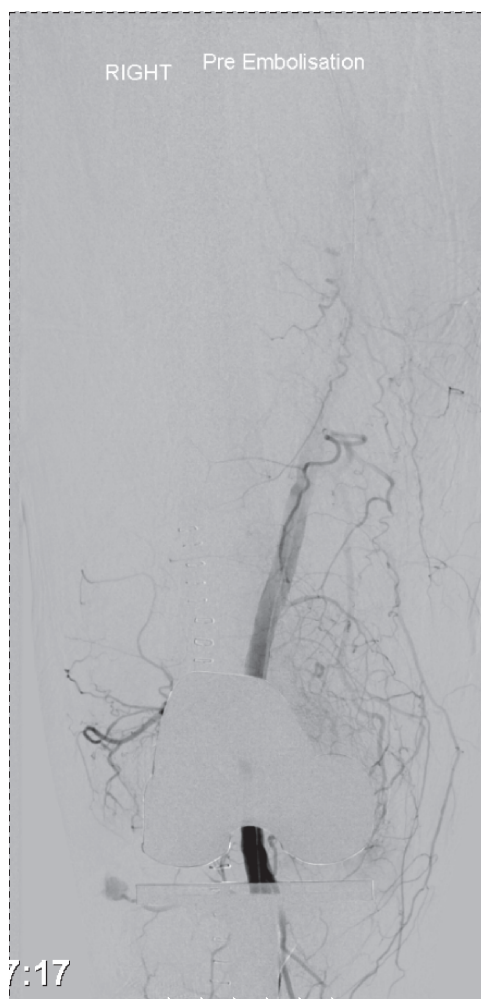


Fig. 1. Selective angiogram demonstrating abnormal blush.

The usual indicators of inflammatory markers and clinical evaluation were always equivocal but a counsel of treating the likely diagnosis was used. In a patient with diabetes with a potentially infected orthopaedic prosthesis, any delay in diagnosis or treatment for infection could have profound consequences. This was an atypical presentation of an uncommon complication of knee surgery with clinical features more in keeping with infection. Normal peripheral pulses and lack of apparent arterial pathology compounded the diagnostic confusion. Arterial injury is a rare entity following TKR^[1,2] and may occur acutely, soon after surgery, with the typical pulseless, ischaemic leg. It may, however, present on a more chronic basis. Kindsfater^[1] showed a mean time at presentation of haemarthrosis at 2 years after arthroplasty. Arterial complications in the literature include pseudoaneurysm formation, arteriovenous fistula formation, popliteal artery thrombosis, transaction or embolisation^[3-13]. Causes of bleeding include coagulopathies, pigmented villonodular synovitis, arteriovenous fistula and injury to geniculate arteries^[14-20].

There has been one report previously of such a lesion to the lateral inferior geniculate artery^[21]. The authors agree with the proposed treatment pathway for recurrent unexplained haemarthrosis after TKR. Following aspiration for confirmation and the failure of conservative measures, femoral arteriography should be considered. The inferior geniculate arteries travel deep to gastrocnemius and traverse close to the collateral ligaments and laterally the head of the fibula. These vessels are at risk at various points during the TKR.

Use of diagnostic and therapeutic angiography with embolisation has been shown to be useful and effective in the management of such cases^[22-25]; it is a simple, relatively non-invasive procedure. Selective embolisation also reduces the risk of ischaemia and is carried out under local anaesthetic.

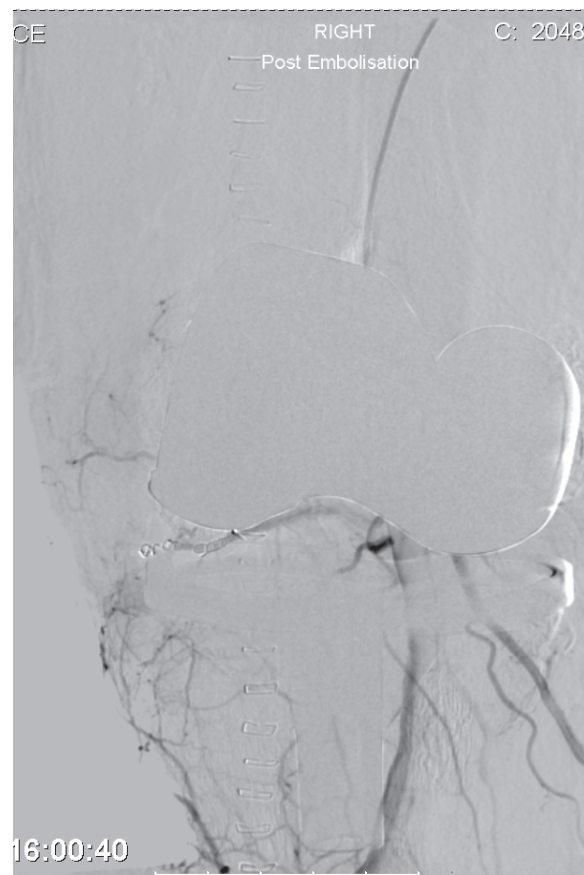


Fig. 2. Angiogram following embolisation. No further bleeding, coils in situ.

Teaching point

Of particular interest in this case is the delay in presentation. The authors recommend in cases where there is a confused clinical picture with swelling and equivocal inflammatory markers that clinicians entertain the differential of haemarthrosis from an on-going arterial bleed.

References

1. Kindsfater K, Scott R. Recurrent haemarthrosis after total knee arthroplasty. *J Arthroplasty* 1995; 10(Suppl): S52-5. doi:10.1016/S0883-5403(05)80231-1.
2. Langkemer VG. Local vascular complications after knee replacement: a review with illustrative case reports. *Knee* 2001; 8: 259-64. doi:10.1016/S0968-0160(01)00103-X.
3. Calligaro KD, DeLaurentis DA, Booth RE, *et al.* Acute arterial thrombosis associated with total knee arthroplasty. *J Vasc Surg* 1994; 20: 927-32.
4. Dennis DA, Neumann RD, Toma P, *et al.* Arteriovenous fistula with false aneurysm of the inferior medial geniculate artery: a complication of total knee arthroplasty. *Clin Orthop* 1987; 222: 255-60.
5. Hozack WJ, Cole PA, Gardner R, *et al.* Popliteal aneurysm following total knee arthroplasty: case report and review of the literature. *J Arthroplasty* 1990; 5: 301-5. doi:10.1016/S0883-5403(08)80087-3.
6. Mureebe L, Gahtan V, Kahn MB, Kerstein MD, Roberts AB. Popliteal artery injury after total knee arthroplasty. *Am Surg* 1996; 62: 366-8.
7. Rand JA. Vascular complications of total knee arthroplasty. *J Arthroplasty* 1987; 2: 89-93. doi:10.1016/S0883-5403(87)80014-1.
8. Rush JH, Vidovich JD, Johnson MA. Arterial complications of total knee replacement: the Australian experience. *J Bone Joint Surg Br* 1987; 69: 400-2.
9. Robson LJ, Walls CE, Swanson AB. Popliteal artery obstruction following Shiers total knee replacement: a case report. *Clin Orthop* 1975; 109: 130-5.

10. McAuley CE, Steed DL, Webster MW. Arterial complications of total knee replacement. *Arch Surg* 1984; 119: 960-2.
11. McWilliams TG, Poon CL, McCollum CN. An unusual complications of total knee replacement. *J Bone Joint Surg Br* 1997; 79: 102-3.
12. DeLaurentis DA, Levitsky KA, Booth RE, *et al.* Arterial and ischaemic aspects of total knee arthroplasty. *Am J Surg* 1992; 164: 237-40. doi:10.1016/S0002-9610(05)81078-5.
13. Zahrani HA, Cuschieri RJ. Vascular complications after total knee replacement. *J Cardiovasc Surg* 1989; 30: 951-2.
14. Oishi CS, Elliott ML, Colwell CW. Recurrent hemarthrosis following a total knee arthroplasty. *J Arthroplasty* 1995; 10: S56-8. doi:10.1016/S0883-5403(05)80232-3.
15. Haddad FS, Prendergast CM, Dorrell JH, Platts A. Arteriovenous fistula after fibular osteotomy leading to recurrent haemarthrosis in a total knee replacement. *J Bone Joint Surg (Br)* 1996; 78: 458-60.
16. Worland RE, Scuderi GR, Insall JN. Patellar fractures in total knee arthroplasty. *J Arthroplasty* 1996; 11: 976-7.
17. Hendel D, Valan G. Late recurrent hemarthrosis after total knee arthroplasty. *Harefuah* 1997; 132: 325-6.
18. Katsimihas M, Robinson D, Thornton M, Langkamer VG. Therapeutic embolisation of the genicular arteries for recurrent hemarthrosis after total knee arthroplasty. *J Arthroplasty* 1995; 10: S52-5.
19. Ballard WT, Clark CR, Callaghan JJ. Recurrent spontaneous hemarthrosis nine years after a total knee arthroplasty. *J Bone Joint Surg (Am)* 1993; 74: 764-7.
20. Cunningham RB, Mariani EM. Spontaneous hemarthrosis 6 years after total knee arthroplasty. *J Arthroplasty* 2001; 16: 133-5. doi:10.1054/arth.2001.9050. PMID:11172285.
21. Alexander R, Gino M, Kerkhoffs MJ, Schneider P, Kuster MS. Recurrent hemarthrosis after total knee arthroplasty. *Knee Surg Sports Traumatol Arthrosc* 2010, in press.
22. Allison DJ. Therapeutic embolisation. *J Bone Joint Surg* 1982; 64B: 151-2.
23. Bennett JD, Brown TC, Coaes CF, MacKenzie D, Sweeney J. Pseudoaneurysm of the inferior gluteal artery. *Can Assoc Radiol J* 1992; 43: 296-8.
24. De Groof E, Violin D, Hermans P, Boghemans J. Bleeding from the lateral circumflex artery following total hip replacement treated by embolisation. *Acta Orthop Belg* 1994; 60: 231-4.
25. Dejean O, Hardy P, Raufaste D, Benoit J. [Embolisation of the circumflex femoral artery for a recurrent haemorrhage after total hip arthroplasty: report of a case]. *Rev Chir Orthop* 1992; 78: 201-4 (in French).