

Unusual ultrasound presentation of testicular metastasis from renal clear cell carcinoma

Lucio Dell'Atti

Department of Urology, University Hospital St. Anna, Ferrara, Italy

Abstract

Testicular metastases from renal clear cell carcinoma (RCC) are extremely uncommon. To the best of our knowledge, only 32 cases have been reported in the literature. We report a rare case of testicular metastasis from RCC. A 69-year-old patient presented with discomfort and pain in his left testis. He had undergone laparoscopic left radical nephrectomy at another institution. Scrotal ultrasonography revealed a non-palpable lesion at the upper pole of the left testis with hypoechoic aspect, highly suspicious for malignancy. We performed a left inguinal orchiectomy. The testicular lesion was diagnosed as a metastasis from RCC. After orchiectomy, a computed tomography of the chest and abdomen revealed no other metastatic lesions. The patient remains free of clinical recurrence after 20 months without adjuvant therapy.

Introduction

With the exception of the infiltration of leukemia and lymphoma, secondary tumors of the testis are rare with a reported incidence of 0.05% at autopsy.¹ The most common primary site of testicular metastases is the prostate, followed by the lung, melanomas, skin, colon, and kidney.² Testicular metastases generally are painless and are detected incidentally as scrotal palpable masses.³ We report the case of a patient with testicular metastasis secondary to renal clear cell carcinoma (RCC) who was diagnosed by an ultrasound examination in the left testis, two years after nephrectomy.

Case Report

A 69-years-old Caucasian male presented to our Urology Department with discomfort and pain in his left testis that had persisted for one month. He had undergone laparoscopic left radical nephrectomy at another institution two years ago. The preoperative metastatic evaluation at the time, including a computed tomography (CT) of the chest, abdomen and pelvis,

was negative. The pathological report of the surgical specimen revealed RCC (grade II, pT1b N0M0). Physical examination revealed no signs of lymphadenopathy in the groin region. There were no signs of a direct or indirect hernia. The soft prostate was palpable by digital rectal exam, without any abnormal findings. Scrotal examination revealed that the man's testes were normal-sized in absence of palpable masses. The upper pole of the left testis was painful on palpation. The scrotal skin showed no evidence of inflammation. Scrotal ultrasonography, using a 10MHz linear probe, revealed a 15×12 mm mass at the upper pole of the left testis with hypoechoic aspect, highly suspicious for malignancy (Figure 1).

The patient did not demonstrate any laboratory signs of inflammation (white blood cells, C reactive protein). Laboratory tests (complete blood count, including platelets, prothrombin, partial thromboplastin levels, urinalysis) were within normal. Moreover, laboratory results for alpha-fetoprotein, human chorionic gonadotropin, and lactate dehydrogenase were negative. A unilateral orchiectomy was then performed in March 2014. Macroscopic examination of the operative specimen reported a yellowish-white lesion in the testis, without extension to the para-testicular tissues. Histological examination revealed cells with small, slightly oval nuclei and abundant clear cytoplasm arranged in cords (Figure 2).

Immunohistochemically, the tumor cells are positive for vimentin, AE1/AE3 keratins, CD10, and carbonic anhydrase IX (G250), but negative for CD117 and lymphoma markers. These results were compatible with a diagnosis of metastasis from RCC. After orchiectomy, a CT of the chest and abdomen revealed no other metastatic lesions. The patient remains free of clinical recurrence after 20 months without adjuvant therapy.

Discussion

Metastases from RCC are frequently observed in lymph nodes, lungs, bones, liver and brain; they are rarely identified in the testes.³ This is the first case of testicular metastasis secondary to RCC observed in patients who underwent radical nephrectomy between 1995 and 2015 at our institution. Bandler and colleagues⁴ reported the first case of RCC metastatic to the testis in 1946. Approximately 32 cases of testicular metastases from RCC have been published during the past few decades.⁵⁻⁸ The majority of these patients had multiple metastases; a solitary testicular metastasis was present in 14 patients and in 56% was ipsilateral to RCC. None of these patients had testicular disease. Moriyama and colleagues⁸ reported the only

Correspondence: Lucio Dell'Atti, Department of Urology, University Hospital St. Anna, 8 A. Moro Street, 44124 Cona, Ferrara, Italy.
Tel: +39.0532.236078. Fax: +39.0532.236547.
E-mail: dellatti@hotmail.com

Key words: Testicular metastasis; renal carcinoma; ultrasound.

Conflict of interest: the author declares no potential conflict of interest.

Received for publication: 15 February 2016.

Revision received: 5 May 2016.

Accepted for publication: 12 May 2016.

This work is licensed under a Creative Commons Attribution NonCommercial 4.0 License (CC BY-NC 4.0).

©Copyright L. Dell'Atti, 2016
Licensee PAGEPress, Italy
Rare Tumors 2016; 8:6471
doi:10.4081/rt.2016.6471

case of simultaneous bilateral testicular metastases from RCC. Following a review of the literature, ipsilateral testicular metastasis from RCC is more frequent and, thus, retrograde venous spread via the spermatic vein may be one of the main pathways of testicular metastasis from RCC.^{3,8} Clinical manifestations of secondary testicular tumors from RCC are varied.⁹ Most often, a palpable mass is detected which may be confused with a primary testicular neoplasm. In our case, the patient had a non-palpable testicular lesion and we suspected primary testicular cancer with ultrasound examination for a scrotal discomfort. Primary testicular seminoma is the most common testicular tumor, accounting up to 50-55% of all testicular tumors and occurs more commonly in younger men (about 35-45 years old) than older men (more than 50-year-old).¹⁰ Histologically seminoma cells have clear to lightly eosinophilic granular cytoplasm and central nuclei. These metastatic cells are closely opposed, with well-defined cytoplasmic border with small oval nuclei and abundant clear cytoplasm arranged in cords or dividing by fine fibrous trabeculae associated with lymphocytic infiltrate.³ Rarely seminomas presented predominantly with intertubular growth with differential diagnosis of metastatic carcinomas or lymphoma.¹⁰ Since most patients are above 60 years of age, lymphoma and metastatic diseases enter in the differential diagnosis. However, if the morphology is not typical for secondary tumors as renal carcinoma, immunohistochemical study generally helps us to arrive at exact diagnosis.

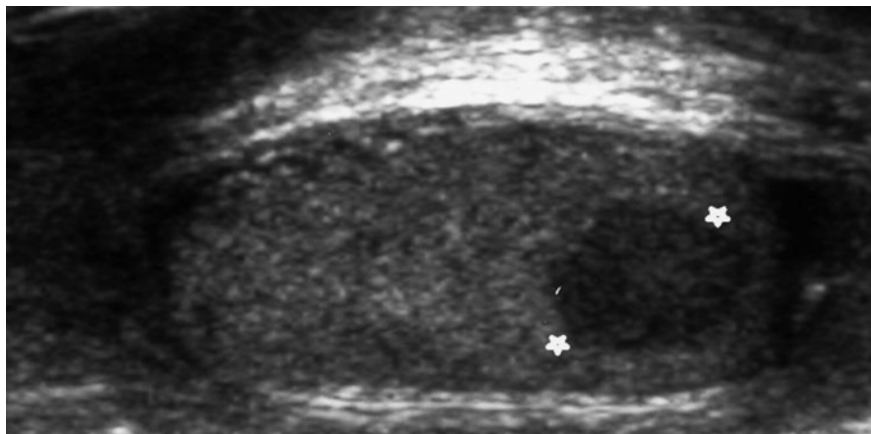


Figure 1. Ultrasonography showing an ovoid and hypoechoic 15×12 mm sized mass in the upper pole of left testis (white stars).

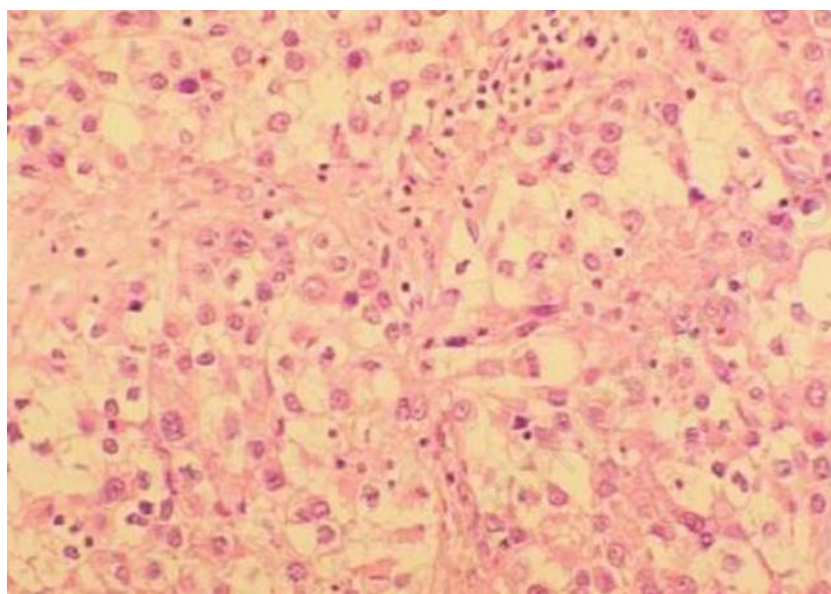


Figure 2. Microscopic section of the left testicular tumor (×200) shows cells with small, slightly oval nuclei and abundant clear cytoplasm: a typical pattern of clear renal cell carcinoma.

Conclusions

This case report highlights the need for careful clinical follow-up of patients with RCC. The prognostic significance of testicular metastasis from RCC is still unknown because

of the rare occurrence in the testis, especially in patients with a history of advanced RCC. Therefore, it is difficult to assess the value of solitary testicular metastasis as a prognostic indicator. Our case is an exception to good prognosis by these secondary tumors.

References

1. Dutt N, Bates AW, Baithun SI. Secondary neoplasms of the male genital tract with different patterns of involvement in adults and children. *Histopathology* 2000;37:323-31.
2. Camerini A, Tartarelli G, Martini L, et al. Ipsilateral right testicular metastasis from renal cell carcinoma in a responder patient to interleukine-2 treatment. *Int J Urol* 2007;14:259-60.
3. Datta MW, Ulbright TM, Young RH. Renal cell carcinoma metastatic to the testis and its adnexa: a report of five cases including three that accounted for the initial clinical presentation. *Int J Surg Pathol* 2001;9:49-56.
4. Bandler CG, Roen PR. Solitary testicular metastasis simulating primary tumor and antedating clinical hypernephroma of the kidney; report of a case. *J Urol* 1946;55:663-9.
5. Nabi G, Gania MA, Sharma MC. Solitary delayed contralateral testicular metastasis from renal cell carcinoma. *Indian J Pathol Microbiol* 2001;44:487-8.
6. Dieckmann KP, Düe W, Loy V. Intrascrotal metastasis of renal cell carcinoma. Case reports and review of the literature. *Eur Urol* 1988;15:297-301.
7. Talerman A, Kniestedt WF. Testicular tumor as the first manifestation of renal carcinoma. *J Urol* 1974;111:584-6.
8. Moriyama S, Takeshita H, Adachi A, et al. Simultaneous bilateral testicular metastases from renal clear cell carcinoma: A case report and review of the literature. *Oncol Lett* 2014;7:1273-5.
9. Blefari F, Risi O, Pino P. Secondary tumors of testis: two rare cases and review of the literature. *Urol Int* 1992;48:469-70.
10. Haupt B, Ro JY, Ayala AG, Zhai J. Metastatic prostatic carcinoma to testis: histological features mimicking lymphoma. *Int J Clin Exp Pathol* 2009;2:104-7.