

# Effect of long-term treatment with rituximab on pulmonary function and skin fibrosis in patients with diffuse systemic sclerosis

D. Daoussis<sup>1</sup>, S.C. Liossis<sup>1</sup>, A.C. Tsamandas<sup>2</sup>, C. Kalogeropoulou<sup>3</sup>, F. Paliogianni<sup>4</sup>, C. Sirinian<sup>2</sup>, G. Yiannopoulos<sup>1</sup>, A.P. Andonopoulos<sup>1</sup>

<sup>1</sup>Division of Rheumatology, Department of Internal Medicine, <sup>2</sup>Department of Pathology, <sup>3</sup>Department of Radiology, and <sup>4</sup>Department of Microbiology-Immunology, Patras University Hospital, University of Patras Medical School, Patras, Greece.

\*Dimitrios Daoussis, MD

\*Stamatis-Nick C. Liossis, MD

Athanassios C. Tsamandas

Christina Kalogeropoulou, MD

Fotini Paliogianni, MD

Chaido Sirinian, MSc

Georgios Yiannopoulos, MD

Andrew P. Andonopoulos, MD, FACP

\*These authors made an equal contribution to this study.

Please address correspondence and reprint requests to:

Dimitrios Daoussis, MD,  
Department of Internal Medicine,  
Division of Rheumatology,  
Patras University Hospital,  
26504 Rion, Patras, Greece.

E-mail: jimdaoussis@hotmail.com

Received on February 9, 2010; accepted in revised form on August 11, 2011.

Clin Exp Rheumatol 2012; 30 (Suppl. 71): S17-S22.

© Copyright CLINICAL AND EXPERIMENTAL RHEUMATOLOGY 2012.

**Key words:** systemic sclerosis, scleroderma, rituximab, B cells, fibrosis, interstitial lung disease

*Funding:* This study was funded by the Hellenic Society for Rheumatology, a non-profitable organisation which did not interfere in any part of the study.

*Competing interests:* none declared.

## ABSTRACT

**Objectives.** To assess the safety and efficacy of long-term treatment with rituximab (RTX) in patients with systemic sclerosis (SSc).

**Methods.** Eight patients with SSc-associated interstitial lung disease (ILD) received 4 cycles of RTX and had a follow-up of 2 years. Lung involvement was assessed by pulmonary function tests and chest HRCT. Skin involvement was assessed both clinically and histologically.

**Results.** We found a linear improvement of lung function and skin thickening over the 2 years of RTX treatment. There was a significant increase of FVC at 2 years compared to baseline (mean  $\pm$  SEM: 77.13 $\pm$ 7.13 vs. 68.13 $\pm$ 6.96, respectively,  $p < 0.0001$ ). Similarly, DLco increased significantly at 2 years compared to baseline (mean  $\pm$  SEM: 63.13 $\pm$ 7.65 vs. 52.25 $\pm$ 7.32, respectively,  $p < 0.001$ ). Skin thickening, assessed with the MRSS, improved significantly at 2 years compared to baseline (mean  $\pm$  SEM: 4.87 $\pm$ 0.83 vs. 13.5 $\pm$ 2.42, respectively,  $p < 0.0001$ ). A reduction in myofibroblast score was seen histologically following RTX treatment.

**Conclusion.** Our results indicate that long-term treatment with RTX may favourably affect lung function and skin fibrosis in patients with SSc. Larger scale, multicentre, randomised, controlled studies are needed to further explore the efficacy of RTX in SSc.

## Introduction

Systemic sclerosis (SSc) is a rheumatic disease characterised of vasculopathy, autoimmunity and progressive fibrosis (1). Lung involvement in the form of interstitial lung disease (ILD) is one of the most serious manifestations of SSc. Patients with severe SSc-associated ILD have a survival rate of only

58% within 10 years from disease onset (2). Therapeutic options for SSc-associated ILD are extremely limited and only cyclophosphamide (CYC) has been formally tested in a multicentre, randomised, double blind, placebo controlled trial, showing statistically significant results (3). The clinical efficacy of CYC is modest, with patients exhibiting a slowing down in the rate of pulmonary function tests (PFTs) decline over time; this effect, though, lasts for only a few months following drug discontinuation (4). This indicates the need for continuous treatment; however, its toxicity restricts its long-term use. The above data underscore the necessity for the development of novel therapies with disease modifying properties and acceptable safety profile that can be administered over a long period of time.

Rituximab (RTX) is a monoclonal antibody against human CD20 that targets B cells. The clinical efficacy of RTX in many systemic rheumatic diseases has brought the B cell under the spotlight; with respect to SSc, several lines of evidence from basic research indicate a potential pathogenic role for B cells in the fibrotic process (5-8). RTX exhibits an acceptable safety profile and consecutive courses can be administered without significant toxicity.

In previous studies, we showed that RTX may improve lung function in patients with SSc-associated ILD, in a 1-year, randomised, controlled, proof of concept study (9), as well as in a case report (10). So far four studies have explored the potential clinical efficacy of RTX in SSc (11-13). Our study, however, was the only one specifically designed to test the effect of RTX on SSc-associated ILD, since the presence of ILD was an inclusion criterion and most patients had severe ILD, in contrast with other studies that focused on

skin disease and excluded patients with severe ILD. In our study, eight patients had received 2 cycles of RTX; the first at baseline and the second at 6 months. On the basis of a good clinical response, these patients remained on RTX treatment and received two additional cycles of RTX at 12 and 18 months. We report herein that long-term treatment with RTX associates with a linear improvement of lung function and skin remodeling as indicated by reduction in skin thickening and myofibroblast score.

## Patients and methods

### Patients

We enrolled 8 patients with a diagnosis of SSc, fulfilling the preliminary American College of Rheumatology criteria for the classification of the disease (14). All patients belonged to the diffuse variety of the disease, were anti-Scl-70 positive, had evidence of ILD, as indicated by findings in PFTs and/or HRCT, and had no change in medications and/or dosage of treatment administered during the last 12 months before enrollment. This is an extension of our previous study; all eight patients recruited in the RTX arm of the original study, remained on RTX treatment and received two additional cycles of RTX at 12 and 18 months and have completed a follow-up of 2 years. A local (Patras University Hospital, Patras, Greece) ethics committee approved the study protocol (which fulfilled the Declaration of Helsinki requirements) and a written informed consent was obtained from all participants.

### Treatment

Patients received 4 weekly pulses of rituximab (375 mg/m<sup>2</sup>) at baseline, at 6 months, at 12 months and at 18 months, on top of the already administered treatment (details in Table I).

### PFTs and chest HRCT

Standard PFTs were performed, at baseline, 6, 12 and 24 months in all patients. All patients had an HRCT performed at baseline, at 6 and 18 months. Semiquantitative evaluation of total disease extent (ground glass and reticular lesions) was performed by two experienced radiologists in a blinded

**Table I.** Demographics, clinical characteristics and medications of study subjects.

Patient n/ sex/age	Disease duration (years)	Organ involvement at baseline other than lung	Number of RTX courses	Follow-up (months)	Previous immune based therapies <sup>§</sup>	Concurrent medications <sup>§</sup>
1/F/47	6	DU, Musc, GI	4	24	D-pen	Pred, Bos
2/M/72	5	Musc, GI, Heart	4	24	CYC	Pred, MMF
3/F/56	6	DU, Musc, GI, Heart	4	24	CYC	Pred, Bos
4/M/39	13	DU, Musc, GI, Heart	4	24	D-pen, CYC	Pred, Bos, MMF
5/F/33	15	Musc, GI	4	24	D-pen, MTX	Pred, MMF
6/F/56	7	GI	4	24	–	MMF
7/F/70	1	GI	4	24	–	–
8/F/50	2	Musc	4	24	–	Pred

<sup>§</sup>Discontinued at least 3 years prior to study enrollment.

<sup>§</sup>Started at least 4 years prior to study enrollment.

Pred: low dose prednisone; Bos: bosentan; MMF: mycophenolate mofetil; CYC: cyclophosphamide; MTX: methotrexate; DU: digital ulcers; Musc: musculoskeletal involvement defined as joint contractures (pts 1, 3, 4, 5), muscle weakness (pt 2) and synovitis (pts 1, 5, 8).

GI: gastrointestinal involvement defined as esophageal motility disturbance as assessed by radioisotope method (pts 1, 3, 4, 5 and 6) and gastro-esophageal reflux (pts 1, 2, 3, 4, 5, 6, 7).

Heart: cardiac involvement defined as pulmonary hypertension (pt 3 had an RVSP of 50–55mmHg), diastolic dysfunction (pt 4) and conduction disturbances (pts 2, 4).

fashion, according to a scoring system proposed by Desai *et al.* (15).

### Clinical assessment of skin thickening

The modified Rodnan skin score (MRSS) was employed for clinical assessment of skin thickening at baseline, 6, 12 and 24 months by an experienced assessor in a blinded fashion (16).

### Skin histology

Histologic assessment of skin fibrosis was made by skin biopsies performed at baseline and at 6 months (a 5mm-punch biopsy of lesional skin) in all patients, prior to RTX administration. Myofibroblasts ( $\alpha$ SMA(+) cells) were detected by a standard streptavidin biotin peroxidase method, using an anti- $\alpha$ SMA antibody (Novocastra, UK). Computerised image analysis was used to quantify the results.

### Overall functional impairment.

Assessment of functional status was performed at baseline, 12 and 24 months using the 20-item Health Assessment Questionnaire-Disability Index (HAQ-DI) (17). Clinically significant improvement in functional status was defined as a 0.14 decrease in HAQ-DI score, as previously described (18).

### Statistical analysis

Statistical analysis was performed using the GraphPad Prism software version 5.

Data are presented as mean  $\pm$  SEM, median (upper and lower quartile values) or percentages, as appropriate. Changes from baseline in PFTs and MRSS at 6, 12 and 24 months were analysed using repeated measure analysis of variance (ANOVA) with Dunnett's *post hoc* test (multiple comparisons with baseline). We also tested for linear associations between time and each parameter (ANOVA, *post hoc* test for linear trend). Pearson correlation and paired *t*-test were used as indicated.

## Results

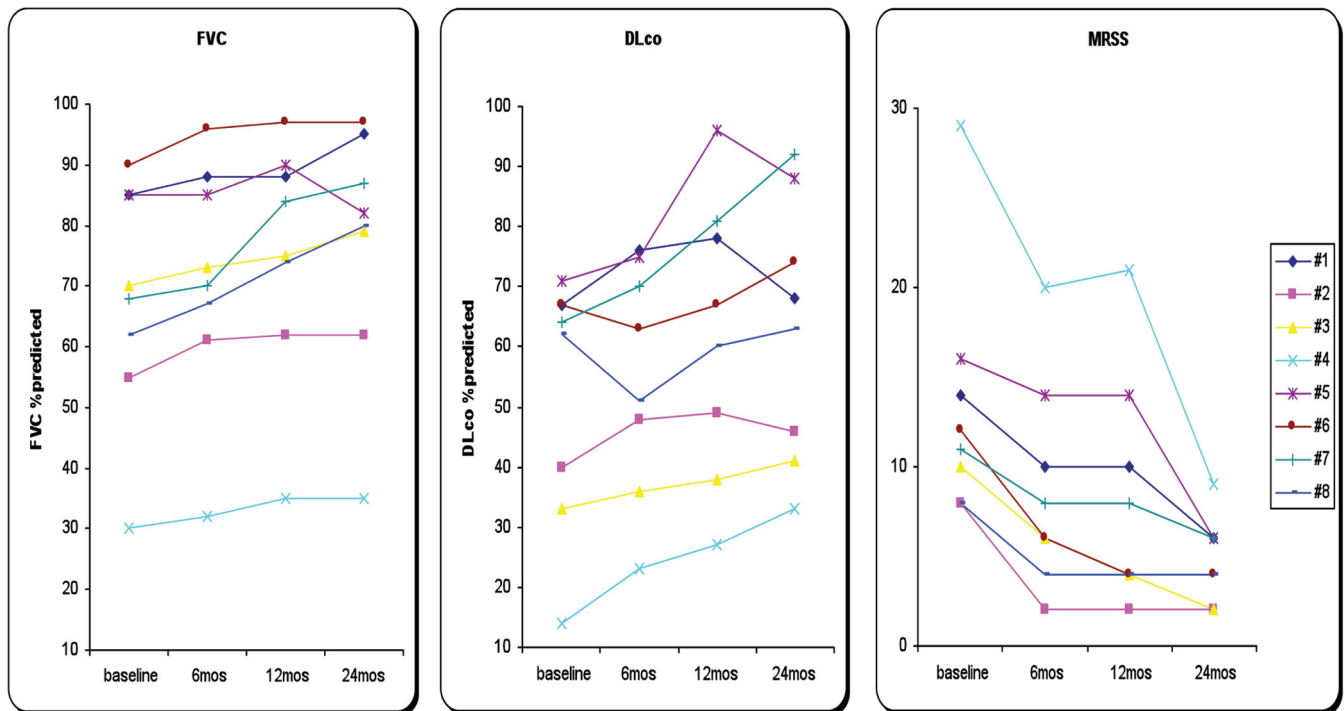
Demographic, clinical characteristics and medications of studied subjects are presented in Table I.

### Effect of long-term RTX treatment on SSc-associated ILD

PFTs and HRCT were used to assess the potential effect of RTX treatment on SSc-associated ILD.

### Long-term RTX treatment is associated with linear improvement of PFTs

PFTs showed a significant, linear improvement over time. There was a significant increase of forced vital capacity (FVC) at 2 years compared to baseline (mean  $\pm$  SEM: 77.13 $\pm$ 7.13 vs. 68.13 $\pm$ 6.96, respectively,  $p < 0.0001$ ). A significant increase in FVC was also evident at 1 year (mean  $\pm$  SEM:



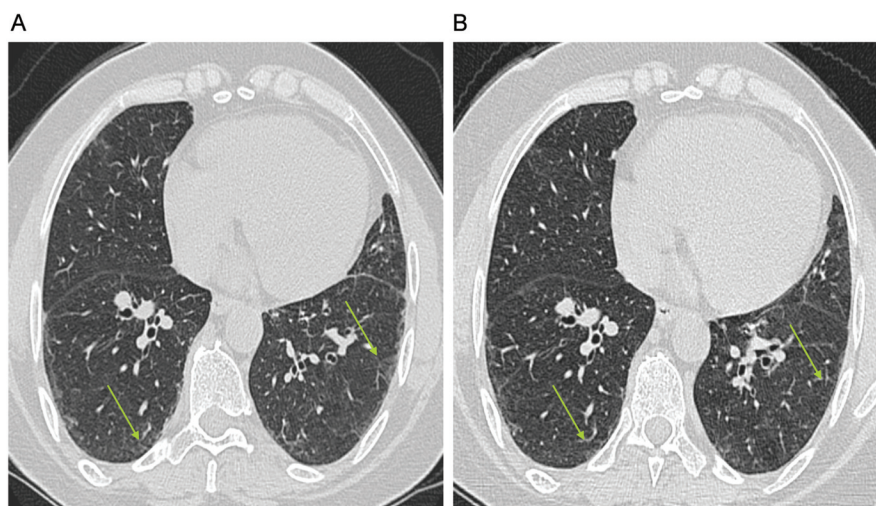
**Fig. 1.** Beneficial effect of long term RTX treatment on lung function and skin thickening in patients with SSc. RTX mediates a significant linear improvement of FVC ( $p<0.0001$ ) and DLco ( $p=0.0003$ ) during a 2-year follow-up (A and B, respectively). Similarly, skin thickening improved as indicated by a significant decline ( $p<0.0001$ ) in MRSS (C).

75.63±6.97,  $p<0.001$  compared to baseline), but not at 6 months (mean ± SEM: 71.5±7,  $p=ns$  compared to baseline). These results indicate a significant linear improvement of FVC over time ( $p<0.0001$ , ANOVA, *post test* for linear trend), as shown in Figure 1A. The median (upper and lower quartile

values) percentage of improvement of FVC at 24 months compared to baseline was 12.79% (8.76–25.12). Patients n. 7 and n. 8, who had early disease, had the most striking improvement (27.94% and 29.03%, respectively). Similarly, DLco increased significantly at 2 years compared to base-

line (mean ± SEM: 63.13±7.65 vs. 52.25±7.32, respectively,  $p<0.001$ ). A significant increase in DLco was also found at 1 year (mean ± SEM: 62±8.2,  $p<0.001$  compared to baseline) whereas at 6 months DLco values showed an upward trend which did not reach statistical significance (mean ± SEM: 55.25±6.78,  $p=ns$  compared to baseline). A significant linear improvement over time was found ( $p=0.0003$ , ANOVA, *post test* for linear trend), as shown in Figure 1B. The median (upper and lower quartile values) percentage of improvement of DLco at 24 months compared to baseline was 19.47% (3.81–27.15).

We retrospectively collected data on PFTs during the last 30 months prior to RTX treatment in the 6 patients who had long-standing disease. These patients had declining PFTs and showed a median percentage of deterioration of 10.25% and 17.9% for FVC and DLco, respectively.



**Fig. 2.** Effects of RTX treatment on chest HRCT. Attenuation of ground glass lesions in areas depicted by the arrows in patient 8 at 18 months (B) compared to baseline (A). Registration of images was automatically conducted by computer software in order to ensure anatomic comparability of slices at follow-up.

#### Effects of long-term RTX treatment on HRCT

Five patients (n. 3, n. 4, n. 6, n. 7 and n. 8) exhibited a modest decrease (5–10%)



in ground glass lesions at 18 months compared to baseline, while reticular lesions remained unchanged (Fig. 2).

#### *Effect of long-term RTX treatment on skin fibrosis in patients with SSc*

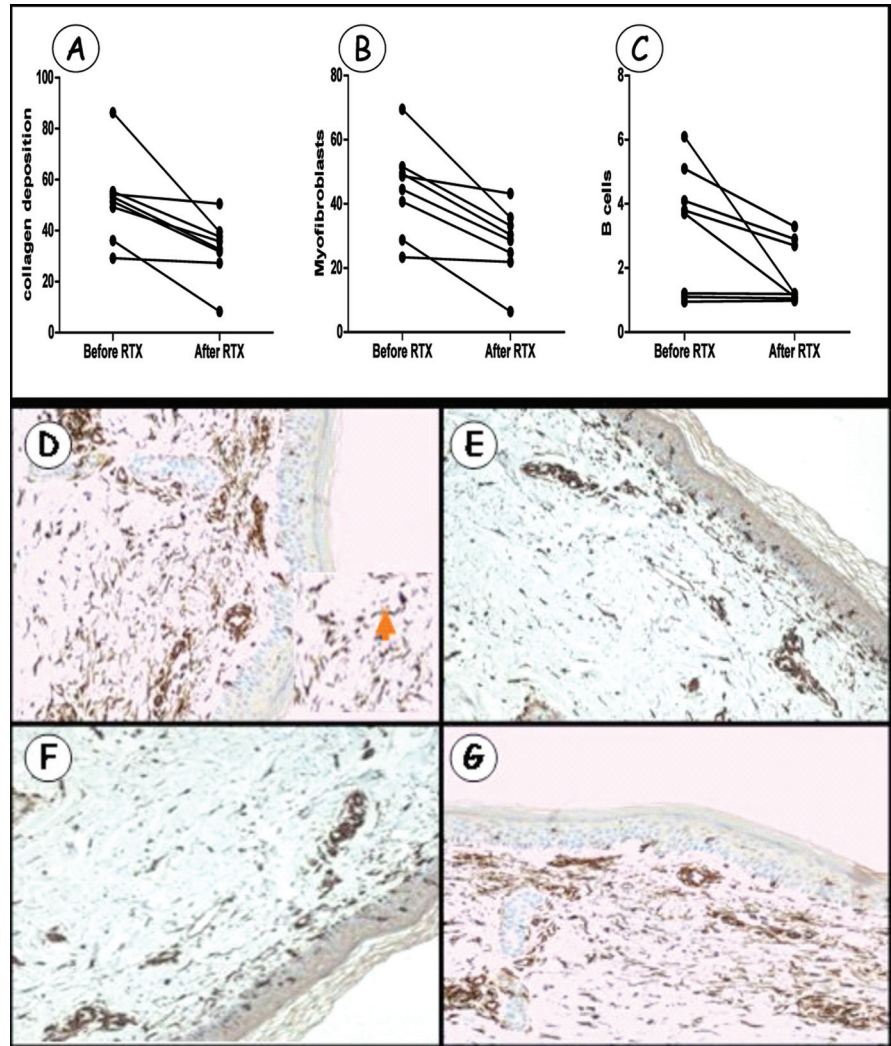
We performed standard clinical assessment by applying the MRSS tool and the skin biopsy analysis in order to assess the effect of RTX on skin fibrosis.

#### *Long-term RTX treatment is associated with improvement of skin thickening*

We found a linear decrease of MRSS over time indicating an improvement of skin thickening. There was a significant decrease of MRSS at 2 years compared to baseline (mean  $\pm$  SEM:  $4.87 \pm 0.83$  vs.  $13.5 \pm 2.42$ , respectively,  $p < 0.0001$ ). A significant decrease in MRSS was also found at 1 year (mean  $\pm$  SEM:  $8.37 \pm 2.28$ ,  $p < 0.001$  compared to baseline) and at 6 months (mean  $\pm$  SEM:  $8.75 \pm 2.06$ ,  $p < 0.001$  compared to baseline). A significant linear decline of MRSS over time, indicating improvement of skin thickening, was found ( $p < 0.0001$ , ANOVA, *post test* for linear trend), as shown in Figure 1C. The median percentage of improvement (upper-lower quartile values) at 1 year was 39.29% (27.35–65) and at 2 years it increased further to 64.58% (51.79–73.74).

#### *Reduction of collagen deposition, skin infiltrating B cells and myofibroblast score following RTX administration*

We have already reported that collagen deposition in the papillary dermis decreases following RTX administration, and that skin B cell depletion correlates with histologic improvement. Evidence of histologic improvement was seen in 6 out of 8 patients (n. 2, n. 3, n. 4, n. 6, n. 7 and n. 8). Myofibroblast score in the papillary dermis decreased significantly following treatment with RTX (mean  $\pm$  SEM,  $44.58 \pm 5.04$  vs.  $8.03 \pm 3.86$ , at baseline vs. 6 months, respectively,  $p = 0.0022$ ). Myofibroblast score decreased in the same 6 patients who showed histologic improvement and remained unchanged in the two patients who did not improve histologically. More details are presented in Figure 3.



**Fig. 3.** RTX-induced changes of skin histology at 6 months. RTX induces a significant decrease in collagen accumulation ( $p = 0.0069$ ), myofibroblast score ( $p = 0.0022$ ) and skin infiltrating B cells (0.044) in the papillary dermis (A, B and C respectively). Representative immunohistochemistry for  $\alpha$ SMA<sup>+</sup> cells (myofibroblasts) in patient 4 prior to (D) and following treatment with RTX (F) as well as in a control patient prior to (E) and 6 months following CYC therapy (G). An obvious reduction in the number of myofibroblasts can be seen in the RTX treated patient in sharp contrast to the control patient, where myofibroblast number increased. The arrow in the inset in panel D (magnified area of the corresponding image) points to a myofibroblast.

#### *Effects of long-term RTX treatment on anti-Scl-70 levels*

Anti-Scl-70 levels were serially evaluated semi-quantitatively in patients who received long-term RTX treatment (at baseline, 6 and 18 months). In patients 3, 6 and 7 a decline in anti-Scl70 levels was found, as shown in Figure 4. No differences were detected in the other patients.

#### *Effects of long-term RTX treatment on functional status, cardiac and renal function*

Cardiac function (ejection fraction and right ventricle systolic pressure) and

renal function (eGFR) remained stable throughout the study (data not shown). A significant improvement in functional status, as indicated by a decline in HAQ-DI scores, was noticed in the 8 patients who received long-term RTX treatment. There was a significant decrease in HAQ-DI scores at 2 years compared to baseline, indicating an improvement in functional status (median [lower and upper quartile values], 0.687 (0.28–1.25) vs. 0.25 (0.125–0.437), at baseline vs. 2 years, respectively,  $p < 0.0001$ ). This improvement was also evident at 1 year (median [lower and upper quartile values] 0.312 (0.125–0.687),  $p < 0.0001$ ).

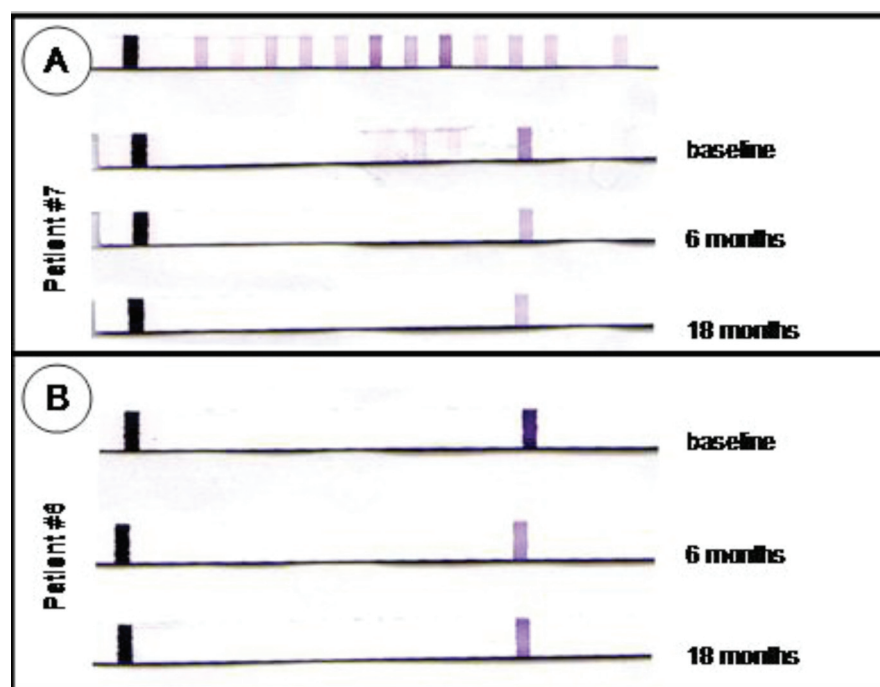


Fig. 4. Long-term treatment with RTX mediates a decline in anti-Scl-70 levels in a subset of patients with SSc. RTX-induced decrease in anti-Scl-70 levels in patient 7 (A) and 6 (B).

Seven patients showed a more than 0.14 decrease in HAQ-DI score, indicating a clinically significant improvement – the single patient who did not improve significantly had a very low baseline score.

#### Adverse events

Three serious adverse events occurred. Patient 2 had a respiratory tract infection three months after the second RTX course. Patient 4 suffered a respiratory tract infection with associated leukopenia 2 months after the third RTX course, and an H1N1 infection 5 months following the fourth RTX course. They both required short-term hospitalisation and recovered fully in a few days. Patient 1 developed a mild infusion reaction during the first RTX course.

#### Discussion

Several lines of evidence from basic research indicate that B cells may be actively involved in the fibrotic process. B cells from the tight skin mouse, an animal model of SSc, show augmented CD19 signalling (19), and treatment with RTX diminishes skin fibrosis (20). In the bleomycin induced mouse model of SSc, where not only skin but also lung fibrosis occurs, CD19 deficiency led to improvement of both

skin and lung fibrosis (21). It has been reported that the development of bleomycin-induced pulmonary fibrosis in mice is regulated by CD19 and that fibrosis associates with the accumulation of CD19<sup>+</sup> B cells in the lungs (22). These studies indicate a potential link between B cell hyperactivity and fibrosis, and provide indirect evidence that modulating B cell function might have beneficial effects on fibrosis. In SSc patients, B cells exhibit increased CD19 expression and are chronically activated (23), whereas genes characteristically expressed in B cells were found to be upregulated in SSc *versus* normal skin (24). Moreover, B cell infiltration was a prominent finding in lung biopsies from patients with SSc-associated ILD (25). The presence of B cells in SSc-associated ILD did not come as a surprise, since other studies have also shown prominent B cell infiltration in RA-associated ILD (26) and idiopathic pulmonary fibrosis (27, 28).

We report herein an improvement of lung function as indicated by a linear increase in PFTs and a modest improvement of HRCT findings, following treatment with RTX during a 2-year period. It is noteworthy that none of the study subjects exhibited worsening of

lung function; instead all patients had an increase by >10% in FVC and/or DLco. In the context of the natural course of the disease, PFTs gradually deteriorate. Patients with disease duration of 4–6 years are reported to have a 3% decline in FVC per year (2), indicating that the significant linear improvement in lung function reported herein is unlikely to be attributed to the natural course of the disease, and suggests disease modifying properties of RTX in SSc-associated ILD.

In other studies (11, 12), assessing the efficacy of RTX in SSc, lung function remained stable throughout a 6-month follow-up. These data are in agreement with ours, since in this study the trend towards improvement in PFTs at 6 months did not reach statistical significance. Therefore, our data indicate that the beneficial effect of RTX on lung function requires more than 6 months to become evident, and that continuous treatment is needed to sustain and further augment this effect. The need for retreatment with RTX was also underscored by a case reported by McGonagle *et al.* (29). The beneficial effect of RTX on SSc-associated ILD in that case waned over time and the patient had to receive a second course of RTX.

Skin thickening significantly improved during the 2-year follow-up of this study in all patients. The median percentage of MRSS decrease at 1 year was approximately 40%, a much higher percentage than that expected within the context of the natural course of the disease, which has been reported to be approximately 20% (30). These data are in agreement with other studies (11–13), also reporting improvement of skin thickening following RTX administration, thus suggesting that RTX may favourably affect skin fibrosis.

Histologic outcomes have rarely been reported in scleroderma trials and up until recently, histologic improvement has only been documented following stem cell transplantation (31). It is noteworthy that histologic improvement has also been reported in the other studies assessing the potential clinical efficacy of RTX in SSc (11–13).

Our study has several potential limitations. These are the small number of



patients recruited and that most patients had long-standing disease. It is generally recommended that patients recruited in scleroderma trials should have early disease, since these patients are more likely to deteriorate over the time of the study and the potential effect of the treatment could be more easily seen. Indeed, the most striking improvement of lung function was documented in the two patients with early disease. Nevertheless, a linear improvement of lung function was also documented in patients with long-standing disease. The fact that a treatment effect could be documented in our study in such patients, which are probably less responsive to any kind of therapy compared to patients with early disease, may provide an argument in favour of the disease modifying role of RTX. Another limitation is that five patients received concurrent treatment with mycophenolate mofetil (MMF) and, even though they have been on that therapy for a long time prior to study enrolment, we cannot exclude the possibility that MMF contributed to the positive outcomes reported herein.

Taking into consideration the limitations of the present study, definite conclusions cannot be drawn. However, our data strongly point to the direction that further exploration of the clinical efficacy of RTX in SSc is warranted. A comparison of RTX *versus* CYC, the gold standard of care so far, in a large, randomised, double blind multicentre study, would seem a reasonable approach.

In conclusion, B cell depletion therapy is well tolerated and may improve lung function and skin fibrosis in patients with SSc. Further exploration of the potential clinical efficacy of RTX in SSc with a multicentre, double blind, controlled study is needed.

## Acknowledgements

We thank Dr A. Kazantzi for her kind contribution in assessing the HRCT scans.

## References

1. GEYER M, MULLER-LADNER U: The pathogenesis of systemic sclerosis revisited. *Clin Rev Allergy Immunol* 2011; 40: 92-103.
2. STEEN VD, CONTE C, OWENS GR, MEDSGER TA JR: Severe restrictive lung disease in systemic sclerosis. *Arthritis Rheum* 1994; 37: 1283-9.
3. TASHKIN DP, ELASHOFF R, CLEMENTS PJ *et al.*: Cyclophosphamide *versus* placebo in scleroderma lung disease. *N Engl J Med* 2006; 354: 2655-66.
4. TASHKIN DP, ELASHOFF R, CLEMENTS PJ *et al.*: Effects of 1-year treatment with cyclophosphamide on outcomes at 2 years in scleroderma lung disease. *Am J Respir Crit Care Med* 2007; 176: 1026-34.
5. SATO S, FUJIMOTO M, HASEGAWA M, TAKEHARA K, TEDDER TF: Altered B lymphocyte function induces systemic autoimmunity in systemic sclerosis. *Mol Immunol* 2004; 41: 1123-33.
6. ASANO N, FUJIMOTO M, YAZAWA N *et al.*: B Lymphocyte signaling established by the CD19/CD22 loop regulates autoimmunity in the tight-skin mouse. *Am J Pathol* 2004; 165: 641-50.
7. WOLLHEIM FA: Is Rituximab a Potential New Therapy in Systemic Sclerosis?: New Evidence Indicates the Presence of CD20-Positive B-lymphocytes in Scleroderma Skin. *J Clin Rheumatol* 2004; 10: 155.
8. HASEGAWA M: B lymphocytes: Shedding new light on the pathogenesis of systemic sclerosis. *J Dermatol* 2010; 37: 3-10.
9. DAOUSSIS D, LIOSSIS SN, TSAMANDAS AC *et al.*: Experience with rituximab in scleroderma: results from a 1-year, proof-of-principle study. *Rheumatology (Oxford)* 2010; 49: 271-80.
10. DAOUSSIS D, LIOSSIS SN, TSAMANDAS AC *et al.*: Is There a role for B-cell depletion as therapy for scleroderma? A case report and review of the literature. *Semin Arthritis Rheum* 2010; 40: 127-36.
11. SMITH V, VAN PRAET JT, VANDOOREN B *et al.*: Rituximab in diffuse cutaneous systemic sclerosis: an open-label clinical and histopathological study. *Ann Rheum Dis* 2010; 69: 193-7.
12. LAFYATIS R, KISSIN E, YORK M *et al.*: B cell depletion with rituximab in patients with diffuse cutaneous systemic sclerosis. *Arthritis Rheum* 2009; 60: 578-83.
13. BOSELLO S, DE SANTIS M, LAMA G *et al.*: B cell depletion in diffuse progressive systemic sclerosis: safety, skin score modification and IL-6 modulation in an up to thirty-six months follow-up open-label trial. *Arthritis Res Ther* 2010; 12: R54.
14. Preliminary criteria for the classification of systemic sclerosis (scleroderma). Subcommittee for scleroderma criteria of the American Rheumatism Association Diagnostic and Therapeutic Criteria Committee. *Arthritis Rheum* 1980; 23: 581-90.
15. DESAI SR, VEERARAGHAVAN S, HANSELL DM *et al.*: CT features of lung disease in patients with systemic sclerosis: comparison with idiopathic pulmonary fibrosis and non-specific interstitial pneumonia. *Radiology* 2004; 232: 560-7.
16. VALENTINI G, D'ANGELO S, DELLA ROSSA A *et al.*: European Scleroderma Study Group to define disease activity criteria for systemic sclerosis. IV. Assessment of skin thickening by modified Rodnan skin score. *Ann Rheum Dis* 2003; 62: 904-5.
17. KHANNA D, FURST DE, CLEMENTS PJ *et al.*: Responsiveness of the SF-36 and the Health Assessment Questionnaire Disability Index in a systemic sclerosis clinical trial. *J Rheumatol* 2005; 32: 832-40.
18. KHANNA D, FURST DE, HAYS RD *et al.*: Minimally important difference in diffuse systemic sclerosis: results from the D-penicillamine study. *Ann Rheum Dis* 2006; 65: 1325-9.
19. SAITO E, FUJIMOTO M, HASEGAWA M *et al.*: CD19-dependent B lymphocyte signaling thresholds influence skin fibrosis and autoimmunity in the tight-skin mouse. *J Clin Invest* 2002; 109: 1453-62.
20. HASEGAWA M, HAMAGUCHI Y, YANABA K *et al.*: B-lymphocyte depletion reduces skin fibrosis and autoimmunity in the tight-skin mouse model for systemic sclerosis. *Am J Pathol* 2006; 169: 954-66.
21. YOSHIZAKI A, IWATA Y, KOMURA K *et al.*: CD19 regulates skin and lung fibrosis via Toll-like receptor signaling in a model of bleomycin-induced scleroderma. *Am J Pathol* 2008; 172: 1650-63.
22. KOMURA K, YANABA K, HORIKAWA M *et al.*: CD19 regulates the development of bleomycin-induced pulmonary fibrosis in a mouse model. *Arthritis Rheum* 2008; 58: 3574-84.
23. SATO S, FUJIMOTO M, HASEGAWA M, TAKEHARA K: Altered blood B lymphocyte homeostasis in systemic sclerosis: expanded naive B cells and diminished but activated memory B cells. *Arthritis Rheum* 2004; 50: 1918-27.
24. WHITFIELD ML, FINLAY DR, MURRAY JI *et al.*: Systemic and cell type-specific gene expression patterns in scleroderma skin. *Proc Natl Acad Sci USA* 2003; 100: 12319-24.
25. LAFYATIS R, O'HARA C, FEGHALI-BOSTWICK CA, MATTESON E: B cell infiltration in systemic sclerosis-associated interstitial lung disease. *Arthritis Rheum* 2007; 56: 3167-8.
26. ATKINS SR, TURESSON C, MYERS JL *et al.*: Morphologic and quantitative assessment of CD20+ B cell infiltrates in rheumatoid arthritis-associated nonspecific interstitial pneumonia and usual interstitial pneumonia. *Arthritis Rheum* 2006; 54: 635-41.
27. CAMPBELL DA, POULTER LW, JANOSSY G, DU BOIS RM: Immunohistological analysis of lung tissue from patients with cryptogenic fibrosing alveolitis suggesting local expression of immune hypersensitivity. *Thorax* 1985; 40: 405-11.
28. WALLACE WA, HOWIE SE, KRAJEWSKI AS, LAMB D: The immunological architecture of B-lymphocyte aggregates in cryptogenic fibrosing alveolitis. *J Pathol* 1996; 178: 323-9.
29. MCGONAGLE D, TAN AL, MADDEN J *et al.*: Successful treatment of resistant scleroderma-associated interstitial lung disease with rituximab. *Rheumatology (Oxford)* 2008; 47: 552-3.
30. MAYES MD, O'DONNELL D, ROTHFIELD NF, CSUKA ME: Minocycline is not effective in systemic sclerosis: results of an open-label multicenter trial. *Arthritis Rheum* 2004; 50: 553-7.
31. NASH RA, MCSWEENEY PA, CROFFORD LJ *et al.*: High-dose immunosuppressive therapy and autologous hematopoietic cell transplantation for severe systemic sclerosis: long-term follow-up of the US multicenter pilot study. *Blood* 2007; 110: 1388-96.