

Patients with systemic lupus erythematosus (SLE) having developed malignant lymphomas. Complete remission of lymphoma following high-dose chemotherapy, but not of SLE

E. Rossi¹, G. Catania¹, M. Truini², G.L. Ravetti³, L. Grassia⁴, A.M. Marmont⁵

¹Division of Haematology 1, Azienda Ospedaliera Universitaria San Martino, Genoa; ²Department of Pathology, National Institute of Cancer Research, Genoa; ³Department of Pathology; ⁴Laboratory of Immunopathology; ⁵Division of Haematology 2, Azienda Ospedaliera Universitaria San Martino, Genoa, Italy.

Edoardo Rossi, MD
Giacchino Catania, MD
Mauro Truini, MD
Gian Luigi Ravetti, MD
Lidia Grassia, MD

Alberto M. Marmont, MD, Professor
Emeritus of Haematology

Please address correspondence
and reprint requests to:

Prof. A.M. Marmont,
I Division of Haematology 2,
Azienda Ospedaliera-Universitaria
S. Martino, L. R. Benzi 10,
16132 Genova, Italy.

E-mail: alberto.marmont@hsanmartino.it

Received on September 27, 2010; accepted
in revised form on January 27, 2011.

© Copyright CLINICAL AND
EXPERIMENTAL RHEUMATOLOGY 2011.

Key words: systemic lupus erythematosus, malignant lymphoma, high-dose chemotherapy

ABSTRACT

The development of malignant lymphomas, generally of the non-Hodgkin type (NHL), and with a preference to diffuse large cell B lymphomas (DLCL), in systemic lupus erythematosus (SLE), has been analysed in an exhaustive recent literature. The combination of germline and somatic mutations, persistent immune overstimulation and the impairment of immune surveillance facilitated by immunosuppressive drugs, is thought to be at the origin of the increased lymphoma genesis. However the treatment and course of such affected patients is less known, and prognosis is generally estimated as poor. Out of 258 patients with complete/incomplete lupus and secondary antiphospholipid syndrome (APS) seen and treated at the institutional Day Hospital between 1982 and 2009, 6 developed lymphomas (4 DLCL, 1 Hodgkin's and 1 indolent lymphocytic lymphoma). The first 5 patients were treated with high dose chemotherapy (HDCT) and achieved complete remissions (CR) with a follow-up comprised between 13 and 172 months. One patient relapsed of lymphoma and died 15 months following CR, with persistent lupus serology. One patient achieved complete remission (CR) of both diseases. In the other 3 lupus serology, Antinuclear and antiphospholipid antibodies (ANA, aPL) persisted, with occasional lupus flares and vascular complications. While eradication of the last cancer stem cell is tantamount to cure in neoplastic disease, persistent autoantigenic overstimulation may contribute to the refractoriness of autoimmunity. The implications of these results for the increasing utilisation of haematopoietic stem cell transplantation for severe autoimmune diseases (SADS), with lupus as a paradigm, are discussed.

Introduction

Recent exhaustive studies have demonstrated the increased risk of developing lymphomas, primarily of the diffuse large B cell type, in autoimmune diseases in general (1-5), and more specifically in SLE (6-8). The progression "from a benign to a malignant state"

(7) has suggested colourful expressions such "double trouble" (9) and "tribulations of B cells" (10). The combination of germline and somatic mutations, persistent immune stimulation, and the impairment of immune surveillance (partly due to immunosuppressive drugs) (6, 11), is thought to be at the origin of the increased lymphomagenesis. In 26 patients mainly affected by rheumatoid arthritis (RA), all of them treated by long-term methotrexate therapy, there were spontaneous remissions of their complicating lymphoproliferative diseases (mainly DLCL) after discontinuation of the immunosuppressive therapy (12). It has been remarked that whether infections (more specifically EBV) and lymphomagenesis in RA are a consequence of too little or too much immunosuppression poses quite a dilemma (13). The endeavours to alter the physiopathology of SLE by means of haematopoietic autologous stem transplantation (ASCT), which relies on a combination of powerful immunosuppression and attendant profound immunological changes (14-17), have been exhaustively discussed elsewhere (18, 19).

The purpose of this contribution is, first, to report that in 5 patients with longstanding SLE having developed malignant lymphomas (4 non-Hodgkin/NHL and 1 Hodgkin's/HD), complete remissions (CR) of the lymphomas have been achieved following high-dose chemotherapy (HDCT), and, second, that in 4 of these 5 patients, who were apparently cured of their lymphomas, there was persistence/relapse of serological and clinical SLE.

Material and methods

Between January 2001 and August 2009 258 patients with SLE (ACR criteria >4) and 294 of incomplete lupus (20), undifferentiated connective tissue disease (21) (UCTD) and secondary antiphospholipid syndrome (APS), were seen and treated at the Day Hospital (with occasional short in-patient stays) of the I Division of Haematology, S. Martino's Hospital, Genoa, Italy. Antinuclear antibodies (ANA) were determined by immunofluorescence utilising Hep-2 cells (IFA), and anti ds-DNA antibodies were determined

Competing interests: none declared.

with the same procedure on Crithidia Luciliae preparations. Anti-phospholipid (aPL) and anti- β 2-glycoprotein I (anti- β 2GPI) were determined by ELISA (Euroimmun, Lübeck, Germany). Malignant lymphomas were classified according to the WHO Classification of Tumours of Haematopoietic and Lymphoid Tissues (22).

Results

Out of 258 lupus patients, 6 developed malignant lymphomas, 5 of the non Hodgkin's (NHL) type and 1 of Hodgkin's (HD), nodular sclerosis subtype. One patient who developed an indolent lymphocytic lymphoma is on a watch and wait (WW) schedule and will not be discussed further. The other 5 were treated with high dose chemotherapy (HDCT) and achieved complete remissions (CR) of their lymphomas, according to the most recent revised response criteria (23). One patient relapsed of lymphoma and died 15 months following CR, with persistent lupus serology. Of the up to now 4 living patients one achieved continuing (90 months) CR of both diseases, one has maintained her autoantibodies (ANA, aPL, anti- β 2GPI), and 2 have also clinically active SLE. In all these cases antibodies to native (ds) DNA had regressed following initial treatment. The lymphoma-free survivals were respectively 13, 20, 54, 90 and 172 months up to the present writing.

Brief case histories

Case 1. A 61-year-old woman progressed from discoid (1971) to systemic (1983) lupus. She was ANA-positive (1:160 homogenous), and treated with azathioprine and prednisone. In February 2004, she was affected by high fever, autoimmune haemolytic anaemia (AIHA) and splenomegaly. A trephine bone marrow biopsy revealed a lymphoma, which was subsequently identified as a non-germinal centre DLBCL stage IV B IPI 5 (high risk). She was treated with the VACOP-B protocol (etoposide, doxorubicin, cyclophosphamide, vincristine, prednisone and bleomycin), and because of no response subsequently with the HAM protocol, consisting of high doses of cytarabine

Table I. A summary of the main clinical and serological results.

Age (12.31.2009)	Gender	Disease	Serology	Lymphoma types	Lymphoma therapy	Outcome
M A M 61 yy; F		SLE ACR 5	ANA homog. 1:160	T-cell rich B Cell lymph.	VACOP-B HAM	CR in both disease R-CHOP x 6 ANA neg
B M 54 yy; F		SLE with s. APS ACR 4	ANA speckl. 1:160 ACA IgM 168 Anti- β 2 GPI IgM 160	DLBCL	R-CHOP x 6	CR of Lymphoma CNS Stroke
A I 51 yy; F		SLE with s. APS ACR 5	ANA speckl. 1:640 LAC pos Anti- β 2 GPI IgM 160 ACA IgG 30	DLBCL	R-CHOP x 6	CR of Lymphoma ANA speckl 1:640
P C 38 yy; F		SLE ACR 5	ANA homog. 1:160	HD NS	ABVD x 4 Mantle radiotherapy	CR of HD ANA homog 1:160
C G 41 yy; F		SLE ACR 4	ANA homog. 1:160 Anti-ds DNA Pos ++ Anti- β 2 GPI IgM > 12	DLBCL	R-CHOP x 6	CR of Lymphoma SLE controlled with therapy

and mitoxantrone. Complete remission was consolidated with 6 courses of R-CHOP (Rituximab, cyclophosphamide, vincristine and doxorubicin), and the patient is currently in CR of both diseases and ANA-negative.

Case 2. A 54-year-old woman was diagnosed with autoimmune vasculitis in 1990. Over 10 years later, the presence of both ANA (speckled) and anti- β 2 glycoprotein antibodies was ascertained, and the diagnosis of secondary antiphospholipid syndrome (APS) was established. Recurrent venous thromboses occurred. The patient was treated with prednisone, hydroxychloroquine, azathioprine and low-molecular weight heparin (LMWH). In September 2004, she developed a diffuse large B cell lymphoma (DLBCL) in stage IV A IPI 4 (high risk), with involvement of bone marrow (BM), lung, liver and spleen. The patient was treated with 6 courses of R-CHOP and achieved CR of the lymphoma, still maintained at the time of this writing. However, in 2007 she developed cerebral thrombosis with persistence of both kinds of antibodies (ANA, aPL and anti- β 2GPI). She is be-

ing currently treated with LMWH and low doses of prednisone.

Case 3. This 51-year-old woman presented with discoid lupus in 1976, and progressed to SLE and secondary APS in 1986 (ANA homogeneous 1:640, anti- β 2 glycoprotein I IgM >160 RU/mL and anti cardiolipin antibodies (ACA) IgG 30 UPL/mL). She was treated with prednisone, hydroxychloroquine and azathioprine. A germinal centre diffuse large B cell lymphoma (DLBCL) was diagnosed in July 2008. The clinical stage was IV A, with involvement of liver and spleen. IPI 3 (high-intermediate risk) She was treated with 6 courses of R-CHOP, and achieved CR with a negative positron emission tomography (PET). However, in September 2009, she suffered from a relapse of lymphoma. Treatment with two courses of R-ICE were followed by a second CR. Autologous haematopoietic stem cells were collected, but the patient declined any form of further therapy and died with overwhelming lymphomatosis 4 months later. SLE was clinically inactive, but ANA of the speckled type persisted at a title

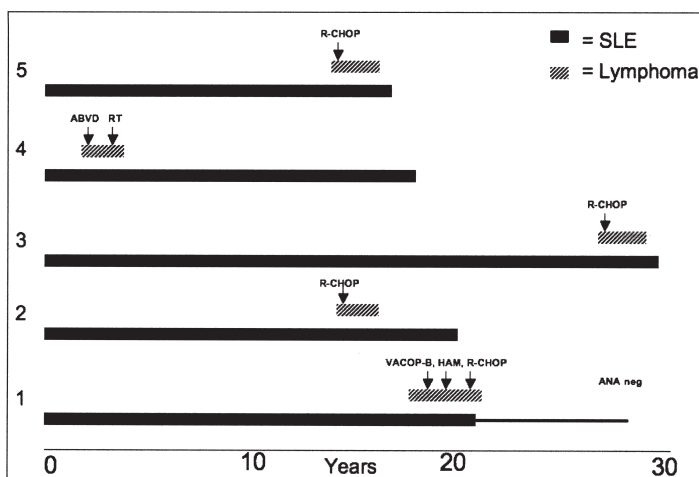


Fig. 1. A synthesis of the patient's course.

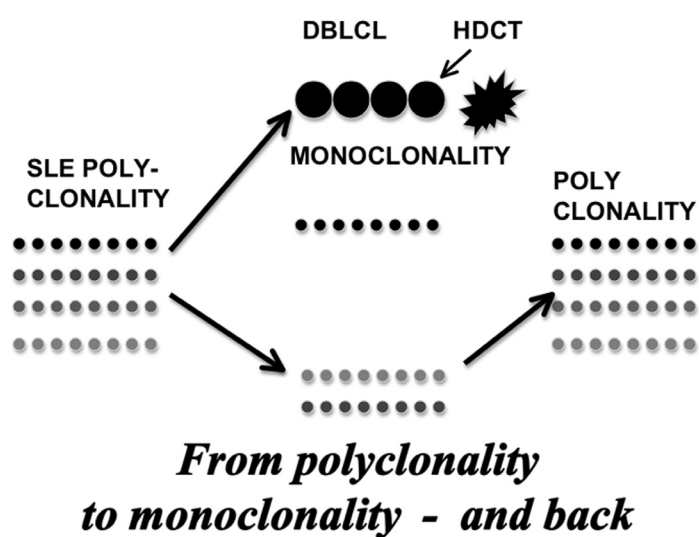


Fig. 2. A theoretical representation of the biological course of these patients, in whom supervened monoclonal development imposed on the original B cell polyclonality, only to return to polyclonal dominance following the cure of lymphoma.

of 1:640 and anti- β 2 glycoprotein and aPL were also present.

Case 4. A 38-year-old woman presented in 1992 with active SLE (fever, arthralgias and exudative pleuritis). She was treated with prednisone, hydroxychloroquine and azathioprine, and attained control of the lupus syndrome with persistent ANA (speckled). In July 1995, she developed Hodgkin's lymphoma, in stage II-A of the nodular sclerosis subtype. She received 4 courses of the ABVD protocol (adriamycin, bleomycin, vincristine and dacarbazine), followed by "mantle" radiotherapy, and went into persistent CR. Lupus symptoms are at present absent, but ANA persist at the titre of 1:160, with an homogeneous pattern.

Case 5. This 41-year-old woman had SLE since 1993, and was treated with prednisone, hydroxychloroquine, azathioprine and methotrexate. In March,

2009, she developed a diffuse large B cell lymphoma (DLBCL) in stage I A, and was treated with 6 courses of R-CHOP, achieving persistent CR. However SLE is still active and symptomatic. ANA are positive (1:320) with a homogenous pattern, and anti- β 2 glycoprotein I antibodies are also strongly positive. She is being currently treated with corticosteroids and ASA.

The course of these cases is shown in Table I and Figure 1.

Discussion

Out of a cohort of 258 patients with SLE, classical (ACR ≥ 4) and incomplete, 6 of them developed malignant lymphomas, 4 of the large B cell type (DLBCL), one of Hodgkin's, nodular sclerosis (NS) type and 1 of lymphocytic lymphoma. This amounts to a 2% incidence, in line with most recent reviews (1-7). Given the increased risk

and incidence of B cell malignant lymphomas in most autoimmune disease (1-5), and more specifically in SLE (6-8), the consensus is that it most probably depends from a combination of incessant overstimulation and defective apoptosis of the "tribulated" (10) B cells, with the additional effects of diminished immunosurveillance and possibly direct oncogenesis caused by many otherwise favourable therapeutic agents (11, 12).

Diffuse large B cell lymphoma (DLBCL) is a highly aggressive lymphomatous type, but its high proliferative rate makes it a suitable target for HDCT. The R-CHOP regimen resulted in the cure of approximately 50% of patients (24). In a recent study, a variety of chemotherapeutic regimens have been utilised with increasing success, and the consensus is that different CT protocols should be performed according to the different cell of origin (25). This strategy has been followed in these patients, and lymphoma-free CRs are comprised between 13 and 172 months. Importantly, the tolerance of HDCT in these lupus patients was excellent. The notion that severe late complications of SLE, such as malignant lymphomas, responded favourably to HDCT with an excellent tolerance, notwithstanding the primary disease, is greatly encouraging, and is in accordance with the results of autologous haematopoietic stem cell transplantation (AHSCT), which are discussed extensively elsewhere (18, 19, 26). Even in the deceased patient the tolerance to chemotherapy was good.

The second objective of this report is to present and discuss the almost paradoxical observation of HDCT being able to cure the lymphomas, but, in 4 patients, not serological and clinical SLE/APS. Only in one case CCR of both diseases was achieved, but to establish a long-term remission prolonged monitoring is necessary. The persistence of autoantibodies after autologous HSCT for SLE is not an infrequent phenomenon (18, 26, 27). The development of ANA with new specificities after autologous HSCT for SLE has been interpreted as a *de novo* development of disease (28). Be that as it may, the presence of au-

toantibodies before any clinical sign and/or symptom of disease have been considered as predictor biomarkers of autoimmune disease in general (29). This chain of events has been clearly demonstrated in SLE (30-32), and also in autoimmune thrombocytopenic purpura (33). In our cases they may be considered as suspicious of potential relapse. Relapses of autoimmune diseases even after the much more powerful procedure of allotransplantation have been reported (34-36). The persistence of long-lived plasmacells (37, 38) has been hypothesized as the cause of these almost paradoxical relapses, but their pathogenesis may be even more complex. The evolution from a polyclonal B cell proliferation to a monoclonal B malignancy, and then back again to the original polyclonality, is depicted in Figure 2.

While mutations in the control pathway are considered to be at the origin of the relentless growth of oncologic disease, relentless stimulation by self-antigens that cannot be cleared from the body has been thought to be at the origin of the multistep pathogenesis of autoimmune disease (39). The "altered self" has been postulated to contribute to the pathogenesis of autoimmunity (40, 41), and key autoantigens have been identified in SLE (42). Among these, nucleosomes have been shown to be critical in SLE (43), and to constitute major autoantigens for both T and B cells (44). Pathogenic autoantibodies are considered to be the primary cause of tissue damage (44), and their production arises by means of extremely complex mechanisms (45, 46). It has been shown that the anti-DNA response has features of an antigen-driven process, in which DNA is the driving antigen (47). While it is widely recognised that a proliferative drive constitutes the link between chronic immune activation and malignant transformation (48), the role of persistent antigenic drive has been clearly demonstrated in organ-specific autoimmune disease. While in the latter category the ablation of the inciting antigens may cancel disease (49), this has not been achieved in systemic autoimmunity. It appears that, while complicating neoplastic disease and

more in general the complete cure of cancer can be obtained by the eradication of the last cancer stem cell (50), the problem is still unresolved in systemic autoimmune disease (51).

In clinical practice, our experience shows that malignant lymphomas complicating SLE may be cured by HDCT, that the patients' tolerance is good, but that resolution of SLE could not be obtained in our cases. The implications of these results on the increasing tendency to treat SLE by means of AHSCT (not to mention the allogeneic procedure), must also be taken into consideration.

References

1. ZINTZARAS E, VOULGARELIS M, MOUTSOPOULOS HM: The risk of lymphoma development in autoimmune diseases: a meta-analysis. *Arch Intern Med* 2005; 165: 2337-44.
2. SMEDBY KE, BAECKLUND E, ASKLING J: Malignant lymphomas in autoimmunity and inflammation: a review of risks, risk factors, and lymphoma characteristics. *Cancer Epidemiol Biomarkers Prev* 2006; 15: 2069-77.
3. HANSEN A, LIPSKY PE, DÖRNER T: B-cell lymphoproliferation in chronic inflammatory rheumatic diseases. *Nat Clin Pract Rheumatol* 2007; 3: 561-9.
4. SMEDBY KE, VAJDIC CM, FALSTER M *et al.*: Autoimmune disorders and risk of non-Hodgkin lymphoma subtypes: a pooled analysis within the InterLymph Consortium. *Blood* 2008; 111: 4029-38.
5. GOLDIN LR, LANDGREN O: Autoimmunity and lymphomagenesis. *Int J Cancer* 2009; 124: 1497-502.
6. BERNATSKY S, JOSEPH L, BOIVIN JF *et al.*: The relationship between cancer and medication exposures in systemic lupus erythematosus: a case-cohort study. *Ann Rheum Dis* 2008; 67: 74-9.
7. KISS E, KOVACS L, SZODORAY P: Malignancies in systemic lupus erythematosus. *Autoimmun Rev* 2010; 9: 195-9.
8. GAYED M, BERNATSKY S, RAMSEY-GOLDMAN R *et al.*: Lupus and cancer. *Lupus* 2009; 18: 479-85.
9. RAMSEY-GOLDMAN R, CLARKE AE: Double trouble: are lupus and malignancy associated? *Lupus* 2001; 10: 388-91.
10. MACKAY IR, ROSE NR: Autoimmunity and lymphoma: tribulations of B cells. *Nat Immunol* 2001; 2: 793-5.
11. TSANG HH, TRENDLE-SMITH NJ, WU AK *et al.*: Diffuse large B-cell lymphoma of the central nervous system in mycophenolate mofetil-treated patients with systemic lupus erythematosus. *Lupus* 2010; 19: 330-3.
12. RIZZI R, CURCI P, DELIA M *et al.*: Spontaneous remission of "methotrexate-associated lymphoproliferative disorders" after discontinuation of immunosuppressive treatment for autoimmune disease. Review of the literature. *Med Oncol* 2009; 26: 1-9.
13. WEYAND CM, GORONZY JJ, KURTIN PJ: Lymphoma in rheumatoid arthritis: an immune system set up for failure. *Arthritis Rheum* 2006; 54: 685-9.
14. ABRAHAMSSON S, MURARO PA: Immune re-education following autologous hematopoietic stem cell transplantation. *Autoimmunity* 2008; 41: 577-84.
15. VAN WIJK F, ROORD ST, VASTERT B *et al.*: Regulatory T cells in autologous stem cell transplantation for autoimmune disease. *Autoimmunity* 2008; 41: 585-91.
16. ZHANG L, BERTUCCI AM, RAMSEY-GOLDMAN R, BURT RK, DATTA SK: Regulatory T cell (Treg) subsets return in patients with refractory lupus following stem cell transplantation, and TGF-beta-producing CD8+ Treg cells are associated with immunological remission of lupus. *J Immunol* 2009; 183: 6346-58.
17. ALEXANDER T, THIEL A, ROSEN O *et al.*: Depletion of autoreactive immunologic memory followed by autologous hematopoietic stem cell transplantation in patients with refractory SLE induces long-term remission through de novo generation of a juvenile and tolerant immune system. *Blood* 2009; 113: 214-23.
18. MARMONT AM, BURT RK: Hematopoietic stem cell transplantation for systemic lupus erythematosus, the antiphospholipid syndrome and bullous skin diseases. *Autoimmunity* 2008; 41: 639-47.
19. FARGE D, LABOPIN M, TYNDALL A *et al.*: Autologous hematopoietic stem cell transplantation (AHSCT) for autoimmune disease: an observational study on 12 years of experience from the European Group for Blood and Marrow Transplantation (EBMT) Working Party on autoimmune diseases. *Haematol* 2010; 95: 284-92.
20. SWAAK TJ, NOSSENT JC: Incomplete lupus erythematosus. In: TSOKOS G, GORDON C, SMOLEN JS: *Systemic lupus erythematosus*. Mosby-Elsevier 2007; 473-81.
21. HOFFMAN RW: Overlap syndrome, mixed connective tissue disease, and undifferentiated connective tissue disease. In: TSOKOS G, GORDON C, SMOLEN JS: *Systemic Lupus Erythematosus*. Mosby-Elsevier 2007; 429-39.
22. SVERDLOW SH, CAMPO E, HARRIS NL *et al.*: WHO Classification of Tumours of Haematopoietic and Lymphoid Tissues (ed 4th). Lyon, France: IARC Press; 2008.
23. CHESON BD, PFISTER B, JUWEID ME *et al.*: Revised response criteria for malignant lymphoma. *J Clin Oncol* 2007; 25: 579-86.
24. ZHANG Q, WANG J, YU Z *et al.*: The effect of biweekly CHOP and standard CHOP in different subgroups of diffuse large B-cell lymphoma. *Onkologie* 2009; 32: 719-23.
25. MURAWSKI N, PFREUNDSCHUH M: Differential therapy for diffuse large B-cell lymphoma with different cells of origin. *Onkologie* 2009; 32: 711-2.
26. JAYNE D, TYNDALL A, MARMONT A *et al.*: Autologous stem cell transplantation for systemic lupus erythematosus. *Lupus* 2004; 13: 168-76.
27. BURT RK, TRAYNOR A, STATKUTE L, BARR WG *et al.*: Nonmyeloablative hematopoietic stem cell transplantation for systemic lupus

- erythematosus. *JAMA* 2006; 295: 527-35.
28. ALEXANDER T, THIEL A, ROSEN O *et al.*: Development of antinuclear antibodies with new specificities in systemic lupus erythematosus after hematopoietic stem cell transplantation suggestive of de novo development of disease rather than lupus reactivation. *Bone Marrow Transplant* 2009; 43 (Suppl. 1): 272 (abstract).
 29. ROSE NR: Predictors of autoimmune disease: autoantibodies and beyond. *Autoimmunity* 2008; 41: 419-28.
 30. SHMERLING RH: Autoantibodies in systemic lupus erythematosus: there before you know it. *N Engl J Med* 2003; 349: 1499-500.
 31. SCOFIELD RH: Autoantibodies as predictors of disease. *Lancet* 2004; 363: 1544-6.
 32. ARBUCKLE MR, MCCLAIN MT, RUBERTONE MV *et al.*: Development of autoantibodies before the clinical onset of systemic lupus erythematosus. *N Engl J Med* 2003; 349: 1526-33.
 33. MARMONT AM: Antinuclear antibody (ANA)-positive thrombocytopenia: primary, but with a difference. *Blood* 2009; 114: 2003-4 (letter).
 34. MCKENDRY RJ, HUEBSCH L, LECLAIR B: Progression of rheumatoid arthritis following bone marrow transplantation. A case report with a 13-year follow-up. *Arthritis Rheum* 1996; 39: 1246-53.
 35. TAPPRICH C, FENK R, SCHNEIDER P, BERNHARDT A, HAAS R, KOBBE G: Early recurrence of rheumatoid arthritis after nonmyeloablative allogeneic blood stem cell transplantation in a patient with multiple myeloma. *Bone Marrow Transplant* 2003; 32: 629-31.
 36. MARMONT AM, GUALANDI F, OCCHINI D *et al.*: Catastrophic relapse of Evans syndrome five years after allogeneic BMT notwithstanding full donor chimerism. Terminal hemolytic-uremic syndrome. *Autoimmunity* 2006; 39: 505-11.
 37. HOYER BF, MANZ RA, RADBRUCH A, HIEPE F: Long-lived plasma cells and their contribution to autoimmunity. *Ann N Y Acad Sci* 2005; 1050: 124-33.
 38. HOYER BF, MOSER K, HAUSER AE *et al.*: Short-lived plasmablasts and long-lived plasma cells contribute to chronic humoral autoimmunity in NZB/W mice. *J Exp Med* 2004; 199: 1577-84.
 39. GOODNOW CC: Multistep pathogenesis of autoimmune disease. *Cell* 2007; 130: 25-35.
 40. EGGLETON P, HAIGH R, WINYARD PG: Consequence of neo-antigenicity of the 'altered self'. *Rheumatology* 2008; 47: 567-71.
 41. DEANE S, MEYERS FJ, GERSHWIN ME: On reversing the persistence of memory. Hematopoietic stem cell transplant for autoimmune disease: in the first ten years. *J Autoimmunity* 2008; 30: 180-96.
 42. RIEMEKAESTEN G, HAHN BH: Key autoantigens in SLE. *Rheumatol* 2005; 44: 975-82.
 43. SCHETT G, STEINER G, SMOLEN JB: Anti-histone antibodies in systemic lupus erythematosus. In: TSOKOS SC, GORDON C, SMOLEN JS: *Systemic Lupus Erythematosus*. Mosby-Elsevier, 2007; 258-64.
 44. BRUNS A, BLÄSS S, HAUSDORF G, BURMEISTER GR, HIEPE F: Nucleosomes are major T and B cell autoantigens in systemic lupus erythematosus. *Arthritis Rheum* 2000; 43: 2307-15.
 45. CROW MK: Developments in the clinical understanding of lupus. *Arthritis Res Ther* 2009; 11: 245.
 46. RAHMAN A, ISENBERG DA: Systemic lupus erythematosus. *N Engl J Med* 2008; 358: 929-39.
 47. PISETSKY DS: Antibodies to DNA. In: TSOKOS GC, GORDON C, SMOLEN JS (Eds): *Systemic Lupus Erythematosus*. Mosby-Elsevier, 2007; 225-32.
 48. FIETTA P, DELSANTE G, QUAINI F: Hematologic manifestations of connective autoimmune diseases. *Clin Exp Rheumatol* 2009; 27: 140-54.
 49. CHIOVATO L, LATROFA F, BRAVERMAN LE *et al.*: Disappearance of humoral thyroid autoimmunity after complete removal of thyroid antigens. *Ann Intern Med* 2003; 130: 346-51.
 50. DINGLI D, MICHOR F: Successful therapy must eradicate cancer stem cells. *Stem Cells* 2006; 24: 2603-10.
 51. MARMONT AM: Treating autoimmune disease: is stem cell therapy the future? *Int J Clin Rheumatol* 2009; 4: 395-408.