

Sacroileitis and pericarditis: atypical presentation of tumour necrosis factor receptor-associated periodic syndrome and response to etanercept therapy

Sirs,

Tumour necrosis factor (TNF)- α receptor-associated periodic syndrome (TRAPS) is a dominantly inherited disease caused by missense mutations in the *TNFRSF1A* gene which encodes for the TNF- α receptor (1). TRAPS is characterised by attacks of fever, polyserositis, arthralgia, myalgia, skin rash, periorbital edema and/or conjunctivitis; up to 25% of patients may develop systemic amyloidosis (2).

Arthralgia occurs during the attacks in about two-thirds of patients, in a monoarticular or oligoarticular distribution, and the main involved joints are the knees, shoulders, elbows, hips, fingers, wrists, and temporomandibular joints. Arthritis is less common, but joint effusion may occur. Sacroiliac involvement has been described only once to date (3). Serosal inflammation is common in the form of polyserositis (4), but sole involvement of pericardium has only recently been described (5).

We report an unusual TRAPS phenotype, characterized by the association of sacroileitis and pericarditis, in absence of the most typical clinical signs of TRAPS.

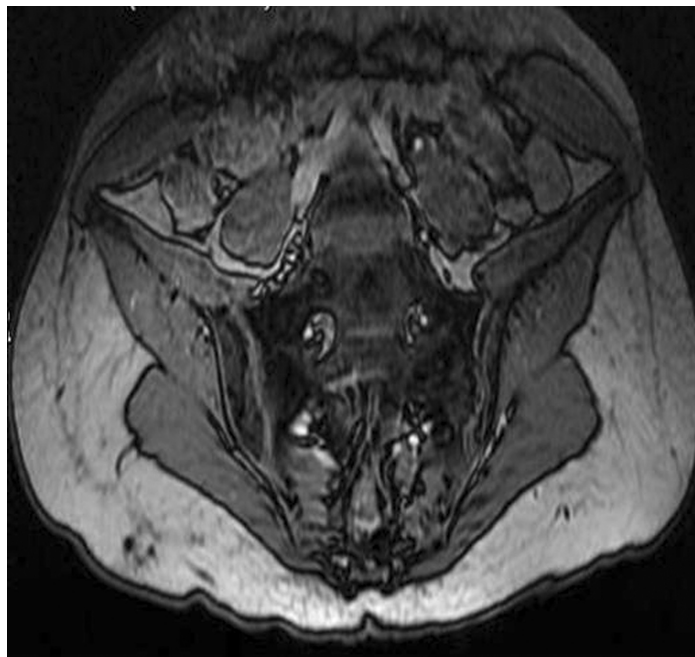
A 27-year-old Caucasian female was admitted to our Unit for high-grade fever over the previous ten days, lower back pain and thoracic pain. Past medical history indicated three previous similar episodes over the previous six months. All fever episodes lasted more than 7 days. Laboratory investigations during admission showed elevation of ESR (78 mm/hour, n.v. <35), C-reactive protein (3.56 mg/dl, n.v. <0.5), white blood cell count $14.29 \times 10^3/\text{mm}^3$ and serum amyloid A levels (SAA) (98 mg/dl, n.v. <10). Kidney and liver function were normal. Echocardiography was performed and revealed a mild-to-moderate pericardial effusion.

In order to better evaluate the low back pain, contrast-enhanced magnetic resonance imaging (MRI) of sacroiliac joints was performed. MRI showed an increased tracer uptake bilaterally, over both sacroiliac joints and mild irregularity of both joint margins (Fig. 1).

The patient was not affected with psoriasis, nor had any family history of psoriasis, and did not present signs of inflammatory bowel diseases. There was also no evidence of previous urinary tract or intestinal infections. HLA B27 and B51 alleles were both negative.

Due to the prolonged fever attacks the patient's DNA was analysed, after written consent had been obtained, for mutations in the *TNFRSF1A* gene (exons 2,3,4,6) and a heterozygous low penetrance R92Q mutation was found. She was diagnosed with

Fig. 1. Contrast-enhanced magnetic resonance imaging showing an increased tracer uptake over both sacroiliac joints.



TRAPS and started treatment with prednisone 1 mg/kg/daily. After two symptom-free months, the patient had another similar febrile attack during corticosteroid treatment. The fever resolved within 2 weeks. Prednisone did not prevent the recurrence of fever and did not alter its duration, and the attack was not milder than the previous ones. Furthermore SAA was highly increased during prednisone treatment, also during the symptom free interval.

Corticosteroid treatment was then interrupted and the patient started etanercept 25 mg twice weekly. Anti-TNF- α therapy brought about a complete resolution of low back pain and of thoracic pain within 1 month, and SAA levels normalised within few weeks after initiation of treatment. At the 6-month-follow-up, the patient was still free of fever attacks and is continuing treatment with etanercept.

The TRAPS phenotype is steadily expanding and since the discovery of *TNFRSF1A*, several studies have suggested that low-penetrance *TNFRSF1A* variants might contribute to atypical inflammatory responses in TRAPS, including cardiac diseases (3, 5).

The low-penetrance R92Q mutation has also been detected in 1.04% of healthy Irish and North American control populations (6), although its increased frequency (3.3%) among patients with periodic fever suggest that this is a low penetrance mutation rather than benign polymorphism (6); this finding has also been supported by functional studies of *TNFRSF1A* (6). Of note, it has been described that the R92Q mutation in *TNFRSF1A* can coexist with mutations in *MEFV*, the gene responsible for familial Mediterranean fever (7); in such cases the clinical phenotype can be modified. In our patient *MEFV* genotyping was performed and no mutations were found. However it is

stated that patients with R92Q present less typical clinical manifestations (6).

Isolated pericardial involvement in patients with TRAPS is rare, but has been recently described (5). Dodé C described two patients, respectively carrying the R92Q and the P46L low-penetrance mutations, who presented with periodic fever episodes and pericarditis as the sole manifestations (5). Sacroileitis has previously been described in association with TRAPS only once, in association with myocarditis, both showing a reversible course with methylprednisolone administration. Trost *et al.* reported this unusual association in a 9-year-old African American male with a recurrent febrile illness, carrying the low penetrance heterozygous P46L mutation in *TNFRSF1A* (3). Although the coexistence of R92Q mutation with sacroileitis may be merely coincidental, in our patient the most common causes of sacroileitis were excluded. Furthermore, the recurrent fever episodes, the prolonged duration of fever and the persistently elevated SAA levels even during symptom free intervals consequent to a chronic subclinical inflammation (8), supported a diagnosis of TRAPS. Our report suggests that the phenotype of TRAPS may be more variable than initially thought, and also adds sacroiliac joint involvement and pericarditis to its clinical spectrum.

In conclusion, we suggest that the TRAPS should be kept in mind in the differential diagnosis of spondyloarthropathies and of pericarditis, especially when accompanied by fever.

L. CANTARINI¹, MD*
O.M. LUCHERINI², PhD*
R. CIMAZ³, MD
C.T. BALDARI², PhD
F. LAGHI PASINI⁴, MD
M. GALEAZZI¹, MD

¹Interdepartmental Research Center of Systemic Autoimmune and Autoinflammatory Diseases, Unit of Rheumatology, and ⁴Unit of Immunological Sciences, Policlinico Le Scotte, University of Siena, Siena, Italy; ²Department of Evolutionary Biology, University of Siena, Siena, Italy; ³Department of Paediatrics, Rheumatology Unit, Anna Meyer Children's Hospital and University of Florence, Italy;

*These authors contributed equally to this study.

Address correspondence and reprint requests to: Luca Cantarini, Department of Clinical Medicine and Immunological Sciences, Unit of Rheumatology, Policlinico "Le Scotte", University of Siena, Viale Bracci 1, 53100 Siena, Italy.
E-mail: cantariniluca@hotmail.com

Competing interests: none declared.

References

1. MCDERMOTT MF, AKSENTIJEVICH I, GALON J *et al*: Germline mutations in the extracellular domains of the 55 kDa TNF receptor, TNFR1, define a family of dominantly inherited autoinflammatory syndromes. *Cell* 1999; 97:133-44.
2. AGANNA E, HAMMOND L, HAWKINS PN *et al*: Heterogeneity among patients with tumor necrosis factor receptor-associated periodic syndrome phenotypes. *Arthritis Rheum* 2003; 48:2632-44.
3. TROST S, ROSÉ CD: Myocarditis and sacroileitis: 2 previously unrecognized manifestations of tumor necrosis factor receptor associated periodic syndrome. *J Rheumatol* 2005; 32: 175-7.
4. CENTOLA M, AKSENTIJEVICH I, KASTNER DL: The hereditary periodic fever syndromes: molecular analysis of a new family of inflammatory diseases. *Hum Mol Genet* 1998; 7: 1581-8.
5. DODÉ C, ANDRÉ M, BIENVENU T *et al*: FRENCH HEREDITARY RECURRENT INFLAMMATORY DISORDER STUDY GROUP. The enlarging clinical, genetic, and population spectrum of tumor necrosis factor receptor-associated periodic syndrome. *Arthritis Rheum* 2002; 46: 2181-8.
6. AKSENTIJEVICH I, GALON J, SOARES M *et al*: The tumor-necrosis-factor receptor-associated periodic syndrome: new mutations in TNFRSF1A, ancestral origins, genotype-phenotype studies, and evidence for further genetic heterogeneity of periodic fevers. *Am J Hum Genet* 2001; 69: 301-14.
7. GRANEL B, SERRATRICE J, DODÉ C, GRATEAU G, DISDIER P, WEILLER PJ: Overlap syndrome between FMF and TRAPS in a patient carrying MEFV and TNFRSF1A mutations. *Clin Exp Rheumatol* 2007; 25 (Suppl. 45): S93-5.
8. HULL KM, DREWE E, AKSENTIJEVICH I *et al*: The TNF receptor-associated periodic syndrome (TRAPS): emerging concepts of an autoinflammatory disorder. *Medicine* (Baltimore) 2002; 81: 349-68.