

Ulnar neuropathy at the elbow: how frequent is the idiopathic form?

An ultrasonographic study in a cohort of patients

G. Filippou¹, M. Mondelli², G. Greco³, I. Bertoldi¹, B. Frediani¹,
M. Galeazzi¹, F. Giannini³

¹Department of Clinical Medicine and Immunology, Rheumatology Unit, University of Siena;
²Electromiography service, Local Health Authority (ASL) 7 Siena; ³Department of Neurosciences,
University of Siena, Siena, Italy.

Abstract

Objective

Ulnar neuropathy at the elbow (UNE) is the second most frequent focal neuropathy of the arm. The aim of our study was to establish the frequency of anatomical changes of the cubital tunnel capable of causing UNE.

Methods

Ninety-one consecutive patients affected by UNE, as established by neurophysiological studies, were enrolled in the study. All patients underwent ultrasonographic examination of the elbow, paying particular attention to the cubital tunnel, which was studied with either static or dynamic scans.

Result

Fifty-four of the 91 patients (59.3%) had at least one anatomical alteration of the cubital tunnel. The changes observed in our patients were: subluxation of the ulnar nerve (18.7%), luxation of the ulnar nerve (9.9%), presence of osteophytes (6.6%), presence of accessory muscle (8.8%), articular ganglion (1.1%), post-traumatic lesions (3.3%), presence of osseous fragments (1.1%).

Conclusions

A possible cause of ulnar nerve entrapment at the elbow was found in more than half of the patients. Joint ultrasonography is indispensable for the identification of such alterations as it allows for both static and dynamic evaluation of the ulnar nerve.

Key words

Neuropathy, ulnar, ultrasonography, UNE

Georgios Filippou, MD, PhD
Mauro Mondelli, MD
Giuseppe Greco, MD, PhD
Ilaria Bertoldi, MD
Bruno Frediani, MD, Professor
Mauro Galeazzi, MD, Professor
Fabio Giannini, MD, Professor

Please address correspondence and reprints requests to:

Dr Georgios Filippou,
Department of Clinical Medicine and Immunology, Rheumatology Unit,
Policlinico Santa Maria alle Scotte,
Viale Bracci,
53100 Siena, Italy.

E-mail: g_filippou@virgilio.it

Received on June 28, 2009; accepted in revised form on October 12, 2009.

© Copyright CLINICAL AND EXPERIMENTAL RHEUMATOLOGY 2010.

Introduction

Ulnar neuropathy at the elbow (UNE) is the second most frequent entrapment neuropathy of the upper limb after carpal tunnel syndrome (CTS). The clinical picture is characterised by paraesthesia in the fourth and fifth fingers, which often also affects the lateral part of the palm and the back of the hand, pain in the elbow and difficulty in performing precise movements and managing small objects. The latter phases are characterised by atrophy of all the intrinsic muscles of the hand, with the exception of the thenar muscles which are innervated by the median nerve. Differential diagnosis includes ulnar neuropathy at the wrist (Guyon's canal syndrome), C8-T1 radiculopathy, brachial plexus dysfunction involving the primary lower trunk, neurogenic thoracic outlet syndrome and the initial phases of amyotrophic lateral sclerosis or other motor neurone diseases, although the latter two cases do not usually involve sensory disturbance.

Clinicians use electromyography (EMG) and nerve conduction studies to confirm a diagnosis of UNE, although the sensitivity of these methods ranges between 37% and 86% (1). Imaging techniques (MRI and ultrasonography) can be of use in the study of UNE as they can detect possible causes of nerve entrapment. Their utility as diagnostic tools is still under investigation.

Musculoskeletal ultrasonography has become important in the diagnosis of carpal tunnel syndrome by even in the initial phases as demonstrated in previous studies (2, 3), and can play an important role in the decision of when to operate and in post-surgery follow-up (4). However, the literature published to date includes few studies on the usefulness of ultrasonography in UNE (7-14). The aim of this study was to identify anatomical anomalies of the elbow using ultrasonography in a cohort of patients affected by "definite" UNE.

Patients and methods

The study population consisted of all subjects recruited consecutively between 1 January and 31 December 2008 at the musculoskeletal ultrasound service of the Rheumatology Unit (Univer-

sity of Siena). Only patients affected by "definite" UNE diagnosed at the EMG clinic of the Department of Neuroscience (University of Siena) or at the Electromyography service of Local Health Authority no.7 of Siena were recruited. Subjects diagnosed with UNE by other EMG clinics were excluded from the study. The diagnosis of "definite" UNE was made by neurophysiologists based on symptoms, clinical examination, and electrodiagnostic results demonstrating slowing of the motor conduction velocity of the ulnar nerve in the above to below elbow segment, as recommended by the American Association of Electrodiagnostic Medicine (1, 20).

Details of the symptoms and the electrophysiological methods employed have already been published elsewhere (14).

Ultrasound studies were performed using a linear probe (10 MHz; Esaote Technos MP). The whole of the ulnar nerve was examined along its passage through the cubital tunnel, from 2cm proximal to its entrance into the tunnel to 2 cm after it passes beneath the aponeurosis of the flexor carpi ulnaris muscle. Both static and dynamic transverse and longitudinal scans were performed. Particular attention was paid to the localisation of the nerve and its relationships with the surrounding structures during flexion and extension of the elbow. The affected side at EMG or the most compromised side in the case of bilateral UNE was included in the study.

Three variations were considered in evaluating the position of the ulnar nerve: normal, when the nerve remains in the cubital groove through a full arc of elbow flexion; subluxation, when the nerve passes on top of the medial epicondyle of the humerus (at any degree of flexion), but does luxate over it; luxation, when the nerve luxates over the medial epicondyle of the humerus at any degree of flexion.

The presence of articular ganglions, osteophytes and osseous fragments (in cases of post-traumatic UNE) was also evaluated. Particular attention was paid to the evaluation of accessory muscles at the cubital groove. In fact, the medial head of the triceps muscle may enter the groove during elbow flexion and

Competing interests: none declared.

mimic an accessory muscle. Longitudinal scans were used in these cases to differentiate the two conditions: the medial head of the triceps appears, in the longitudinal scan, as a hypo-anechoic structure that is clearly attached to the triceps muscle when followed proximally with the probe; when we found an “independent” muscle of small dimensions above the ulnar nerve and in the context of the Osborne band that was not attached to the triceps brachii, we defined it as an accessory anconeus-epitrochlearis muscle.

Results

During the study period 91 patients (42 females) with a median age of 49 years (range 15–81) were recruited. An anatomical anomaly was identified in 54 of the 91 patients studied (59.3%) and was a possible cause of the neuropathy. The alterations found were (in order of frequency – see Table I): subluxation of the ulnar nerve, luxation of the ulnar nerve, the presence of osteophytes, the presence of accessory muscle, articular cyst, post-traumatic lesions, presence of osseous fragments (Fig. 1).

Among the post-traumatic cases of UNE, one was due to a cut just above the entrance of the nerve into the cubital tunnel, which resulted in the formation of adhesions and entrapment of the nerve. The other two cases were trauma-related contusions. In all cases, ultrasonographic examination revealed focal thickening of the ulnar nerve in the region of the trauma, without other anatomical alterations of the cubital tunnel.

Discussion

Few studies have been performed on the diagnostic utility of joint ultrasonography in UNE. The main objective of these studies was to define an ultrasound parameter for the diagnosis of UNE. The parameters proposed in the literature so far include the diameter of the nerve measured by longitudinal or axial scans (7), the area of the nerve calculated as a product of the diameters (11), the length of the thickened segment of the nerve (9), the ratio between the diameter of the nerve at the entrance into and exit from the cubital canal (9)

Table I. Frequency of the anatomic alterations found in our study population.

	Sub-luxation	Luxation	Osteophytes	Accessory Muscle	Articular Cyst	Trauma	Osseous Fragment	More than one	Total (91 pts)
Number	17	9	6	8	1	3	1	9	54
Percentage	18.7	9.9	6.6	8.8	1.1	3.3	1.1	9.9	59.3

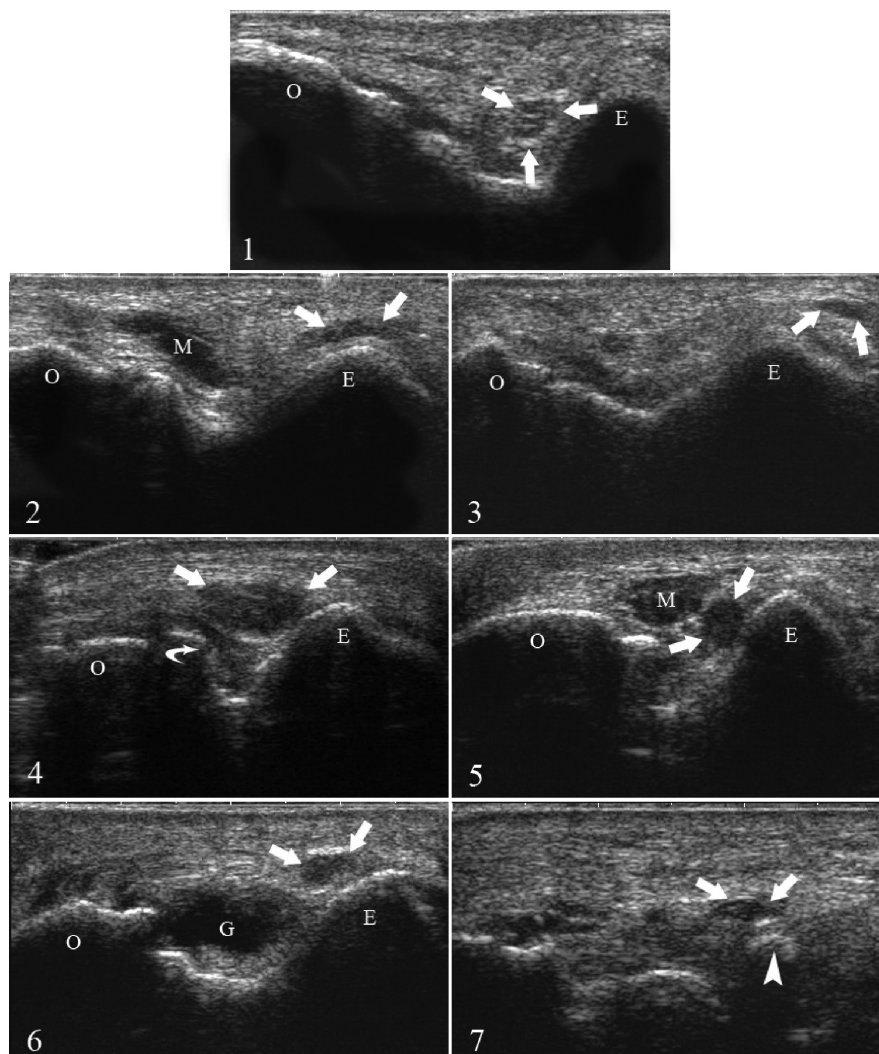


Fig. 1. Transverse scan of the cubital tunnel (arrows: ulnar nerve, O: olecranon, E: medial epicondyle, M: muscle, G: articular ganglion, curved arrow: osteophyte, arrowhead: small osseous fragment).

1. Normal aspect. Note the position of the ulnar nerve and the absence of other anatomical structures, such as muscles or tendons, inside the tunnel.
2. Ulnar nerve subluxation: the ulnar nerve is located on top of the medial epicondyle. Note the elongated form of the nerve as it is stretched over the bone.
3. Ulnar nerve luxation: the ulnar nerve is located on the internal side of the medial epicondyle.
4. Humeral osteophytosis (curved arrow): the osteophyte reduces the depth of the tunnel, causing compression and medial dislocation of the ulnar nerve. Note the enlargement of the ulnar nerve due to compression at this level.
5. Accessory muscle (M): an accessory muscle causes the compression of the ulnar nerve, which appears slightly enlarged and hypoechoic (at contralateral examination). It may be difficult to differentiate between an accessory muscle and a hypertrophic tricipital muscle (Fig 1-2). Comparative examination of the two sides (although accessory muscles are sometimes monolateral), the patient's history (type of activity and dominant hand) and a careful scan that follows the muscle proximally should be of help in defining diagnosis.
6. Articular ganglion: an articular ganglion causing medial dislocation of the ulnar nerve.
7. Osseous fragment: presence of a small osseous fragment in a patient with a history of elbow fracture, causing compression of the ulnar nerve at the tunnel outlet. In this case, the ulnar nerve appears thinned, probably because of a concomitant lesion due to continuous friction.

and, lastly, the cross section area (CSA) of the nerve at various points of the cubital tunnel (10, 13, 14).

The data in the literature are conflicting and there is a lack of agreement regarding which of the ultrasonographic parameters is most useful. Comparison of the studies is hindered by the fact that they vary in the recruitment of patients, the way in which the diagnosis of UNE was reached, the severity of the neuropathy and the ultrasonographic measurements. A previous paper of ours (14) included a summary of the data present in the literature concerning ultrasonographic studies in UNE.

At the elbow, the ulnar nerve passes in front of the medial head of the triceps brachii and under the arcade of Struthers, then runs into a bony groove on the humerus (the cubital tunnel) and around the posterior side of the medial epicondyle of the humerus. The proximal edge of the roof of the cubital tunnel is superficially closed by several fibrous bands of about 4mm in width, extending from the medial epicondyle to the olecranon and perpendicular to the flexor carpi ulnaris aponeurosis: these bands are known as the cubital tunnel retinaculum (CTR) (15). Osborne was the first to correlate this retinaculum with compression of the ulnar nerve, thus it is also known as the "Osborne band" (16). When it exits the tunnel, the nerve passes deep into the robust aponeurosis that unites the two heads (humeral and ulnar) of the flexor carpi ulnaris (FCU) muscle. The sites in which the ulnar nerve most frequently becomes entrapped are the cubital tunnel and the aponeurosis that unites the two heads of the FCU, while entrapment at the arcade of Struthers and the floor of the tunnel below the FCU is less frequent.

As part of a cadaver study, O'Driscoll described possible anatomical variations of the Osborne band, dividing them into four types (15). In type 0 the retinaculum was absent; in type Ia it was present and appeared lax in extension and taut in full flexion; in type Ib the retinaculum was present but appeared taut at moderate degrees of flexion (between 90° and 120°), and in type II the retinaculum was replaced by accessory

anconeus epitrochlearis muscle. According to O'Driscoll and colleagues, types 0, Ib and II could cause ulnar neuropathy, but via different mechanisms. In fact the authors observed instability of the nerve in the first type, while in the latter two types they witnessed compression within the canal.

In the presence of symptoms compatible with a diagnosis of UNE, it is impossible to distinguish between the various sites of entrapment of the nerve clinically. Electrophysiology is of little help and the various electrodiagnostic methods used (including the inching technique) provide contrasting results concerning identification of the exact site of entrapment, although imaging techniques may be useful in this context.

Our ultrasonographic results demonstrate the presence of at least one anatomical alteration in 59.3% of patients with UNE, which could represent the cause of the neuropathy. The high percentage of cases we encountered with luxation and/or subluxation of the nerve (28%, almost one third of our patients) is in line with the observation that the fibres of the ligament that forms the roof of the tunnel are not always effective in constraining the nerve in the ulnar tunnel, rendering it less stable and therefore more susceptible to direct traumatic insults.

One of the most studied causes of ulnar nerve luxation is snapping (dislocation) of the medial head of the triceps over the medial epicondyle. In some cases the medial head of the triceps enters in the cubital tunnel, increasing the pressure inside it. This can result in one of three conditions: 1) the fibres that close the cubital tunnel manage to constrain the nerve, 2) the nerve luxates, slipping over the medial epicondyle, causing a snapping sensation, 3) the medial head of the triceps follows the luxation of the ulnar nerve, also slipping over the medial epicondyle and causing a second snap. While the first case will result in compression of the ulnar nerve, the second may cause a lesion due to chronic friction of the nerve against the medial epicondyle. In fact it seems that ulnar nerve luxation is determined by the ability of the retinaculum to constrain the structures of the cubital tunnel, rather

than by the pressure exerted by the muscle, also bearing in mind that some cases of instability are unrelated to the luxation of the triceps. In effect, O'Driscoll and colleagues (15) found that the cubital tunnel retinaculum (CTR) can be completely absent, while Dellon (17) demonstrated the presence of varying degrees of instability in the elbows of 25% of cadavers. These data are in line with our results, and our slightly higher percentage of instability (28%) may be explained by the fact that our study only dealt with patients with ulnar nerve neuropathy, so a higher proportion of cases of instability was to be expected.

Among the other causes of UNE we found the presence of articular cysts, secondary of articular effusion, and osteophytes in 7.7% of the patients. In our cohort we did not have patients with arthritis but we can expect a higher prevalence of articular effusion in these patients and secondary a higher prevalence of UNE. In this case local treatment with steroids could resolve the clinical picture, whether articular and neurological. In the case of osteoarthritis even if a surgical approach is necessary, US can provide valuable informations thanks to dynamic scanning that permits to define the dimensions of the osteophytes and the position of the nerve.

In the 40.7% of cases in which an anatomical cause of compression was not found, the neuropathy may have been caused by microtrauma. Unfortunately, the type of trauma may not always be revealed by the patient's medical history as, at least in theory, repeated flexion-extension, even unrelated to sport or work, may be sufficient to provoke neural damage. Richardson and Jamieson (18), for example, demonstrated that UNE is more frequent in heavy smokers, possibly due to the repeated flexion-extension movement of the arm, causing a chronic microtrauma to the nerve. Such movements determine a reduction in the diameter of the cubital tunnel, with a consequent increase in intratunnel pressure and continuous stretching and contracting of the nerve. Indeed, it has been demonstrated that UNE is a "repetitive strain injury" (19), as it is much more common in subjects who perform repetitive tasks involving

forced or very frequent extension of the elbow.

One bias of our study is the lack of a control group, as cases of ulnar nerve instability have also been described in asymptomatic patients. This renders the ultrasonographic diagnosis of UNE very difficult as the anatomic anomaly identified may not necessarily be related to entrapment of the nerve. The thickening and hypoechogenicity of the nerve that frequently accompany anatomic alteration in these cases may also not be sufficient: we found in a previous study that this parameter has a sensitivity of 55% for the diagnosis of UNE (14). A recent study by Thoirs *et al.* demonstrated that age, weight, BMI (body mass index), sex and position of the elbow are confounding factors for the evaluation of the ulnar nerve at the elbow and that measurements can only be considered reliable following correction of these factors (21).

Despite these reservations, joint ultrasonography is capable of accurately evaluating the relationship of nerves with surrounding structures, also through the use of dynamic movements, and of highlighting any anatomical abnormalities of the elbow that could cause a neuropathy. Thus, with the help of ultrasonography, many forms that are diagnosed as idiopathic could be classified as secondary to anatomical alterations of the cubital tunnel, consequently changing therapeutic decisions.

In conclusion, ultrasonography is indispensable for correct diagnostic identification of ulnar neuropathy at the elbow and subsequent therapeutic orientation, as approximately 3 out of 5 cases of UNE could be secondary to anatomical

alterations of the elbow. In addition to the well known advantages of US with respect to other imaging techniques (repeatability, speed of performance, innocuousness), US offers the possibility of using dynamic manoeuvres without sacrificing excellent definition of soft tissues, the osseous structures of the cubital tunnel and the nerve itself. Dynamic scanning of the cubital groove should always be carried out when a US examination of the elbow is performed.

References

1. Practice parameter for electrodiagnostic studies in ulnar neuropathy at the elbow: summary statement. American Association of Electrodiagnostic Medicine, American Academy of Physical Medicine and Rehabilitation, American Academy of Neurology. *Arch Phys Med Rehabil* 1999; 80: 357-59.
2. MONDELLI M, FILIPPOU G, GALLO A, FREDIANI B: Diagnostic utility of ultrasonography versus nerve conduction studies in mild carpal tunnel syndrome. *Arthritis Rheum* 2008; 59: 357-66.
3. NARANJO A, OJEDA S, MENDOZA D, FRANCISCO F, QUEVEDO JC, ERAUSQUIN C: What is the diagnostic value of ultrasonography compared to physical evaluation in patients with idiopathic carpal tunnel syndrome? *Clin Exp Rheumatol* 2007; 25: 853-9.
4. MONDELLI M, FILIPPOU G, ARETINI A, FREDIANI B, REALE F: Ultrasonography before and after surgery in carpal tunnel syndrome and relationship with clinical and electrophysiological findings. A new outcome predictor? *Scand J Rheumatol* 2008; 37: 219-24.
5. PARK GY, KIM JM, LEE SM: The ultrasonographic and electrodiagnostic findings of ulnar neuropathy at the elbow. *Arch Phys Med Rehabil* 2004; 85: 1000-5.
6. NAKAMICHI K, TACHIBANA S, KITAJIMA I: Ultrasonography in the diagnosis of ulnar tunnel syndrome caused by an occult ganglion. *J Hand Surg (Br)* 2000; 25: 503-4.
7. BEEKMAN R, SCHOEMAKER MC, VAN DER PLAS JP *et al.*: Diagnostic value of high-resolution sonography in ulnar neuropathy at the elbow. *Neurology* 2004; 62: 767-73.
8. WIESLER ER, CHLOROS GD, CARTWRIGHT MS, SHIN HW, WALKER FO: Ultrasound in the diagnosis of ulnar neuropathy at the cubital tunnel. *J Hand Surg* 2006; 31A: 1088-93.
9. YOON JS, KIM BJ, KIM SJ *et al.*: Ultrasonographic measurements in cubital tunnel syndrome. *Muscle Nerve* 2007; 36: 853-5.
10. OKAMOTO M, ABE M, SHIRAI H, UEDA N: Diagnostic ultrasonography of the ulnar nerve in cubital tunnel syndrome. *J Hand Surg (Br)* 2000; 25: 499-502.
11. JACOBSON JA, JEBSON PJ, JEFFERS AW, FESSELL DP, HAYES CW: Ulnar nerve dislocation and snapping triceps syndrome: diagnosis with dynamic sonography- report of three cases. *Radiology* 2001; 220: 601-5.
12. CHIOU HJ, CHOU YH, CHENG SP *et al.*: Cubital tunnel syndrome: diagnosis by high-resolution ultrasonography. *J Ultrasound Med* 1998; 17: 643-8.
13. YOON JS, HONG SJ, KIM BJ *et al.*: Ulnar nerve and cubital tunnel ultrasound in ulnar neuropathy at the elbow. *Arch Phys Med Rehabil* 2008; 89: 887-9.
14. MONDELLI M, FILIPPOU G, FREDIANI B, ARETINI A: Ultrasonography in ulnar neuropathy at the elbow: relationships to clinical and electrophysiological findings. *Neurophysiol Clin* 2008; 38: 217-26.
15. O'DRISCOLL SW, HORIE E, CARMICHAEL SW, MORREY BF: The cubital tunnel and ulnar neuropathy. *J Bone Joint Surg (Br)* 1991; 73: 613-7.
16. OSBORNE GV: The surgical treatment of tardy ulnar neuritis. *J Bone Joint Surg (Br)* 1957; 39B: 782.
17. DELLON AL: Musculotendinous variations about the medial humeral epicondyle. *J Hand Surg (Br)* 1986; 11: 175-81.
18. RICHARDSON JK, JAMIESON SC: Cigarette smoking and ulnar mononeuropathy at the elbow. *Am J Phys Med Rehabil* 2004; 83: 730-4.
19. VAN TULDER M, KOES B: Repetitive strain injury. *Lancet* 2007; 369: 1815-22.
20. MONDELLI M, GIANNINI F, BALLERINI M, GINANNESCHI F, MARTORELLI E: Incidence of ulnar neuropathy at the elbow in the province of Siena (Italy). *J Neurol Sci* 2005; 234: 5-10.
21. THOIRS K, WILLIAMS MA, PHILLIPS M: Ultrasonographic measurements of the ulnar nerve at the elbow: role of confounders. *J Ultrasound Med* 2008; 27: 737-43.