

Tenofovir-induced osteomalacia

D.P. Wanner, A. Tyndall,
U.A. Walker

Department of Rheumatology,
Basle University, Basel, Switzerland,

Daniel P. Wanner, MD

Alan Tyndall, MD

Ulrich A. Walker, MD

Please address correspondence to:

Ulrich A. Walker, MD,

Department of Rheumatology,

Basel University, Basel, Switzerland.

E-mail: ulrich.walker@fjps-basel.ch

Received on February 6, 2009; accepted in
revised form on May 26, 2009.

© Copyright CLINICAL AND

EXPERIMENTAL RHEUMATOLOGY 2009.

Key words: Osteomalacia, tenofovir,
Fanconi syndrome, mitochondrial
toxicity.

ABSTRACT

We present an HIV-infected woman in whom antiretroviral treatment with tenofovir disoproxil fumarate (TDF) induced severe skeletal pain, synovial effusions and multiple fractures secondary to a Fanconi syndrome with hypophosphatemia and osteomalacia. TDF interferes with the replication of mitochondrial DNA in the proximal tubules of the kidney, which can explain the delayed onset of this form of renal phosphate loss. Nephrotoxicity had been precipitated by cotreatment with lopinavir/r, an HIV protease inhibitor which increases tenofovir serum levels and inhibits the tubular multidrug resistance protein 4, which is responsible for the efflux of tenofovir from tubular cells.

Awareness is needed to link the typically prolonged onset of clinical symptoms with TDF exposure and then establish the correct diagnosis.

Introduction

HIV-infected patients often receive medication for lifetime in order to inhibit viral replication. Some of the antiretrovirals used are nucleoside or nucleotide analogues which have been designed to inhibit HIV-reverse transcriptase. Side effects from the prolonged use of this class of HIV-inhibitors may arise from the fact that they also interfere with the function of polymerase- γ , a human polymerase required for the replication of mitochondrial DNA (1).

We present a case of severe whole body pain with multiple microfractures, synovial effusions, renal dysfunction and hypophosphatemia in an HIV-infected patient. The symptoms were due to osteomalacia secondary to the prolonged use of tenofovir disoproxil fumarate (TDF), a nucleotide analogue HIV-reverse transcriptase inhibitor. We would like to raise awareness of this so far rare complication of TDF administration and point out that skeletal pain may be an increasingly frequent side effect because it may be triggered when TDF is given in combination with ritonavir-boosted lopinavir (lopinavir/r) an HIV-protease inhibitor now commonly used.

Case report

In July 2007, a 62-year-old white woman was referred to our rheumatology service with a 6-month history of progressive and immobilizing pain involving the back, knees and ankles. Her pain was exacerbated upon exercise and permitted ambulation only with the aid of a cane. Her previous medical history was remarkable for an episode of acute renal failure due to exsiccosis at 53 years of age. HIV infection was diagnosed at 54 years of age (CDC stage B2), shortly prior to the institution of antiretroviral therapy. Following HIV treatment with didanosine, stavudine and nelfinavir, the patient had developed side effects such as lipoatrophy and polyneuropathy, prompting a switch of antiretrovirals to abacavir, didanosine and lopinavir/r in 2005. In July 2006, didanosine had been exchanged for TDF (300 mg every 72 hours).

On physical examination the patient presented with cachexia (BMI 14.9 kg/m²). There was pain upon compression of the rib cage and the pelvis and effusions in both ankle joints, but no other signs of arthritis.

The laboratory revealed moderate anemia (Hb 11.2 g/dL) and severely impaired renal function (Table I). There was considerable proteinuria (1.6 g/L), predominantly of tubular origin. Serum organic phosphate was low and alkaline phosphatase high but 25-OH-vitamin D was within normal limits. The ankle joint fluid contained 850 cells/ μ L and no crystals or bacteria. Antinuclear antibodies were negative. There was no detectable HIV replication; CD4⁺ cells were 674 per μ L.

Radiographs of the skeleton were essentially normal. Skeletal scintigraphy using ^{99m}Tc-dicarboxypropane diphosphonate (DPD) revealed an enhanced tracer uptake at the bone-cartilage junctions of most ribs, the right femur neck and both knee joints. Furthermore, there was early enhancement of both medial and distal tibiae and the forefoot (Fig. 1).

Osteomalacia was diagnosed and TDF nephrotoxicity was identified as the most likely cause. After replacement of TDF by another antiretroviral agent

Competing interests: none declared.

Table I. Course of the patient's laboratory test results before, during and after TDF exposure from July 2006 until August 2007.

Month/year	07/2005	11/2005	06/2006	11/2006	03/2007	06/2007	07/2007	07/2007	09/2007	10/2007	10/2007	11/2008
Serum creatinine ($\mu\text{mol/L}$)	68	65	66	97	117	110	132	136	117	102	110	97
GFR (ml/min)	47	58	57	39	32	34	28	28	32	37	34	39
Serum calcium (2.0–2.6 mmol/L)	2.7		2.5	2.4	2.5		2.4		2.5	2.5	2.4	2.6
Serum alkaline phosphatase (39–117 U/L)	89	105	119	313	560	498	349	308		224	219	57
Serum phosphate (0.9–1.5 mmol/L)							0.6		0.6	1.1	1.5	1.1

(saquinavir) in August 2007, pain and joint effusions improved rapidly; after three months, all symptoms had vanished completely. After discontinuation of tenofovir, serum phosphate and alkaline phosphatase normalised and renal function improved (Table I).

Discussion

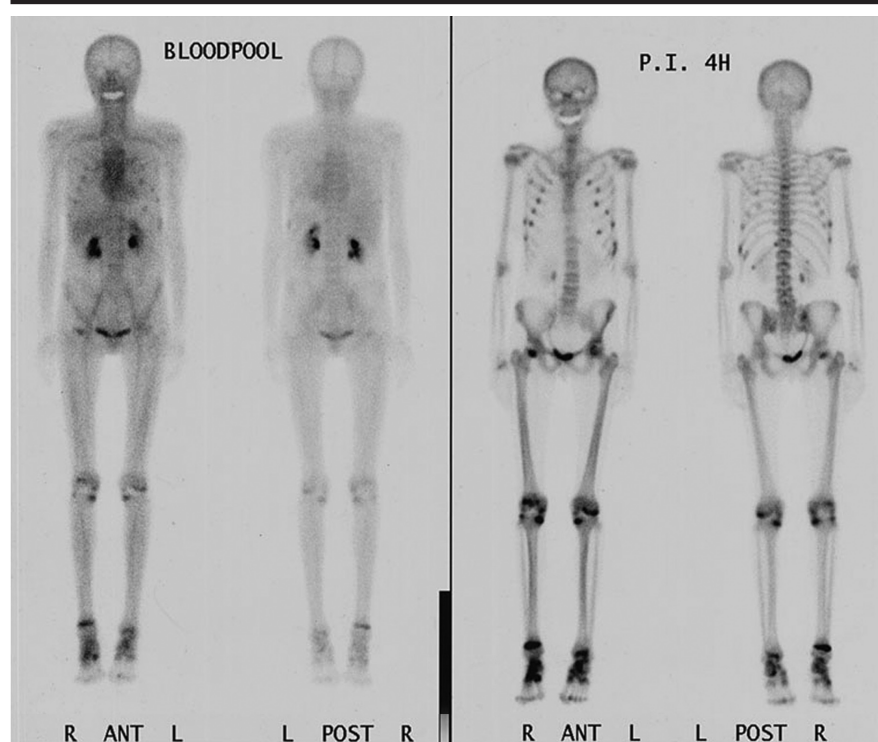
To our knowledge, only two further reports have described symptomatic osteomalacia due to TDF nephrotoxicity in humans (2, 3). TDF is a prodrug which allows for a high bioavailability of tenofovir, a nucleotide analogue HIV reverse transcriptase inhibitor in the serum. Tenofovir is eliminated by glomerular filtration and tubular secretion in the kidney. For this purpose, tenofovir is actively taken up from the bloodstream into the proximal tubule cells by the human renal organic anion transporters 1 and 3. Efflux from these cells into the tubular lumen is mediated by the multidrug resistance protein 4 (MDR-4) (4). Excessively high intracellular tenofovir concentrations locally interfere with the replication of mitochondrial DNA, a molecule which is necessary for the function of the tubular respiratory chain (5, 6). Thus, an acquired mitochondrial dysfunction in the kidney due to TDF may be pathogenetically similar to the Fanconi syndrome which is observed with inherited mutations in mitochondrial DNA (7). In animals, supratherapeutic doses of TDF induced a Fanconi syndrome with tubular phosphate loss and osteomalacia (8). Randomised trials have demonstrated a good safety profile of TDF, but showed an increased frequency of hypophosphatemia (9). Most investigations so far, however, have focused on

glomerular filtration rates (10) and serum phosphate, even though a compromise in renal function is not expected in Fanconi syndrome and normal serum phosphate levels may be preserved by increased phosphate mobilisation from bone, thus masking increased renal loss (11). More sensitive methods have recently been developed and revealed a diminished renal phosphate resorption (hyperphosphaturia) in patients treated with TDF (12). Moreover, a large HIV-cohort has demonstrated that TDF therapy is associated with a significant increase in serum alkaline phosphatase (13).

In our patient preexisting renal damage and cotherapy with lopinavir/r represent

risk factors for TDF nephrotoxicity. Lopinavir/r increases tenofovir serum levels and also may inhibit MDR4, with both mechanisms then contributing to intratubular tenofovir accumulation (4, 14, 15). It is interesting to note that lopinavir/r was also used in all other three cases described (2, 3).

This complication of TDF therapy is likely to become more prevalent in the future because lopinavir and TDF are increasingly used in HIV treatment. Awareness is needed by infectious diseases specialists, rheumatologists and nephrologists to link the typically prolonged onset of clinical symptoms with drug exposure and then establish the correct diagnosis.

**Fig. 1.** Skeletal scintigraphy (September 2007) showing multiple pseudofractures (Looser's zones).

References

1. BRINKMAN K, SMEITINK JA, ROMIJN JA, REISS P: Mitochondrial toxicity induced by nucleoside-analogue reverse-transcriptase inhibitors is a key factor in the pathogenesis of antiretroviral-therapy-related lipodystrophy. *Lancet* 1999; 354: 1112-5.
2. PARSONAGE MJ, WILKINS EG, SNOWDEN N, ISSA BG, SAVAGE MW: The development of hypophosphataemic osteomalacia with myopathy in two patients with HIV infection receiving tenofovir therapy. *HIV Med* 2005; 6: 341-6.
3. TORRES ISIDRO MV, GARCIA BT, VAL GOMEZ MM *et al.*: Role of bone gammagraphy in the diagnosis of secondary osteomalacia in a patient treated with tenofovir. *Rev Esp Med Nucl* 2006; 25: 103-6.
4. CIHLAR T, RAY AS, LAFLAMME G *et al.*: Molecular assessment of the potential for renal drug interactions between tenofovir and HIV protease inhibitors. *Antivir Ther* 2007; 12: 267-72.
5. LEBRECHT D, VENHOFF AC, KIRSCHNER J, WIECH T, VENHOFF N, WALKER UA: Mitochondrial tubulopathy in tenofovir-DF treated rats. *J Acquir Immune Defic Syndr* 2009; 51: 258-63.
6. COTE HC, MAGIL AB, HARRIS M *et al.*: Exploring mitochondrial nephrotoxicity as a potential mechanism of kidney dysfunction among HIV-infected patients on highly active antiretroviral therapy. *Antivir Ther* 2006; 11: 79-86.
7. ROTIG A: Renal disease and mitochondrial genetics. *J Nephrol* 2003; 16: 286-92.
8. TENOFOVIR REVIEW TEAM: Memorandum. www.fda.gov 2001.
9. GALLANT JE, STASZEWSKI S, POZNIAK AL *et al.*: Efficacy and safety of tenofovir DF vs stavudine in combination therapy in antiretroviral-naïve patients: a 3-year randomized trial. *JAMA* 2004; 292: 191-201.
10. MADEDDU G, BONFANTI P, DE SOCIO GV *et al.*: Tenofovir renal safety in HIV-infected patients: results from the SCOLTA Project. *Biomed Pharmacother* 2008; 62: 6-11.
11. IZZEDINE H, HULOT JS, VITTECOQ D *et al.*: Long-term renal safety of tenofovir disoproxil fumarate in antiretroviral-naïve HIV-1-infected patients. Data from a double-blind randomized active-controlled multicentre study. *Nephrol Dial Transplant* 2005; 20: 743-6.
12. KINAI E, HANABUSA H: Renal tubular toxicity associated with tenofovir assessed using urine-beta 2 microglobulin, percentage of tubular reabsorption of phosphate and alkaline phosphatase levels. *AIDS* 2005; 19: 2031-3.
13. FUX CA, RAUCH A, SIMCOCK M *et al.*: Tenofovir use is associated with an increase in serum alkaline phosphatase in the Swiss HIV Cohort Study. *Antivir Ther* 2008; 13: 1077-82.
14. GUPTA SK: Tenofovir-associated Fanconi syndrome: review of the FDA adverse event reporting system. *AIDS Patient Care STDs* 2008; 22: 99-103.
15. KEARNEY BP, MATHIAS A, MITTAN A, SAYRE J, EBRAHIMI R, CHENG AK: Pharmacokinetics and safety of tenofovir disoproxil fumarate on coadministration with lopinavir/ritonavir. *J Acquir Immune Defic Syndr* 2006; 43: 278-83.