
Extra-articular manifestations

H. Mielants and F. Van den Bosch

Department of Rheumatology,
University Hospital Gent, Gent, Belgium.

Herman Mielants, MD, PhD,
Professor of Rheumatology
Filip Van den Bosch, MD, PhD

Please address correspondence to:
Prof. Herman Mielants

Department of Rheumatology,
University Hospital,
De Pintelaan 185,
B-9000 Gent, Belgium.

E-mail: herman.mielants@ugent.be

Received and accepted on July 29, 2009.

Clin Exp Rheumatol 2009; 27 (Suppl. 55):
S56-S61.

© Copyright CLINICAL AND
EXPERIMENTAL RHEUMATOLOGY 2009.

Key words: Rheumatoid arthritis,
spondyloarthritis, ankylosing
spondylitis, extra-articular
manifestations.

ABSTRACT

Rheumatoid arthritis and spondyloarthritis, a concept which includes diseases like ankylosing spondylitis, psoriatic arthritis, and arthritis/spondylitis associated with inflammatory bowel disease, are both chronic inflammatory rheumatologic conditions. This article focuses on extra-articular manifestations, defined as diseases and symptoms not directly related to the locomotor system. The different manifestations are addressed per body system. Diagnostic and prognostic implications of these manifestations in daily practice are discussed.

Introduction

Ankylosing spondylitis (AS) and rheumatoid arthritis (RA) can be considered as prototypes of inflammatory rheumatic diseases. In both diseases, the locomotor problem is prominent: it includes arthritis (RA, AS), but also other specific problems such as tenosynovitis (RA), enthesitis (AS), dactylitis, sacroiliitis and axial disease (AS). Besides the articular/axial component, other body systems are frequently involved. We consider extra-articular manifestations, all the conditions and symptoms which are not directly related to the locomotor system.

Systemic features in RA are frequent, mostly related to vasculitis, and often a reflection of longstanding inflammation. Most organs can be involved. These manifestations occur as frequent in men as in women, and may appear at any age (1). Prevalence of these manifestations is about 40% of patients at any time during the course of the disease. The occurrence of these systemic manifestations is a major predictor of mortality in patients with RA.

Whereas RA is a relatively homogeneous disease, AS belongs to a broader disease concept, namely spondyloarthritis (SpA). Major diseases belonging to this concept (beside AS) are arthritis/spondylitis associated with inflammatory

bowel disease, some forms of psoriatic arthritis, and reactive arthritis (Fig. 1). In early disease a large group of patients will initially be classified as undifferentiated (axial) SpA; over time this may evolve into a more specific diagnosis.

In AS, extra-articular manifestations can be subdivided in 2 groups: those related to the SpA concept, such as involvement of skin, eye, gut or urogenital system, and those more reflecting chronic, longstanding inflammation, which are involvement of lung, heart, kidney and nerves. The concept-related manifestations are relatively frequent (20–60%) (2), can occur at any moment of the disease evolution (sometimes as first manifestation), and can sometimes be related to axial or peripheral joint inflammation. The non-concept related manifestations are very rare (1 to 5%), are frequently subclinical, occur only in longstanding disease, and are not related to the locomotor manifestations. We will discuss the different manifestations per body system.

Skin manifestations

RA: Rheumatoid nodules are the most frequent skin manifestation in RA. They have a firm, rubbery consistency, are painless and subcutaneously, and occur most commonly on pressure areas, including elbows, finger joints, sacral prominences and Achilles tendon. They occur mainly in rheumatoid factor positive RA patients and in early RA give risk to severe extra-articular manifestations. A recent study found that positivity for rheumatoid factor, smoking and human leucocyte antigen (HLA)DRB1*0401 were the only factors independently associated with nodules (3). Histologically focal central fibrinoid necrosis with surrounding fibroblasts is observed: it is believed to occur as a result of small vessel vasculitis. Regression of nodules may occur during treatment with disease modifying drugs (DMARD); paradoxically methotrexate may increase nodules,

Competing interests: none declared.

despite improvement in overall disease activity (4).

Other manifestations of rheumatoid small vessel vasculitis affecting the skin are splinter haemorrhages, periungual infarcts, leg ulcers, digital gangrene and sharply demarcated painful ulcerations. They appear mostly at the lower extremities or where skin is exposed to pressure. Vasculitis can be present without active joint disease, mostly in RA patients with high rheumatoid factor, and the skin manifestations are frequently associated with other extra-articular features like episcleritis, pleural and pericardial effusions (5). Capillaries, small venules, veins, arterioles, and medium-sized arteries are most frequently involved (6), but large vessels can also be affected. Early lesions show fibrinoid necrosis of the vessel wall, with an inflammatory cell infiltrate. Later on, artery wall fibrosis with occlusion can appear.

AS: Psoriatic or psoriatic-like lesions occur more frequently in AS, compared to the general population, and can precede the disease in 15% of the cases. The skin and nail lesions are identical to isolated skin disease, mostly compatible with plaque psoriasis (vulgaris), but the lesions are sometimes localised on more atypical localisations, such as palms of hands and feet (palmoplantar pustulosis). The clinical picture of psoriatic AS is identical to that of non-complicated AS; radiologically, however, sacroiliitis is more frequently asymmetrical, while the syndesmophytes occur also more asymmetrical and can be more plump; zygoapophyseal fusion is more seldom. There are no data supporting a parallelism between the activity of psoriasis and the locomotor inflammation.

Erythema nodosum, which are painful red nodules mostly localised on the distal extremities, are observed in associated inflammatory bowel disease (IBD), occurring in up to 15% of patients (7). It is seen in association with peripheral arthritis and often parallels the activity of the inflammatory bowel disease. Biopsy shows focal panniculitis.

Pyoderma gangrenosum is an ulcerative disease of the skin of unknown origin, associated with an underlying

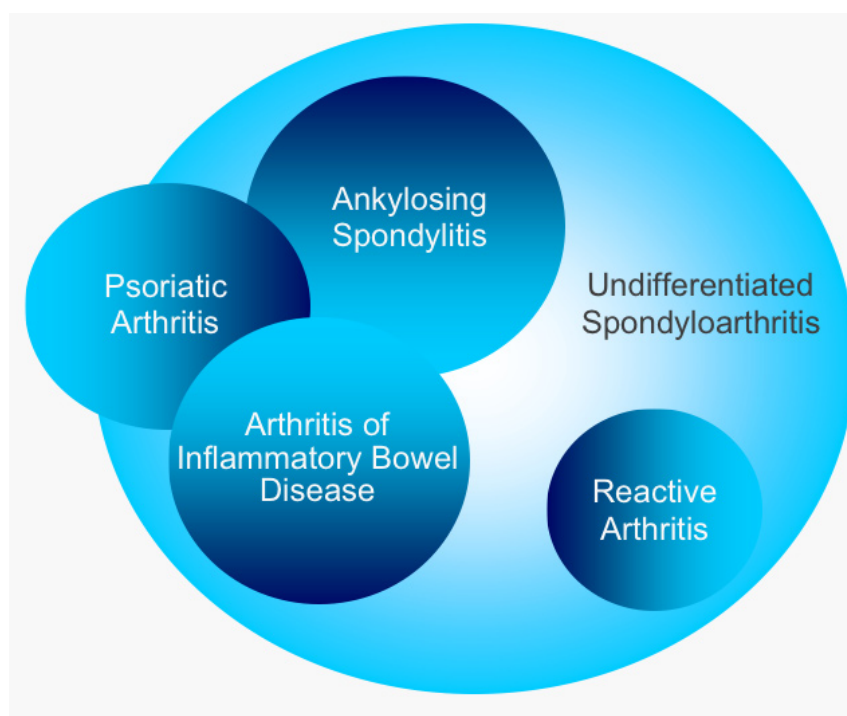


Fig. 1. The Spondyloarthritis (SpA) concept.

systemic disease, most commonly IBD (8). The lesions present as erythematous papules or pustules, with subsequent necrosis of the dermis, leading to deep ulcerations.

Keratoderma blennorrhagica (mostly related to genitourinary involvement) is an unusual, but more severe skin manifestation, which begins with clear vesicles, progressing to pustular keratotic lesions that are painful on pressure. There is no relationship with the activity of the AS inflammation. In most cases, from a histological point of view, this condition cannot be differentiated from palmoplantar pustulosis.

Ocular manifestations

RA: Different eye manifestations can occur in RA. The most frequent is keratoconjunctivitis sicca, which affects at least 10% of patients. It is frequently observed together with xerostomia in a secondary Sjögren's syndrome. Ocular symptoms range from dry eyes, over a burning sensation of a foreign body, to mucoid discharge. The diagnosis is supported by a positive Schirmer test and a reduced tears break-up time. In patients with dry mouth syndrome, a reduced salivary flow rate, and minor salivary gland biopsy, can support the diagnosis.

Episcleritis, inflammation of the layer superficial to the sclera, occurs in fewer than 1% of patients with RA and is generally a self-limiting condition. It presents with focal dusky redness and irritation of the eye, but without disturbing visual acuity. The phenomenon usually correlates with the activity of RA.

Scleritis is a more aggressive process, characterized by an intensely painful inflammation of the sclera itself. This process may be either nodular or diffuse. It is seen in patients with vasculitis and long-standing arthritis. Untreated scleritis may progress to scleromalacia with a risk for perforation.

Peripheral ulcerative keratitis develops as an extension of scleral inflammation with involvement of the peripheral cornea and can lead to corneal melt; it is frequently bilateral and can cause poor outcome for vision.

AS: Acute anterior uveitis (AAU) occurs in 30 to 40% of AS patients (9), and is strongly associated with HLA-B27. In large series of patients, the mean frequency of active episodes of uveitis was 0.8 attacks per year (10). About 50% of patients with AAU as an initial presentation, have or will develop a form of SpA. The disease primarily affects only the anterior chamber of the

Table I. Rheumatoid arthritis and spondyloarthritis: summary of extra-articular manifestations per body system.

	Rheumatoid arthritis	Spondyloarthritis (SpA)	
		SpA concept-related	Non-SpA concept-related
Skin	Rheumatoid nodules	Psoriasis	
	Rheumatoid vasculitis	Erythema nodosum Pyoderma gangrenosum Keratoderma blennorrhagica	
Eye	Keratoconjunctivitis sicca	Acute anterior uveitis	
	Episcleritis Scleritis		
Gastrointestinal	Vasculitis	Inflammatory bowel disease * Crohn's disease * Ulcerative colitis	
Pulmonary	Pleuritis		Upper lobe fibrosis
	Pulmonary nodules Interstitial pulmonary fibrosis Bronchiolitis obliterans organising pneumonia		Pleural thickening
Cardiac	Pericarditis		Aortitis, aortic insufficiency
	Myocarditis (nodules) Endocarditis (nodules)		Conduction abnormalities (bundle branch block, AV conduction block)
Renal	Glomerulonephritis		Secondary amyloidosis
	Secondary amyloidosis		IgA nephropathy
Neurological	Mononeuritis multiplex		Cauda Equina syndrome
	Peripheral entrapment neuropathies		
Haematological	Anaemia, thrombocytosis		
	Lymphadenopathy Felty's syndrome		

eye. A typical attack has a sudden onset and is unilateral (but in subsequent attacks the other eye may be involved): local redness, pain, photophobia and reduced vision are the cardinal symptoms. In most cases local treatment is sufficient; relapses however are frequent, and prolonged, uncontrolled anterior uveitis can extend into the posterior part of the eye with formation of synechiae and secondary glaucoma. Only in these cases systemic treatment with corticosteroids, immunosuppressive agents (such as methotrexate or cyclosporine) or TNF-blocking agents may be necessary.

Gastrointestinal system

RA: Gastrointestinal complications in RA are mostly iatrogenic and caused by medications (non-steroidal anti-inflammatory drugs, methotrexate, leflunomide etc.).

Primary involvement of the gastrointestinal tract, caused by mesenteric vasculitis leading to intestinal infarction, is very rare (11). This condition causes acute abdominal pain, and can lead to

intestinal bleeding and perforation. There is no direct relation with arthritis activity, but as with other vasculitides, it is mostly observed in RA patients with high rheumatoid factor and subcutaneous nodules. Prognosis is poor and outcome frequently fatal.

AS: Inflammatory bowel diseases (IBD), such as Crohn's disease and ulcerative colitis, are part of the SpA concept. Overt clinical IBD is observed in 5 to 10% of AS patients. There are many arguments to consider that the gut could play an important role in the pathogenesis of SpA (reviewed in 12). Following ileocolonoscopy, microscopic intestinal inflammation has been seen in up to 60% of patients with AS (13). The intestinal inflammation seems more frequent in the presence of peripheral arthritis. Moreover a strong relationship exists between the presence of actual rheumatological disease activity and the presence of gut inflammation; in patients in clinical remission, the gut inflammation usually also disappears (14). Subclinical intestinal inflammation is immunologically closely related to the inflammation

in Crohn's disease (CD), with structural abnormalities in the gut and formation of granulomas. While in the majority of the patients the disease remains subclinical, about 6.5% of AS patients with subclinical gut inflammation will later develop overt Crohn's disease (15). Recently polymorphisms in the CARD 15 gene (16) and studies on the IL23 R gene, have demonstrated a genetic linkage between CD (17) and AS (18), giving further support to this gut-joint axis.

Pulmonary manifestations

RA: Pulmonary involvement in RA is frequent although not always clinically recognized. Pleural disease is common but usually asymptomatic; autopsy studies reported pleural involvement in 50% of cases, with only 10% clinically detected (19). Pleural effusions are usually exudates with mixed cell counts and high protein concentration (20). Multinucleated giant cells are highly specific but seen in fewer than 50% of the cases. The disease is frequently associated with exudative pericarditis, and with interstitial lung disease.

Parenchymal pulmonary nodules generally are asymptomatic and found in RF-positive patients with nodules elsewhere. They can cavitate and cause pleural effusions. Pathological examination of the nodules reveals a central necrotic zone surrounded by a cellular area of proliferating fibroblasts. As with classical subcutaneous nodules, the underlying process appears to be a vasculitis. Differentiation with neoplasms and tuberculous or fungal infections can be difficult.

Diffuse interstitial pulmonary fibrosis in RA tends to occur more often in RF-positive male patients with longstanding nodular disease (20). The clinical presentation and course of pulmonary fibrosis in RA is similar to that of idiopathic pulmonary fibrosis, but response to immunosuppression may be better.

Bronchiolitis obliterans organizing pneumonia (BOOP) responds to glucocorticoid treatment and has a good prognosis; obliterative or constrictive bronchiolitis responds poorly and has a poor prognosis (20).

Finally low-dose weekly methotrexate therapy may rarely lead to life-threatening pneumonitis (21).

AS: Pulmonary involvement in AS is uncommon and estimated to occur in less than 1%, mostly in long-standing and severe disease (22). Involvement of the costovertebral joints and ankylosis of the thoracic spine will lead to a limited chest expansion which might affect the patients' breathing capacity, but only rarely leads to restrictive respiratory impairment, because diaphragmatic function is not impaired.

The most frequently recognized manifestations are upper lobe fibrosis and pleural thickening (23). Fibrosis is typically asymptomatic. These manifestations have no direct relationship with the disease evolution, and no treatment seems to be efficacious.

Cardiac disease

RA: The risk for myocardial infarction in female RA patients is twice that of women without RA, and in long-standing disease of at least 10 years, the risk is 3 times higher (24). Although the exact mechanism is not completely understood, there are associations between C-reactive protein levels and

cardiovascular outcome for both acute coronary syndromes and long-term risk for cardiovascular and cerebrovascular disease, independent of lipid levels (25).

Pericarditis is the most common cardiac manifestation in RA. Although symptomatic pericarditis is relatively uncommon, autopsy studies revealed evidence of pericardial inflammation in 50% of the patients (26). It usually occurs in RF-positive patients with nodules (27) and analysis of pericardial fluid reveals changes similar to those found in rheumatoid pleural effusions.

Myocarditis (with presence of rheumatoid nodules) has been observed in autopsy studies, and myocardial fibrosis can lead to conduction abnormalities (28). Congestive heart failure may be more frequent than is clinically evident in RA.

Endocarditis with formation of rheumatoid nodules in the aortic or mitral valves can lead to valvular dysfunction (28).

AS: In daily clinical practice, symptoms of heart involvement in AS patients are rarely seen, and clinical significant cardiac disease occurs in 2–10% of patients, mostly after longstanding disease (29), with no association with articular disease activity. Nearly all patients with cardiac manifestations are HLA B27 positive.

Valvular pathology secondary to aortitis with aortic insufficiency (aortic regurgitation), or bundle-branch block occur in approximately 5% of patients with AS, usually after longstanding disease (30). This can lead to heart failure, usually over several years.

Multiple forms of atrioventricular conduction blocks have been reported; only in a few cases do complete blocks occur, necessitating pacemaker implantation.

Myocardial involvement with abnormal left ventricular diastolic function may be the result of the sclerosing inflammatory process, involving aortic root and valves.

Renal disease

RA: Renal involvement in RA is rare; mesangial glomerulonephritis was the most common histopathological finding (31), whereas amyloidosis was the most common finding among patients

with nephrotic syndrome. Glomerulonephritis and interstitial renal disease are uncommon in the absence of vasculitis. Renal abnormalities are frequently iatrogenic, induced by the use of DMARDs or NSAIDs ("analgesic abuse nephropathy").

AS: The most common renal manifestation in AS is secondary amyloidosis (32). It is reported in 1–3% of patients with longstanding active disease. Patients present with proteinuria progressing to nephrotic syndrome and renal failure.

Immunoglobulin (Ig)A nephropathy is also uncommon. Patients have increased IgA serum levels, microscopic haematuria and proteinuria, and can develop renal insufficiency. In some studies a correlation was shown between high levels of IgA in serum and disease activity in AS patients (33).

Neurological manifestations

RA: Peripheral neuropathy, presenting as diffuse sensorimotor neuropathy or mononeuritis multiplex, occurs in a small subset of patients with RA. The underlying mechanism is small vessel vasculitis of the vasa vasorum of the nerves with ischemic neuropathy and demyelination. These manifestations are part of the rheumatoid vasculitis syndrome.

Peripheral entrapment neuropathies, like carpal tunnel syndrome, are frequent and are related to the degree and severity of local synovitis or tenosynovitis, but not related to other extra-articular manifestations of RA. They may be the initial symptoms in early RA.

Cervical myelopathy, caused by atlantoaxial subluxation or pannus formation, occurs frequently in RA patients with severe and longstanding disease (35). Basilar invagination, with upward impingement of the odontoid process into the foramen magnum, can also result in cord compression. This complication may require surgical intervention. Surgeons and anaesthetists should be aware of this possible atlantoaxial subluxation, because intubation could lead to sudden death secondary to pressure and bleeding in the upper part of the spinal cord.

AS: Neurological involvement in AS is most often related to spinal fracture, at-

lantoaxial subluxation or cauda equina syndrome. This last manifestation, is slowly progressive and insidious, and mostly a late manifestation of AS, often when the disease is no longer active (36). It leads to sensory, motor and reflex loss progressing to sphincter dysfunction.

Haematologic manifestations

RA: The cause of anaemia in RA is multifactorial. Iron utilization is impaired as reflected by decreased serum iron and transferrin concentrations. There is an increased synthesis of ferritin and haemosiderin, and abnormal retention of iron from senescent red blood cells by the reticuloendothelial system. Anemia of chronic disease is observed in RA, where it usually correlates with the disease activity, particular the degree of articular inflammation. It is normochromic and normocytic.

Thrombocytosis is a frequent finding in active RA and is correlated with the number of active inflamed joints.

Lymphadenopathy is sometimes observed in active RA, usually presenting on biopsy as benign follicular hyperplasia. RA is however associated with an increased risk of malignant non-Hodgkin's lymphoma compared with the general population (37), probably as a consequence of longstanding inflammation. Large B cell lymphoma is the most frequent form.

Felty's syndrome is defined as a combination of RA with splenomegaly and leucocytopenia. The syndrome occurs mostly in patients with longstanding, RF-positive, nodular, deforming RA. Thrombocytopenia is frequently associated. Bone marrow is usually normal or hyperplastic. Splenectomy may improve the haematological abnormalities and may be indicated for recurrent serious infections caused by neutropenia. There is an increased risk for development of lymphoproliferative disorders and other malignancies in patients with Felty's syndrome (37).

AS: With the exception of increased inflammatory markers, which are more associated with peripheral arthritis and extra-articular manifestations than with axial disease, no specific haematological abnormalities are observed.

Conclusion

The occurrence of signs and symptoms outside the locomotor apparatus is a frequent finding in patients with chronic inflammatory rheumatic conditions, such as AS or RA. Whereas in RA, almost all manifestations are a consequence of longstanding active disease (vasculitis), the extra-articular manifestations in AS can be divided into rather frequent concept-related manifestations, sometimes leading to overt diseases such as psoriasis or inflammatory bowel disease, and non-concept-related manifestations. Awareness of these extra-articular manifestations is important for the clinician both from a diagnostic (concept-related manifestations) and a prognostic viewpoint. As such, it is not surprising that occurrence of *e.g.* diarrhoea, uveitis or psoriasis are considered valuable clues for classification of patients presenting with early signs of articular disease suggestive of SpA (38). An initial check-up and regular control of these manifestations should be a necessary part of the follow-up of patients with these inflammatory rheumatic diseases.

References

1. TURESSON C, JACOBSSON L, BERGSTROM U: Extra-articular rheumatoid arthritis: prevalence and mortality. *Rheumatology* 1999; 38: 668-741.
2. VANDER CRUYSSSEN B, RIBBENS C, BOONEN A *et al.*: The epidemiology of ankylosing spondylitis and the commencement of anti-TNF therapy in daily rheumatology practice. *Ann Rheum Dis* 2007; 66: 354-9.
3. MATTEY DL, DAWES PT, FISHER J *et al.*: Nodular disease in rheumatoid arthritis: association with cigarette smoking, and HLA-DRB1/TNF gene interaction. *J Rheumatol* 2002; 29: 2313-18.
4. SEGAL R, CASPI D, TISHLER M *et al.*: Accelerated nodulosis and vasculitis during methotrexate therapy for rheumatoid arthritis. *Arthritis Rheum* 1988; 31: 1182-85.
5. VOSKUYL AE *et al.*: Factors associated with the development of vasculitis in rheumatoid arthritis: results of a case-control study. *Ann Rheum Dis* 1996; 55: 190-2.
6. BACON PA, CARRUTHERS DM: Vasculitis associated with connective tissue disorders. *Rheum Dis Clin North Am* 1995; 21: 1077-96.
7. VELOSO F, CARVALHO J, MAGRO F: Immune-related systemic manifestations of inflammatory bowel disease. A prospective study of 792 patients. *J Clin Gastroenterology* 1996; 23: 29-34.
8. MIR-MADJELESSI SH, TAYLOR JS, FARMER RG: Clinical course and evolution of erythema nodosum and pyoderma gangrenosum in chronic ulcerative colitis: a study of 42 patients. *Am J Gastroenterol* 2003; 98: 1821-6.
9. BRAUN J, BARALIOKOS X, LISTING J, SIEPER J: Decreased incidence of anterior uveitis in patients with Ankylosing spondylitis treated with anti-tumor necrosis factor agents infliximab and etanercept. *Arthritis Rheum* 2005; 52: 2447-51.
10. MONNET D, MOACHON L, DOUGADOS M, BREZIN AP: Severe uveitis in a HLA-B 27-positive patients with Ankylosing spondylitis. *Nat Clin Pract Rheumatol* 2006; 2: 393-7.
11. MOSLEY JG, DESAI A, GUPTA I: Mesenteric arteritis. *Gut* 1990; 31: 956-7.
12. DE KEYSER F, ELEWAUT D, DE VOS M *et al.*: Bowel inflammation and the spondyloarthropathies. *Rheum Dis Clin North Am* 1998; 24: 785-813.
13. MIELANTS H, VEYS EM, CUVELIER C, DE VOS M: Ileocolonoscopy findings in seronegative spondyloarthropathies. *Br J Rheumatol* 1988; 27: 595-605.
14. MIELANTS H, VEYS EM, CUVELIER C *et al.*: The evolution of spondyloarthropathies in relation to gut histology. Part III: relation between gut and joint. *J Rheumatol* 1995; 22: 2273-8.
15. MIELANTS H, VEYS EM, CUVELIER C *et al.*: The evolution of spondyloarthropathies in relation to gut histology. Part I: clinical aspects. *J Rheumatol* 1995; 22: 2266-72.
16. LAUKENS D, PEETERS H, MARICHAL D *et al.*: CARD 15 gene polymorphisms in patients with spondyloarthropathies identify a specific phenotype previously related to Crohn's disease. *Ann Rheum Dis* 2005; 64: 930-5.
17. DUERR RH, TAYLOR KD, BRANT SR *et al.*: A genome-wide association study identifies IL23R as an inflammatory bowel disease gene. *Science* 2006; 314: 1461-3.
18. RAHMAN P, INMAN RD, GLADMAN DD *et al.*: Association of interleukin 23 receptor variants with ankylosing spondylitis. *Arthritis Rheum* 2008; 58: 1020-5.
19. TURESSON C, O'FALLON WM, CROWSON CS *et al.*: Occurrence of extra-articular disease manifestations is associated with excess mortality in population-based cohort of patients with rheumatoid arthritis. *J Rheumatol* 2002; 29: 62-7.
20. ANAYA JM, DICTHELM L, ORTIZ LA *et al.*: Pulmonary involvement in RA. *Semin Arthritis Rheum* 1995; 24: 242-54.
21. BARRERA P *et al.*: Methotrexate-related pulmonary complications in rheumatoid arthritis. *Ann Rheum Dis* 1994; 53: 434-9.
22. CASSERLY IP, FENLON HM, BREATNACH E, SANT SM: Lung findings on high resolution computed tomography in idiopathic ankylosing spondylitis- correlation with clinical findings, pulmonary function testing and plain radiograph. *Br J Rheumatol* 1997; 36: 677-82.
23. MAGHRAOUI AE, CHAOUI S, ABID A *et al.*: Lung findings on thoracic high-resolution computed tomography in patients with Ankylosing spondylitis. Correlations with disease duration, clinical findings and pulmonary function testing. *Clin Rheumatol* 2004; 23: 123-8.
24. SOLOMON DH, KARLSON EW, RIMM EB *et*

- al.: Cardiovascular morbidity and mortality in women diagnosed with rheumatoid arthritis. *Circulation* 2003; 107: 1303-7.
25. RIDKER PM, GLYNN RJ, HENNEKENS CH: C-reactive protein adds to the predictive value of total and HDL cholesterol in determining risk of first myocardial infarction. *Circulation* 1998; 97: 2007-11.
 26. BONFIGLIO T, ATWATER EC: Heart disease in patients with seropositive RA. *Arch Intern Med* 1969; 124: 714-9.
 27. HARA KS, BALLARD DJ, ILSTRUM DM *et al.*: Rheumatoid pericarditis: clinical features and survival. *Medicine* 1990; 69: 81-91.
 28. CATHCART ES, SPODICK DH: Rheumatoid heart disease: a study of the incidence and nature of cardiac lesions in rheumatoid arthritis. *N Engl J Med* 1962; 266: 959-64.
 29. HUFFER LL, FURGERSON IL: Aortic root dilatation with sinus of valsalva and coronary artery aneurysms associated with Ankylosing spondylitis. *Tex Heart Inst J* 2006; 33: 70-3.
 30. BRUNNER F, KUNZ A, WEBER U and KISSLING R: Ankylosing spondylitis and heart abnormalities : do cardiac conduction disorders, valve regurgitation and diastolic dysfunction occur more often in male patients with diagnosed Ankylosing spondylitis for over 15 years than in normal population? *Clin Rheumatol* 2006; 25: 24-9.
 31. KORPELA M, MUSTONEN J, TEPPONEN AM *et al.*: Mesangial glomerulonephritis as an extra-articular manifestation of rheumatoid arthritis. *Br J Rheumatol* 1997; 36: 1189-95.
 32. STROBEL ES, FRITSHKA E: Renal diseases in Ankylosing spondylitis: review of the literature illustrated by case reports. *Clin Rheumatol* 1998; 17: 524-30.
 33. LAI KN, LI PK, HAWKINS B, LAI FM: IgA nephropathy associated with Ankylosing spondylitis: occurrence in women as well in men. *Ann Rheum Dis* 1989; 48: 435-7.
 34. COLLADO A, SANMARTI R, BRANCOS MA *et al.*: Immunoglobulin A and C reactive protein levels in ankylosing spondylitis. *Ann Rheum Dis* 1987; 46: 719-20.
 35. LAIHO K, KAARELA K, KAUPPI M: Cervical spine disorders in patients with rheumatoid arthritis and amyloidosis. *Clin Rheumatol* 2002; 21: 227-30.
 36. GINSBURG WW, COHEN MD, MILLER GM, BARTLESON JD: Posterior vertebral body erosion by arachnoid diverticula in cauda equine syndrome: an unusual manifestation of ankylosing spondylitis. *J Rheumatol* 1997; 24: 1417-20.
 37. GRIDLEY G, McLAUGHLIN JK, ERBOM A *et al.*: Incidence of cancer among patients with rheumatoid arthritis. *J Nat Cancer Inst* 1993; 85: 307-11.
 38. RUDWALEIT M, VANDER HEIJDE D, LANDEWÉ R *et al.*: The development of Assessment of SpondyloArthritis international Society classification criteria for axial spondyloarthritis (part II): validation and final selection. *Ann Rheum Dis* 2009; 68: 777-83.