

Sustained success of therapy with inhaled iloprost for severe pulmonary arterial hypertension associated with systemic sclerosis and pulmonary fibrosis

K. Ahmadi-Simab¹, A. Köhler², W.L. Gross¹

¹Department of Rheumatology, University Hospital of Schleswig-Holstein, Campus Lübeck and Rheumaklinik Bad Bramstedt, Germany; ²Paracelsus-Klinik Glückstadt GmbH, Germany.

Keihan Ahmadi-Simab, MD;

Annika Köhler, MD;

Wolfgang Ludwig Gross, MD, Professor.

Please address correspondence to:

Dr. Keihan Ahmadi-Simab, Department of Rheumatology, University Hospital of Schleswig-Holstein, Campus Lübeck and Rheumaklinik Bad Bramstedt, Oskar-Alexander Str. 26, D-24576 Bad Bramstedt, Germany.

E-mail: ahmadi@email.de

Received on March 31, 2006; accepted in revised form on February 16, 2007.

© Copyright CLINICAL AND

EXPERIMENTAL RHEUMATOLOGY 2007.

Key words: Pulmonary hypertension, systemic sclerosis, iloprost.

ABSTRACT

Case report. We report here the case of a woman with diffuse cutaneous systemic sclerosis with pulmonary involvement and severe (WHO functional class III) pulmonary arterial hypertension (PAH) and recurrent cardiac decompensation. The simultaneous presence of primary biliary cirrhosis with markedly elevated transaminase levels constituted a contraindication for bosentan, which would otherwise have been the first-line treatment for PAH. The patient was therefore treated with inhaled iloprost.

Discussion. Once inhaled iloprost therapy had been started, we promptly noted a definite and sustained improvement in physical exercise capacity and normalisation of haemodynamic variables. In cases where bosentan is contraindicated, inhaled iloprost is an effective alternative for the treatment of severe PAH.

Introduction

Pulmonary arterial hypertension (PAH) is one of the most serious complications of systemic sclerosis (SSc). A high prevalence of PAH in patients with SSc has been reported in one recently published study, according to which 23% of such patients show elevated pulmonary artery pressure (PAP > 30 mmHg) (1, 2). Patients with PAH related to SSc have a markedly worse prognosis than patients with idiopathic PAH. For example, if the condition is left untreated, the mean survival time of patients with idiopathic PAH is 2.8 years whereas patients with SSc-PAH have a mean life expectancy of only 1 year and approximately 80% of PAH patients will have died within 2 years (2). Whereas even a few years ago lung transplantation was the only therapeutic option for patients with severe PAH, immense advances have recently been achieved in the pharmacological management of this condition. The development of prostanooids in various formulations (intravenous, subcutaneous, oral or inhaled) and of endothelin receptor antagonists has clearly contributed to improving the treatment of PAH associated with collagen vascular disease. The efficacy of the endothelin receptor antagonist

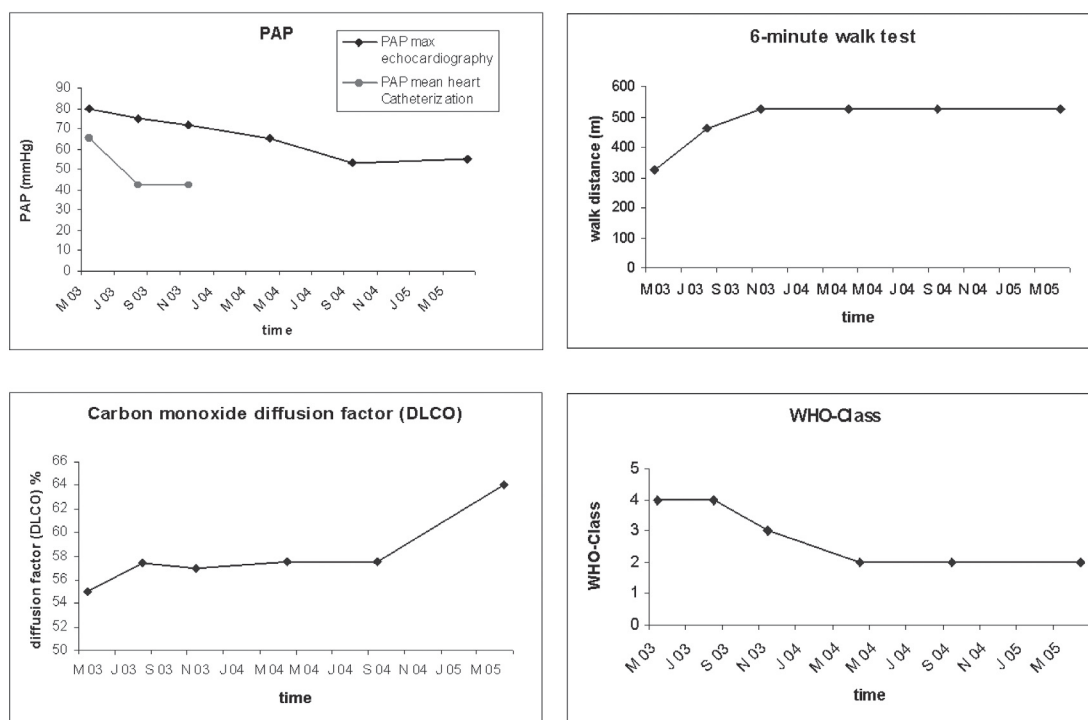
bosentan in PAH has been confirmed in two randomised double-blind studies. The efficacy of intravenous administration of epoprostenol in PAH secondary to the scleroderma spectrum of disease has been demonstrated in a large randomised open-label study in 111 patients (3). In the randomised, placebo-controlled AIR Study conducted in 203 patients, administration of inhaled iloprost led to a significant increase in the 6-minute walking distance compared with placebo and to an improvement in disease severity by one WHO functional class in 24% of patients (4). The present case report describes the rapid efficacy and sustained effect of inhaled iloprost in a female patient with severe PAH associated with collagen vascular disease.

Case report

This 61-year-old woman presented with diffuse cutaneous systemic sclerosis with Raynaud's syndrome, dermatosclerosis, arthritis, pulmonary involvement in the form of lymphocytic alveolitis (BAL: 17% CD8-positive lymphocytes) and signs of pulmonary fibrosis (HRCT: reticular abnormality and honeycombing with basal and peripheral predominance) and positive ANA and SCL70 status. In addition, she presented with a secondary ACLA syndrome (ACLA IgG-positive, history of deep leg-vein thromboses) without any signs of relevant embolism in HRCT. In April 2003, against a background of multiple recurrent cardiac decompensation, we diagnosed severe PAH (WHO functional class III with dyspnoea under light physical strain) with a mean pulmonary artery pressure (PAP) of 65 mmHg as determined by right-heart catheterisation. Vasoreactivity to NO was absent. Her 6-minute walking distance measured under controlled conditions was 325 metres. Ventilation perfusion scintigraphy of the lung excluded a thromboembolic origin for PAH. In addition, the patient had elevated liver aminotransferase values due to primary biliary cirrhosis (PBC) as diagnosed serologically. Immunosuppressive therapy was instituted with 12.5 mg methotrexate (i.v.) and 4 mg prednisolone for the patient's arthritis, lymphocytic alveolitis and PBC. Because

Competing interests: none declared.

Fig. 1. Change in key variables over the course of treatment. Top left: Reduction in PAP; top right: Increase in 6-minute walking distance; bottom left: Marked improvement in diffusion capacity; bottom right: Reduction in PAH severity.



her transaminase values were raised (to more than 3 times the upper limit of normal) due to underlying PBC, a relative contraindication was established to the use of bosentan as first-line therapy. Because of the presence of ACLA syndrome and because of a relative contraindication for the implantation of a port or catheter access required for continuous intravenous administration of epoprostenol, this therapy also could not be implemented. Treatment was therefore started with inhaled iloprost. Within a short time there was a definite improvement in the patient's general condition and physical exercise capacity. The treatment had a beneficial effect on haemodynamic variables (Fig. 1, top left panel). Initially (for the first three visits) the haemodynamic variables were monitored both invasively by right-heart catheterisation and by echocardiography. During the subsequent course of treatment as the patient's situation stabilised, monitoring was performed by echocardiography only. The 6-minute walking distance was improved to 465 metres after about 8 weeks (Fig. 1, top right panel) and dyspnoea was markedly reduced (WHO functional class III). Over time the patient managed to sustain a 6-minute walking

distance of about 525 metres. There was also a marked improvement in diffusion capacity measured over time (Fig. 1, bottom left panel). Over the ensuing two years no further cardiac decompensation was noted. The severity of PAH improved over time by two WHO functional classes (Fig. 1, bottom right panel). This patient has experienced impressive stabilisation and improvement in her initially severe PAH, coupled with a sustained improvement in her physical exercise capacity.

Discussion

According to the WHO World Symposium recommendations issued in 2003, only the endothelin receptor antagonist bosentan and the continuous intravenous administration of prostanoids are approved as first-line measures for the treatment of severe PAH (WHO functional classes III and IV). Inhaled iloprost therapy is a useful alternative in situations where bosentan is contraindicated, especially in cases of moderate to severe liver function disturbances, and because of the multiple complications associated with the administration of intravenous prostanoids (5). Positive experiences have already been reported

concerning the administration of inhaled iloprost in bosentan-refractory PAH associated with collagen vascular disease (6). Continuous intravenous administration of prostanoids is associated with numerous complications and necessitates implantation of a catheter access port, which constitutes a source of infection especially in SSc patients receiving immunosuppressive therapy. The adverse systemic effects are also not inconsiderable (7, 8). By contrast, inhaled doses of the stable prostacyclin analogue iloprost from an ultrasonic nebuliser device are deposited only in the lungs and are absorbed selectively. The adverse systemic effects are consequently far less pronounced. Inhaled iloprost has been approved in Europe since September 2003 for the treatment of idiopathic and familial pulmonary hypertension. The efficacy of inhaled iloprost therapy in pulmonary hypertension was investigated in the AIR Study. Significantly more patients in the active treatment group achieved the combined end-point (improvement by at least one WHO functional class, 10% improvement in the 6-minute walking distance, absence of further deterioration or death). Comparable efficacy has also been demonstrated with the

continuous infusion of epoprostenol or administration of bosentan (4). The AIR Study also included patients with PAH associated with appetite suppressant ingestion (n = 9), collagen vascular disease (n = 35) or chronic thromboembolic diseases (n = 57). Here too improvements were demonstrated in physical exercise capacity, the Mahler Dyspnea Index and quality of life (EuroQoL). Our case report illustrates that treatment with inhaled iloprost represents a useful alternative for PAH associated with collagen vascular disease in situations where bosentan is contraindicated.

References

1. POPE JE, LEE P, BARON M *et al.*: Prevalence of elevated pulmonary arterial pressures measured by echocardiography in a multicenter study of patients with systemic sclerosis. *J Rheumatol* 2005; 32: 1273-8.
2. DE AZEVEDO AB, SAMPAIO-BARROS PD, TORRES RM, MOREIRA C: Prevalence of pulmonary hypertension in systemic sclerosis. *Clin Exp Rheumatol* 2005; 23: 447-54.
3. KAWUT SM, TAICHMAN DB, ARCHER-CHICKO CL, PALEVSKY HI, KIMMEL SE: Hemodynamics and survival in patients with pulmonary arterial hypertension related to systemic sclerosis. *Chest* 2003; 123: 344-50.
4. BADESCH DB, TAPSON VF, MCGOON MD *et al.*: Continuous intravenous epoprostenol for pulmonary hypertension due to the scleroderma spectrum of disease. A randomized, controlled trial. *Ann Intern Med* 2000; 132: 425-34.
5. OLSCHESKI H, SIMONNEAU G, GALIE N *et al.*: Aerosolized Iloprost Randomized Study Group. Inhaled iloprost for severe pulmonary hypertension. *N Engl J Med* 2002; 347: 322-9.
6. BAKER SE, HOCKMAN RH: Inhaled iloprost in pulmonary arterial hypertension. *Ann Pharmacother* 2005; 39: 1265-74.
7. AHMADI-SIMAB K, LAMPRECHT P, GROSS WL: Successful therapy of bosentan-refractory pulmonary arterial hypertension (PAH) with inhalative iloprost. *Clin Exp Rheumatol* 2005; 23: 402-3.
8. GALIE N, MANES A, BRANZI A: Prostanoids for pulmonary arterial hypertension. *Am J Respir Med* 2003; 2: 123-37.
9. BARST RJ, RUBIN LJ, MCGOON MD, CALDWELL EJ, LONG WA, LEVY PS: Survival in primary pulmonary hypertension with long-term continuous intravenous prostacyclin. *Ann Intern Med* 1994; 121: 409-15.