

# Capillaroscopic observations in childhood rheumatic diseases and healthy controls

F. Ingegnoli, S. Zeni, V. Gerloni, F. Fantini

*Department of Rheumatology, Istituto Gaetano Pini, University of Milan, Italy*

---

## Abstract

### Objective

*To describe, by using video nailfold capillaroscopy (NFC), microvascular abnormalities in children with rheumatic diseases and to evaluate the capillary changes over a follow up period.*

---

### Methods

*118 children suffering from rheumatic diseases: 55 juvenile idiopathic arthritis (JIA), 7 mixed connective tissue disease (MCTD), 6 primary Raynaud's phenomenon (PRP), 34 systemic lupus erythematosus (SLE), 8 juvenile systemic sclerosis (JSSc) and 8 juvenile dermatomyositis (JDM) were included in the study. Patients with major capillaries abnormalities or scleroderma pattern were followed up for at least 12 months. 70 age- and sex-matched healthy controls (HC) were also examined.*

---

### Results

*In HC there was a significant correlation between age and capillary length ( $p = 0.001$ ). JIA patients showed capillary number, size, shape and arrangement similar to HC. Minor abnormalities were frequently observed. The percentage of major abnormalities were significantly increased compared to HC in MCTD ( $p = 0.008$ ), SLE ( $p = 0.0002$ ) and JDM patients ( $p < 0.0001$ ). 5/8 of JSSc had a scleroderma pattern from the onset of the disease. The serial observations in connective tissue diseases also showed that the evolution of capillaroscopic pattern was not unidirectional. In fact, in some nailfolds there was an increase in capillary loss and in avascular areas, whereas sometimes it remained stable on repeated examination.*

---

### Conclusion

*NFC can be used as a simple, inexpensive, non-invasive method to evaluate the microvascular abnormalities in childhood rheumatic conditions, and it may be useful in early recognition and monitoring scleroderma spectrum disorders.*

---

### Key words

Capillaroscopy, childhood rheumatic diseases, healthy controls.

Francesca Ingegnoli, MD; Silvana Zeni, MD; Valeria Gerloni, MD; Flavio Fantini, MD, Prof.

Please address correspondence to: Francesca Ingegnoli, MD, Department of Rheumatology, Istituto Gaetano Pini, University of Milan, Via Pini no. 9, 20122 Milan, Italy.

E-mail: francesca.ingegnoli@unimi.it

Received on July 6, 2004; accepted in revised form on October 27, 2005.

© Copyright CLINICAL AND EXPERIMENTAL RHEUMATOLOGY 2005.

## Introduction

Video nailfold capillaroscopy (NFC) can be considered an extension of the widefield technique, which allows more accurate data storing, analysis and quantification of capillary abnormalities. Basically, the nailfold region is easily accessible for the microscopic examination of the capillary network and in this area the loops are placed horizontally, allowing them to be visualized on their long axis, in children as well as in adults. NFC is widely used for the diagnosis of scleroderma spectrum disorders because of its remarkable value in the differential diagnosis of some connective tissue diseases (CTDs) primarily in the adult population; these disorders include systemic sclerosis (SSc), mixed connective tissue disease (MCTD) and dermatomyositis (1-3). Furthermore, it is well established that of all the rheumatic diseases, CTDs frequently presented characteristic nailfold capillary patterns (2), and it has been demonstrated that these capillaroscopic patterns correlate blindly with the clinical diagnosis, disease severity and prognosis in several adult CTDs (1, 4-7).

Previous studies demonstrated that CTDs cover a wide range of morphologic capillary abnormalities and may be useful in prospective evaluation of rheumatic patients as these capillary abnormalities may reflect an underlying vascular involvement (8).

Few studies exist about capillaroscopic patterns in healthy children and in pediatric rheumatic diseases, and these reports suggest that NFC may be considered a reliable method of identifying microcirculatory alterations that are associated with pediatric CTDs (9, 8). In fact, considering that the NFC technique is relatively simple, non-invasive, inexpensive and allows direct observation of the capillary network in living tissue, it may be a useful tool for the early detection of young patients who are potential candidates for developing scleroderma spectrum disorders (10). Moreover, in previous studies, age related differences in capillary parameters have been noted in healthy children (9, 11, 12).

The first aim of this study was to inves-

tigate the microvascular aspects by using NFC in a group of healthy controls (HC) made up of children, adolescents and adults. This was the starting-point to establish if children suffering from rheumatic diseases show peculiar capillary abnormalities, as occur in adults. The second purpose of our study was to ascertain NFC discriminatory value in differential diagnosis between capillary abnormalities in childhood juvenile idiopathic arthritis (JIA), juvenile SSc (JSSc) and other CTDs, such as systemic lupus erythematosus (SLE), juvenile dermatomyositis (JDM), MCTD and primary Raynaud's phenomenon (PRP). Finally, the present study was undertaken to obtain some data on the value of monitoring the capillary changes over a follow up period in childhood rheumatic diseases.

## Materials and methods

### Patients and controls

118 Italian children suffering from rheumatic diseases (90 girls and 28 boys) who attended the Pediatric Unit of Rheumatology Department at the Istituto Ortopedico Gaetano Pini (Milan, Italy) were included in the study.

As shown in Table I, the patients were divided into the following diagnostic groups: JIA (n=55); MCTD (n=7); PRP (n=6); SLE (n=34); JSSc (n=8); and JDM (n=8).

JIA patients fulfilled the classification criteria proposed by the International League of Association for Rheumatology (ILAR) (13) and they were grouped as follows: 28 oligoarthritis, 13 polyarticular and 14 systemic. SLE patients were classified according to the ACR criteria (14), the JSSc patients fulfilled the criteria proposed by the ACR (15) and the new proposed classification criteria (16), the JDM according to the Bohan and Peter criteria (17) and the MCTD group according to the Alarcón-Segovia criteria (18). None of the patients was in acute phase of disease nor took vasoactive drugs. Sequential NFC examinations were carried out for the CTDs and PRP patients with major capillaries abnormalities or scleroderma pattern. These patients were followed up for at least 12 months (mean  $52.3 \pm 40.6$ ; range 12-168 months).

**Table I.** Main demographic characteristics of the study population.

Groups	Pt. no.	Sex (M/F)	Mean age $\pm$ SD (yrs.)	Range (yrs.)
Adult HC	20	7/13	39.2 $\pm$ 9.53	24 - 57
Childhood HC	50	25/25	9 $\pm$ 3.27	2 - 16
JIA				
Oligoarthritis	28	7/21	10.7 $\pm$ 4.75	3 - 16
Polyarticular (RF negative)	9	3/6	10.5 $\pm$ 2.06	7-13
Polyarticular (RF positive)	4	1/3	13.6 $\pm$ 2.08	10 - 16
Systemic	14	7/7	11.9 $\pm$ 3.95	4 - 16
MCTD	7	1/6	15.8 $\pm$ 3.38	9 - 18
PRP	6	1/5	15.1 $\pm$ 1.83	13 - 17
SLE	34	3/31	14.5 $\pm$ 3.08	5 - 17
JSSc	8	2/6	11.2 $\pm$ 2.06	9 - 14
JDM	8	3/5	12.0 $\pm$ 4.06	7 - 18

HC: healthy controls; JIA: juvenile idiopathic arthritis; RF: rheumatoid factor; MCTD: mixed connective tissue disease; SLE: systemic lupus erythematosus; JSSc: juvenile systemic sclerosis; JDM: juvenile dermatomyositis; PRP: primary Raynaud's phenomenon.

70 age- and sex-matched HC were also examined (Table I). The subjects were divided into the following two groups: 1) 50 children recruited from one local primary and secondary school; 2) 20 adults from staff members from the Department of Rheumatology, Istituto Ortopedico Gaetano Pini, Milan.

Appropriate informed consent was obtained from each person or parent at the time of examination.

#### *Nailfold capillaroscopy technique and image analysis*

All observations were performed with the subjects in a comfortable environmental temperature (from 22°C to 25°C). Briefly, to examine nailfold capillaries the patient was placed in a sitting position, either alone or on the parent's lap as appropriate, with the hand at heart level. The equipment was ex-

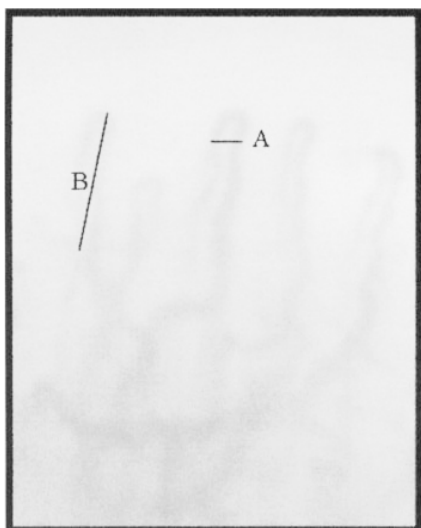
plained to the child and a drop of immersion oil was applied to the nailfold to maximize the translucency of the keratin layer. Every finger of both hands was examined, paying greater attention to the ring finger of the non dominant hand. NFC was performed using a video-capillaroscopy provided with an optic probe of 200x (Moritex Video Microscope System Scopeman Model MS-500). Images were subsequently captured, coded and stored through a Videocap 8.14 software. In order to minimize observer bias, the images taken at the time of examination were coded and subsequently analysed both by the first observer (S.Z.) and a second observer (F.I.).

We captured all the areas of the nailfold in which there was good capillary visibility and the evaluation of capillaroscopic images was based on qualitative

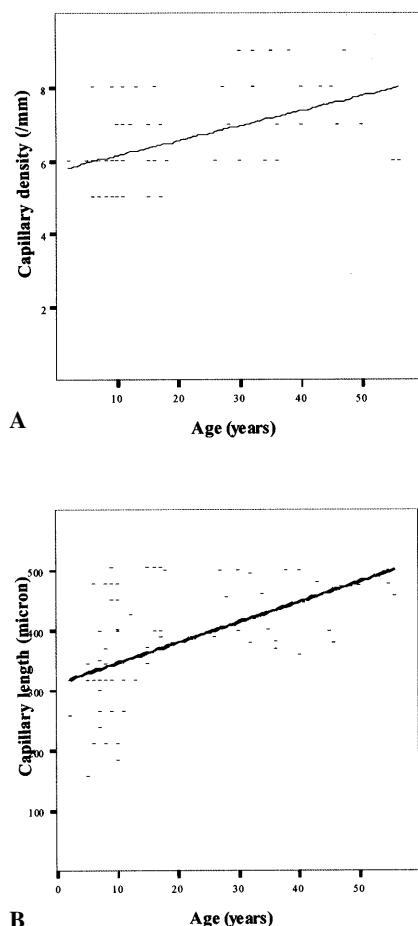
and quantitative parameters. As can be seen in Table II, the overall capillaroscopic patterns were defined as: normal (6-8 capillaries/mm, capillaries length between 200-500 $\mu$ , hairpin-shaped loops arranged in parallel rows, absence of hemorrhages), minor abnormalities (6-8 capillaries/mm, less than 10% of the total loops can be longer than normal, less than 50% can be tortuous loops, arranged in parallel rows, with the absence of hemorrhages), major abnormalities (normal or decreased capillary density, more than 10% of the total loops can be longer than normal, more than 50% can be tortuous, enlarged, meandering, branched loops, disarranged, with the presence hemorrhages), and scleroderma pattern (decreased number of capillaries, more than 10% of the total loops can be longer than normal, tortuous, branched, bushy,

**Table II.** Nailfold capillaroscopic patterns.

Patterns	Density (capillaries/mm)	Length (microns)	Capillary parameters Capillary shape	Capillary arrangement	Pathologic hemorrhages
Normal	6-8/mm	200-500 $\mu$	Hairpin	Parallel rows	–
Minor abnormalities	6-8/mm	Elongated < 10%	Tortuous < 50%	Parallel rows	–
Major abnormalities	$\leq$ 6-8/mm	Elongated > 10%	Tortuous > 50%, enlarged, meandering, branched	Disarrangement	-/+
Scleroderma pattern	< 6/mm	Elongated > 10%	Tortuous, branched, enlarged, bushy, giant	Disarrangement, with or without avascular areas	++



**Fig. 1.** Measurement performed on nailfold capillaries: loop width (A) and length (B).



**Fig. 2.** Linear capillary density and length in healthy population. (A) Linear capillary density (capillary number/mm) did not vary significantly with age ( $r = 0.226$ ;  $p = 0.15$ ); (B) HC had significantly increased capillary length with age ( $r = 0.485$ ;  $p = 0.001$ ).

enlarged, giant, disarranged, presence of hemorrhages).

To evaluate the reproducibility and the repeatability of our classification of capillaroscopic findings we measured agreement between the two observers (S.Z. and F.I.) using the Cohen's kappa ( $k=0.85$ ). This result means that there is good agreement between the two observers in the overall evaluation of capillaroscopic pattern.

#### *Classification of capillaroscopic findings*

The following characteristics of the nailfold capillaries were registered for each child in this study: 1) capillary density (number of loops in the terminal capillary row per mm); 2) size of a representative loop (width of loop, measurement across the loop's widest aspect, and its length was measured) (Fig. 1); 3) capillary shape (presence of tortuous, meandering, branched, enlarged, giant, or "bushy" capillary loops); 4) capillary arrangement (parallel rows with the transitional limb pointing towards the distal end of the finger, disarrangement when this parallel pattern of nailfold loops is lost); 5) avascular areas were considered present when two or more capillaries were missing in a certain area of the distal row compared to the density of capillaries in the remainder of the row (19, 20); and 6) the presence of "pathologic" hemorrhages (over the top or around the whole length of the capillary).

#### *Statistical analyses*

The statistical significance for the various associations was calculated using the  $\chi^2$  analyses or Fisher's exact test, whichever was appropriate.

### **Results**

#### *Capillaroscopic parameters in healthy population*

NFC images of 70 HC (50 children and 20 adults) were examined in this study. The mean capillary density was 6.1 loops/mm (range 5–8) in healthy children, while in healthy adults it was 7.3 loops/mm (range 6–8). As shown in Figure 2A, the number of capillaries per millimetre increased progressively

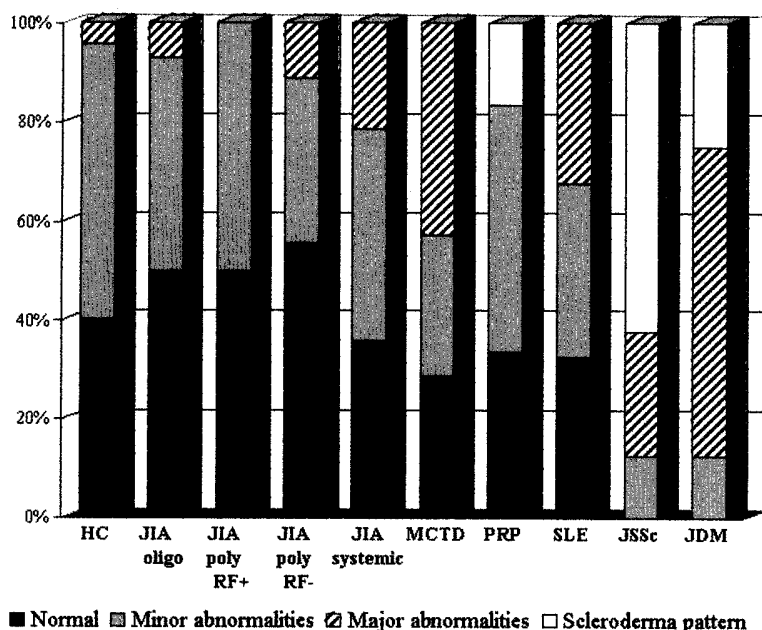
in relation to age, but this trend did not reach statistical significance ( $R = 0.226$ ;  $p=0.15$ ). Data were subsequently analysed comparing the length of capillaries in children and adults HC. As can be seen in Figure 2B, there was a significant correlation between age and capillary length ( $R = 0.485$ ;  $p = 0.001$ ). The mean capillary length was  $341.04 \mu\text{m}$  (range 159–500) in healthy children and  $442.77 \mu\text{m}$  (range 359–500) in adults.

Microhemorrhages grouped within limited areas were observed in 7/70 cases (10%). Capillary loops were arranged in parallel rows in all the individuals tested. Finally, normal NFC pattern was observed in 28/70 (40%), minor abnormalities were noted in 39/70 (55.7%) and major capillary abnormalities were present in 3/70 (4.3%). None of these subjects had a scleroderma pattern (Fig. 3).

#### *Capillaroscopic parameters in children suffering from JIA*

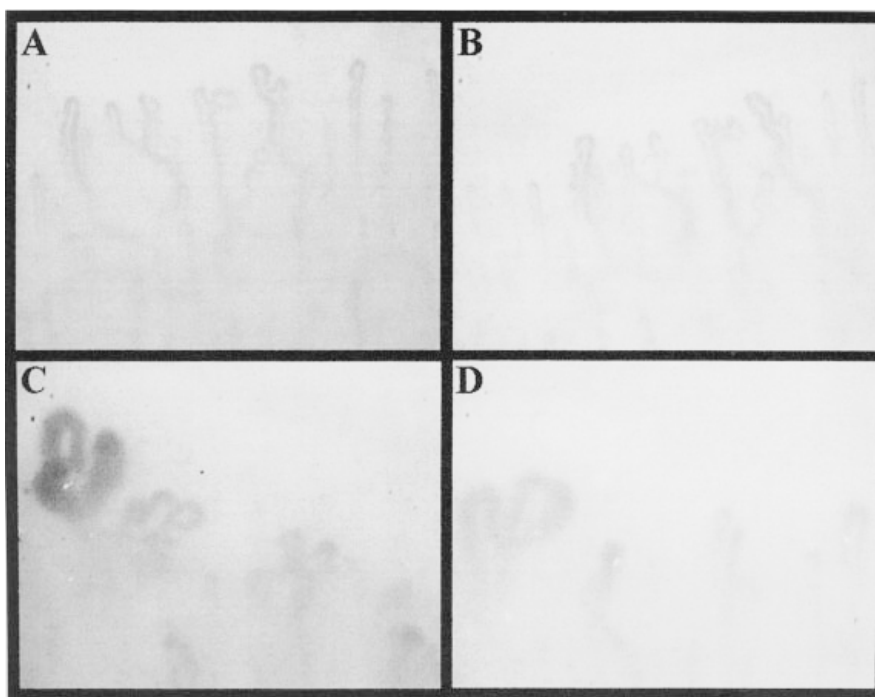
NFC findings were examined in 55 children suffering from JIA. The capillary number, size, shape and arrangement were similar to HC. Minor abnormalities, characterized by an increased tortuosity of loops and major abnormalities which consist of branched loops were observed, however no specific pattern was observed.

Data were further analysed upon dividing patients according to ILAR classification criteria; similar prevalence of capillaroscopic patterns was observed in each group. As can be seen in Figure 3, normal capillaroscopic pattern was observed in 14/28 (50.0%) of patients with oligoarthritis, in 2/4 (50%) of polyarthritis rheumatoid factor (RF) positive, in 5/9 (55.56%) of polyarthritis RF negative and in 5/14 (35.7%) of systemic disease. Minor abnormalities were present in 12/28 (42.9%) of oligoarthritis, in 2/4 (50%) of polyarthritis RF positive, in 3/9 (33.33%) of polyarthritis RF negative and in 6/14 (42.9%) of systemic JIA. Major abnormalities were noted in 2/28 (7.1%) of oligoarthritis, in 1/9 (11.11%) of polyarthritis RF negative and in 3/14 (21.4%) of systemic onset. None of these patients had scleroderma pattern.



**Fig. 3.** Distribution of nailfold capillaroscopic pattern in healthy controls and study groups at the time of the first examination.

HC: healthy controls; JIA: juvenile idiopathic arthritis; RF: rheumatoid factor; MCTD: mixed connective tissue disease; SLE: systemic lupus erythematosus; JSSc: juvenile systemic sclerosis; JDM: juvenile dermatomyositis; PRP: primary Raynaud's phenomenon.



**Fig. 4.** Nailfold vascular pattern at the time of the first visit and after a year follow up. (magnification x200). (A) SLE capillary pattern characterized by branched loops and prominent subpapillary venular plexus (B) the same capillaroscopic pattern was present a year later; (C) JDM on the first examination showed enlargement of isolated loop and meandering capillaries (D) the same nailfold a year later, showed decreased number of meandering loops.

#### Capillaroscopic parameters and follow-up in children suffering from CTDs and PRP

NFC images of 63 children suffering

from CTDs (7 MCTD, 34 SLE, 8 JSSc, 8 JDM) and 6 PRP were also analysed (Fig. 3).

No significant differences in the capil-

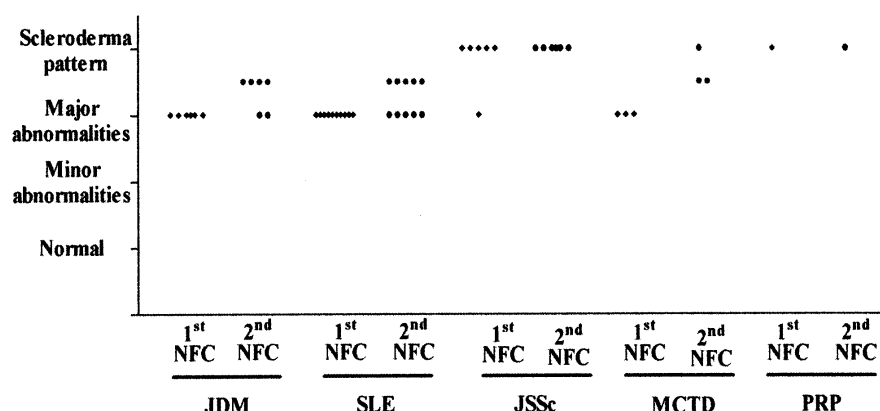
lary number and arrangement, between MCTD patients and HC, were noted; whereas the percentage of major abnormalities were significantly increased in MCTD patients compared to HC ( $p = 0.008$ ). These capillary abnormalities were characterized by loop elongation, dilatation of the venular branch, increased tortuosity and branched.

Six young patients with PRP were also studied; one of them had a typical scleroderma pattern and in all the other cases the capillary number, size, shape and arrangement were similar to HC.

We could not find any significant difference between SLE and HC regarding capillary density, length and arrangement. On the other hand, major morphologic loop abnormalities, characterized by elongated, tortuous loops, were significantly increased in this group ( $p = 0.0002$ ). None of these patients had a scleroderma pattern.

We also observed NFC images of 8 children suffering from JSSc, 5 of them had a scleroderma pattern from the onset of the disease. Capillary density was lower than HC, loops appeared with irregular length, bushy or giant enlarged shapes. There were pathologic hemorrhages and avascular areas. Minor abnormalities pattern was present in 1/8 (12.5%), and major abnormalities were noted in 2/8 (25%). None of these patients had a normal pattern. NFC examination, in the group of children suffering from JDM, demonstrated a significant increase of major capillary abnormalities ( $p < 0.0001$ ), such as elongated, enlarged, giant and bushy loops.

In order to explore whether qualitative and quantitative NFC findings were changing over a follow up period, capillaroscopic follow-up was carried out on 26 children suffering from CTDs (10 SLE, 6 JDM, 6 JSSc and 3 MCTD) and one child with PRP who all showed major capillary abnormalities or scleroderma pattern. During the follow up period, 8/26 (30.8%) of patients with major abnormalities pattern (1 PRP, 5 SLE and 2 JDM), did not show any changes in their capillary findings (Fig. 4A-B). In 11/26 (42.3%) of children with major abnormalities (5 SLE, 4 JDM and 2 MCTD) and in 5/26 (19.23%) of



**Fig. 5.** Nailfold capillaroscopy follow up in 26 patients who showed major capillary abnormalities or scleroderma pattern at the time of the first examination.

NFC: nailfold capillaroscopy; JDM: Juvenile dermatomyositis; SLE: Systemic Lupus Erythematosus; JSSc: Juvenile Systemic Sclerosis; MCTD: Mixed Connective Tissue Disease; PRP: primary Raynaud's phenomenon.

subjects with scleroderma pattern (5 JSSc) at the time of the first examination, NFC sequential examinations showed the same overall pattern, but with modification in the number of morphologic abnormalities and progressive disorganization of the capillary bed (Fig. 4C-D). Particularly, NFC follow-up, in all patients with a scleroderma pattern, showed a progressive disarrangement, decreased capillary density and increased number of avascular areas. Evidence of progression towards a scleroderma pattern was noted in 2/26 (7.7%) of patients (1 JSSc and 1 MCTD). None of the SLE patients developed a scleroderma pattern in the follow up period (Fig. 5).

## Discussion

We investigated some capillaroscopic parameters in children with either JIA or CTDs to better define the microvascular abnormalities underlying these rheumatic conditions. In this report we also analyse whether NFC findings were changing over a follow up period. In this study we found that: 1) there was a significant correlation between age and capillary length and the overall capillary patterns in healthy children are similar to those of healthy adults; 2) minor abnormalities, characterized by an increased tortuosity of loops were frequently noted in JIA, however no specific pattern was observed; 3) CTD capillary abnormalities are similar,

both in frequency and morphology, in children and adults; 4) during the follow-up period, NFC changes were noted in the majority of young patients, but other studies will be needed to ascertain the importance of these observations within a clinical and therapeutic setting.

Previous reports have confirmed that there is a progressive increase of capillary density and a significant increase of length, but there was relatively high variability between different authors on capillaroscopic parameters in healthy children, this may be due to physiological differences of the nailfold vasculature itself and different methods of NFC analyses (9, 12, 21). Previous studies have focused on subpapillary venular plexus visibility (3, 12, 21), but it probably does not depend on age, and it is influenced by the integrity of the cuticle. Furthermore, this parameter is unreliable for the testing of children because of onychophagia and lesions while playing.

Our observations of aspecific overall capillaroscopic patterns in JIA patients, characterized by normal capillary number, size, shape and arrangement was in agreement with similar studies in children (8, 9). These data were further confirmed after having divided patients according to articular involvement, in fact similar capillaroscopic patterns were observed in each group.

Another objective of our study was to

investigate whether NFC had a diagnostic potential in childhood CTDs, as occurs in adult CTDs (4-6, 22, 23).

Our data on MCTD patients confirm that patterns with major abnormalities were present in 42,85% of these children, but without specific capillary abnormalities; this percentage was similar to the one in adult MCTD (2, 4).

A NFC test of juvenile SLE revealed a variety of bizarre capillary abnormalities, both specific and non-specific, as described in adult SLE (2, 22, 23). In fact, also in this group of patients we could not find an overall characteristic pattern.

Although PRP NFC changes were minor and non-specific, we observed scleroderma pattern in a child (monitored for more than a year) who did not develop scleroderma, but because of these findings closer attention will be made in the follow up of this patient.

In children SSc is a very rare disease (16), and scleroderma patterns were noted in the majority of young patients with SSc, as reported in adult SSc. Scleroderma patients show very characteristic abnormalities: giant loops, avascular areas, pathologic haemorrhages, confirming that NFC examination may have predictive and diagnostic value (24).

The serial observations in CTDs patients also showed that the evolution of capillaroscopic pattern was not unidirectional. In fact, in some nailfolds there was an increase in capillary loss and in avascular areas, whereas sometimes it remained stable on repeated examination. Interestingly, during the follow-up period, NFC changes (loss of capillaries, increased number of avascular areas and haemorrhages) were noted in child and adult patients with scleroderma spectrum disorders (4).

Moreover, our findings in JDM confirmed reported data indicating that these capillary abnormalities are the most striking of all CTDs (17, 25). As described in previous studies, in these patients loop abnormalities were found to correlate with a more severe clinical course and outcome, calcinosis and ulcerative complications (26-28), and these characteristic morphologic abnormalities have been correlated with

the microangiopathy present in muscle biopsy (29).

In conclusion, video NFC is an extension of the widefield technique examination, has advantages and disadvantages as we have seen. This method has limitations such as taken good results depend on skin transparency and integrity of the nail cuticle. The interpretation of results correlate with the observer experience and thus subjective. On the whole, the advantages of NFC far outweigh the disadvantages. For example, it allows individual capillaries to be measured and therefore abnormalities to be quantified. In addition, images can be stored for later analysis or reanalysis. It is a simple, non-invasive, reproducible and inexpensive diagnostic method that allows *in vivo* study of the capillary network in childhood rheumatic diseases.

## References

1. KENIK JG, MARICQ HR, BOLE GG: Blind evaluation of the diagnostic specificity of nailfold capillary microscopy in the connective tissue diseases. *Arthritis Rheum* 1981; 24: 885-91.
2. MARICQ HR, MAIZE JC: Nailfold capillary abnormalities. *Clin Rheum Dis* 1982; 8: 455-78.
3. KABASAKAL Y, ELVINS DM, RING EFJ, MCHUGH NJ: Quantitative nailfold capillaroscopy findings in a population with connective tissue disease and in normal healthy controls. *Ann Rheum Dis* 1996; 55: 507-12.
4. MARICQ HR, LEROY EC, D'ANGELO WA *et al.*: Diagnostic potential of *in vivo* capillary microscopy in scleroderma and related disorders. *Arthritis Rheum* 1980; 23: 183-189.
5. BLOCKMANS D, BEYENS G, VERHAEGHE R: Predictive value of nailfold capillaroscopy in the diagnosis of connective tissue diseases. *Clin Rheumatol* 1996; 15: 148-53.
6. ZUFFEREY P, DEPAIRON M, CHAMOT AM, MONTI M: Prognostic significance of nailfold capillary microscopy in patients with Raynaud's phenomenon and scleroderma-pattern abnormalities. A six-year follow-up study. *Clin Rheumatol* 1992; 11: 536-41.
7. LOVY M, MACCARTER D, STEIGERWALD JC: Relationship between nailfold capillary abnormalities and organ involvement in systemic sclerosis. *Arthritis Rheum* 1985; 8: 496-501.
8. SPENCER-GREEN G, SCHLESINGER M, BOVE KE *et al.*: Nailfold capillary abnormalities in childhood rheumatic diseases. *J Pediatr* 1983; 102: 341-6.
9. DOLEZALOVA P, YOUNG SP, BACON PA, SOUTHWOOD TR: Nailfold capillary microscopy in healthy children and in childhood rheumatic diseases: a prospective single blind observational study. *Ann Rheum Dis* 2003; 62: 444-9.
10. CARPENTIER P, JEANNOEL P, BOST M, FRANCO A: La capillaroscopie péri-unguëale en pratique pédiatrique. *Pédiatrie* 1988; 43: 165-9.
11. HERRICK AL, MOORE T, HOLLIS S, JAYSON MIV: The influence of age on nailfold capillary dimensions in childhood. *J Rheumatol* 2000; 27: 797-800.
12. TERRERI MTRA, ANDRADE LE, PUCCINELLI L, HILARIO MOE, GOLDENBERG J: Nail fold capillaroscopy: normal findings in children and adolescents. *Semin Arthritis Rheum* 1999; 29: 36-42.
13. PETTY RE, SOUTHWOOD TR, BAUM J *et al.*: Revision of the proposed classification criteria for juvenile idiopathic arthritis: Durban 1997. *J Rheumatol* 1998; 25: 1991-4.
14. TAN EM, COHEN AS, FRIES JF *et al.*: The 1982 revised criteria for the classification of systemic lupus erythematosus. *Arthritis Rheum* 1982; 25: 1271-7.
15. SUBCOMMITTEE FOR SCLERODERMA CRITERIA OF THE AMERICAN RHEUMATISM ASSOCIATION DIAGNOSTIC AND THERAPEUTIC CRITERIA COMMITTEE: Preliminary criteria for the classification of systemic sclerosis (scleroderma). *Arthritis Rheum* 1980; 23: 581-90.
16. FOELDVARI I: Scleroderma in children. *Curr Opin Rheumatol* 2002; 14: 699-703.
17. BOHAN A, PETER JB: Polymyositis and dermatomyositis (first of two parts). *N Engl J Med* 1975; 292: 344-7.
18. ALARCON-SEGOVIA D, VILLAREAL M: Classification and diagnostic criteria for mixed connective tissue disease. In KAASUKAWA R and SHARP G (Eds.): *Mixed Connective Tissue Disease and Antinuclear Antibodies*. Amsterdam, Excerpta Medica 1987; 33.
19. JONES BF, MORRIS CW, RING EF: A proposed taxonomy for nailfold capillaries based on their morphology. *IEEE* 2001; 20: 333-41.
20. HOUTMAN PM, KALLENBERG CGM, FIDLER V, WOUDA AA: Diagnostic significance of nailfold capillary patterns in patients with Raynaud's phenomenon. *J Rheumatol* 1986; 13: 556-63.
21. CONY M, KLENE-BOUDARD C, FONTAN I *et al.*: Etude des aspects capillaroscopiques péri-unguëaux chez l'enfant normal. *Arch Fr Pédiatr* 1992; 49: 171-4.
22. REDISCH W, MESSINA EJ, HUGHES G, MC-EWEN C: Capillaroscopic observations in rheumatic diseases. *Ann Rheum Dis* 1970; 29: 244-52.
23. MARICQ HR, LEROY EC: Pattern of finger capillary abnormalities in connective tissue disease by "wide-field" microscopy. *Arthritis Rheum* 1973; 16: 619-28.
24. JOYAL F, CHOQUETTE D, ROUSSIN A, LEVINGTON C, SENECAJL: Evaluation of the severity of systemic sclerosis by nailfold capillary microscopy in 112 patients. *Angiology* 1992; 43: 203-10.
25. NUSSBAUM AI, SILVER RM, MARICQ HR: Serial changes in nailfold capillary morphology in childhood dermatomyositis. *Arthritis Rheum* 1988; 26: 1169.
26. SILVER RM, MARICQ HR: Childhood dermatomyositis: serial microvascular studies. *Pediatrics* 1989; 83: 278-83.
27. SPENCER-GREEN G, CROWE WE, LEVINSON JE: Nailfold capillary abnormalities and clinical outcome in childhood dermatomyositis. *Arthritis Rheum* 1982; 25: 954-8.
28. RAMANAN AV, FELDMAN BM: Clinical outcomes in juvenile dermatomyositis. *Curr Opin Rheumatol* 2002; 14: 658-62.
29. SPENCER-GREEN G, CROWE WE, BOVE KE: Correlation of muscle angiopathy with nailfold capillary abnormalities in childhood dermatomyositis. *Bibl Anat* 1981; 20: 702-7.