

Favorable outcomes with tacrolimus in two patients with refractory interstitial lung disease associated with polymyositis/dermatomyositis

S. Ochi, T. Nanki, K. Takada,
F. Suzuki, Y. Komano,
T. Kubota¹, N. Miyasaka

Department of Medicine and
Rheumatology, Graduate School,
¹Graduate School of Health Sciences,
Tokyo Medical and Dental University,
Tokyo, Japan.

Sae Ochi, MD; Toshihiro Nanki, MD,
PhD, Assistant Professor; Kazuki Takada,
MD, MHS, Assistant Professor; Fumihito
Suzuki, MD; Yukiko Komano, MD; Tetsuo
Kubota¹, MD, PhD, Associate Professor;
Nobuyuki Miyasaka, MD, PhD, Professor.
Please address correspondence and reprint
requests to: Nobuyuki Miyasaka, MD,
PhD, Department of Medicine and
Rheumatology, Graduate School, Tokyo
Medical and Dental University, 1-5-45,
Yushima, Bunkyo-ku, Tokyo, 113-8519
Japan.

E-mail: miya.rheu@tmd.ac.jp

Received on November 29, 2004; accepted
in revised form on June 24, 2005.

© Copyright CLINICAL AND EXPERIMENTAL
RHEUMATOLOGY 2005.

Key words: Polymyositis,
dermatomyositis, interstitial lung
disease, tacrolimus.

ABSTRACT

Two cases of progressive interstitial lung disease associated with polymyositis/dermatomyositis are presented. Both patients were refractory to conventional therapy with high-dose corticosteroids, cyclosporine, and intermittent pulse cyclophosphamide, and thus a therapeutic trial of tacrolimus was instituted. Tacrolimus was markedly effective in achieving subjective, laboratory and radiographic improvement in both patients.

Introduction

Polymyositis (PM) and dermatomyositis (DM) are systemic autoimmune diseases which principally target the skeletal muscle and, in the latter, skin. Frequently, the diseases target other sites as well, and manifest Raynaud's phenomenon, vasculopathy, arthritis, cardiomyopathy and interstitial lung disease (ILD). ILD complicates PM/DM frequently (5-40%) and accounts for a significant proportion of the morbidity and mortality of affected patients because of the resistance to therapy. Therapeutic approaches conventionally begin with corticosteroids, to which about 50% of affected patients has been estimated to respond favorably (1,2). If they fail, immunosuppressive drugs such as cyclophosphamide and cyclosporine are employed, but their efficacy is supported only by retrospective case collections or open trials (3-6).

Tacrolimus is a relatively new immunosuppressive drug that inhibits T-cell activation and proliferation (7), and is indicated for the prophylaxis against rejections after organ transplantation. Recently, tacrolimus has been used also in several autoimmune diseases with success, and is suggested to offer a novel strategy to the management of autoimmune diseases resistant to corticosteroids (8, 9).

We report 2 PM/DM patients with ILD refractory to prednisolone, cyclosporine, and intermittent pulse cyclophosphamide, who responded favorably to tacrolimus.

Case reports

Case 1

A 69-year-old previously healthy

woman was referred to the Tokyo Medical and Dental University Hospital in March, 2002, with a 6-month history of rash over the hands and gradually worsening exertional dyspnea accompanied by dry cough. Examination revealed fine crackles over the bilateral lower lung fields, proximal muscle weakness in all four extremities, violaceous papules over her elbows, knees, and proximal interphalangeal and metacarpophalangeal joints, and small fingertip ulcers. Although myogenic enzymes were not elevated (CPK 112 U/L, aldolase 6.1 U/L) and anti-Jo-1 antibody was negative, electromyogram revealed the myogenic pattern and muscle biopsy showed perivascular infiltration of inflammatory cells, which are compatible with DM. Computed tomography (CT) of the chest demonstrated subpleural reticulolinear densities in the mid-to-lower fields of both lungs and occasional areas of ground glass opacities (Fig. 1A). The alveolar-arterial oxygen gradient (AaDO₂) was 21.4 mmHg and serum KL-6 level was 1,010 U/mL (< 500 U/mL). Serum level of KL-6, a glycoprotein produced by type II alveolar cells, is known to reflect the extent of injury of the pulmonary interstitium (10) and is routinely measured for the assessment of ILD in Japan.

She was thus diagnosed with DM associated with active ILD, and was started on a high-dose prednisolone (Predonine®, Shionogi & Co., Ltd.) therapy (1 mg/kg/day). Her disease however remained active and, although cyclosporine (Neoral®, Novartis Pharmaceuticals) was subsequently added (doses adjusted for a target trough level of 100-200 ng/mL), it progressed with AaDO₂ widening to 28 mmHg and KL-6 increasing to 1150 U/mL (Fig. 1D). Cyclosporine was therefore discontinued, and a cyclophosphamide (Endoxan®, Shionogi & Co., Ltd.) pulse (500 mg) was administered, following which she suffered from prolonged lymphopenia (<100/μL) and developed *Pneumocystis jiroveci* pneumonia (PCP).

Upon the resolution of PCP with a sulfamethoxazole-trimethoprim (Baktar®, Shionogi & Co., Ltd.) therapy and after informed consent was obtained, tacrolimus (Prograf®, Fujisawa Pharmaceu-

tical) was started with its dose adjusted for a target whole-blood trough level of 5 ng/mL. Within 2 weeks after the start of tacrolimus, she experienced a significant improvement in dyspnea, and levels of AaDO₂ and KL-6 decreased dramatically without any significant adverse effects (Fig. 1D). Percent vital capacity (%VC) and percent diffusion capacity of carbon monoxide (%DLCO) improved from 57.9% and 35.9% when tacrolimus was started to 87.9% and 55.6% at 9 months, and to 103.5% and 75.8% at 18 months, respectively. Repeat CT in 5 and 14 months revealed a remarkable diminution of subpleural reticulolinear densities (Figs. 1B and 1C). Doses of prednisolone could be uneventfully tapered down to a maintenance dose of 5mg/day over the following 10 months, and she has remained in remission on tacrolimus over a total of 24 months till now.

Case 2

A 56-year-old woman initially developed, in 1998, symmetrical proximal muscle weakness accompanied by elevated CPK and positive anti-Jo-1 antibody. She was diagnosed with PM and responded very well to prednisolone. In March, 2000, she started to have exertional dyspnea and was referred to our hospital. Physical examination revealed fine crackles over the bilateral lower lung fields and proximal muscle weakness of all extremities. Serum CPK was 2.260 U/L and partial pressure of oxygen in arterial blood (PaO₂) was 58 mmHg. Chest CT revealed intense subpleural reticulolinear densities in the lower lung fields of both lungs. She was thus diagnosed with PM relapse complicated by newly developed ILD. Pulse methylprednisolone (Solu-Medrol®, Pfizer Japan Inc.) (500 mg for 3 days) was administered, followed by

prednisolone 30 mg/day and cyclosporine, but her respiratory condition worsened over the next 6 weeks. Cyclosporine was therefore switched to intermittent pulse cyclophosphamide (500mg) to which she responded, and subsequently a total of 16 cyclophosphamide pulses were administered over the following 22 months. However, in 2 months after the last pulse was given in March, 2002, dyspnea and muscle weakness worsened with PaO₂ 77 mmHg, KL-6 1.250 U/L, and CPK 459U/L. After informed consent was obtained, 3 mg/kg/day of tacrolimus was started with its whole-blood trough levels maintained at approximately 5 ng/mL. Exertional dyspnea and muscle weakness began to improve, and levels of CPK and KL-6 significantly decreased and PaO₂ improved over the following 6 months (Fig. 2C). Radiographically, subpleural reticulolinear densities markedly diminished (Figs. 2A, 2B). Prednisolone was continued at a maintenance dose.

Discussion

Association of ILD significantly impacts on survival of PM/DM patients (11) and, in one report, 5-year survival was 60.4% (12). Nevertheless, there is currently no established therapy for this grave complication. Conventionally, high-dose corticosteroids therapy is employed first and, although no controlled trials have been undertaken to show its efficacy, about 50% of recipients have been estimated to respond favorably (1,2). To those patients who fail to or cannot tolerate high-dose corticosteroid therapy, use of other immunosuppressive agents is necessitated. Intermittent pulse cyclophosphamide therapy is used to control various intractable autoimmune diseases, such as proliferative lupus nephritis (13), and several case reports and case series demonstrated successes with this therapy in controlling "rapidly progressive" or refractory ILD in PM/DM (3, 14, 15). Although the precise etiology of ILD in PM/DM remains unknown, accumulating evidence now suggests that activated T cells may play essential roles in the pathogenesis and thus cultivated interests in applying T cell-specific im-

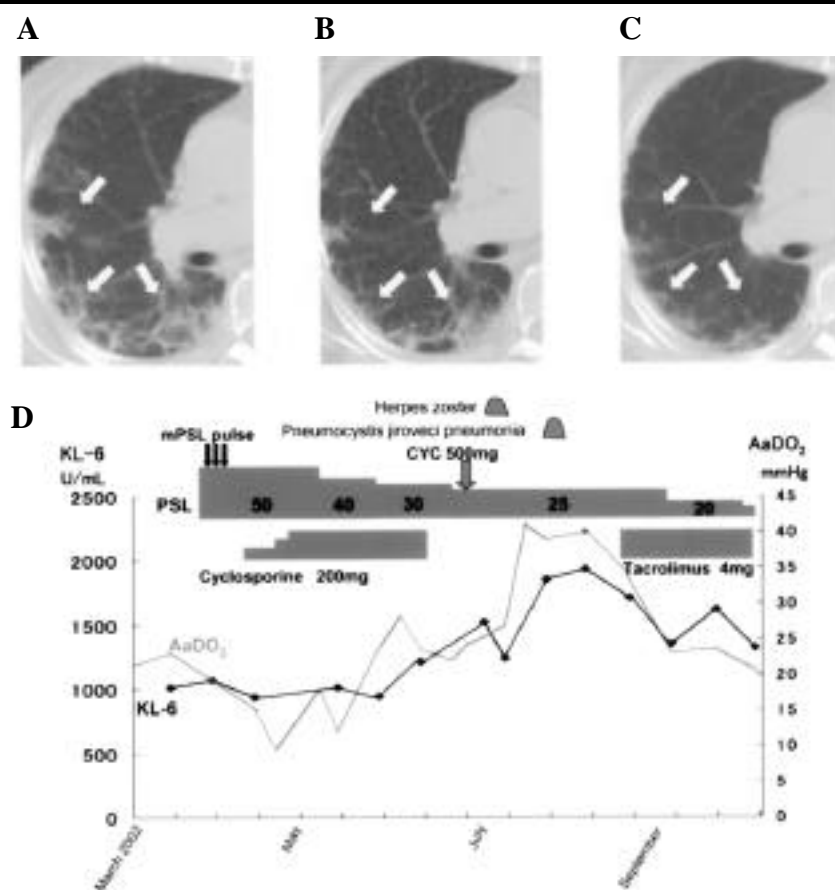


Fig. 1. Changes in radiographic findings and clinical course of patient 1. High-resolution computed tomography (CT) of the chest showed subpleural reticulolinear densities (arrows) in the mid-to-lower lung fields (A). Repeat CT taken 5 (B) and 14 (C) months after the initiation of tacrolimus treatment showed a remarkable diminution of subpleural reticulolinear densities (arrows). Clinical course (D). MPS: Methylprednisolone; PSL: prednisolone; CYC: cyclophosphamide.

munosuppressive agents for the treatment of this refractory condition. Most commonly employed among them is cyclosporine, and retrospective analyses of small (4, 5, 16) and relatively large cohorts (6), all reported from Japan, suggested its efficacy as well as its favorable safety profile. These therapies however warrant further, prospective, investigation.

Tacrolimus is a macrolide immunosuppressive drug that inhibits T-cell activation and proliferation in a manner that is strikingly similar to that of cyclosporine, and is currently indicated for the prophylaxis against rejections after organ transplantation. Recently, efficacy of tacrolimus has been also shown in several autoimmune diseases, most extensively in rheumatoid arthritis (9), and provided motives for using tacrolimus in treating refractory ILD in PM/DM.

Oddis *et al.* (17) were the first to report experiences with tacrolimus in PM/DM patients with ILD. In their report, 3 of 5 anti-Jo-1 antibody-positive PM patients with active ILD improved and another patient had the disease stabilized. Subsequently, they performed more comprehensive retrospective review of a total of 13 PM/DM patients with ILD who had failed corticosteroids and at least one other immunosuppressive agent, and reported significant improvement in pulmonary function when treated with tacrolimus for an average of 51.2 months (18).

Our patients had ILD that were resistant to cyclosporine, and the one developed PCP due to immunosuppression induced by pulse cyclophosphamide while the other flared despite receiving pulse cyclophosphamide. In both patients, tacrolimus resulted in significant improvement in symptoms, gas exchange, radiographic findings, and serum KL-6 levels without showing any adverse effects. Tacrolimus also allowed corticosteroid tapering in case 1. Serum trough levels of tacrolimus were carefully monitored during the treatment and maintained at approximately 5 ng/ml. Our experience thus concurs with those of Oddis and suggest that tacrolimus may be effective for ILD associated with PM/DM. Furthermore,

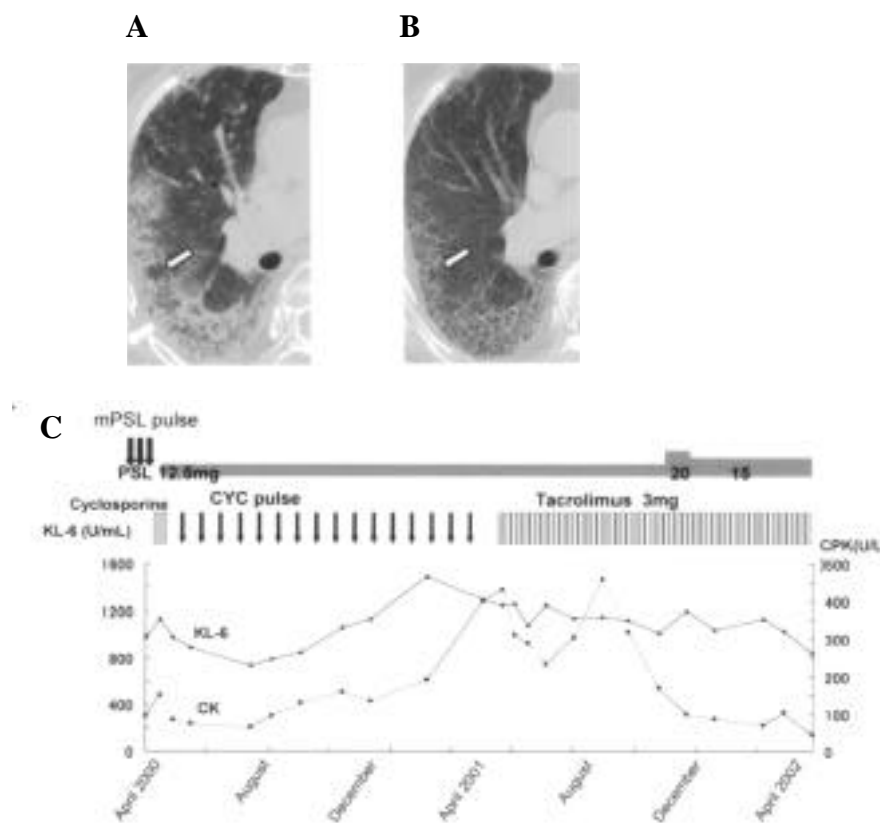


Fig. 2. Changes in radiographic findings and clinical course of patient 2. High-resolution CT of the chest showed intense subpleural reticulolinear densities in the lower lung fields (A). Repeat CT taken 6 months after the initiation of tacrolimus treatment (B) showed that subpleural reticulolinear densities (arrows) diminished significantly. Clinical course (C).

our experience is unique in showing that those patients who were refractory to cyclosporine responded well to tacrolimus. While both tacrolimus and cyclosporine inhibit the phosphatase activity of calcineurin on the nuclear factor of activated T cells (NFAT), the potency of tacrolimus in inhibiting *in vitro* T-cell activation and proliferation is up to 100 times greater than that of cyclosporine (7). Indeed, numerous studies in animal models and human clinical trials of organ transplantation confirmed its higher potency as well as more favorable safety profile than cyclosporine (7, 19).

In summary, tacrolimus was effective in controlling refractory ILD in 2 PM/DM patients with favorable safety profile. Given the significant morbidity and mortality associated with this condition and limited therapeutic options, additional therapeutic armaments are welcomed. Prospective investigation of tacrolimus in ILD associated with PM/DM is therefore warranted.

References

- SCHWARZ MI, MATTHAY RA, SAHN SA, STANFORD RE, MARMORSTEIN BL, SCHEINHORN DJ: Interstitial lung disease in polymyositis and dermatomyositis: analysis of six cases and review of the literature. *Medicine (Baltimore)* 1976; 55: 89-104.
- DICKEY BF, MYERS AR: Pulmonary disease in polymyositis/dermatomyositis. *Semin Arthritis Rheum* 1984; 14: 60-76.
- YOSHIDA T, KOGA H, SAITOH F *et al.*: Pulse intravenous cyclophosphamide treatment for steroid-resistant interstitial pneumonitis associated with polymyositis. *Intern Med* 1999; 38: 733-8.
- MAEDA K, KIMURA R, KOMUTA K, IGARASHI T: Cyclosporine treatment for polymyositis/dermatomyositis: is it possible to rescue the deteriorating cases with interstitial pneumonitis? *Scand J Rheumatol* 1997; 26: 24-9.
- NAWATAY, KURASAWA K, TAKABAYASHI K *et al.*: Corticosteroid resistant interstitial pneumonitis in dermatomyositis/polymyositis: prediction and treatment with cyclosporine. *J Rheumatol* 1999; 26: 1527-33.
- NAGASAKA K, HARIGAI M, TATEISHI M *et al.*: Efficacy of combination treatment with cyclosporin A and corticosteroids for acute interstitial pneumonitis associated with dermatomyositis. *Mod Rheumatol* 2003; 13: 231-8.

7. DUMONT FJ: FK506, an immunosuppressant targeting calcineurin function. *Curr Med Chem* 2000; 7: 731-48.
8. WAKATA N, SAITO T, TANAKA S, HIRANO T, OKA K: Tacrolimus hydrate (FK506): therapeutic effects and selection of responders in the treatment of myasthenia gravis. *Clin Neurol Neurosurg* 2003; 106: 5-8.
9. YOCUM DE, FURST DE, KAINE JL *et al.*: Efficacy and safety of tacrolimus in patients with rheumatoid arthritis: a double-blind trial. *Arthritis Rheum* 2003; 48: 3328-37.
10. BANDO S, FUJITA J, OHTSUKI Y *et al.*: Sequential changes of KL-6 in sera of patients with interstitial pneumonia associated with polymyositis/dermatomyositis. *Ann Rheum Dis* 2000; 59: 257-62.
11. MARIE I, HACHULLA E, CHERIN P *et al.*: Interstitial lung disease in polymyositis and dermatomyositis. *Arthritis Rheum* 2002; 47: 614-22.
12. DOUGLAS WW, TAZELAAR HD, HARTMAN TE *et al.*: Polymyositis-dermatomyositis-associated interstitial lung disease. *Am J Respir Crit Care Med* 2001; 164: 1182-5.
13. AUSTIN HA, III, KLIPPEL JH, BALOW JE *et al.*: Therapy of lupus nephritis. Controlled trial of prednisone and cytotoxic drugs. *N Engl J Med* 1986; 314: 614-9.
14. SHINOHARA T, HIDAKA T, MATSUKI Y *et al.*: Rapidly progressive interstitial lung disease associated with dermatomyositis responding to intravenous cyclophosphamide pulse therapy. *Intern Med* 1997; 36: 519-23.
15. SCHNABELA, REUTER M, GROSS WL: Intravenous pulse cyclophosphamide in the treatment of interstitial lung disease due to collagen vascular diseases. *Arthritis Rheum* 1998; 41: 1215-20.
16. KURASAWA K, NAWATA Y, TAKABAYASHI K *et al.*: Activation of pulmonary T cells in corticosteroid-resistant and -sensitive interstitial pneumonitis in dermatomyositis/polymyositis. *Clin Exp Immunol* 2002; 129: 541-8.
17. ODDIS CV, SCIURBA FC, ELMAGD KA, STARZL TE: Tacrolimus in refractory polymyositis with interstitial lung disease. *Lancet* 1999; 353: 1762-3.
18. WILKES M, SEREIKI S, FERTIG N, LUCAS M, PEREZ A, ODDIS C: Treatment of anti-synthetase associated interstitial lung disease with tacrolimus in patients with idiopathic inflammatory myopathy. *Arthritis Rheum* 2003; 48 (Suppl. 9): S434.
19. OCHIAI T, NAKAJIMA K, SAKAMOTO K *et al.*: Comparative studies on the immunosuppressive activity of FK506, 15-deoxyspergualin, and cyclosporine. *Transplant Proc* 1989; 21: 829-32.