

Inflammatory changes of hip synovial structures in polymyalgia rheumatica

F. Cantini¹, L. Niccoli¹, C. Nannini¹, A. Padula², I. Olivieri², L. Boiardi³, C. Salvarani³

¹*II Divisione di Medicina, Unità Reumatologica, Ospedale Misericordia e Dolce di Prato;*
²*Dipartimento di Reumatologia, Ospedale S. Carlo di Potenza ed Ospedale Madonna delle Grazie di Matera;* ³*Divisione di Reumatologia, Arcispedale S. Maria Nuova, Reggio Emilia, Italy.*

Abstract

Objective

To investigate the hip inflammatory lesions and to evaluate the accuracy of clinical examination compared to magnetic resonance imaging (MRI) in patients with polymyalgia rheumatica (PMR) with pelvic girdle symptoms. Secondary end-point was to evaluate the sensitivity and specificity of ultrasonography (US) compared to MRI in the assessment of hip lesions.

Methods

Case-control study of 20 consecutive PMR patients and 40 controls with different rheumatic conditions. Both groups were clinically assessed for the presence of hip synovitis, trochanteric, iliopsoas and ischiogluteal bursitis. Hip MRI was performed in all case-patients and in 10 controls. Both groups were examined by US. An additional group of 10 healthy controls was examined by hip US.

Results

Both MRI and US detected trochanteric bursitis in 100% of PMR patients, bilateral in 18/20 (90%), and in 12/40 (30%) controls ($p < 0.001$). Hip synovitis was detected in 17/20 (85%) by MRI and in 9/20 (45%) by US ($p < 0.02$) in case-patients and in 18/40 (45%) controls. In PMR, MRI and US showed iliopsoas bursitis in 10/20 (50%) and 6/20 (30%) and ischiogluteal bursitis in 5/20 (25%) and 4/20 (20%) with no differences compared to controls. Clinical examination showed a good accuracy for hip synovitis, trochanteric and ischiogluteal bursitis, while it overestimated the presence of iliopsoas bursitis. US was less sensitive than MRI for the detection of hip synovitis and iliopsoas bursitis (53% and 60%).

Conclusion

Trochanteric bursitis represents the most frequent hip lesion in PMR. A careful physical examination allows to detect all inflammatory lesions excluding iliopsoas bursitis. US is less sensitive than MRI in the assessment of hip synovitis and iliopsoas bursitis.

Key words

Polymyalgia rheumatica, MRI, ultrasonography, bursitis, synovitis.

Fabrizio Cantini, MD; Laura Niccoli, MD; Carlotta Nannini, MD; Angela Padula, MD; Ignazio Olivieri, MD; Luigi Boiardi, MD; Carlo Salvarani, MD.

Please address correspondence and reprint requests to: Dr. Fabrizio Cantini, II Divisione di Medicina, Unità Reumatologica, Ospedale Misericordia e Dolce di Prato, Piazza Ospedale no. 1, 59100 Prato, Italy.

E-mail: fcantini@usl4.toscana.it or cantini.fabrizio@virgilio.it

Received on October 5, 2004; accepted in revised form on April 1, 2005.

© Copyright CLINICAL AND EXPERIMENTAL RHEUMATOLOGY 2005.

Introduction

Proximal musculoskeletal pain and stiffness in the neck, shoulder and pelvic girdles in association with elevated acute-phase reactants is the clinical hallmark of polymyalgia rheumatica (PMR). Pelvic girdle is involved in about 60% of the cases causing pain and stiffness in the back and hips (1). From proximal areas the discomfort radiates distally along the thighs toward the knees. Pain is usually felt on the anterior and lateral aspect of the thigh and less frequently posteriorly. It is more pronounced in the morning and may become severe enough to cause difficulty getting up from bed or from a chair (2).

Hip joint synovitis has been considered responsible for the proximal pelvic symptoms experienced by PMR patients (3,4). Recent magnetic resonance imaging (MRI) and ultrasonography (US) studies have shown that PMR mainly affects the extra-articular synovial structures of the shoulders (5-7). Similarly to that observed in the shoulders, other synovial structures such as bursae of the pelvic girdle may be involved by the inflammatory process of PMR (8).

We designed a case-control, magnetic resonance imaging (MRI) and ultrasonography (US) study with two primary end-point: to investigate the hip lesions in a clinical series of patients with untreated PMR and to evaluate the accuracy of clinical examination in the assessment of different articular and soft tissue inflammatory changes compared to MRI. As secondary end-point we assessed the sensitivity and specificity of US with respect to MRI to detect the hip inflammatory lesions in PMR.

Essential anatomy of the synovial structures of the hip

Coxo-femoral joint (hip joint). The synovial membrane lines the deep surface of the articular capsule. Proximally, it covers the surface of the cartilaginous rim of acetabulum and encloses the ligamentum teres. Distally, the synovial membrane extends up to the cartilaginous surface of the femoral head (9).

Trochanteric bursa. The trochanteric bursa is situated between the gluteus

maximum muscle and the posterolateral surface of the greater trochanter. It is usually a multilocular, collapsed bursa whose inner surface is covered by synovial tissue (10).

Iliopsoas bursa. The iliopsoas (or ileopsoas) bursa, which is present and bilateral in 98% of adults, lies between the deep surface of the iliopsoas muscle and the anterior capsule of the hip. It is the largest bursa in the body and is flanked by the femoral artery, vein and nerve. The iliopsoas bursa communicates with the hip joint cavity in 14% of adult cadavers and it is collapsed unless distended by fluid collection secondary to inflammatory involvement (11).

Ischiogluteal bursa (or ischiatic bursa). This bursa is situated over the ischiatric tuberosity and overlies the sciatic and the posterior femoral cutaneous nerves (9, 12).

Patients and methods

Disease and control patients

All consecutive, untreated new patients with PMR according to the Healey criteria (13) who had pelvic girdle involvement observed in the outpatient clinic of 3 secondary rheumatology centers (Hospitals of Prato, Reggio Emilia and Potenza) during a 6-month period were included in the study.

Patients treated with corticosteroids prior to the clinical evaluation, those with positivity of rheumatoid factor (Rose-Waaler titer 40 or nephelometric determination 20 IU/ml on 2 or more occasions) and/or fluorescent antinuclear antibody testing (titer 1:32) were excluded from the study. Temporal artery biopsies were performed only in patients with cranial signs and/or symptoms suggestive of giant cell arteritis (GCA). At diagnosis and over the follow up, all patients were evaluated for fulfillment of American College of Rheumatology (ACR; formerly, the American Rheumatism Association) 1987 revised criteria for rheumatoid arthritis (RA) (14).

The two consecutive outpatients with active rheumatic diseases, older than 50, with bilateral hip aching who were observed after the patient with PMR served as disease controls. An addition-

al group of 10 healthy controls constituted by 6 females and 4 males with a mean age of 61 ± 8.1 years was evaluated.

Clinical assessment

All case and control patients were clinically assessed and prospectively followed up by the same rheumatologists who recorded medical informations on a standardized collection form at every visit. Specifically, patients were assessed for the presence of clinical signs of hip synovitis (coxo-femoral joint synovitis), trochanteric bursitis, iliopsoas bursitis, ischiogluteal bursitis defined as follows:

- hip synovitis: pain in the groin eventually radiating to the anterior and medial thigh toward the knee worsened by passive and active movements and associated with positivity of Fabere test (9);
- trochanteric bursitis: deep, aching pain on the lateral aspect of the hip and thigh increased by external rotation and abduction of the hip associated with localized tenderness on palpation of the area with or without swelling over the greater trochanter (10,15);
- iliopsoas bursitis: tenderness aggravated by extension and relieved by flexion of the hip, associated or not with palpable swelling in the area of the middle third of the inguinal ligament and lateral to the femoral pulse (9,11);
- ischiogluteal bursitis: pain over the ischions aggravated by sitting and lying associated with tenderness on palpation over the ischial tuberosity with or without swelling (16).

Ultrasound and magnetic resonance imaging

As MRI is considered the gold standard method to assess the articular and extraarticular inflammatory lesions (17), to evaluate the accuracy of clinical examination, the clinical findings were compared to MRI results.

Before starting corticosteroid therapy, bilateral hip US was performed in all patients and controls. Bilateral hip MRI was done in all PMR patients and in 10 disease controls. MRI was per-

formed with a median interval from US evaluation of 7 days (range: 1-10 days). The median interval between clinical examination and imaging assessment was 6 days (range: 2-9 days). Healthy controls were examined only by US.

The equipment used for US was the Toshiba SSA340A (Tokyo, Japan) with a 7.5 MHz linear transducer.

All US examinations were performed together by 2 radiologists with special training in musculoskeletal sonography. They were blind to the clinical diagnosis and agreed on the US findings. Hip sonograms were obtained according to previously standardized techniques (18).

MRI scans were also evaluated by 2 radiologists. To compare the findings, the radiologists evaluated the US and MRI scans on an independent basis and blind to the clinical diagnosis and to the reciprocal results. To reach a consensus, the radiologists evaluated all scans, and after the blinded phase compared the reciprocal evaluations. As regards the US examinations there were no discordant cases because measurements were expressed in millimeters. Concerning MRI examinations, in debated cases the radiologists agreed to the lower grade on the semiquantitative scale.

MRI scans were performed with a 0.5-T superconductive magnet system Philips Gyroscan T5 II, 0.5 Tesla (Eindhoven, The Netherlands) and a 17-cm extremity bore transmit-receive coil. Pulse sequences included coronal T1-weighted sequences (240-ms repetition time, 25-ms echo time, and two excitations) and T2-weighted sequences (2000-ms repetition time, 90-ms echo time, and two excitations). The coronal section was 5 mm thick, and the axial section was 7 mm thick; both had an intersection gap of 1 mm. The field of view was 20 cm; the matrix size was 160 cm x 224 cm or 128 cm x 192 cm.

US and MRI were used to evaluate the following synovial hip structures: coxo-femoral joint space, trochanteric, iliopsoas and ischiatic bursae. Inflammatory involvement of these structures was determined by the amount of fluid accumulation.

At US examination, hip synovitis was

diagnosed when a distance of 7 mm or more between the joint capsule and the femur or a difference of more than 1 mm between the two hips were measured and the side with the greater distance was considered as indicating synovitis (18). Hip synovitis was graded at US as done for MRI scans (see below). Bursae inflammation was diagnosed by US if an hypoechoic area suggesting fluid collection was detected in the anatomical sites of trochanteric, iliopsoas and ischiatic bursae (20-24). The hypoechoic area was measured in mm². Fluid collection was graded 0, 1, 2 or 3 if the hypoechoic area was absent, less than 50, between 50 and 100 and more than 100 mm², respectively.

As previously reported (5, 6), for MRI scans, measurement of fluid accumulation was graded by using a semiquantitative scale (0 = no accumulation; 1 = sufficient accumulation to allow visualization of the articular shoulder structure, periarticular shoulder structure, or both; 2 = moderate accumulation; 3 = sufficient quantity to stretch the walls of the structures).

The study protocol was reviewed and approved by ethics committees of the participating centers and written informed consent was obtained from all participating patients.

Statistical analysis was done using SPSS statistical package (SPSS Inc., Chicago, Illinois). Chi-square test was used to compare the results.

Results

Over the study period we observed 43 patients with a new diagnosis of PMR. Of these 23 (53.4%) had pelvic girdle involvement. Three patients were excluded from the study because they had started taking corticosteroids prescribed by the practitioner. Therefore, we studied 20 patients with PMR and 40 controls with different active rheumatic diseases. The demographic and clinical characteristics of case and control patients are shown in Tables I and II. Rapid improvement of symptoms was observed in all patients with PMR after corticosteroid therapy and none of them met the ACR 1987 criteria for RA (14) or developed articular erosions during the followup period.

Table I. Demographic and clinical characteristics of the 20 studied patients with polymyalgia rheumatica.

Female/male, %	75/25
Age at onset of disease, yrs	73 ± 6.9
Duration of symptoms before diagnosis, mo	3 ± 1
Duration of follow-up, mo	26 ± 7.2
Systemic symptoms and signs (fever, anorexia and weight loss) %	40
Morning stiffness duration, minutes	184 ± 45.4
Distal manifestations (peripheral arthritis, distal extremity swelling with pitting edema) %	28
ESR at diagnosis, mm/h	68 ± 10.4
CRP at diagnosis, mg/dl	5.5 ± 2.1
Biopsy proven GCA, %	15

ESR: erythrocyte sedimentation rate; CRP: C-reactive protein; GCA: giant cell arteritis. Except where otherwise indicated, values are expressed as mean ± SD.

Table II. Demographic and clinical characteristics of the 40 control-patients.

Diagnosis	No.	Male/ female, %	Age yrs	Disease duration, mo	ESR, mm/h	CRP, mg/dl
Rheumatoid arthritis	22	68/32	57 ± 9.6	38 ± 15.4	40 ± 7.3	2.9 ± 2.7
Psoriatic arthritis	10	40/60	55 ± 8.5	44 ± 20.6	43 ± 14.2	3.1 ± 2.0
Osteoarthritis	8	50/50	67 ± 4.6	52 ± 11.1	16 ± 4.2	0.6 ± 0.2

Except where otherwise indicated, values are expressed as mean ± SD.

Table III. Hip US and MRI findings in 20 patients with active polymyalgia rheumatica and pelvic girdle involvement.

Patient	Coxo-femoral joint synovitis		Trochanteric bursitis		Iliopsoas bursitis		Ischiatic bursitis	
	US l/r	MRI l/r	US l/r	MRI l/r	US l/r	MRI l/r	US l/r	MRI l/r
1	0/0	1/0	2/2	2/2	1/0	1/0	0/0	0/0
2	0/0	1/1	3/2	3/3	0/0	1/1	0/0	0/0
3	0/0	1/1	0/1	0/2	0/0	0/0	0/0	0/0
4	1/0	1/0	3/2	3/2	0/0	0/0	0/0	0/0
5	0/0	0/1	2/1	2/2	1/0	2/0	0/0	0/0
6	1/0	1/0	2/2	2/3	0/0	0/0	0/0	0/0
7	0/0	1/0	1/2	2/2	0/0	0/0	0/0	0/0
8	0/0	0/1	3/3	3/2	1/0	1/1	0/0	0/0
9	1/0	1/1	1/2	2/2	1/1	1/2	1/0	1/1
10	1/0	1/1	2/2	2/2	0/0	0/1	0/0	0/0
11	1/0	1/1	1/2	2/3	0/0	0/0	0/0	1/1
12	0/0	0/1	2/2	2/2	0/0	0/1	0/0	0/0
13	1/0	1/0	3/2	3/3	2/0	2/1	1/1	1/2
14	0/0	0/0	1/2	2/2	0/1	1/1	0/0	0/0
15	1/1	2/1	2/2	3/2	0/0	0/0	0/0	0/0
16	0/0	0/0	0/2	0/3	0/0	1/0	0/1	0/2
17	1/1	1/2	1/2	2/2	0/0	0/0	0/0	0/0
18	0/0	0/1	2/2	2/2	0/0	0/0	1/2	2/2
19	0/0	0/0	1/1	1/2	0/0	0/0	0/0	0/0
20	0/1	0/2	2/3	3/3	0/0	0/0	0/0	0/0

l: left; r: right. Fluid collection was graded on a semiquantitative scale ranging from 0 to 3 (see Patients and methods section).

US and MRI findings in patients with PMR and controls

Table III shows the results of hip US and MRI examination in 20 consecutive patients with PMR with pelvic girdle symptoms.

Both US and MRI detected trochanteric bursitis in 100% of patients (Figs. 1,2), while US showed this lesion in 12/40 (30%) of controls ($p < 0.001$). In case-patients trochanteric bursitis was bilateral in 18/20 (90%). US and MRI, respectively, showed grade 3 trochanteric bursitis in 6/40 (15%) and 12/40 (30%) hips, grade 2 in 23/40 (57.5%) and 25/40 (62.5%), grade 1 in 9/40 (22.5%) and 1/40 (2.5%).

MRI was significantly more sensitive than US to detect hip synovitis. This inflammatory lesion was evident in 17/20 (85%) patients with PMR examined by MRI and in 9/20 (45%) studied by US ($p = 0.02$). This finding was unilateral in 10/17 (59%) patients. Hip synovitis was also observed by US in 18/40 (45%) controls. Iliopsoas bursitis was present in 6/20 (30%) PMR patients at US and in 10/20 (50%) at MRI ($p = \text{NS}$). The same lesion was detected by US in 4/40 (10%) controls. Ischiogluteal bursitis was evident in 4/20 (20%) patients at US and in 5/20 (25%) at MRI ($p = \text{NS}$).

Ischiogluteal bursitis was observed by US in 2/40 (5%) of controls. The differences in the frequencies of iliopsoas and ischiogluteal bursitis at US between PMR patients and controls were not significant.

In the 10 controls studied by both US and MRI the two methods did not show any differences in the detection of hip lesions: hip synovitis in 4/10 (40%) at US and 5/10 (50%) at MRI, iliopsoas bursitis in 1/10 (10%) and 2/10 (20%), trochanteric bursitis and ischiatic bursitis in 2/10 (20%) and 1/10 (10%), respectively.

None of 10 healthy controls had hip inflammatory lesions at US examination.

Relationship between clinical and MRI findings in patients with PMR

As shown in Table IV, on clinical examination hip synovitis was found in 12/20 (60%) of patients, bilateral in 4/20 (20%). Trochanteric bursitis was

shown in 100% of the cases, bilateral in 17/20 (85%). No significant differences of these two lesions were present between clinical and MRI findings. Clinical findings of iliopsoas bursitis were observed in 17/20 (85%) of patients while this lesion was confirmed by MRI only in 10/20 (50%) (figure 3). The difference was statistically significant ($p < 0.05$). Clinical signs of ischiogluteal bursitis were found in 6/20 (30%) patients and in 5/20 (25%) at MRI scans ($p = \text{NS}$).

Sensitivity and specificity of US

Assuming MRI as the gold standard method and dividing the results into presence/absence of the various lesions, the sensitivity and specificity of US were respectively of 53% and 100% for hip synovitis, 100% and 100% for trochanteric bursitis, 60% and 100% for iliopsoas bursitis and 80% and 100% for ischiogluteal bursitis.

Discussion

Pelvic girdle aching and stiffness in patients with PMR are probably related to the inflammatory changes affecting the synovial structures of the hip region. A few scintigraphic and US studies have demonstrated the presence of hip joint synovitis in most patients (3, 4). However, pain due to hip synovitis is usually felt in the groin often radiating to the anterior and medial thigh (9). Therefore, hip joint synovitis alone does not fully explain the distribution of pain to the lateral and posterior regions of the thigh observed in PMR patients (1, 2).

Occasional reports have shown that extraarticular synovial structures of the pelvis are involved by the inflammatory process of PMR (5,8,25). This is the first controlled US and MRI study designed to investigate the inflammatory changes of pelvic synovial structures in untreated PMR. Similarly to shoulder findings (5-7), a prominent involvement of extraarticular synovial structures was detected using both MRI and US. Indeed, trochanteric bursitis, bilateral in 90% of the cases, was observed in all case patients with a highly significant difference with respect to con-

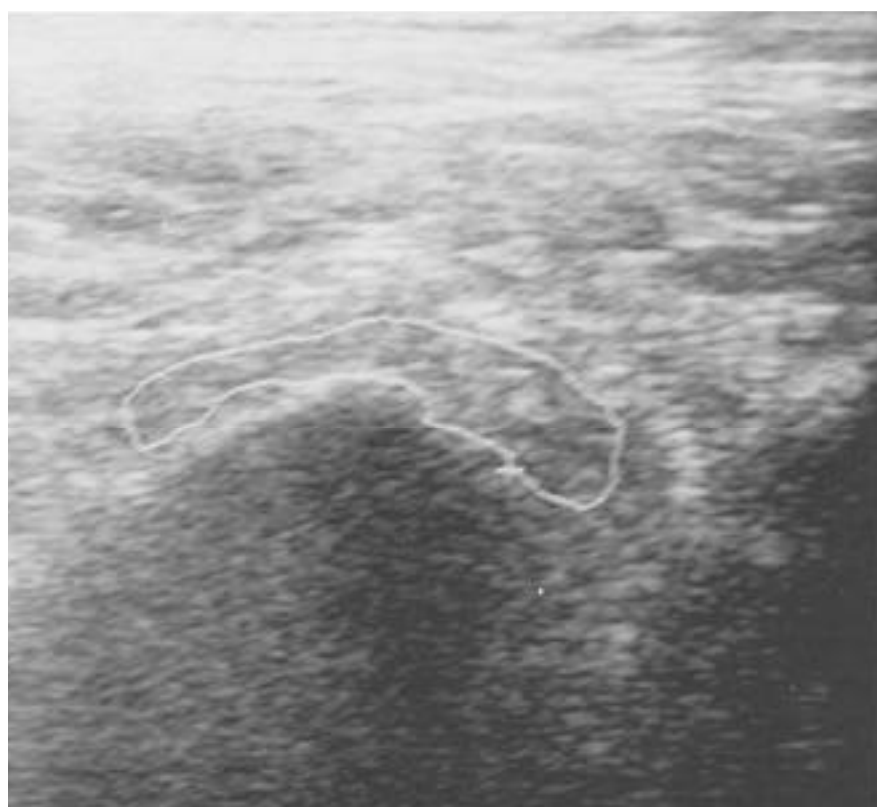


Fig. 1. Longitudinal US scan of the hip of a patient with PMR showing abundant fluid collection within the trochanteric bursa (outlined in white).

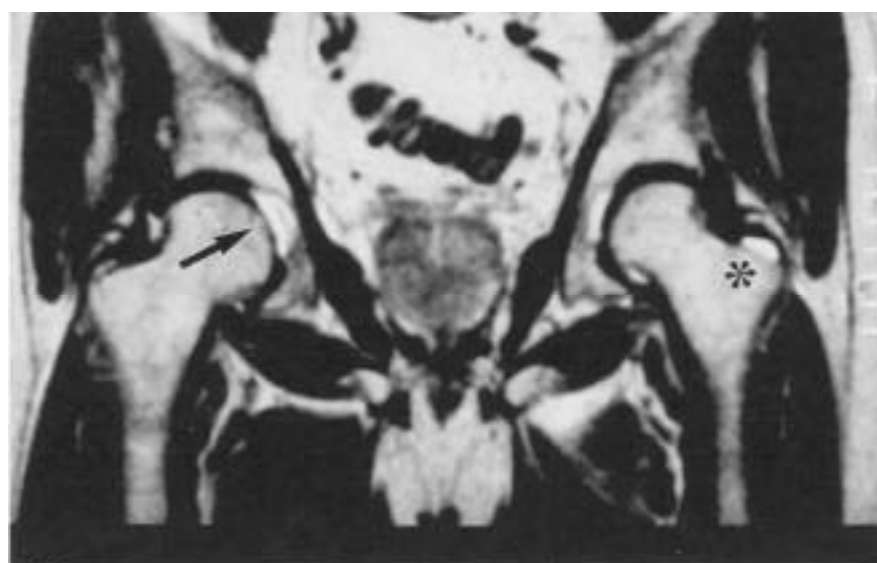

Fig. 2. Hip MRI of a patient with PMR. Axial T2-weighted scan shows bilateral trochanteric bursitis (asterisk) and right hip synovitis (arrow).

trols. Hip synovitis was observed in 17/20 (85%) PMR patients. This finding was more frequently unilateral and its frequency was not significantly different compared to controls. Other hip bursae, such as iliopsoas and ischiogluteal bursae, were involved in 30%

and 20% of the cases respectively, but their frequencies were similar to those observed in the controls. If considered separately, these lesions are not specific of PMR because they may be observed in other inflammatory or degenerative rheumatic conditions. However,

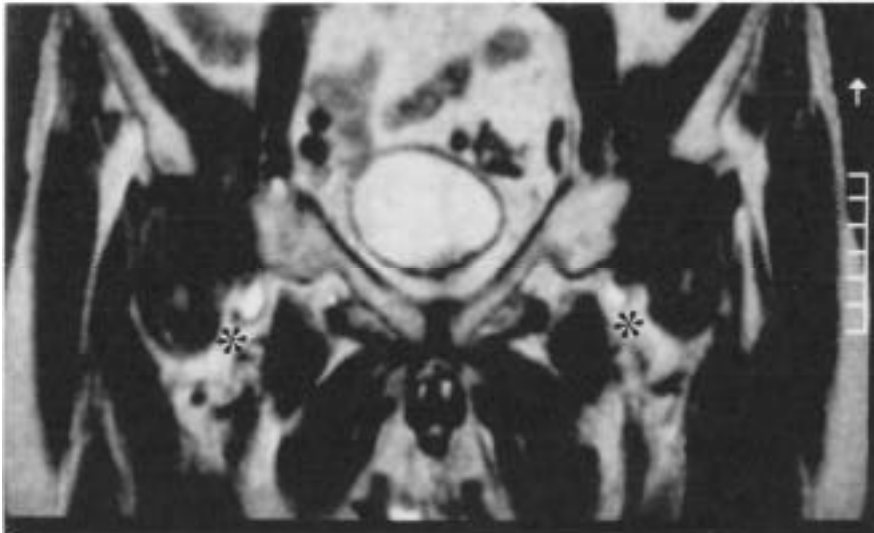


Fig. 3. Axial T2-weighted MRI scan of the hip in PMR: presence of fluid within the iliopsoas bursae (asterisks) suggesting bilateral bursitis.

our results indicate that bilateral trochanteric bursitis and the concomitant inflammatory involvement of coxo-femoral joint, iliopsoas and ischio-gluteal bursae, although less frequently observed, are a likely basis for much of the discomfort in the proximal girdle of patients with PMR. Similarly to those observed in shoulders, these findings confirm that PMR may be an inflammatory process that predominantly affects

extraarticular synovial structures (26). Trochanteric bursitis, variously associated with hip joint synovitis and hip bursae involvement, better explains the distribution of pain in PMR patients with pelvic girdle symptoms. Indeed, pain in the lateral region of the thigh frequently observed in PMR patients can be better related to inflammatory involvement of trochanteric bursa rather than hip joint synovitis

alone (10). In addition, gluteal pain, difficulty standing up, and pain worsening while seated experienced by some patients is better explained if other extraarticular synovial structures, such as ischio-gluteal and iliopsoas bursae are affected (11, 12).

The second aim of this study was to evaluate the accuracy of physical examination compared to MRI in the detection of hip inflammatory lesions in PMR. We found a good relationship between clinical examination results and MRI findings in the diagnosis of hip joint synovitis, trochanteric and ischio-gluteal bursitis. Surprisingly, clinical findings suggesting ilio-psoas bursitis were detected in 17/20 (85%) patients while MRI confirmed this lesion only in 10/20 (50%) with a statistically significant difference ($p < 0.05$).

Commonly employed physical maneuvers, including presence of tenderness in a rather precise site of the middle third of the inguinal compartment just laterally to the femoral pulse with pain aggravated by extension and relieved by flexion of the hip seem to be accurate for the diagnosis of iliopsoas bursitis (11, 27). In addition, the diagnosis is relatively straightforward when a palpable mass due to enlarged bursa is detectable in the same region (28). On clinical examination, these findings were present in the majority of PMR patients but iliopsoas bursa inflammation was confirmed only in 10/17 (59%) of the cases by MRI. There is a consistent body of evidence that MRI represents the most accurate method to investigate the inflammatory changes of iliopsoas bursa (29, 30). In absence of MRI detectable inflammatory lesions, it's difficult to explain the physical finding of pain and tenderness over iliopsoas bursa observed in our patients with PMR.

Apart from the discrepancy between clinical and MRI assessment in the diagnosis of iliopsoas bursitis, our study indicates that a careful physical examination is sufficient to detect the hip synovial structures involved by the inflammatory process of PMR and that MRI or US should not be routinely employed in clinical practice.

Secondary end point of the study was

Table IV. Clinical and MRI findings of the hip in 20 patients with PMR.

Patient No	Hip joint synovitis		Trochanteric bursitis		Iliopsoas bursitis		Ischio-gluteal bursitis	
	Clinical examination l/r	MRI l/r	Clinical examination l/r	MRI l/r	Clinical examination l/r	MRI l/r	Clinical examination l/r	MRI l/r
1	+/-	+/-	++	++	+/-	+/-	-/-	-/-
2	+/-	++	++	++	++	++	-/-	-/-
3	++	++	-/-	-/-	++	-/-	-/-	-/-
4	+/-	+/-	++	++	+/-	-/-	-/-	-/-
5	-/+	-/+	++	++	++	+/-	-/-	-/-
6	+/-	+/-	++	++	+/-	-/-	-/-	-/-
7	-/-	+/-	++	++	++	-/-	-/-	-/-
8	-/-	-/+	++	++	++	++	-/+	-/-
9	-/-	++	++	++	++	++	++	++
10	++	++	++	++	-/-	-/-	-/-	-/-
11	+/-	++	-/-	++	-/-	-/-	-/+	++
12	-/-	-/+	++	++	-/-	-/-	-/-	-/-
13	+/-	+/-	++	++	++	++	++	++
14	-/-	-/-	++	++	++	++	-/-	-/-
15	++	++	++	++	-/-	-/-	-/-	-/-
16	-/-	-/-	-/+	-/+	++	+/-	-/+	-/+
17	++	++	++	++	++	-/-	-/-	-/-
18	-/-	-/+	++	++	-/-	-/-	++	++
19	-/-	-/-	++	++	-/-	-/-	-/-	-/-
20	-/+	-/+	++	++	++	-/-	-/-	-/-

l: left; r: right; -: absent; +: present.

to assess the sensitivity and specificity of US compared to MRI in the detection of hip inflammatory changes. US resulted a good method to detect trochanteric bursitis with a sensitivity and a specificity of 100%. According to other reports (31), US was significantly less accurate to detect hip synovitis with low sensitivity of 53%, but a high specificity (100%). The sensitivity of US for iliopsoas bursitis diagnosis was low (60%), while the sensitivity of US was better for ischio-gluteal bursitis (80%).

In conclusion, the results of our case-control study demonstrate that trochanteric bursitis, bilateral in 90% of the cases, is the most frequent hip synovial inflammatory lesion of PMR. The association of this lesion with other less frequently observed inflammatory changes such as hip joint synovitis, iliopsoas and ischio-gluteal bursitis is a likely basis for much of the discomfort in pelvic girdle of PMR patients and better explains the distribution of aching in this area. These findings confirm that in PMR there is an extensive inflammatory involvement of extraarticular synovial structures. Moreover, a careful physical examination is sufficient to assess the synovial structures involved by inflammation and US or MRI are usually not required in clinical practice. Finally, US is less accurate than MRI to detect coxo-femoral joint synovitis while it has the same diagnostic power for other hip inflammatory lesions.

References

1. SALVARANI C, CANTINI F, BOIARDI L, HUNDER GG: Polymyalgia rheumatica and Giant Cell Arteritis. *N Engl J Med* 2002; 347:261-71.
2. HUNDER GG: Giant cell arteritis and polymyalgia rheumatica. *Med Clin North Am* 1997; 81: 195-219.
3. O'DUFFY JD, WAHNER HW, HUNDER GG: Joint imaging in polymyalgia rheumatica. *Mayo Clin Proc* 1976; 51: 519-24.
4. KOSKI JM: Ultrasonographic evidence of synovitis in axial joints in patients with polymyalgia rheumatica. *Br J Rheumatol* 1992; 31: 201-3.
5. SALVARANI C, CANTINI F, OLIVIERI I *et al.*: Proximal bursitis in active polymyalgia rheumatica. *Ann Intern Med* 1997; 27: 27-31.
6. CANTINI F, SALVARANI C, OLIVIERI I *et al.*: Shoulder ultrasonography in the diagnosis of polymyalgia rheumatica: a case-control study. *J Rheumatol* 2001; 5: 1049-55.
7. CANTINI F, SALVARANI C, OLIVIERI I *et al.*: Inflamed shoulder structures in polymyalgia rheumatica with normal erythrocyte sedimentation rate. *Arthritis Rheum* 2001; 44: 1155-9.
8. CANTINI F, SALVARANI C, OLIVIERI I, NICCOLI L, PADULA A, BOZZA A: Hip bursitis in active polymyalgia rheumatica. *Clin Exp Rheumatol* 1999; 17: 512-3.
9. POLLEY HF, HUNDER GG: *Rheumatologic Interviewing and Physical Examination of the Joints*. 2nd ed. Philadelphia; WB Saunders, 1978.
10. SHBEEB MI, MATTESON EL: Trochanteric bursitis (greater trochanter pain syndrome). *Mayo Clin Proc* 1996; 71: 565-9.
11. TOOHEY AK, LASALLE TL, MARTINEZ S, POLISSON RP: Iliopsoas bursitis: clinical features, radiographic findings, and disease association. *Semin Arthritis Rheum* 1990; 20: 41-7.
12. SWARTOUT R, COMPERE EL: Ischio-gluteal bursitis. *JAMA* 1974; 227: 551-2.
13. HEALEY LA: Long term follow-up of polymyalgia rheumatica: evidence for synovitis. *Semin Arthritis Rheum* 1984; 13: 322-8.
14. ARNETT FC, EDWORTHY SM, BLOCH DA *et al.*: The American Rheumatism Association 1987 revised criteria for the classification of rheumatoid arthritis. *Arthritis Rheum* 1988; 31: 315-24.
15. SCHAPIRA D, NAHIR M, SCHARF Y: Trochanteric bursitis: a common clinical problem. *Arch Phys Med Rehabil* 1986; 67:815-7.
16. MAZIERES B, CARETTE S: Regional pain problems. The hip. In: KLIPPEL JH, DIEPPE PA editors. *Rheumatology*. 2nd Edition. London: Mosby 1998; 4.10.1-4.10.8.
17. JACOBSON JA: Musculoskeletal sonography and MR imaging. *Radiol Clin North Am* 1999; 37: 713-35.
18. KOSKI JM, ANTILAPI, ISOMAKI HA: Ultrasonography of the adult hip. *Scand J Rheumatology* 1989; 18: 113-7.
19. GRAIF M: Ultrasound of the hip. *Eur J Ultrasound* 2001; 14: 35-43.
20. CHHEM RK, KAPLAN PA, DUSSAULT RG: Ultrasonography of the musculoskeletal system. *Radiol Clin North Am* 1994; 32: 275-89.
21. JACOBSON JA, VAN HOLSBEECK MT: Musculoskeletal ultrasonography. *Orthop Clin North Am* 1998; 29: 135-67.
22. HASHIMOTO BE, KRAMER DJ, WIITALA L: Applications of musculoskeletal sonography. *J Clin Ultrasound* 1999; 27: 293-318.
23. WANG S, CHHEM RK, CARDINALE, CHO K: Joint sonography. *Radiol Clin North Am* 1999; 47: 653-68.
24. ERICKSON SJ: High-resolution imaging of the musculoskeletal system. *Radiology* 1997; 205: 593-618.
25. PAVLICA P, BAROZZI L, SALVARANI C, CANTINI F, OLIVIERI I: Magnetic resonance imaging in the diagnosis of PMR. *Clin Exp Rheumatol* 2000 (Suppl. 20); 18: S38-S39.
26. SALVARANI C, CANTINI F, OLIVIERI I, HUNDER GG: Polymyalgia rheumatica: a disorder of extraarticular synovial structures? *J Rheumatol* 1999; 26: 517-21.
27. ARMSTRONG P, SAXTON H: Ilio-psoas bursa. *Br J Radiol* 1972; 45: 493-5.
28. UNDERWOOD PL, MCLEOD RA, GINSBURG WW: The varied clinical manifestations of iliopsoas bursitis. *J Rheumatol* 1988; 15: 1683-5.
29. KOZLOV DB, SONIN AH: Iliopsoas bursitis: diagnosis by MRI. *J Comput Assist Tomogr* 1998; 22: 625-8.
30. WUNDERBALDINGER P, BREMER C, SCHELENBERGER E, CEJNA M, TURETSCHKE K, KAINBERGER F: Imaging features of iliopsoas bursitis. *Eur Radiol* 2002; 12: 409-15.
31. MOSS SG, SCHWEITZER ME, JACOBSON JA *et al.*: Hip joint fluid: detection and distribution at MR imaging and US with cadaveric correlation. *Radiology* 1998; 208: 43-8.