

---

# Proinflammatory pathways in cervicogenic headache

---

P. Martelletti

---

Department of Clinical Medicine  
University "La Sapienza", Rome, Italy  
Please address correspondence and reprint  
requests to: Paolo Martelletti, MD,  
Dipartimento di Medicina Clinica,  
Università degli Studi di Roma "La  
Sapienza", Policlinico Umberto I, Viale  
del Policlinico, 155, 00161 Rome, Italy.  
E-mail: martelletti@uniroma1.it

Clin Exp Rheumatol 2000; 18 (Suppl. 19):  
S33-S38.

© Copyright CLINICAL AND EXPERIMENTAL  
RHEUMATOLOGY 2000.

**Key words:** Cervicogenic headache,  
cervical spine, inflammation,  
cytokines, nitric oxide, acetylsalicylic  
acid, cyclooxygenase.

## ABSTRACT

*Cervicogenic headache (CEH) is a relatively common form of headache arising from the neck structures. The pathophysiology probably results from various local pain-producing factors such as intervertebral dysfunction, with a no less important role played by the frequent coexistence of a history of head traumas. This report represents a series of pathophysiological studies in CEH patients and the results achieved by pharmacological treatment of the disease.*

*Interleukin-1 $\beta$  (IL-1 $\beta$ ) and Tumour Necrosis Factor  $\alpha$  (TNF- $\alpha$ ) exert their multifunctional biological effects by promoting and increasing the molecular events of cellular inflammation. We found that the cytokine pattern of CEH patients is - similar to cluster headache - biased towards an inflammatory status. Higher levels of both IL-1 $\beta$  and TNF- $\alpha$  were detected in the sera of CEH patients than the levels in patients with migraine without aura and in healthy subjects. There were also differences between the spontaneous and mechanically worsened pain phases of CEH.*

*Nitric oxide (NO) synthase is also activated in cervicogenic headache. No change in NO metabolites levels has been observed after NO donor administration. This behaviour is clearly different from that observed in migraine and tension headache patients.*

*We conclude that the high degree of cytokine and NO production in CH may depend on the differing pathophysiological mechanisms at work in CEH than in other forms of headache.*

## Introduction

There is now growing evidence to support the hypothesis of cervicogenic headache (CEH), an uncommon and still controversial headache disorder, as a multifactorial, strictly unilateral head pain syndrome arising from the neck structures (1). CEH has been recognized as a pain syndrome by the International As-

sociation for the Study of Pain (IASP) (1) and is currently accepted as a diagnosis in Europe and in parts of Canada, but it is almost universally rejected in the United States. CEH has not as yet been accepted by the International Headache Society as a diagnostic category (2), but on the basis of the first 1990 edition (3) new diagnostic criteria have recently been published by an ad hoc international study group (CHISG) (4).

## Anatomical bases of pain

The biomechanics of the cervical spine are based upon the complex interaction between vertebral articulations, ligaments, and the intrinsic and long muscular structure of the spine itself. Additionally, muscles of the superior portion of the thorax and shoulders have a stabilizing function. The craniocervical junction (C0-C2) is different in terms of biomechanics from the rest of the cervical spine. The most frequent movements of the head (e.g., lateral rotation up to 25 degrees and nuchal extension) are carried out in large part by segments C0/C1 and C1/C2, and the posture of the cervical column is controlled by proprioceptors situated locally in the articulations, tendons, and muscles. Also, there are close ties between the superior part of the cervical column, the vertebral artery, the nerve roots, and some of the peripheral nerves (e.g., the sinuvertebral nerve).

The C1 and C2 vertebrae are also unique in that they do not have posterior articulations and their respective cervical nerves do not emerge from the vertebral foramen or dural sheaths (as in the case of cranial nerves). The localization of some forms of headache in the neck region has always led to nosologic uncertainty and confusion. For example, certain migraine-type headaches have for years been attributed to a degenerative syndrome of the superior segment of the vertebral spine simply because the pain originated in or radiated to that area. The

recent International Headache Society's somewhat complex classification of headaches, which employs a mathematical approach to arrive at the diagnosis, was unable to expand upon some points of broad interest, such as headaches stemming from the neck structures (2). The problem of pain originating in the neck region and not related to degenerative situations of the cervical column was first raised by Hunter and Mayfield in 1949 (5). However, a paper published in 1949 by Josey reported on 6 "illustrative" cases of cervical-related headache which, if considered from a more recent perspective, could correspond to CEH (6). Only more recently has it been hypothesized that one could define a new and distinct clinical entity which Sjaastad and colleagues in 1983 termed "cervicogenic headache" (7, 8).

#### **Clinical and diagnostic assessment of cervicogenic headache**

Cervicogenic headache represents a frequent cause of pain starting from the C2/C3 dermatome with radiation to the occipital area, to vertex of the head (C2 level), the peri-oculo-frontal-auricular-temporal area, and sometimes even to the mandibular and neck regions (C3 level) (9). The pattern of pain from the neck can also follow other directions; for example, to the shoulder and the ipsilateral arm, thus mimicking a radicular type of headache. There may be some clinical variability in the type of pain, which is often continuous, non-pulsating, and non-burning, with some radicular characteristics. Additionally, there may be problems with the sense of balance and autonomic functions. Often there are periodic recurrences of paroxysmal attacks which are asymmetrically, unilaterally localized, and there is frequent concomitance of pain elsewhere in the osteoarticular apparatus. Additionally, variation of position and/or movement of the cervical column at the onset of pain are an important distinguishing feature. These factors combine to make the cervicogenic headache a true multifactorial syndrome (10).

Cervicogenic headache appears to be based more on a functional disorder than on degenerative lesions of the cervical spine (11). Even though clinical infor-

mation in the past has attributed the pain observed in these regions to osteochondritic/osteoarthritic type problems, various studies have shown that there are no radiological (X-ray, CT) correlations between cervicogenic headache and cervical degenerative lesions (12, 13).

Furthermore, it is important to remember that degenerative lesions of the cervical spine are to be found more frequently in the lower and mid-cervical rather than in the upper cervical region, probably because the latter is associated with fewer degenerative risk factors (for example, there is no intervertebral disc between C0/C1 and C1/C2) (12).

Symptoms that may distinguish cervicogenic headaches from certain other common headache syndromes include: a female predominance, the strictly unilateral localization of pain (neck, temporal, orbital and frontal regions), and a distinct reduction in the range of movement of the cervical column. Also, the intensity of pain is often severe in contrast to the radicular syndromes. These clinical symptoms appear to be linked to a very low pain pressure threshold in the occipital part of the head in these patients, with reproduction of pain in the site of pain predominance (14, 15). No pathologic findings have been observed on orbital phlebography in cervicogenic headache or in other forms of primary headaches which lack a vascular inflammatory etiology (16).

Previous trauma in the head and neck region is frequently reported as a characteristic element in the history of patients suffering from cervicogenic headache (10), a fact which may create diagnostic confusion. However, post-traumatic headache or the "postconcussion syndrome" generally have a different clinical picture. The differential diagnosis of this form of headache creates difficulties because of signs and symptoms similar to various other pain syndromes located within the same region. Neri-Barrè-Lieou syndrome should, however, be considered as completely distinct from cervicogenic headache because of the prominence of altered autonomic function, if this syndrome can be said to represent a true clinical entity (17, 18). Another pain syndrome with cervicocervical localization that should be consid-

ered distinct from the cervicogenic headache is Arnold's neuralgia, which electively responds to local steroid therapy (19, 20).

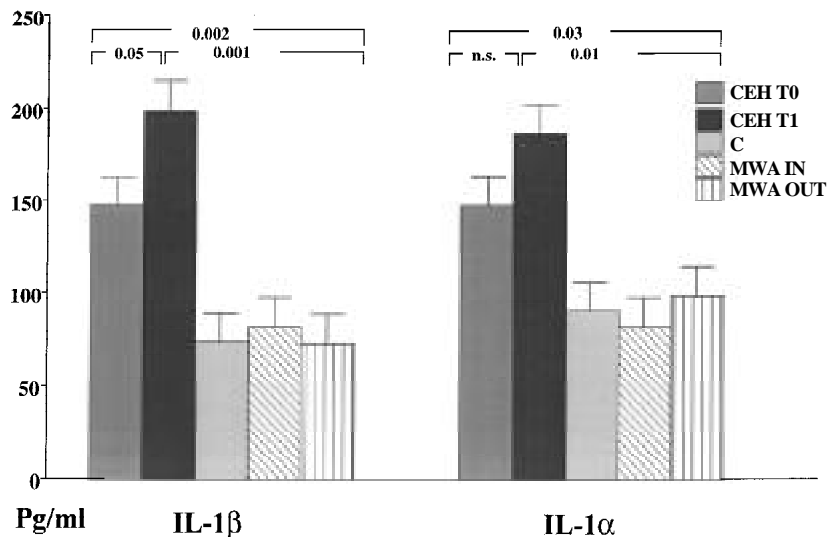
The differential diagnosis of cervicogenic headache includes other common entities such as tension headache and migraine (21), and a rare SUNCT syndrome (a short-lasting, unilateral, neuralgiform headache and tension-type headache) (22). In fact, while the localization of pain in the neck may or may not be present in tension headache, it represents a starting point in cervicogenic headache. In tension headache, the pain can occur on a daily basis and may not be localized in the neck region. There may be a "weight" or pressure-like sensation, and often there is the sensation of a tight skullcap. These clinical characteristics of tension headache are not found in cervicogenic headache. A strict and consistent unilaterality of pain is very rare in migraine with or without aura (23), while it is the rule in cervicogenic headache.

Another form of headache which may be clinically separated from cervicogenic headache is that associated with the Chiari type I malformation (24). The presence of dizziness is often the dominant feature in Chiari patients. However, herniation of the lowest intervertebral cervical disc(s) can also produce a unilateral headache and radiating pain in the ipsilateral arm mimicking cervicogenic headache (25).

The pattern of response of cervicogenic headache to various therapeutic interventions, as well as the findings on certain diagnostic tests, serve to mark this headache as a distinct entity. These clinical characteristics and diagnostic criteria can be used to define similarities and differences with the various other identified headache syndromes.

#### **Proinflammatory cytokines and cervicogenic headache**

No evidence of inflammation has yet been demonstrated in CEH, although the administration of epidural corticosteroid (C7) seems to have a short-term clinical effectiveness (26, 27). The diagnostic value of this blockade is supported by the existence of numerous sensitive but non-motor connections between C2 and



**Fig. 1.** Mean serum values ( $\pm$  SE) of interleukin-1 ( $IL-1$ ) and tumour necrosis factor- ( $TNF-$ ) in patients with cervicogenic headache (CEH) ( $n = 15$ ), patients with migraine without aura (MWA) ( $n = 15$ ), and in controls (C) ( $n = 15$ ) (NPAR1WAY and Duncan's t-test). For details, see text.

C7 (28). However, the clinical evaluation of this approach over time revealed no valuable therapeutic impact (29).

Our laboratory has previously reported impaired function of the pro-inflammatory cytokine  $IL-1\beta$  but not of  $TNF-$  in patients suffering from other forms of strictly unilateral headache, such as cluster headache (30).

Currently the clinical debate on the existence of CEH has centered on its difference from migraine without aura (MWA). This postulated difference from

migraine could be based on the demonstrated effectiveness of steroids in alleviating CEH pain (10).

We observed increased levels of serum  $IL-1\beta$  and  $TNF-$  in CEH both during periods of spontaneous fluctuating basal pain and during mechanically-induced attacks (31). Statistically significant differences in the cytokines levels between the different groups were found (Fig. 1). CEH patients showed higher levels of  $IL-1\beta$  and  $TNF-$  during both continuous (T0) and mechanically-in-

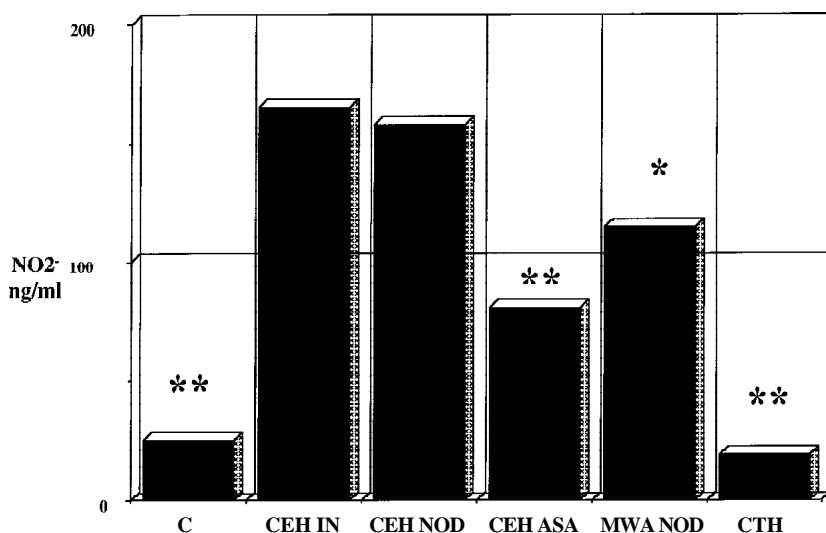
duced attacks (T1) compared with both MWA patients (both during (IN) and outside (OUT) spontaneous attacks) and with controls.

The nature of the pain in CEH has not yet been defined. However, the enhanced production of both  $IL-1\beta$  and  $TNF-$  in CEH, as shown in the present experiment, could represent a specific signal from the immune system resulting in the subsequent activation of the well-known links existing between immunopeptides and neuropeptides, such as Substance P and calcitonin-gene-related peptide (10). Moreover, the increased level of  $IL-1\beta$  and  $TNF-$  that we measured during the mechanically-induced CEH attacks could be stress-related, but this would not account for the high values detected during the inter-ictal phase. Although the role of these pro-inflammatory cytokines remains to be determined, both  $IL-1\beta$  and  $TNF-$  may promote hyperalgesia in CEH. Furthermore, the anatomical derivation of blood sampling in CEH (extracranial circulation) reinforces the observed differences with migraine (intracranial vessels) (28) and could help to define CEH diagnostically as an inflammatory headache.

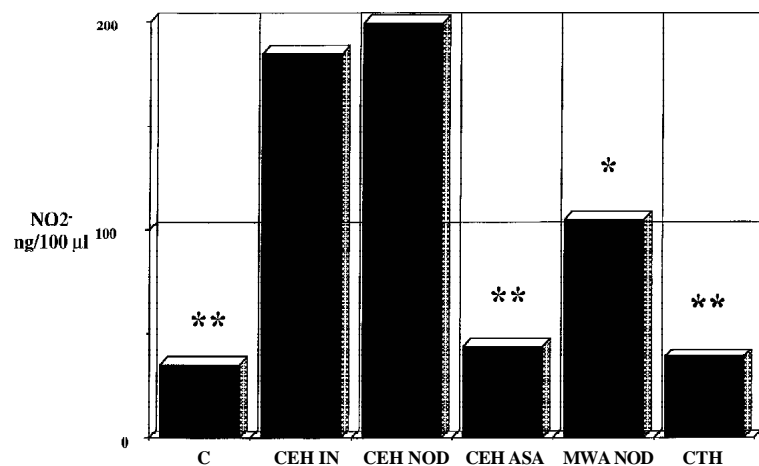
Lastly, since chronic pain in the cervical spine (at the cervical zygapophyseal joint level) seems to be a very common problem after whiplash injury (32, 33) our results could be explained as an inflammatory consequence of local traumatic events.

### Role of nitric oxide in cervicogenic headache

The pivotal role of nitric oxide (NO) was recently suggested in other forms of headaches, such as migraine and cluster headache (34-36). In migraine, NO reduces the cytokine-induced expression of a number of pathophysiological effector molecules characteristic of endothelial activation. Pain crises induced in migraine patients by administering an NO donor (NOD) reduces the monocyte expression of intercellular adhesion molecule 1 (ICAM-1) (37), as well as of endothelial leukocyte adhesion molecule 1 (ELAM-1) (38). Conversely, NO generation (assayed as nitrite levels) appears to be upregulated progressively in migraine from the basal condition to pain



**Fig. 2.** Comparative values of serum nitrite ( $NO_2^-$ ) accumulation in cervicogenic headache (CEH) patients studied during both spontaneous pain (CEH IN) and nitric oxide donor (CEH NOD)-elicited pain, and 15 min after the administration of i.v. acetylsalicylic acid (ASA) 1000 mg (CEH ASA). The control group consisted of healthy subjects (C), NOD migraine patients (MWA), and chronic tension headache patients (CTH). \* $P < 0.02$ ; \*\* $P < 0.001$ .



**Fig. 3.** Comparative values of nitrite (NO<sub>2</sub><sup>-</sup>) accumulation from cell culture supernatants in cervicogenic headache (CEH) patients studied during both spontaneous (CEH IN) and nitric oxide donor (CEH NOD)-elicited pain, and 15 min after the administration of i.v. acetylsalicylic acid (ASA) 1000 mg (CEH ASA). The control group consisted of healthy subjects (C), NOD migraine patients (MWA) and chronic tension headache patients (CTH). \*P < 0.01; \*\* P < 0.001.

attack (39), but only during the pain phase in cluster headache (36).

We found that CEH patients showed a more marked activation of the NO pathway than that reported in migraine or in cluster headache (40); moreover, no difference in NO release was found between a spontaneous CEH attack and CEH pain elicited by NOD administration (Figs. 2-4). Interestingly, pulse intravenous administration of acetylsalicylic acid 1 g (ASA) dramatically reduced the NO levels in CEH patients (Figs.

2-4). Furthermore, the visual analogue scale (VAS) of pain was not affected by the administration of NOD to CEH patients and showed a marked reduction after ASA administration (Fig. 5). Lastly, two subgroups of CEH patients may be distinguished with different amounts of nitrite accumulation and different disease activity (VAS scores) (Fig. 6).

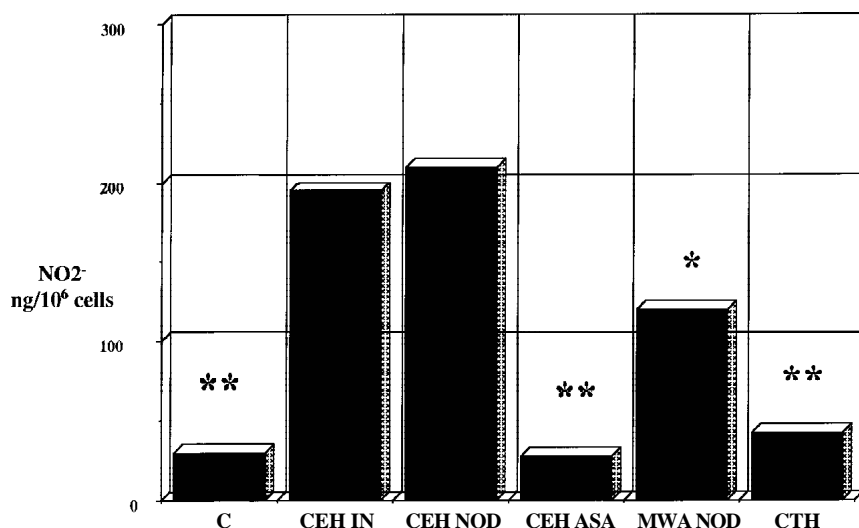
The hypothesis that upregulated NO synthase activity may be related to an activation of the NO-ergic vascular endothelial system is widely accepted for both

migraine and cluster headache, partly on the basis of the demonstrated effectiveness of drugs acting on the cerebral vasculature, such as triptans or hyperbaric oxygen (41, 42). Since the cerebral blood flow velocity has been shown to be unchanged during the pain phase of CEH (43) and in addition oxygen, ergotamine and sumatriptan have been proven to be ineffective in CEH (44), the upregulation of the NO-ergic system that occurs during this pain phase cannot be accounted for by a cerebrovascular dysfunction.

The role of NO in various cytotoxic and inflammatory processes is diverse. Although numerous reports contend that NO can mediate or increase oxidative injury, a strong case can be made that in fact NO is an antioxidant. The evidence so far suggests that protection against oxidative stress requires submicromolar fluxes of NO, which are achievable under normal physiological conditions. However, at higher concentrations of NO the effects of the various reactive nitrogen oxide species (RNOS) may trigger other mechanisms which can lead to tissue injury and consequently to localized pain (45).

Summarizing these concepts, within a putative cervicogenic headache pathophysiology, the observed increase in NO formation in the presence of reactive oxygen species (ROS) may act jointly with IL-1 $\beta$  and TNF- $\alpha$  (31) as deleterious, pro-inflammatory, pain-producing agents. In fact, in addition to familiar inflammatory mediators, such as the prostaglandins and bradykinin, potentially important pronociceptive roles have been proposed for a variety of "exotic" species, including the cytokines and nitric oxide (46). Their activation plays a key role in the induction of neuronal sensitization, a process underlying prolonged painful states, such as may be the case with cervicogenic headache.

Lastly, the observed influence on RNOS after ASA administration could be due to a direct inhibition of the NO synthase (NOS) / cyclooxygenase type 1 and 2 (COX-1 COX-2) ratio (47). The inducible isoforms of these two enzymes both have a deleterious effect in various inflammatory diseases (48), among which cervicogenic headache should be included.



**Fig. 4.** Comparative values of nitrite (NO<sub>2</sub><sup>-</sup>) accumulation from total cell extracts in cervicogenic headache (CEH) patients studied during both spontaneous (CEH IN) and nitric oxide donor (CEH NOD)-elicited pain, and 15 min after the administration of i.v. acetylsalicylic acid (ASA) 1000 mg (CEH ASA). The control group consisted of healthy subjects (C), NOD migraine patients (MWA) and chronic tension headache patients (CTH). \*P < 0.03; \*\*P < 0.002.

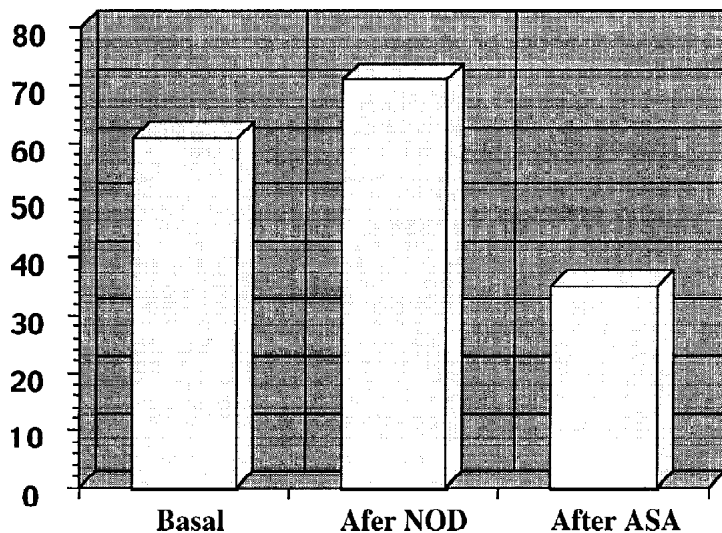


Fig. 5. Visual analogue scale (VAS) evaluation of pain in cervicogenic headache. (NOD nitric oxide donor; ASA acetylsalicylic acid).

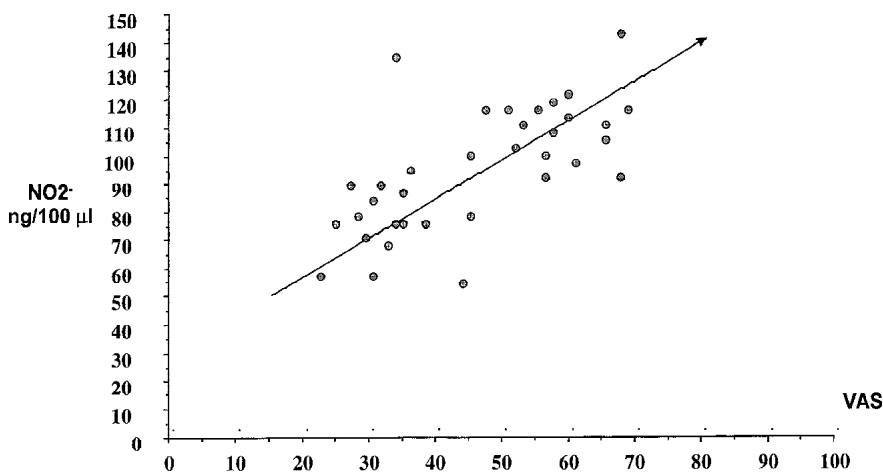


Fig. 6. Correlations between serum NO<sub>2</sub><sup>-</sup> levels and disease activity in cervicogenic headache patients (n = 34), as measured by the mean visual analogue scale (VAS) scores per week ( $r = 0.46$ ;  $p < 0.01$ ; Spearman's rank correlation test).

## Conclusions

In summary, cervicogenic headache seems to represent an ideal experimental model for the study of the multifactorial mechanisms which lie at the origin of headaches stemming from the neck. A growing body of evidence indicates that cervicogenic headache is a distinct nosological entity, clearly distinguishable from both migraine and tension headache (49).

In the future, when the parameters for the clinical, diagnostic and pathophysiological definition of cervicogenic headache have been validated, it will finally be possible to give the proper weight to this under-recognized type of headache (50).

## Acknowledgements

I wish to thank Dr. Giuseppe Stirparo (Institute of Biomedical Technologies, CNR, Rome), Dr. Alessandra Zicari (Department of Experimental Medicine and Pathology, University "La Sapienza", Rome), and Dr. Mara Favilla (Institute of Toxins and Mycotoxins, CNR, Bari) for their valuable help in the realization of these studies. The secretarial assistance of Michaela Schmid is greatly appreciated.

## References

1. MERSKEY H, BOGDUK N: *Classification of Chronic Pain*, 2nd ed., Seattle, International Association for the Study of Pain (IASP) Press, 1994.
2. Headache Classification Committee of the In-

ternational Headache Society: *Classification and Diagnostic Criteria for Headache Disorders, Cranial Neuralgias and Facial Pain*. *Cephalalgia* 1988; 8 (Suppl. 7): 1-96.

3. SJAASTAD O, FREDRIKSEN TA, PFAFFENRATH V: Cervicogenic headache. Diagnostic criteria. *Headache* 1990; 30: 725-6.
4. SJAASTAD O, FREDRIKSEN TA, PFAFFENRATH V: Cervicogenic headache. Diagnostic criteria. *Headache* 1998; 38: 442-5.
5. HUNTER CR, MAYFIELD FH: Role of the upper cervical roots in the production of pain in the head. *Am J Surg* 1949; 78: 775-80.
6. VINCENT M, LUNA RA: Cervicogenic headache. Josey's cases revisited. *Arq Neuropsiquiatr* 1997; 55: 841-8.
7. SJAASTAD A, SAUNTE C, HOVDAL H, BREVIK H, GRONBAEK E: Cervicogenic headache: an hypothesis. *Cephalalgia* 1983; 3: 249-56.
8. SJAASTAD A: Cervicogenic headache: The controversial headache. *Clin Neurol Neurosurg* 1992; 94 (Suppl.): 147-9.
9. POLETTI CE: C2 and C3 pain dermatomes in man. *Cephalalgia* 1991; 11: 155-9.
10. MARTELLETTI P, LA TOUR D, GIACOVAZZO M: Spectrum of pathophysiological disorders in cervicogenic headache and its therapeutic indications. *J Neuromusculoskeletal System* 1995; 3: 182-7.
11. JAEGER B: Are cervicogenic headaches due to myofascial pain and cervical spine dysfunction? *Cephalalgia* 1989; 9: 157-64.
12. MARK BM: Cervicogenic headache. Differential diagnosis and clinical management: Literature review. *Cranio* 1990; 8:332-8.
13. FREDRIKSEN TA, FOUGNER R, TANGERUD A, SJAASTAD O: Cervicogenic headache. Radiological investigations concerning head/neck. *Cephalalgia* 1989; 9: 139-46.
14. BOVIM G: Cervicogenic headache, migraine, and tension-type headache. Pressure-pain threshold measurements. *Pain* 1992; 51:169-73.
15. SAND T, ZWART JA, HELDE G, BOVIM G: The reproducibility of cephalic pain pressure thresholds in control subjects and headache patients. *Cephalalgia* 1997; 17: 748-55.
16. BOVIM G, JENSSEN G, ERICSON K: Orbital phlebography: A comparison between cluster headache and other headaches. *Headache* 1992; 32: 408-12.
17. NERI V: La sindrome del nervo vertebrale. *Riv ONO* 1956; 31: 2-9.
18. BARRÉ JA: Le syndrome sympathique cervical postérieur; le rôle du nerf vertébral et des ses origines dans sa genèse; la acuse ordinaire de l'irritation du nerf vertébral: l'arthrite cervical chronique. *Rev Otoneurophthalmol* 1926; 4: 65-71.
19. SAND T, BOVIM G, HELDE G: Intracutaneous sterile water injections do not relieve pain in cervicogenic headache. *Acta Neurol Scand* 1992; 86: 526-8.
20. BOGDUK N: The anatomical basis for cervicogenic headache. *J Manipulative Physiol Ther* 1992; 15: 67-70.
21. VERNON H, STEIMAN I, HAGINO C: Cervicogenic dysfunction in muscle contraction head-

- ache and migraine: A descriptive study. *J Manipulative Physiol Ther* 1992; 15: 418-29.
22. KRUSZEWSKI P, ZHAO JM, SHEN JM, SJAASTAD O: SUNCT syndrome: Forehead sweating pattern. *Cephalalgia* 1993; 13: 108-13.
23. SJAASTAD O, FREDRIKSEN TA, SAND T, ANTONACI F: Unilaterality of headache in classic migraine. *Cephalalgia* 1989; 9: 71-7.
24. STOVNER LJ: Headache associated with the Chiari type I malformation. *Headache* 1993; 33: 175-81.
25. MICHLER RP, BOVIM G, SJAASTAD O: Disorders in the lower cervical spine. A cause of unilateral headache? A case report. *Headache* 1991; 31: 550-1.
26. MARTELLETTI P, DI SABATO F, GRANATA M, et al.: Epidural steroid-based technique for cervicogenic headache. *Funct Neurol* 1998; 13: 84-7.
27. MARTELLETTI P, DI SABATO F, GRANATA M, et al.: Epidural corticosteroid blockade in cervicogenic headache. *Eur Rev Med Pharmacol Sci* 1998; 2: 25-30.
28. MORIISHI J: The intersegmental anastomoses between spinal nerve roots. *The Anat Rec* 1989; 224: 110-6.
29. MARTELLETTI P, DI SABATO F, GRANATA M, et al.: Failure of long-term results of epidural steroid injection in cervicogenic headache (Letter). *Eur Rev Med Pharmacol Sci* 1998; 2: 10.
30. MARTELLETTI P, GRANATA M, GIACOVAZZO M: Serum interleukin- $\beta$  is increased in cluster headache. *Cephalalgia* 1993; 13: 343-5.
31. MARTELLETTI P, STIRPARO G, GIACOVAZZO M: Proinflammatory cytokines in cervicogenic headache. *Funct Neurol* 1999; 14: 159-62.
32. LORD SM, BARNSLEY L, WALLIS BJ, McDONALD GJ, BOGDUK N: Percutaneous radiofrequency neurotomy for chronic cervical zygapophyseal-joint pain. *N Engl J Med* 1996; 335: 1721-6.
33. VAN SUJLEKOM HA, VAN KLEEF M, BARENDSE GA, SLUIJTER ME, SJAASTAD O, WEBER WE: Radiofrequency cervical zygapophyseal joint neurotomy for cervicogenic headache: A prospective study of 15 patients. *Funct Neurol* 1998; 13: 297-303.
34. GIACOVAZZO M, MARTELLETTI P (Eds.): Special Issue: Nitric Oxide and Migraine. *EOS J Immunol Immunopharmacol* 1998; 18: 45-122.
35. THOMSEN LL, OLESEN J: A pivotal role of nitric oxide in migraine pain. *Ann NY Acad Sci* 1997; 835: 363-72.
36. MARTELLETTI P, STIRPARO G, GIACOVAZZO M: Nitric oxide as coevolution factor in cluster headache pathophysiology. *EOS J Immunol Immunopharmacol* 1999; 19: 19-22.
37. MARTELLETTI P, STIRPARO G, MORRONE S, RINALDI C, GIACOVAZZO M: Inhibition of intercellular adhesion molecule-1 (ICAM-1), soluble ICAM-1 and interleukin-4 by nitric oxide expression in migraine patients. *J Mol Med* 1997; 75: 448-53.
38. STIRPARO G, MARTELLETTI P, FIORE G, LOCOCO E, ZICARI A, LENTI L: Migraine without an aura: Which role for polymorphonuclear neutrophils? *EOS J Immunol Immunopharmacol* 1998; 18: 115-8.
39. MARTELLETTI P, D'ALÒ S, STIRPARO G, RINALDI C, CIFONE G, GIACOVAZZO M: Modulation of nitric oxide synthase by nitric oxide donor compounds in migraine. *Int J Clin Lab Res* 1998; 28: 135-9.
40. MARTELLETTI P, STIRPARO G, FAVILLA M: Nitric oxide (NO)-ergic system in spontaneous and NO-donor elicited pain. *The Journal of Headache and Pain* 2000; 1 (in press).
41. MARTELLETTI P: Serotonin, its receptor and the mechanisms of migraine: A transforming ancient union. *J Serotonin Research* 1995; 1: 59-66.
42. DI SABATO F, ROCCO M, MARTELLETTI P, GIACOVAZZO M: Hyperbaric oxygen in chronic cluster headaches: Influence on serotonergic pathways. *Undersea Hyperbaric Med* 1997; 24: 117-22.
43. MARTELLETTI P, GALLO MF, FIORE G, IANNAZZO P, FUSCO BM, GIACOVAZZO M: Transcranial doppler analysis of blood flow velocities in cervicogenic headache. *Cephalalgia* 1993; 13 (Suppl 13): 174.
44. BOVIM G, SJAASTAD O: Cervicogenic headache: Response to nitroglycerin, oxygen, ergotamine and morphine. *Headache* 1993; 33: 249-52.
45. WINK D, VODOVOTZ Y, GRISHAM MB, et al.: Antioxidant effects of nitric oxide. In *Methods in Enzymology*, Vol. 301, New York, Academic Press 1999: 413-24.
46. MILLAN J: The induction of pain: An integrative view. *Progr Neurobiol* 1999; 57: 1-164.
47. CHEN X, LEVINE JD: NOS inhibitor antagonism of PGE<sub>2</sub>-induced mechanical sensitization of cutaneous C-fiber nociceptors in the rat. *J Neurophysiol* 1999; 81: 963-6.
48. KIMURA S, WATANABE K, YAIJRI Y et al.: Cerebrospinal fluid nitric oxide metabolites in painful diseases. *Neuroreport* 1999; 10: 275-9.
49. POLLMAN W, KEIDEL M, PFAFFENRATH V: Headache and cervical spine. *Cephalalgia* 1997; 17: 801-6.
50. LEONE M, D'AMICO, GRAZZI L, ATTANASIO A, BUSSONE G: Cervicogenic headache: A critical review of the current diagnostic criteria. *Pain* 1998; 78: 1-5.