

# Concurrent increase of cholesterol, sphingomyelin and glucosylceramide in the spleen from non-neurologic Niemann–Pick type C patients but also patients possibly affected with other lipid trafficking disorders

Klaus Harzer<sup>a,\*</sup>, Gero Massenkeil<sup>b</sup>, Eckhart Fröhlich<sup>c</sup>

<sup>a</sup>Institut für Hirnforschung, Universität Tübingen, Calwer Strasse 3, 72076 Tübingen, Germany

<sup>b</sup>Abteilung für Hämatologie und Onkologie, Charité, Campus Virchow-Klinikum Berlin, 13353 Berlin, Germany

<sup>c</sup>Innere Klinik 1, Abteilung für Gastroenterologie, Karl-Olga-Krankenhaus Stuttgart, D-70190 Stuttgart, Germany

Received 21 November 2002; revised 18 January 2003; accepted 20 January 2003

First published online 6 February 2003

Edited by Guido Tettamanti

**Abstract** Niemann–Pick type C disease (NPC) is a neurovisceral (or, extremely rarely, only visceral) lipidosis caused by mutations in the *NPC1* gene or, in a few patients, the *HE1* gene, which encode sterol regulating proteins. NPC is characterised by a complex lipid anomaly including a disturbed cellular trafficking of cholesterol but also multi-lipid storage in visceral organs and brain. Lipids were studied using conventional methods in enlarged spleens that had been removed from five patients for different therapeutic and diagnostic reasons and found to have microscopic signs of lysosomal storage disease not suspected clinically. The spleen lipid findings with a concurrent accumulation of cholesterol, sphingomyelin and glucosylceramide (Acc-CSG) allowed us to suggest NPC diagnoses for these patients, who were free of neurologic symptoms. From two patients no material for confirmatory studies was available, but in two other patients NPC diagnoses could be confirmed with the filipin cytochemical cholesterol assay and *NPC1* gene analysis, respectively. However, these tests and also *HE1* gene analysis were negative in a third patient. Since the Acc-CSG lipid pattern seems to indicate a multi-lipid trafficking defect rather than being highly specific for NPC, this patient, if not affected with very atypical NPC, may be a candidate for a different lipid trafficking disorder. The Acc-CSG pattern was considered to be similar to the lipid pattern known for the lipid rafts, these functional cell structures being probably disorganised and accumulated in late endosomes and lysosomes of NPC cells.

© 2003 Published by Elsevier Science B.V. on behalf of the Federation of European Biochemical Societies.

**Key words:** Niemann–Pick type C disease; Spleen lipid; Cholesterol; Sphingolipid; Ceramide; Raft

## 1. Introduction

Genetic defects in the sterol regulating proteins NPC1 and, very rarely, HE1 (= NPC2) cause a fatal lipid storage disease, Niemann–Pick type C disease (NPC) [1–3]. A well known

aspect of the complex lipid anomaly in NPC is the lysosomal accumulation of cholesterol in cells (e.g. fibroblasts) that are cultured from typically affected patients, challenged with exogenous low density lipoprotein (LDL) cholesterol and analysed using the cholesterol reagent filipin [4,5]. This in vitro effect seems to reflect the disturbed mobilisation, partitioning and recycling (briefly: trafficking) of cholesterol considered as an essential pathogenetic factor in NPC [6].

However, in visceral tissues (e.g. spleen) from NPC patients accumulations of sphingolipids such as sphingomyelin and glycolipids are concurrent to the increase in cholesterol [1,7,8], while in brain tissue distinct cholesterol and sphingomyelin increases are absent but accumulations of glycolipids including gangliosides are present [9]. It has been assumed that not only the trafficking of cholesterol but also that of other lipids is disturbed in NPC, but the exact mechanisms of such a multi-lipid trafficking defect are not well understood [10].

In recent studies the organisation of so-called lipid rafts, which are functional lipid microdomains enriched in cholesterol [11], sphingomyelin [12] and glycolipids [13] in lateral cell regions, was suggested to be impaired in NPC [14]. The disturbed lipid cycling in NPC cells seems to prevent the formation of cholesterol microdomains equivalent to rafts in the cell periphery [15] but, instead, lead to overcrowding of lipid structures in late endocytic organelles including lysosomes, and lipid storage in NPC cells could result from falsely partitioned, lysosomally sequestered raft material [14,16].

Interestingly, the lipid pattern in raft microdomains [11–13] is similar to that found in visceral, in particular splenic NPC tissue [7] and the sphingolipids stored in NPC contain a high percentage of saturated fatty acyl chains [17], tight packing of such chains favouring raft formation [11,18]. Therefore, the possibility was considered that the NPC spleen lipid pattern with a concurrent accumulation of cholesterol, sphingomyelin, glucosylceramide (Acc-CSG) and some other lipids [1,7,19] reflects a relatively unspecific accumulation of normal lipid membrane structures like the rafts, the Acc-CSG lipid pattern suggesting a general affection of lipid trafficking involving rafts.

We used conventional methods for lipid analysis of human spleens, which were removed for different therapeutic and diagnostic reasons, including the clarification of splenomegaly. We discovered the Acc-CSG lipid pattern in five patients and suggested NPC diagnoses for these patients, who had a

\*Corresponding author. Fax: (49)-7472-931 826.

E-mail address: harzer-rottenburg@t-online.de (K. Harzer).

**Abbreviations:** Acc-CSG, combined accumulation of cholesterol, sphingomyelin and glucosylceramide; NPC, Niemann–Pick type C disease; *NPC1* and *NPC2* (= *HE1*), the two NPC genes, and the respective proteins NPC1 and HE1; TLC, thin-layer chromatography

Table 1  
Non-neurologic patients with splenic Acc-CSG

| Patient no.    | Age at diagnosis/last examination (years) | Splenomegaly                    | Laboratory signs: filipin test (FIL) and others                                   | Niemann–Pick cells or sea-blue histiocytes in bone marrow (BM) or spleen (SP) | Clinical comments  |
|----------------|---|---------------------------------|---|---|--|
| 1              | 19/20                                     | +                               | FIL not done (no cells available)<br>FIL Ø on repeated assays                     | BM not tested, SP ++  | spleen ruptured in car accident and removed  |
| 2              | 26/28                                     | +++; mesenteric lymphadenopathy |   | BM +, SP ++   | spleen removed after periods of fever; accessory spleen not removed but now increased; cyclothymic illness |
| 3              | 52/55                                     | ++                              | FIL +; thrombocyto-penia, mild anaemia; ferritin ↑                                | BM ++, SP ++  | spleen removed for hypersplenism; 'fatty liver' by ultrasound  |
| 4              | 53/56                                     | +++; also liver enlarged        | FIL not done (no cells); liver enzymes, cholesterol, triglycerides and ferritin ↑ | BM not tested, SP ++  | spleen removed for suspected malignancy; coronary heart disease  |
| 5 <sup>a</sup> | 54/64                                     | ++                              | FIL +   | BM +, SP ++   | spleen removed for suspected malignancy <sup>b</sup> ; parental consanguinity                              |

Symbols: ++, distinct; +, present; Ø, absent sign; ↑, increased parameter.

<sup>a</sup>Homozygous *NPC1* mutations (see [21] for family no. 24).

<sup>b</sup>Earlier clinical report [22].

diagnosis of unclear lysosomal storage disease only on the histopathology of their removed spleens, but were previously undiagnosed and, in particular, always free of neurologic symptoms. Since NPC usually presents as a neurovisceral lipidoses with severe neurodegeneration, non-neurologic [20,21] or otherwise atypical NPC patients [1] may often remain undiagnosed.

There was consent only from three patients to confirmatory studies for the suggested NPC diagnosis, which in fact could be corroborated in two of them by *NPC1* gene analysis and cytochemical filipin testing, respectively. However, in the third patient, these tests and also *HEI* gene analysis were negative, raising the question whether the finding of splenic Acc-CSG may also have a potential in identifying candidates for lipid trafficking disorders possibly different from NPC.

## 2. Materials and methods

### 2.1. Tissue materials and patients

Formalin-fixed splenic tissues from different patients with lipidoses were collected in our diagnostic laboratory in Tübingen, Germany. Clinical information on the patients being the subject of this study is provided in Table 1. These patients felt well or complained of fatigue. The reasons for admission were splenic rupture in an accident in patient no. 1, unclear fever periods after a stay in India in patient no. 2 and splenomegaly in patients 3–5. Splenomegaly in patients 1 and 2 was noted only after admission. The spleen volumes were found to be increased by about 30% to about 400% over its normal size corrected for age. In patients 3–5 there was an inhomogeneous structure of the sonographed spleens with highly echogenic, up to 5 cm large, round foci [22]. These lesions were the reason for splenectomy in order to exclude malignant tissue transformation. The first suspicion of a lysosomal storage disease, in particular lipidosis, came from the histologic findings of foamy or sea-blue storage macrophages in the spleen, or bone marrow cytologic findings of Niemann–Pick cells or sea-blue histiocytes.

### 2.2. Cell culture and cytochemical testing for cholesterol accumulation (filipin method)

Before use, the skin fibroblast cultures from patients were maintained for 1 week in standard medium 199 (C.C. Pro GmbH, Neustadt, Germany) with glutamine and 10% (v/v) foetal calf serum under an atmosphere of 5% CO<sub>2</sub>. Lysosomal cholesterol present after challenging the cells with exogenously added LDL was analysed using a described fluorescence microscopic method with the cholesterol reagent filipin [5].

### 2.3. Lipid determination

Formalin-fixed splenic tissue samples were available (see Section 2.3.1). Tissue was homogenised in 50 volumes of chloroform/methanol (2/1, by vol.) and stirred for 1 h. Centrifuged supernatant (total lipid extract) was analysed by thin-layer chromatography (TLC) as described [8] with the following modifications. For the determination of *sphingomyelin* and *glucosylceramide*, amounts corresponding to 1–3 mg tissue wet weight were applied to start positions on thin-layer plates (Merck, Darmstadt, Germany, no. 1.05721., activated for 10 min at 60°C) as 15 mm streaks. Test amounts of standard cell total lipid extract were also applied. The standard extract had been calibrated in comparison with lipid standards (cholesterol, no. C8667, Sigma, Deisenhofen, Germany; sphingomyelin from bovine brain, no. 4700, Roth, Karlsruhe, Germany; glucosylceramide, prepared in our laboratory by preparative TLC from Gaucher disease spleen; ceramides, natural mixture, no. 22100, Applied Science Lab., State College, PA, USA). Chromatographic solvent systems were chloroform/methanol/water (14/6/1, by vol., solvent A) and *n*-heptane/ethyl ether/conc. acetic acid (80/6/1, by vol., solvent B). Plates were chromatographed in solvent A, 16 cm upwards from start, dried and then chromatographed in solvent B, 19 cm upwards from start. The dried plates were stained by spraying with conc. acetic acid/conc. sulphuric acid/4-methoxybenzaldehyde (490/10/3, by vol.) and heating (25 min, 140°C). After 1 day equilibration in the dark, lipid spot reflectometric densi-

tometry was carried out at 600 nm (Fig. 1). Some precautions [23] and lipid identity criteria [8] were carefully observed. Scanned lipid peak areas were quantified in comparison with peak areas from the standard extract. Since in these chromatograms, cholesterol peaks were too high and too close to the front for precise evaluation, and ceramide peaks were not separated, *cholesterol* and *ceramide* were quantified on separate TLC plates. In the method described for cholesterol [24], lipid extract from 0.3–0.9 mg tissue wet weight, and in the method for ceramide [25], extract from 4–8 mg wet weight, was used, as a starting sample. The ceramide determination included three instead of two [25] main ceramide fractions, the third fraction having distinctly lower mobility on TLC (see component N in chromatogram of used ceramide standard as depicted in an earlier paper [26]) than the other fractions.

**2.3.1. Assay of chemical resistance of cholesterol, sphingomyelin, glucosylceramide and ceramide against formalin.** Deep-frozen native spleen tissue (0.1 g) from a juvenile NPC patient was homogenised in 1.33 mol/l aqueous formaldehyde solution (5 ml). From this homogenate, 1 ml was immediately dried and lipid-extracted (extract A) and 1 ml was incubated in a sealed vial for 2 weeks at 37°C, dried and extracted (extract B). Determination of lipids in extracts A and B was according to Section 2.3.

### 3. Results

#### 3.1. Cytochemical findings

Fibroblast cultures were available from patients nos. 2, 3 and 5 (Table 1). In the used cholesterol assay with filipin, cells from patients 3 (Fig. 1) and 5 were positive, with distinct amounts of cholesterol-positive, fluorescent perinuclear lysosomal granules (Fig. 1) in at least three of five experiments, but cells from patient no. 2 remained negative in six experiments.

#### 3.2. Biochemical findings in spleen samples

In Fig. 2 the lipid pattern with Acc-CSG in spleen tissue is shown for patient no. 2 in comparison with a control. These lipids have long been accepted in the literature as being resistant against formalin [19,27,28], and the present experiment of long-term incubation of homogenised tissue with formalin (Section 2.3.1) resulted in quantitatively unchanged cholesterol, sphingomyelin, glucosylceramide and also ceramide in the

extracts (data not shown); some small differences are explained by the methodological variability (see Table 2). The Acc-CSG is the essential part of the known lipid changes in NPC spleen [7] and was determined quantitatively in the present five patients, where also the concentration of ceramide was measured. The results (Table 2) show very similar Acc-CSG, but normal or only very slightly higher than normal ceramide content in the spleens of these patients, in comparison with normal and pathologic controls. However, the pathologic control with *HE1* (= *NPC2*) mutations had a distinct increase in the splenic ceramide concentration (Table 2). Other lipids than those listed in Table 2 could not be studied for their changes [1,7,19] because of their formalin sensitivity (see also caption to Fig. 2).

**3.2.1. Additional biochemical findings.** In patients nos. 2, 3 and 5, Niemann–Pick disease type B and Gaucher disease, the most important differential diagnoses for adult lipidosis patients, were excluded by normal results of sphingomyelinase and  $\beta$ -glucocerebrosidase activity assays [22] in fibroblast homogenates, using natural substrates, i.e. tritium-labelled sphingomyelin and glucosylceramide, respectively. Compared to the normal control range of sphingomyelinase activity (10–40 nmol substrate cleaved per h and mg fibroblast protein [22]), patient no. 2's activity was slightly above the upper control limit, no. 3's activity well within the control range, but no. 5's activity very close to the lower control limit. Compared to the normal control range of  $\beta$ -glucocerebrosidase activity (0.3–0.8 nmol/h mg protein, low substrate concentration method, unpublished), the activities of patients 2, 3 and 5 were all well within this range. But also in patients 1 and 4, where no appropriate enzyme test materials were available, Niemann–Pick type B and Gaucher disease were almost completely excluded by the splenic Acc-CSG finding, which lipid pattern is well discriminated from the patterns in Niemann–Pick B and Gaucher disease (Table 2).

#### 3.3. Molecular findings

Molecular findings in patient no. 5 were published earlier

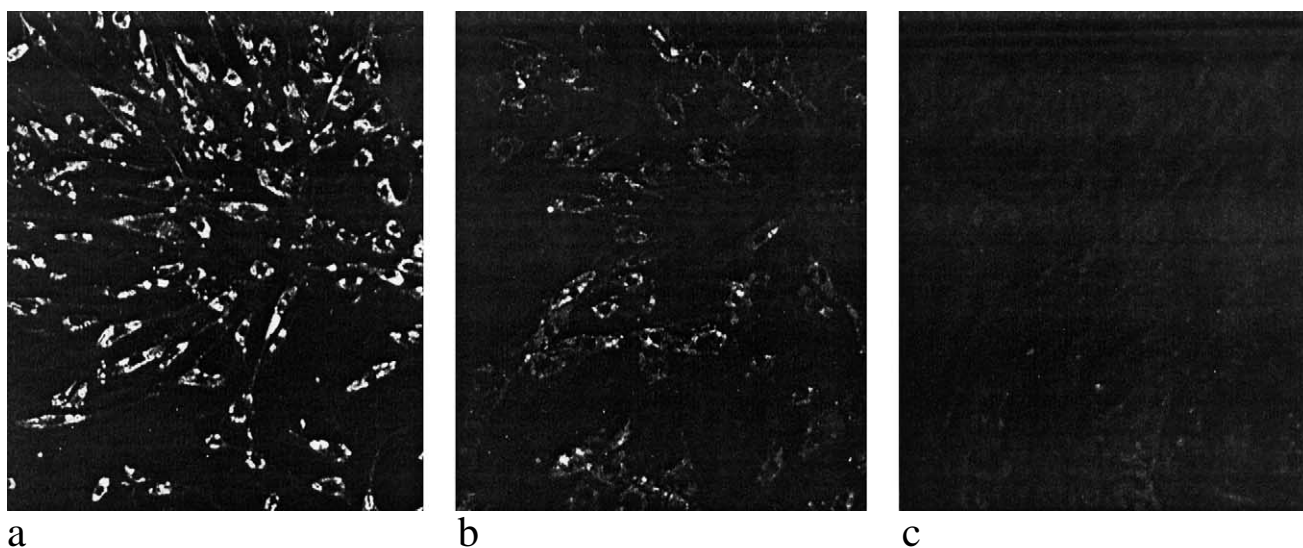


Fig. 1. Cytochemical assay of cholesterol with the filipin method [5] in skin fibroblast cultures. Cholesterol accumulation is seen by brightly fluorescent cellular regions surrounding the fluorescence-negative areas of the cell nuclei. a: Early-infantile Niemann–Pick type C (*NPC1* mutant; unpublished) disease. b: Present patient no. 3 (Tables 1 and 2). c: Normal control proband (48 years old). Magnification:  $\times 65$ .

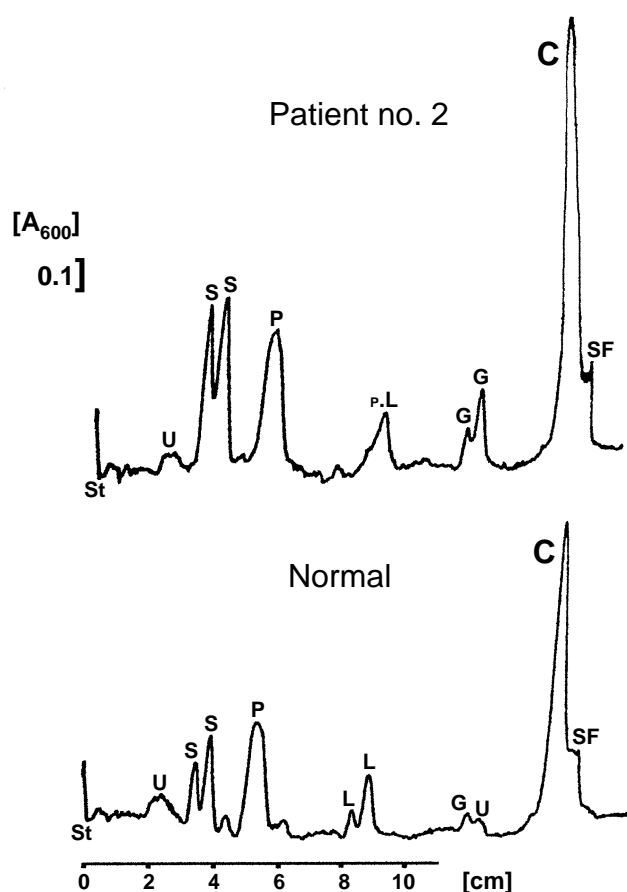


Fig. 2. Densitometric scans of total lipid extracts from formalin-fixed spleen corresponding to 1.4 mg tissue wet weight ('Patient no. 2', 26-year-old, see Tables 1 and 2) or 2.4 mg wet weight ('Normal', 29-year-old control proband), chromatographically separated and stained on a silicagel thin-layer plate. Abscissa, distance from chromatographic start ('St') position; ordinate, linear for absorption at 600 nm, a 0.1 absorption unit is marked. 'SF', solvent front. Peak identification (some lipids have two chemical subtypes, i.e. two peaks): C, cholesterol; G, glucosylceramide; L, lactosylceramide; P, phospholipids and formalin-induced products; S, sphingomyelin; U, unidentified. Seen are increased cholesterol, glucosylceramide and sphingomyelin peaks in patient no. 2 as compared to normal control (note different wet weight equivalents). C, G and S are resistant against formalin (see Section 3); also, L is formalin-resistant, but only L is additionally and artificially released by formalin action from gangliosides (unpublished).

(see [21] for family no. 24) and included homozygous *NPC1* mutations in the cysteine-rich luminal loop of the NPC1 protein. Other molecular findings referred to in this study came from generous personal communications for the present study by Marie T. Vanier, Laboratoire Fondation Gillet-Mérrieux, Centre Hospitalier Lyon-Sud, Pierre Bénite, France. Starting from fibroblast cultures of patient no. 2, no mutations were found in the *NPC1*, nor in the *HE1* gene, but it was emphasised that the, though extended, *NPC1* analysis may still have missed peculiar *NPC1* alterations. In the cells of patient no. 3, one presumably pathogenic mutation on one *NPC1* allele was determined, and no *HE1* mutation was found (unpublished).

#### 4. Discussion

Although the lipid abnormalities present in NPC visceral tissue, in particular spleen, have long been known [1,7,8], they were not strictly considered in the not well elucidated scenario of disturbed lipid trafficking in NPC. The Acc-CSG pattern as the major part of the NPC spleen lipid changes has thus far been observed only in this disease and never correlated with other lipid disorders. In fact, the Acc-CSG pattern may be relatively unspecific in a sense that it merely indicates a general disorganisation of cellular lipids in which the accumulation of cholesterol, sphingomyelin and glycolipids may reflect increased amounts of normal membrane compartments which at their own have similarly high contents in those lipids. Examples of such compartments are the lipid rafts (see Section 1). It should be mentioned that the lipid composition of rafts may not be very constant in different cells, but a tight assembly of cholesterol and sphingolipids containing saturated acyl chains [18] seems to be essential for these structures, the sphingolipids probably varying in their sphingomyelin [12], neutral and acidic glycosphingolipid patterns [11]. This variability may give rise, for example, to rafts with high cholesterol, sphingomyelin and glucosylceramide content in NPC visceral tissue, but also rafts with high ganglioside content in NPC brain. Rafts seem to have roles in cell signalling [12] and serve as platforms for protein and lipid sorting and trafficking processes [11,14,29]. It is remarkable that a fraction of murine NPC1 protein colocalises with rafts [30]. NPC1 protein being defective in most human NPC cases [1,21], it is tempting to propose a raft disorganisation that compromises signalling and other functions in NPC cells. The involvement in cell signalling and the high sphingolipid content of rafts have

Table 2  
Lipids in formalin-fixed spleen (values as  $\mu\text{g}/\text{mg}$  tissue wet weight)

|  | Total lipids | Cholesterol | Sphingomyelin | Glucosylceramide | Ceramide |
|--|--------------|-------------|---------------|------------------|----------|
| Normal controls ( $n=5$ ; 2-, 8-, 29-, 48- and 56-year-old), range | 19–25        | 1.9–2.9     | 1.1–2.0       | 0.05–0.10        | 0.2–0.45 |
| Methodological variation coefficient (%)                           | 9            | 12          | 12.5          | 20.5             | 22.5     |
| Present patients (see Table 1)                                     |              |             |               |                  |          |
| no. 1  | 45           | 7.7         | 6.2           | 1.0              | 0.45     |
| no. 2  | 44           | 9.2         | 4.8           | 1.1              | 0.5      |
| no. 3  | 50           | 10.5        | 8.8           | 1.0              | 0.3      |
| no. 4  | 51           | 9.7         | 7.7           | 0.9              | 0.45     |
| no. 5 <sup>a</sup>   | 48           | 9.0         | 6.6           | 1.4              | 0.5      |
| Late-infantile neurologic NPC <sup>b</sup>                         | 60           | 11.9        | 10.3          | 2.5              | 0.6      |
| Early-infantile NPC with <i>HE1</i> (=NPC2) mutations <sup>c</sup> | 46           | 11.0        | 9.9           | 0.85             | 0.95     |
| Niemann–Pick disease type B (30-year-old)                          | 55           | 5.5         | 21.5          | 0.05             | 0.25     |
| Gaucher disease type 1 (22-year-old)                               | 79           | 1.4         | 1.4           | 37               | 0.4      |

<sup>a</sup>Homozygous *NPC1* mutations (see ref. [21] for family no. 24).

<sup>b</sup>Published earlier [8] and re-studied.

<sup>c</sup>Homozygous *HE1* mutations (see ref. [31] for Case 4) in an earlier published patient [32].



also suggested a role of free ceramide [11,12], and experimental raft models can be stabilised by an increased ceramide proportion, although natural rafts usually seem to be free of high ceramide proportions [11]. We were still interested whether the Acc-CSG lipid pattern as a putative sign of raft accumulation in NPC spleen was associated with an increase in ceramide, but analysis of ceramide on TLC revealed normal or only very slightly elevated ceramide levels in the present five patients. However, the pathologic control of the *HE1* (*NPC2*) mutated, early-infantile patient had an about three-fold elevated concentration in all ceramide fractions studied (see Section 2). The present quantitative data show about twice higher control spleen ceramide concentrations than reported in the literature [28], which may be due to methodological differences.

In the present study the demonstration of the Acc-CSG pattern in visceral patient tissue was supposed to identify patients with NPC or similar lipid trafficking disorders. In fact, patients with previously undiagnosed NPC were identified. The Acc-CSG pattern was also equally present in NPC patients of both the *NPC1* and *HE1* gene mutated type [19,31,32] (Table 2). However, one Acc-CSG-positive patient (no. 2 in Table 1) but with negative *NPC1* and *HE1* molecular results and also negative cholesterol cytochemistry using filipin was provisionally diagnosed as having a very atypical NPC condition or other lipid trafficking disorder.

A clinical aspect of the present study was that of providing some information on the very rare variant of non-neurologic NPC disease [20,21]. The fatal downhill course in most NPC patients is dominated by progressive neurodegeneration, where muscle weakness, ataxia, epilepsy and dementia are some frequent features [1]. However, the present patients, including those with a confirmed NPC diagnosis, have remained free of neurologic symptoms; no. 3 (Table 1) is working as usual, taking responsibility in a penal institution, and he recently had an unremarkable magnet resonance neuro-imaging examination; no. 5 seemed to be slightly simply structured psychically but is a friendly and active lady, fully able to take care of herself [21]. These two patients would not have been diagnosed as having NPC, unless their splenic Acc-CSG lipid pattern had been shown. Screening for Acc-CSG can also be done in routinely formalin-fixed spleen. Enlarged spleens present in very different diseases but including a number of lysosomal storage disorders are sometimes removed for therapeutic or diagnostic reasons.

In conclusion, the Acc-CSG lipid pattern identified in pathologic spleen tissue is of diagnostic use, but, in addition, it might have a potential in identifying candidates for lipid trafficking disorders similar to, or possibly different from NPC. The Acc-CSG pattern might also be viewed as a sign of a peculiar pathology of the lipid rafts in these disorders. The present lipid study using conventional methods was thought to stimulate investigations on the mechanisms of putative lipid trafficking disorders in selected patients.

**Acknowledgements:** The molecular work of Dr. M.T. Vanier, Centre Hospitalier, Lyon-Sud, France, on the *NPC1* and *HE1* genes of patients nos. 2 and 3 provided invaluable help for the present study. The help of Dr. B. Kustermann-Kuhn, Universitäts-Kinderklinik, Tübingen, Germany, in the cytochemical cholesterol assays with filipin is thankfully acknowledged.

## References

- [1] Patterson, M.C., Vanier, M.T., Suzuki, K., Morris, J.A., Carstea, E., Neufeld, E.B., Blanchette-Mackie, J.E. and Pentchev, P.G. (2001) in: *The Metabolic and Molecular Bases of Inherited Disease*, 8th edn. (Scriver, C.R., Beaudet, A.L., Sly, W.S. and Valle, D., Eds.), Vol. 3, pp. 3611–3633, McGraw-Hill, New York.
- [2] Morris, J.A., Zhang, D., Colemann, K.G., Nagle, J., Pentchev, P.G. and Carstea, E.D. (1999) *Biochem. Biophys. Res. Commun.* 26, 493–498.
- [3] Naureckiene, S., Sleat, D.E., Lackland, H., Fensom, A., Vanier, M.T., Wattiaux, R., Jadot, M. and Lobel, P. (2000) *Science* 290, 2298–2301.
- [4] Liscum, L., Ruggiero, R.M. and Faust, J.R. (1989) *J. Cell Biol.* 108, 1625–1636.
- [5] Vanier, M.T., Rodriguez-Lafrasse, C., Rousson, R., Gazzah, N., Juge, M.-C., Pentchev, P.G., Revol, A. and Louisot, P. (1991) *Biochim. Biophys. Acta* 1096, 328–337.
- [6] Roff, C.F., Goldin, E., Comly, M.E., Blanchette-Mackie, J., Cooney, A., Brady, R.O. and Pentchev, P.G. (1992) *Am. J. Hum. Genet.* 42, 593–598.
- [7] Vanier, M.T. (1983) *Biochim. Biophys. Acta* 750, 178–184.
- [8] Harzer, K., Schlote, W., Peiffer, J., Benz, H.U. and Anzil, A.P. (1978) *Acta Neuropathol. (Berlin)* 43, 97–104.
- [9] Vanier, M.T. (1999) *Neurochem. Res.* 24, 481–489.
- [10] Liscum, L. (2000) *Traffic* 1, 218–225.
- [11] Xu, X., Bittman, R., Duportail, G., Heissler, D., Vilcheze, C. and London, E. (2001) *J. Biol. Chem.* 276, 33540–33546.
- [12] Dobrowsky, R.T. (2000) *Cell Signal.* 12, 81–90.
- [13] Ohanian, J. and Ohanian, V. (2001) *Cell Mol. Life Sci.* 58, 2053–2068.
- [14] Lusa, S., Blom, T.S., Eskelinen, E.-L., Kuusimäki, E., Månsson, J.-E., Simons, K. and Ikonen, E. (2001) *J. Cell Sci.* 114, 1893–1900.
- [15] Kruth, H.S., Ifrim, I., Chang, J., Addadi, L., Perl-Treves, D. and Zhang, W.Y. (2001) *J. Lipid Res.* 42, 1492–1500.
- [16] Simons, K. and Gruenberg, J. (2000) *Trends Cell Biol.* 10, 459–462.
- [17] Koike, T., Ishida, G., Taniguchi, M., Higaki, K., Ayaki, Y., Saito, M., Sakakihara, Y., Iwamori, M. and Ohno, K. (1998) *Biochim. Biophys. Acta* 1406, 327–335.
- [18] Brown, D.A. and London, E. (2000) *J. Biol. Chem.* 275, 17221–17224.
- [19] Elleder, M., Houšková, H., Zeman, J., Ledvinová, J. and Poupětová, H. (2001) *Virchows Arch.* 39, 206–211.
- [20] Fensom, A.H., Grant, A.R., Steinberg, S.J., Ward, C.P., Lake, B.D., Logan, E.C. and Hulman, G. (1999) *J. Inher. Metab. Dis.* 22, 84–86.
- [21] Millat, G., Marçais, C., Tomasetto, C., Chikh, K., Fensom, A.H., Harzer, K., Wenger, D.A., Ohno, K. and Vanier, M.T. (2001) *Am. J. Hum. Genet.* 68, 1373–1385.
- [22] Fröhlich, E., Harzer, K., Heller, T. and Rühl, U. (1990) *Ultraschall Med.* 11, 119–122.
- [23] Harzer, K., Wässle, W., Sandhoff, K. and Jatzkewitz, H. (1968) *Z. Anal. Chem.* 243, 527–536.
- [24] Harzer, K. and Kustermann-Kuhn, B. (2001) *Clin. Chim. Acta* 305, 65–73.
- [25] Levade, T., Enders, H., Schliephacke, M. and Harzer, K. (1995) *Eur. J. Pediatr.* 154, 643–648.
- [26] Harzer, K. and Benz, H.U. (1973) *J. Neurochem.* 21, 999–1001.
- [27] Jatzkewitz, H. (1964) *Physiol. Chem. Hoppe-Seyler* 336, 25–39.
- [28] Hůlková, H., Červenková, M., Ledvinová, J., Tocháčková, M., Hřebíček, M., Poupětová, H., Běfekadu, A., Berná, L., Paton, B.C., Harzer, K., Böör, A., Šmid, F. and Elleder, M. (2001) *Hum. Mol. Genet.* 10, 927–940.
- [29] Ikonen, E. (2001) *Curr. Opin. Cell Biol.* 13, 470–477.
- [30] Garver, W.S., Heidenreich, R.A., Erickson, R.P., Thomas, M.A. and Wilson, J.M. (2000) *J. Lipid Res.* 41, 673–687.
- [31] Millat, G., Chikh, K., Naureckiene, S., Sleat, D.E., Fensom, A.H., Higaki, K., Elleder, M., Lobel, P. and Vanier, M.T. (2001) *Am. J. Hum. Genet.* 69, 1013–1021.
- [32] Schofer, O., Mischo, B., Püschel, W., Harzer, K. and Vanier, M.T. (1998) *Eur. J. Pediatr.* 157, 45–49.