

Particularities of Renal Manifestations in Chronic Viral Hepatitis

V.F. IOVANESCU¹, C.T. STREBA², D.O. ALEXANDRU³,
A.F. CONSTANTINESCU¹, C.C. VERE², I. ROGOVEANU², E. MOTA⁴

¹PhD Student, University of Medicine and Pharmacy of Craiova, Romania

²Gastroenterology Department, University of Medicine and Pharmacy of Craiova, Romania

³Department of Medical Informatics and Biostatistics, University of Medicine and Pharmacy of Craiova, Romania

⁴Department of Nephrology, University of Medicine and Pharmacy of Craiova, Romania

ABSTRACT: Introduction: Chronic viral hepatitis represent major health problems worldwide, with an evolution that is sometimes marked by a series of extrahepatic manifestations. Among these, kidney disease may occur, either as glomerulonephritis, and/or renal dysfunction. Material and methods: The purpose of this study was to achieve a complete assessment of the liver and kidney function in a series of patients diagnosed with chronic viral hepatitis, in order to identify a possible kidney disease in this context. 104 patients with chronic viral hepatitis B and C, aged between 25 and 80, were included in the study. These patients were assessed by a series of tests that allowed us to perform a complete evaluation of both liver and kidney function: liver cytolysis enzymes, serum bilirubin, markers of cholestasis, markers of viral infection, urinalysis, albuminuria, electrophoresis of urinary proteins, urea, creatinine, and abdominal ultrasound. Results: Glomerular injury was a rare finding in patients with chronic hepatitis. Patients with chronic hepatitis B had glomerular disease in 5,88 % of cases, while 10 % of the patients with hepatitis C presented this type of renal disease. Acute kidney injury was not identified in our patient group. None of the patients in the hepatitis B study group presented chronic kidney disease. CKD was present in two patients with chronic hepatitis C that had no other associated conditions.

KEYWORDS: chronic hepatitis B, chronic hepatitis C, extrahepatic manifestations in hepatitis, glomerular injury in hepatitis, acute kidney injury, chronic kidney disease

Introduction

Chronic viral hepatitis represent major health problems worldwide, and this fact is due to a number of reasons. Among these, the incidence of chronic viral hepatitis is one of the most important, given the fact that it reaches concerning numbers, which go as high as 350 million patients chronically infected with hepatitis B virus, and probably another 200 million with hepatitis C virus. The concern regarding chronic viral hepatitis is strongly related to the evolution of the disease, which can lead to liver cirrhosis and hepatocellular carcinoma, conditions that are associated with poor prognosis. Yet, there are other serious extrahepatic complications that may occur in the evolution of chronic viral hepatitis, complications that can be responsible for an unfavorable evolution [1,2]. Among these, no exception is made by the renal manifestations that may occur. Numerous authors have described the association between viral hepatitis and renal disease, although the causality relationship is often very difficult to prove. Moreover, pathogenic mechanisms have not been completely uncovered, making it sometimes difficult to approach these patients. Kidney involvement in the context of chronic

viral hepatitis may take different forms, depending on the type of the hepatitis virus and many other factors, such as age, gender and ethnicity [3]. The most common type of renal involvement is represented by glomerular disease [4,5], with a series of particularities depending on the type of the hepatitis virus. In chronic hepatitis B infection, the glomerulopathies that may occur are represented by membranous glomerulonephritis, which is the most frequent [6,7], membranoproliferative glomerulonephritis [8], IgA nephropathy [9] and other rare types, for instance glomerulosclerosis and polyarteritis nodosa [10,11,18]. Regarding chronic viral hepatitis C, the most frequent type of glomerular disease is represented by membranoproliferative glomerulonephritis [12,13,14], sometimes associated with cryoglobulinemia [15]. The evolution of chronic viral hepatitis can also be marked by the occurrence of renal dysfunction, especially chronic kidney disease. Acute kidney injury is exceptionally rare, with few cases described in literature, and it appears as a consequence of glomerulonephritis [5,7]. Chronic kidney disease is most often the consequence of the progression of different glomerular diseases that may complicate viral hepatitis [11,16,17].

Material And Methods

The main purpose of this study was to perform a complete clinical and biological evaluation of a representative group of patients diagnosed with chronic viral hepatitis B or C, from two different perspectives: first, the liver disease and second, the kidney function. The main goals of the study were represented by: the initial identification, through specific investigations, of kidney disease that may have occurred in the evolution of chronic viral hepatitis; identifying the type and particularities of the renal disease that occurred in this context, regarding the etiology of the viral hepatitis; assessing the type and stage of renal dysfunction in those cases where it was present.

We conducted a prospective study on 104 patients that were diagnosed with chronic hepatitis B and C, which were hospitalized in the Clinical Emergency Hospital of Craiova, Romania. The patients were assessed using all clinical, biological and imagistic methods available in this facility. Thus, in each patient, we evaluated the presence or absence of hepatic cytolysis, levels of serum bilirubin, the presence or absence of markers of cholestasis, markers of viral infection and performed abdominal ultrasound, in order to obtain a complete assessment of the liver disease. Kidney disease, which was demonstrated in a number of cases, was diagnosed using a series of tests, including urine tests such as Addis-Hamburger test, albuminuria, albuminuria/urinary creatinine

ratio, electrophoresis of urinary proteins, urea and creatinine. In those cases where signs of kidney disease were found, we determined the glomerular filtration rate, in order to identify and assess an eventual renal dysfunction. After we evaluated the entire group of patients, we proceeded to analyzing the cases in relation to a series of characteristics, which will be displayed in detail. The study was approved by the Ethics Committee of the University of Medicine and Pharmacy of Craiova, Romania, with each participant having signed an informed consent and was conducted in compliance with the Declaration of Helsinki.

Statistical analysis was performed using Microsoft Excel and IBM SPSS Statistics 20.0 for processing the data.

Descriptive analysis of the study group was performed with Excel, using Pivot Tables, Functions-Statistical, Charts and Data Analysis module, while complex statistical tests (Z test for proportions, Chi Square test) were performed using SPSS.

Results And Discussions

Our study was conducted on a total of 104 patients, from which 36 patients, representing 34,6%, were males, while 68 patients, representing 65,4%, were females. These differences proved to be statistically significant (Z test for proportions < 0.001 HS), taking into consideration that in our region females represent 51.36 % from general population, according to 2011 population census.

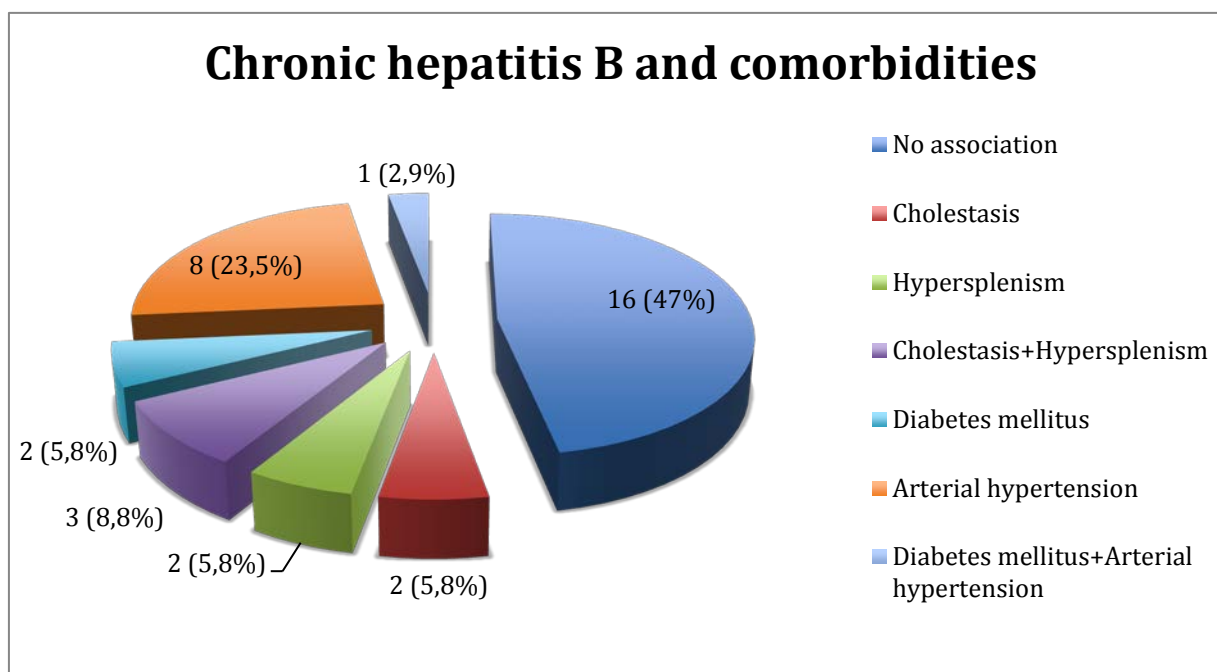


Fig.1. Chronic hepatitis B and comorbidities

The majority of the patients included in this study were diagnosed with chronic hepatitis C – 70 patients, accounting for 67,3% of the study group, while chronic hepatitis B infection was present in 34 patients (32,69%).

We made correlations between different types of chronic viral hepatitis and several clinical parameters and associated conditions. The main correlations were made between chronic viral hepatitis and presence or absence of cholestasis, hypersplenism, as well as arterial hypertension and type II diabetes mellitus.

Hepatitis B study group

Regarding chronic hepatitis B infection, the main associations are shown in Fig.1. In the hepatitis B group, an important percentage of patients (47%) had no associated condition. The most frequent comorbidity was represented by arterial hypertension, which was present in 23,5 % of the patients. While type II diabetes mellitus alone was found in 2 patients, only one patient presented both arterial hypertension and diabetes

mellitus. Cholestasis alone was found in 2 patients, as well as hypersplenism, representing each 5,8 % of the hepatitis B group. Cholestasis and hypersplenism together were present in 3 cases, accounting for 8,8 % of the patients in this group. Glomerular disease was very rare among hepatitis B patients. Only two patients (5,88 %) from the total of 34 diagnosed with hepatitis B presented glomerular injury and none of these patients associated any other condition that might have been responsible for glomerular injury, except hepatitis B. Acute kidney injury, as well as chronic kidney disease, was not identified in these patients.

In this group, none of the patients that presented glomerular injury associated cholestatic forms or the presence of hypersplenism.

Hepatitis C study group

In patients with chronic hepatitis C, the same correlations were made and these are displayed in figure 2 and explained beneath.

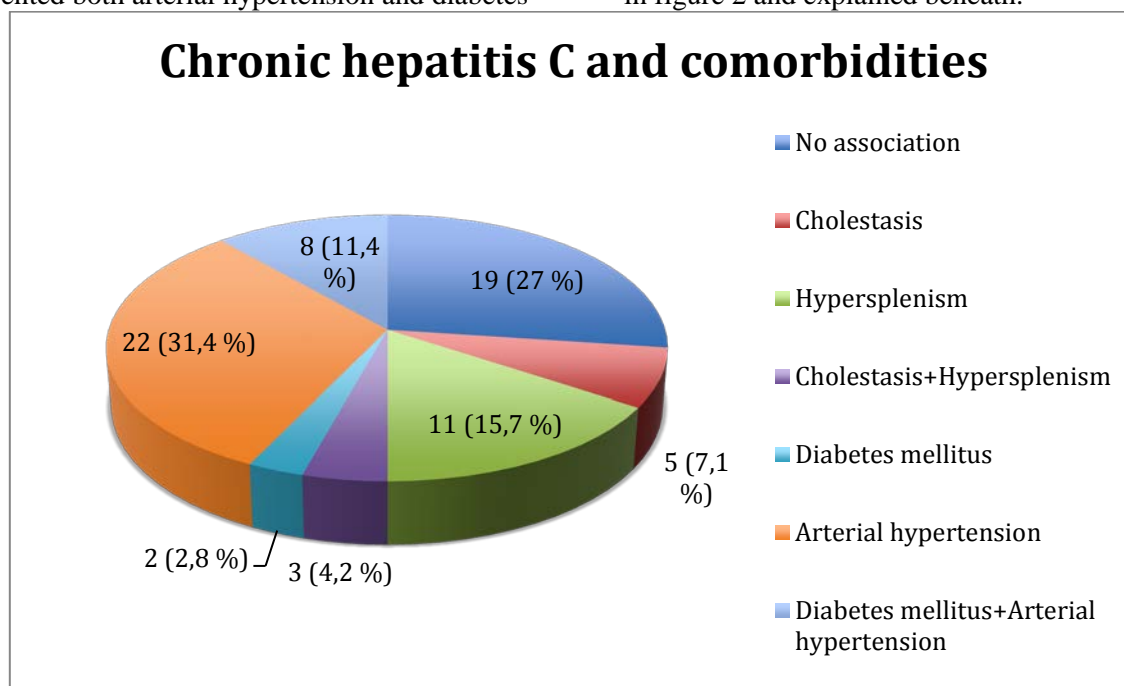


Fig.2. Chronic hepatitis C and comorbidities

In contrast to the hepatitis B study group, where an important number of patients did not present any comorbidity, the majority of the patients with chronic hepatitis C had associated conditions. Thus, only 19 patients out of 70 did not present any other comorbidity. Similar to the hepatitis B study group, the most frequent association that was found was between arterial hypertension and chronic hepatitis C, which occurred in 22 patients, accounting for 31,4 % of this group. Type II diabetes mellitus alone was

rather uncommon, occurring in 2 patients. The association between arterial hypertension and diabetes mellitus was found in 11,4% of patients in the hepatitis C group. The frequency of glomerular disease was higher in patients with hepatitis C than in those with hepatitis B. Thus, 7 patients of this group (10 %) were diagnosed with glomerular injury. It is important to mention that, among these patients, two of them presented associated conditions that might be responsible for the damage of the renal

glomeruli – one patient had arterial hypertension and the other was diagnosed with diabetes mellitus. In conclusion, 5 patients, representing 7,1 %, had glomerular injury in the context of chronic hepatitis C, without other comorbidities that could have been responsible. Similar to the hepatitis B group, acute kidney injury was not diagnosed in any patient. Things were different regarding chronic kidney disease. In the hepatitis C study group, CKD was found in 4 patients, from which two had diabetes mellitus

that had evolved for over 15 years. Only two patients with glomerulopathies without other associated conditions presented chronic kidney disease. One of these patients was assigned to stage III CKD (eGFR=34 ml/min/1.73 m²), while the other was considered to be stage IV (eGFR=21 ml/min/1.73 m²).

Renal disease, either glomerular injury, or kidney dysfunction, did not occur in patients with cholestasis or hypersplenism.

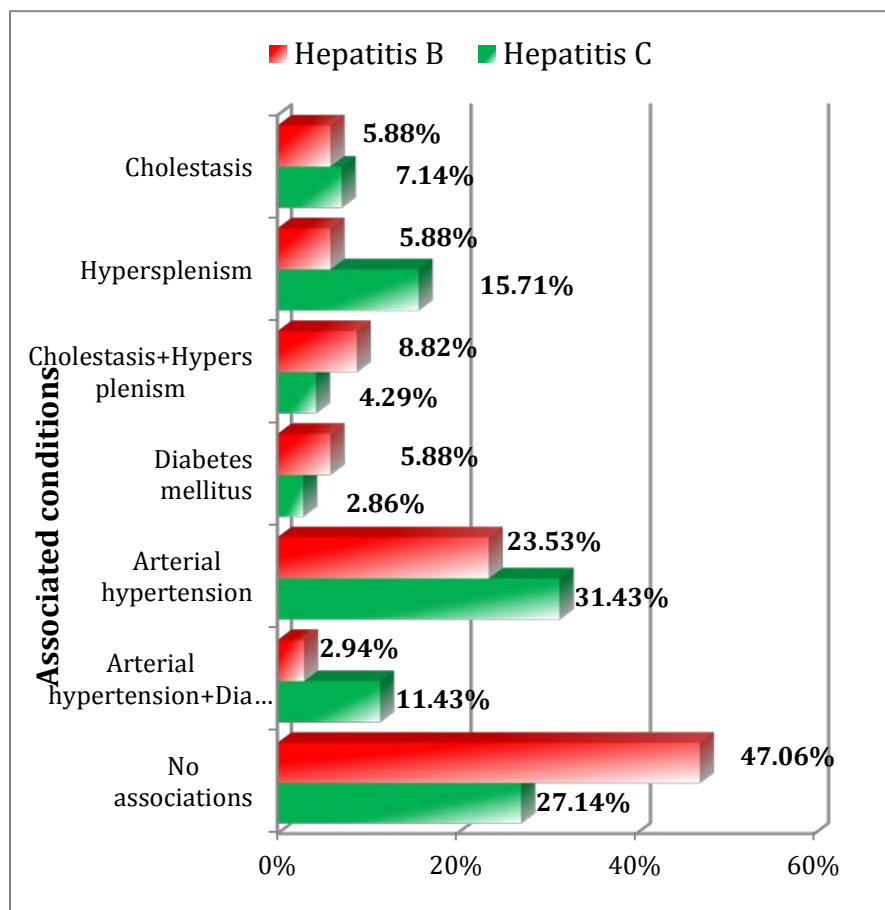


Fig.3. Comparison of frequency of associated conditions in chronic viral hepatitis B and C

Despite percentage differences noticed between the different types of morbid associations of chronic hepatitis B and C, the result of the Chi square test was above the maximum accepted limit, which would indicate statistic significance ($p=0.218>0.05$). This can be explained by the reduced number of cases from each of the comorbidity categories.

Conclusions

The occurrence of kidney disease in patients with chronic viral hepatitis is not a common finding. Our study revealed that, in patients with chronic hepatitis B, the occurrence of

glomerular injury was rather uncommon, affecting only two patients out of 34, which accounted for 5,88 % of this group. These patients were not diagnosed with other comorbidity that could be responsible for glomerular injury, and presented non-nephrotic proteinuria, with preservation of renal function. In the hepatitis C study group, glomerular disease was found in 7 patients, accounting for 10 % of the total. Among these, only 5 patients (7,1 %) did not present other comorbidities that could induce glomerular injury, such as arterial hypertension or type II diabetes mellitus, fact that allowed us to conclude that, in these cases,

glomerular disease was a consequence of chronic viral hepatitis C. Two of these 5 patients presented selective nephrotic proteinuria, with a clinical picture of nephrotic syndrome. The presence of nephrotic syndrome is highly

suggestive for membranoproliferative glomerulonephritis and this type of glomerular injury is mentioned as the most frequent glomerulopathy in the evolution of chronic viral hepatitis C.

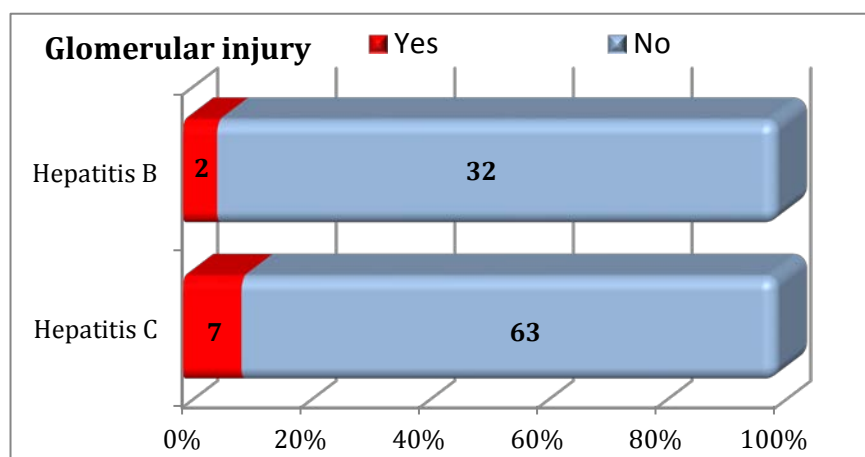


Fig. 4. Comparison of the frequency of glomerular injury in patients with chronic viral hepatitis

For the patients with chronic hepatitis B and C with glomerular injury, the Chi square equation was calculated (p Chi square=0.385>0.05).

Glomerular injury, responsible or not for renal dysfunction, which occurs in the evolution of chronic viral hepatitis, even if not a common finding, represents an important factor of prognosis, requiring a particular management of both liver and kidney disease.

Acute kidney injury was not present at all in the patients that we evaluated, while chronic kidney disease was found in four patients with hepatitis C and no patient with hepatitis B. Two patients with hepatitis C and glomerular injury presented CKD alone, without other comorbidity that could lead to renal dysfunction. One of these patients was assigned to stage III CKD, while the other was considered to be stage IV. The other two cases with CKD occurred in patients with chronic viral hepatitis C that associated type II diabetes mellitus.

None of the patients that were included in this study presented an association between any type of kidney disease (glomerulonephritis or kidney dysfunction) and cholestasis and hypersplenism. In conclusion, our study revealed no pathogenic relationship between these complications of the liver disease and renal disease that appeared in chronic viral hepatitis.

Acknowledgement

This paper was published under the frame of European Social Fund, Human Resources Development Operational Programme 2007-2013, project no. POSDRU/159/1.5/S/133377.

References

1. Trépo C, Amiri M, Guillemin L. Extrahepatic Manifestations of Hepatitis B Infection. *Viral Hepatitis*. 2013;4:154-162. doi: 10.1002/9781118637272.ch11.
2. Enríquez R, Sirvent AE, Andrada E, et al. Cryoglobulinemic glomerulonephritis in chronic hepatitis B infection. *Ren Fail*. 2010;32(4):518-22. doi: 10.3109/08860221003675252.
3. Chan TM. Hepatitis B and renal disease. *Curr Hepat Rep*. 2010; 9(2): 99–105.
4. Zhen J, Zhang L, Pan J et al. AIM2 mediates inflammation-associated renal damage in hepatitis B virus-associated glomerulonephritis by regulating caspase-1, IL-1 β , and IL-18. *Mediators Inflamm*. 2014;2014:190860. doi: 10.1155/2014/190860.
5. Amet S, Bronowicki J-P, Thabut D, et al. Prevalence of renal abnormalities in chronic HBV infection: The HARPE study. *Liver International*. 2014; 34(8). doi: 10.1111/liv.12480.
6. Kar N.L. Hepatitis-related Renal Disease. *Future Virology*. 2011;6(11):1361-1376.
7. Bhimma R, Coovadia H. Hepatitis B Virus-Associated Nephropathy. *Am J Nephrol*. 2004;24(2):198–211. doi: 10.1159/000077065.
8. William GC, Richard JJ. The etiology of glomerulonephritis: roles of infection and autoimmunity. *Kidney International advance online publication*. 2014; doi:10.1038/ki.2014.49.
9. Kiperova B. Glomerular diseases associated with HBV and HCV infection. *Acta Medica Medianae*. 2014;53(1):58-64. doi:10.5633/amm.2014.0111.

10. Johnson RJ, Couser WG: Hepatitis B infection and renal disease: clinical, immunopathogenetic and therapeutic considerations. *Kidney International*. 1990; 37(2):663-76. doi:10.1038/ki.1990.32.
11. Wang NS, Wu ZL, Zhang YE, et al. Role of hepatitis B virus infection in pathogenesis of IgA nephropathy. *World J Gastroenterol*. 2003;9(9):2004-2008.
12. Sharma A, Sharma K. Hepatotropic Viral Infection Associated Systemic Vasculitides—Hepatitis B Virus Associated Polyarteritis Nodosa and Hepatitis C Virus Associated Cryoglobulinemic Vasculitis. *Journal of Clinical and Experimental Hepatology*. 2013; 3(3):204-212
13. Gerber MA, Brodin A, Steinberg D, et al. Periarteritis nodosa, Australia antigen and lymphatic leukaemia. *N Engl J Med*. 1972;286:14-17
14. Daghestani L, Pomeroy C. Renal manifestations of hepatitis C infection. *The American Journal of Medicine*. 1999;106(3):347-354
15. Kamar N, Izopet J, Alric L, et al. Hepatitis C virus-related kidney disease: an overview. *Clinical Nephrology*. 2008;69(3):149-160
16. Ozkok A, Yildiz A. Hepatitis C virus associated glomerulopathies. *World J Gastroenterol*. 2014;20(24):7544-54.
17. Gragnani L, Fognani E, Zignego AL. Hepatitis C virus-related mixed cryoglobulinemia: Is genetics to blame? *World J Gastroenterol*. 2013;19(47):8910-8915
18. Samuel DG, Rees IW. Extrahepatic Manifestations of Hepatitis C Virus (HCV). *Frontline Gastroenterol*. 2013;4(4):249-254.
19. Baig S, Alamgir M. The extrahepatic manifestations of hepatitis B virus. *J Coll Physicians Surg Pak*. 2008;18(7):451-7. doi: 07.2008/JCPSP.451457.

Corresponding Author: Vlad Florin Iovanescu, PhD Student, University of Medicine and Pharmacy of Craiova, Romani, Petru Rares St., No.2, Craiova-200349, Romania; e-mail: iovanescu_vlad@yahoo.com