

High Reproducibility of Tumor Hypoxia Evaluated by ^{18}F -Fluoromisonidazole PET for Head and Neck Cancer

Shozo Okamoto¹, Tohru Shiga¹, Koichi Yasuda², Yoichi M. Ito³, Keiichi Magota¹, Katsuhiko Kasai¹, Yuji Kuge⁴, Hiroki Shirato², and Nagara Tamaki¹

¹Department of Nuclear Medicine, Hokkaido University Graduate School of Medicine, Sapporo, Japan; ²Department of Radiology, Hokkaido University Graduate School of Medicine, Sapporo, Japan; ³Department of Biostatistics, Hokkaido University Graduate School of Medicine, Sapporo, Japan; and ⁴Central Institute of Isotope Science, Hokkaido University, Sapporo, Japan

Tumor hypoxia is well known to be radiation resistant. ^{18}F -fluoromisonidazole (^{18}F -FMISO) PET has been used for noninvasive evaluation of hypoxia. Quantitative evaluation of ^{18}F -FMISO uptake is thus expected to play an important role in the planning of dose escalation radiotherapy. However, the reproducibility of ^{18}F -FMISO uptake has remained unclear. We therefore investigated the reproducibility of tumor hypoxia by using quantitative analysis of ^{18}F -FMISO uptake. **Methods:** Eleven patients with untreated head and neck cancer underwent 2 ^{18}F -FMISO PET/CT scans (^{18}F -FMISO₁ and ^{18}F -FMISO₂) with a 48-h interval prospectively. All images were acquired at 4 h after ^{18}F -FMISO injection for 10 min. The maximum standardized uptake (SUVmax), tumor-to-blood ratio (TBR), and tumor-to-muscle ratio (TMR) of ^{18}F -FMISO uptake were statistically compared between the 2 ^{18}F -FMISO scans by use of intraclass correlation coefficients (ICCs). The hypoxic volume was calculated as the area with a TBR of greater than or equal to 1.5 or the area with a TMR of greater than or equal to 1.25 to assess differences in hypoxic volume between the 2 ^{18}F -FMISO scans. The distances from the maximum uptake locations of the ^{18}F -FMISO₁ images to those of the ^{18}F -FMISO₂ images were measured to evaluate the locations of ^{18}F -FMISO uptake. **Results:** The SUVmax (mean \pm SD) for ^{18}F -FMISO₁ and ^{18}F -FMISO₂ was 3.16 ± 1.29 and 3.02 ± 1.12 , respectively, with the difference between the 2 scans being $7.0\% \pm 4.6\%$. The TBRs for ^{18}F -FMISO₁ and ^{18}F -FMISO₂ were 2.98 ± 0.83 and 2.97 ± 0.64 , respectively, with a difference of $9.9\% \pm 3.3\%$. The TMRs for ^{18}F -FMISO₁ and ^{18}F -FMISO₂ were 2.25 ± 0.71 and 2.19 ± 0.67 , respectively, with a difference of $7.1\% \pm 5.3\%$. The ICCs for SUVmax, TBR, and TMR were 0.959, 0.913, and 0.965, respectively. The difference in hypoxic volume based on TBR was 1.8 ± 1.8 mL, and the difference in hypoxic volume based on TMR was 0.9 ± 1.3 mL, with ICCs of 0.986 and 0.996, respectively. The maximum uptake locations of the ^{18}F -FMISO₁ images were different from those of the ^{18}F -FMISO₂ images and were within the full width at half maximum of the PET/CT scanner, except in 1 case. **Conclusion:** The values for ^{18}F -FMISO PET uptake and hypoxic volume in head and neck tumors between the 2 ^{18}F -FMISO scans were highly reproducible.

Such high reproducibility of tumor hypoxia is promising for accurate radiation planning.

Key Words: tumor hypoxia; ^{18}F -FMISO; reproducibility; head and neck cancer

J Nucl Med 2013; 54:201–207

DOI: 10.2967/jnumed.112.109330

It has been well established that hypoxic regions of tumors are radiation resistant and that head and neck cancers with substantial areas of hypoxia are associated with a poor prognosis (1,2). ^{18}F -fluoromisonidazole (^{18}F -FMISO) PET has been used for noninvasive evaluation of hypoxia, and ^{18}F -FMISO uptake is related to patient prognosis (3–6). Quantitative evaluation of ^{18}F -FMISO uptake is expected to play an important role in the planning of dose escalation radiotherapy (7–9). However, the reproducibility of ^{18}F -FMISO uptake has remained unclear. A single report has indicated a low reproducibility of ^{18}F -FMISO uptake (10). In that report, the hypoxic volume was calculated on the basis of the tumor-to-blood ratio (TBR). However, there has been no report evaluating the stability of radioactivity in the blood pool. On the other hand, another report has shown a correlation between the values obtained from a tumor-to-muscle ratio (TMR) evaluation of ^{18}F -FMISO PET and pO_2 polarography (11), indicating that TMR is a suitable marker of tumor hypoxia.

We postulated that high-resolution, high-contrast ^{18}F -FMISO images collected by use of a state-of-the-art PET camera might provide a high reproducibility of tumor hypoxia. Therefore, the aim of this study was to investigate the reproducibility of ^{18}F -FMISO uptake by use of quantitative analysis, including TBR and TMR.

MATERIALS AND METHODS

Patients

Patients with untreated head and neck cancer were prospectively enrolled in this study. Signed informed consent was obtained in all cases, and this study was approved by the Institutional Review Board of Hokkaido University. Twelve patients were recruited

Received Jul. 17, 2012; revision accepted Sep. 18, 2012.

For correspondence or reprints contact: Tohru Shiga, Department of Nuclear Medicine, Hokkaido University Graduate School of Medicine, North 15th, West 7th, Kitaku, Sapporo 060-8638, Japan.

E-mail: tshiga@med.hokudai.ac.jp

Published online Jan. 15, 2013.

COPYRIGHT © 2013 by the Society of Nuclear Medicine and Molecular Imaging, Inc.

between June 2010 and March 2012 at Hokkaido University Hospital. Technical problems prevented adequate collection of the ^{18}F -FMISO scan in 1 patient. Therefore, ^{18}F -FMISO images were analyzed for 11 patients, including 4 patients with nasopharyngeal cancer, 1 with oropharyngeal cancer, 2 with hypopharyngeal cancer, 2 with laryngeal cancer, 1 with maxillary sinus cancer, and 1 with ethmoid sinus cancer (Table 1).

^{18}F -FMISO PET

Patients underwent 2 ^{18}F -FMISO PET/CT scans (^{18}F -FMISO₁ and ^{18}F -FMISO₂) with a 48-h interval. All images were acquired at 4 h after injection of ^{18}F -FMISO for 10 min in the 3-dimensional mode with a PET/CT scanner (TruePoint Biograph with TrueV Option; Siemens Japan). Compared with the scanner without the true V option (axial field of view, 16.2 cm), the TruePoint Biograph with the TrueV Option had an extended axial field of view (21.6 cm), sensitivity that was 1.82 times higher, and a comparable scatter fraction (32% of the National Electrical Manufacturers Association standard NU 2-2007) (12). The images were reconstructed with the iterative TrueX reconstruction method, which included partial-volume correction (13). The full width at half maximum after reconstruction was 8 mm, and the slice thickness was 3 mm. Venous blood sampling was performed immediately after scanning.

Image Analysis

^{18}F -FMISO PET images were analyzed quantitatively, including assessment of the maximum standardized uptake value (SUVmax), TBR, and TMR. The SUVmax was calculated as the activity concentration/(injected dose/body weight). The TBR was derived as the maximum concentration of the tumor divided by the concentration of blood collected from venous blood sampling. For calculation of the TMR, a region of interest was placed over the primary lesion and posterior cervical muscle. The TMR was then defined as the tumor uptake divided by the uptake of the posterior cervical muscle. The hypoxic volume was also calculated to evaluate the reproducibility of hypoxia clinically. Although a threshold for the definition of hypoxia has not been formally established, a TBR of greater than or equal to 1.5 was defined as hypoxia for the calculation of hypoxic volume based on TBR (HV-TBR) in this study; the threshold for hypoxic volume based on TMR (HV-TMR) was set at 1.25.

CT images from the first and second PET/CT scans were co-registered by maximization of mutual information on a Windows XP (Microsoft) workstation, and ^{18}F -FMISO PET images were coregistered with the same parameters (14). The distances from the maximum uptake locations of the ^{18}F -FMISO₁ images to those of the ^{18}F -FMISO₂ images were measured to evaluate the locations of ^{18}F -FMISO uptake.

Statistical Analyses

For statistical analyses of the reproducibility of ^{18}F -FMISO uptake and hypoxic volume, the intraclass correlation coefficients (ICCs) were calculated for SUVmax, TBR, TMR, HV-TBR, and HV-TMR. In addition, SDs in the paired data were statistically compared between TBR and TMR and between HV-TBR and HV-TMR (15). Bland-Altman analysis was used for evaluation of the differences in these parameters (16). Because tumors expand in an exponential fashion, log10-scale analyses were added for HV-TBR and HV-TMR. We also calculated Pearson correlation coefficients for all patients from scatterplots of ^{18}F -FMISO₁ versus ^{18}F -FMISO₂. Plots were extracted from 3-dimensional regions of interest that covered all of the hypoxic area in the tumor. *P* values of less than 0.05 were considered to indicate statistical significance. Statistical analyses were performed with JMP version 10 software (SAS Institute Inc.).

RESULTS

The 11 patients ranged in age from 44 to 78 y (mean \pm SD, 62.0 ± 11.9). The injected dose of ^{18}F -FMISO was 414 ± 26 MBq, and the time interval between injection and the start of the scan was 262 ± 21 min. Because 1 patient had a problem with blood sampling, blood data for this patient were excluded from analysis (Table 1). There were no statistically significant differences in the injected dose, time interval, SUVmax, TBR, or TMR between ^{18}F -FMISO₁ and ^{18}F -FMISO₂ (Table 2).

The SUVmax (mean \pm SD) for ^{18}F -FMISO₁ and ^{18}F -FMISO₂ was 2.08 ± 1.18 , with a range of 1.21–5.01 (Table 2). The difference in SUVmax between the 2 ^{18}F -FMISO studies was $7.0\% \pm 4.6\%$ (range, 1.2%–11.7%). The TBR (mean \pm SD) was 2.98 ± 0.72 (range,

TABLE 1
Characteristics of Patients*

Patient	Age (y)	Histologic diagnosis	Stage	^{18}F -FMISO PET
1	59	Laryngeal cancer	IV A	Incomplete because of inadequate blood sampling
2	78	Laryngeal cancer	IV A	Complete
3	52	Nasopharyngeal cancer	III	Complete
4	67	Maxillary sinus cancer	IV A	Complete
5	46	Ethmoid sinus cancer	IV B	Complete
6	71	Oropharyngeal cancer	IV A	Complete
7	77	Nasopharyngeal cancer	I	Complete
8	53	Nasopharyngeal cancer	III	Complete
9	69	Hypopharyngeal cancer	IV A	Complete
10	44	Nasopharyngeal cancer	III	Complete
11	66	Hypopharyngeal cancer	I	Complete

*All patients were men.

TABLE 2
Parameters of 2 ^{18}F -FMISO PET Studies and Distances Between ^{18}F -FMISO₁ and ^{18}F -FMISO₂ Maximum Uptake Locations

Patient	SUVmax		TBR		TMR		HV-TBR (mL)		HV-TMR (mL)		Distance (mm)
	^{18}F -FMISO ₁	^{18}F -FMISO ₂	^{18}F -FMISO ₁	^{18}F -FMISO ₂	^{18}F -FMISO ₁	^{18}F -FMISO ₂	^{18}F -FMISO ₁	^{18}F -FMISO ₂	^{18}F -FMISO ₁	^{18}F -FMISO ₂	
1	1.22	1.28			1.25	1.22			0.1	0.0	3.6
2	2.38	2.27	2.70	2.96	2.17	2.06	6.4	9.7	5.7	5.7	4.3
3	1.29	1.28	1.76	1.98	1.34	1.45	0.5	2.0	0.1	0.6	5.7
4	4.95	4.51	4.71	4.39	3.82	3.80	54.3	54.1	52.5	56.8	4.3
5	2.74	2.61	2.38	2.59	2.20	2.22	9.9	13.6	14.4	15.0	4.5
6	4.23	4.08	3.54	3.17	2.73	2.62	26.3	20.6	22.2	20.3	0.9
7	3.76	3.50	2.87	2.97	2.41	2.28	4.1	6.5	4.3	4.8	1.5
8	3.12	3.49	2.42	2.77	1.70	1.92	6.5	7.6	1.7	2.2	4.4
9	3.40	3.64	2.95	3.22	2.36	2.47	11.9	13.3	10.8	11.1	11.8
10	5.01	4.11	3.76	3.22	2.59	2.19	13.5	13.1	4.5	3.7	0.9
11	2.62	2.48	2.68	2.42	2.22	1.91	1.6	1.8	1.6	1.5	4.8
Mean	3.16	3.02	2.98	2.97	2.25	2.19	13.5	14.2	10.7	11.1	4.3
SD	1.29	1.12	0.83	0.64	0.71	0.67	16.1	15.1	15.4	16.5	3.0
<i>P</i> *	NS		NS		NS		NS		NS		

*As determined with Mann–Whitney *U* test. NS = not significant.

1.76–4.71), and the difference in TBR between the 2 ^{18}F -FMISO studies was $9.9\% \pm 3.3\%$ (range, 3.4%–14.5%). The TMR (mean \pm SD) was 2.23 ± 0.67 (range, 1.22–3.82), and the difference in TMR between the 2 ^{18}F -FMISO studies was $7.1\% \pm 5.3\%$ (range, 0.4%–15.3%). The ICCs for SUVmax, TBR, and TMR were 0.959, 0.913, and 0.965, respectively (Fig. 1). The SD for the difference in TMR was significantly smaller than that for the difference in TBR ($P = 0.04$).

HV-TBR ranged from 0.5 mL to 54.3 mL. The difference between ^{18}F -FMISO₁ and ^{18}F -FMISO₂ was 1.8 ± 1.8 mL. HV-TMR ranged from 0.0 mL to 56.8 mL, and the difference was 0.9 ± 1.3 mL. The ICCs for HV-TBR, HV-TMR, log HV-TBR, and log HV-TMR were 0.986, 0.996, 0.951, and 0.993, respectively (Fig. 2). The SD for the difference in log HV-TMR was also significantly smaller than that for the difference in log HV-TBR ($P = 0.03$).

Figure 3 shows scatterplots of ^{18}F -FMISO₁ versus ^{18}F -FMISO₂ for all patients. The straight line represents

a TBR of 1.5, and the dotted line represents a TMR of 1.25. Of the 11 patients, 7 had ICCs of greater than 0.9.

The distance between the maximum uptake location of ^{18}F -FMISO₁ and that of ^{18}F -FMISO₂ was 4.3 ± 3.0 mm. This distance was smaller than the full width at half maximum of the PET/CT scanner (8 mm), except in 1 case. In that 1 case, the 11.8-mm distance had 2 peaks with similar ^{18}F -FMISO uptake values, and the maximum uptake of ^{18}F -FMISO₁ was located at a peak different from that of ^{18}F -FMISO₂. The locations of the 2 peaks were different—that is, 2.3 and 3.3 mm—and both were within the full width at half maximum of the PET/CT scanner (Fig. 4).

Another representative case (maxillary sinus cancer) is shown in Figure 5. The values for SUVmax (4.95 vs. 4.91), TBR (4.71 vs. 4.39), TMR (3.82 vs. 3.80), HV-TBR (54.3 vs. 54.1 mL), and HV-TMR (52.5 vs. 56.8 mL) were similar. The distance between the maximum uptake of ^{18}F -FMISO₁ and that of ^{18}F -FMISO₂ was 4.3 mm.

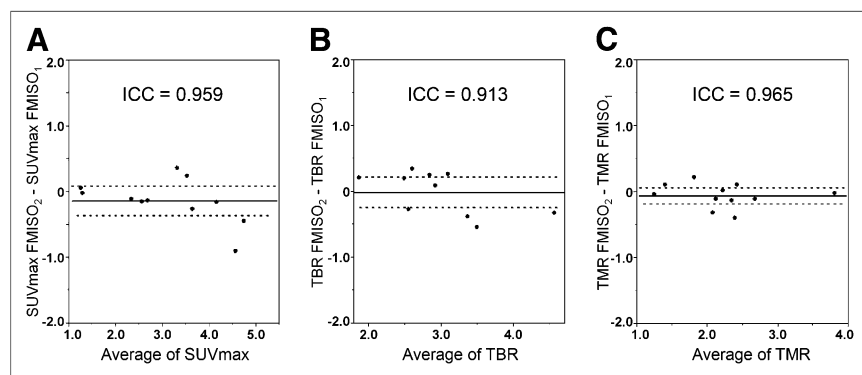


FIGURE 1. Bland–Altman plots of SUVmax (A), TBR (B), and TMR (C) of ^{18}F -FMISO₁ and ^{18}F -FMISO₂. Lines show combined mean and 95% confidence interval. SD of difference for TMR was significantly smaller than that for TBR ($P = 0.04$).

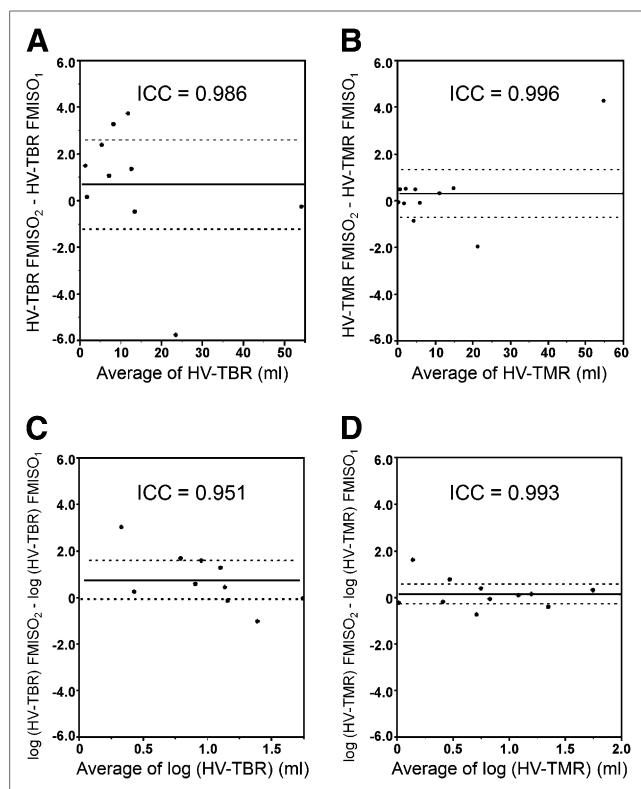


FIGURE 2. Bland-Altman plots of HV-TBR (A), HV-TMR (B), log HV-TBR (C), and log HV-TMR (D). Lines show combined mean and 95% confidence interval. SD of difference for log HV-TMR was significantly smaller than that for log HV-TBR ($P = 0.03$).

DISCUSSION

To our knowledge, this is the first report to demonstrate a high reproducibility of ^{18}F -FMISO uptake through the use of major methods of ^{18}F -FMISO analysis, such as SUVmax, TBR, TMR, HV-TBR, HV-TMR, and the location of maximum ^{18}F -FMISO uptake. Validation of the reproducibility of ^{18}F -FMISO uptake is critically important for clinical applications, because various factors, including acute hypoxia, might cause changes in the hypoxic area between the ^{18}F -FMISO study and the actual radiation planning. Such high reproducibility of tumor hypoxia is promising for accurate radiation planning.

Our results for the reproducibility of tumor hypoxia evaluated by ^{18}F -FMISO uptake were different from those obtained by Nehmeh et al. (10). There are several possible reasons for the discrepancy. First, the time interval from ^{18}F -FMISO injection to scanning in the study of Nehmeh et al. (10) was short and variable among patients (117–195 min). The images with short time intervals included ^{18}F -FMISO accumulation in the blood pool (17,18). We considered ^{18}F -FMISO imaging at 4 h after injection to be more suitable than imaging in less than 3 h, as used in several other studies (3–5,7–11), for the following reasons. Because blood clearance of ^{18}F -FMISO is rather slow, residual blood pool activity at 1–3 h remains relatively high. Such high blood pool

activity might cause poor reproducibility of the tumor-to-blood pool activity ratio and decrease image quality. However, high-quality ^{18}F -FMISO images were obtained even at 4 h after ^{18}F -FMISO administration, as shown in Figures 4 and 5. Therefore, a high reproducibility of several hypoxic parameters was observed on ^{18}F -FMISO images obtained at 4 h after injection. Unfortunately, we did not compare the reproducibilities of ^{18}F -FMISO images at 2 and 4 h after tracer administration with the same PET camera. Such a comparison would be the next step in confirming the value of ^{18}F -FMISO imaging at 4 h.

Second, PET was performed in the 2-dimensional mode with a short scanning time (8 min) in the study of Nehmeh et al. (10). In the present study, ^{18}F -FMISO images were obtained for 10 min with 3-dimensional acquisition on a PET/CT system with high spatial resolution and high sensitivity (19,20). In addition, those images were reconstructed with the iterative TrueX reconstruction method, which included partial-volume correction. Therefore, we obtained images with high contrast and low statistical noise as well as stable ^{18}F -FMISO uptake.

The hypoxic area in a tumor has been reported to include chronic hypoxia and acute hypoxia (1,21). Acute hypoxia can change every few hours or days. Therefore, acute hypoxia could have changed the distribution of ^{18}F -FMISO uptake between the 2 ^{18}F -FMISO studies. In the present investigation, no case showed major changes in SUVmax, TBR, TMR, HV-TBR, and HV-TMR. Our results did not indicate an effect of acute hypoxia on ^{18}F -FMISO studies with a 48-h interval. Mönnich et al. (22) reported that acute hypoxia did not influence the reproducibility of PET imaging in simulations. Our results are consistent with their report.

Dose escalation for a hypoxic tumor is an important consideration for improving the effect of radiotherapy (23–25). The definition of hypoxic volume is essential for choosing the target for dose escalation. The high reproducibility of tumor hypoxia evaluated by ^{18}F -FMISO uptake offers hope for defining the hypoxic area. In the present study, the hypoxic area was defined as the area with a TBR of greater than or equal to 1.5 or a TMR of greater than or equal to 1.25. The threshold for TBR has been not established, so different thresholds (from 1.2 to 1.4) have been used in various reports (5,10,26–28). The threshold for TBR (1.5) in the present study was higher than those in previous studies. The reason was that the time interval (4 h) between ^{18}F -FMISO injection and scanning in the present study was longer than those in previous studies (from 2 to 3 h) and resulted in higher lesion contrast and less background activity. The threshold for TMR (1.25) was determined as the upper limit of the 95% confidence interval for normal muscle uptake in 11 people without carcinoma. These thresholds are not widely used.

Another study is needed to determine a more appropriate threshold for applying ^{18}F -FMISO PET to clinical dose escalation in patients. For clinical practice, immobilization of a patient's head and neck is important. We immobilized them by using a dedicated device for the PET/CT scanner.

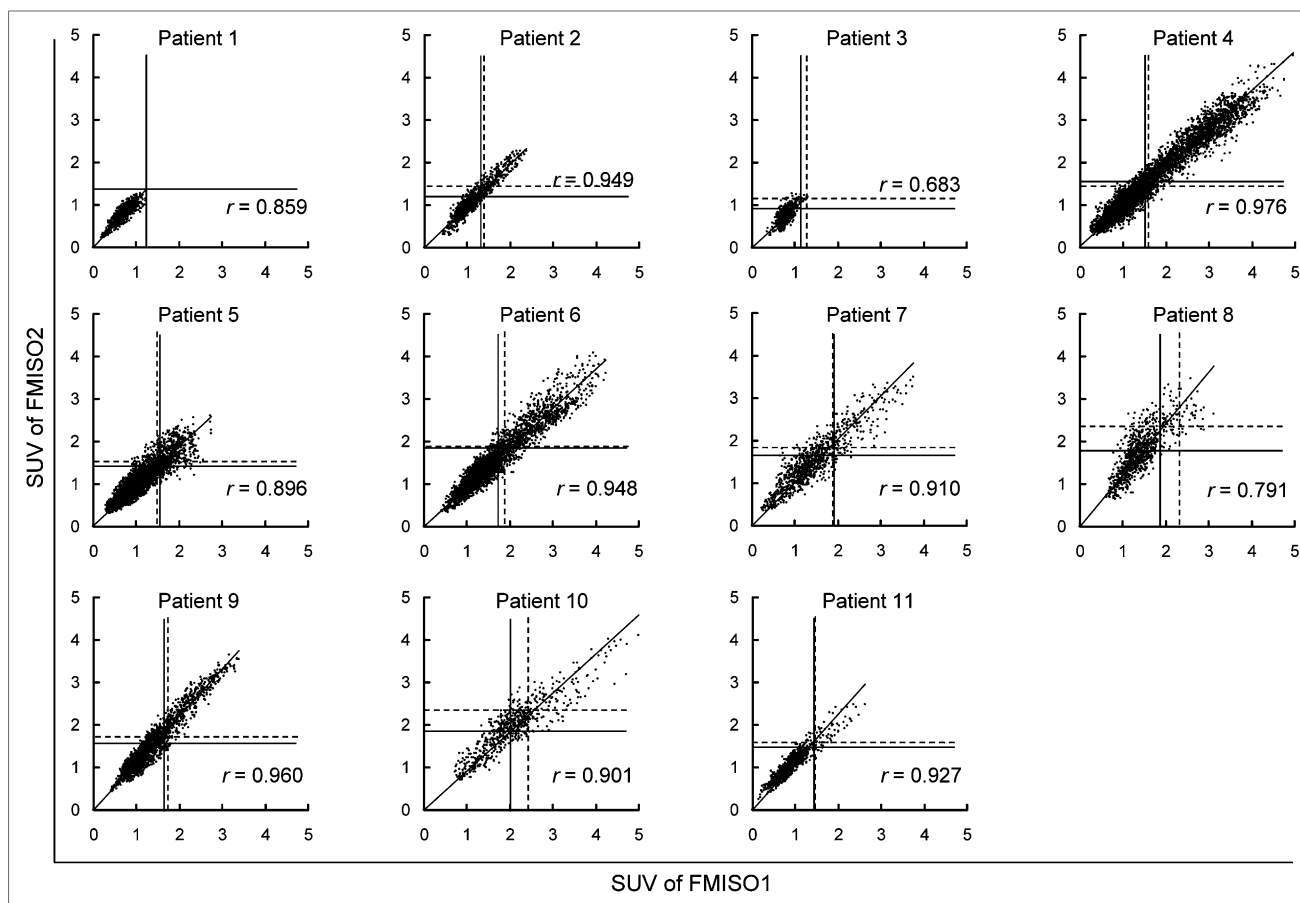


FIGURE 3. Scatterplots of tumor voxel SUV of ^{18}F -FMISO₁ vs. tumor voxel SUV of ^{18}F -FMISO₂ for each patient. Solid lines indicate TBR of 1.5, and broken lines indicate TMR of 1.25.

When possible, ^{18}F -FMISO PET with immobilization devices, such as radiation treatment masks, would be helpful for the delineation of dose painting in dose escalation radiotherapy.

Our results indicated that TMR analysis yielded better reproduction of tumor hypoxia than TBR analysis. TMR anal-

ysis is a unique quantitative method that has been shown to be correlated with pO_2 polarography (11). TBR analysis typically has been used for quantification of ^{18}F -FMISO uptake and definition of the hypoxic area. However, this method requires blood sampling, which is invasive for patients and

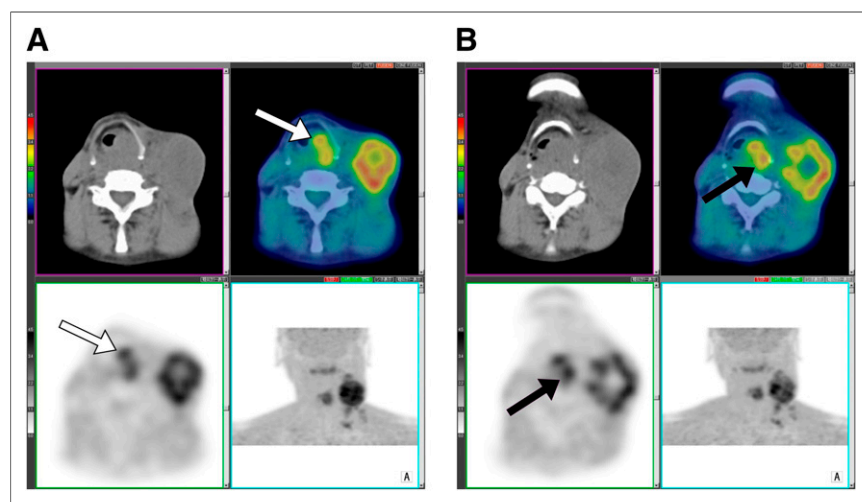
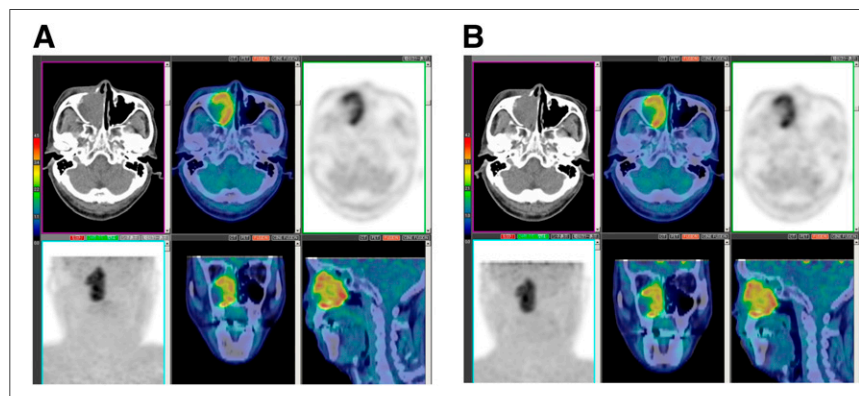


FIGURE 4. ^{18}F -FMISO imaging of patient 9, who had hypopharyngeal cancer. Distance between maximum uptake on ^{18}F -FMISO₁ image (A) and that on ^{18}F -FMISO₂ image (B) was 11.8 mm. On ^{18}F -FMISO₁ image, maximum uptake was observed at SUVmax of 3.40 (white arrow). On ^{18}F -FMISO₂ image, maximum uptake was observed at another peak (SUVmax, 3.64) (black arrow). Locations of peaks (white arrow and black arrow) were different—that is, 2.3 and 3.3 mm, respectively.

FIGURE 5. ^{18}F -FMISO imaging of patient 4, who had maxillary sinus cancer. Uptake of ^{18}F -FMISO on ^{18}F -FMISO₁ image (A) was similar to that on ^{18}F -FMISO₂ image (B). Distance between maximum uptake on ^{18}F -FMISO₁ image and that on ^{18}F -FMISO₂ image was 4.3 mm (smaller than full width at half maximum of PET scanner). Values for SUVmax (4.95 vs. 4.91), TBR (4.71 vs. 4.39), TMR (3.82 vs. 3.80), HV-TBR (54.3 vs. 54.1 mL), and HV-TMR (52.5 vs. 56.8 mL) were similar.



can introduce technical mistakes. In contrast, TMR analysis is a noninvasive, simple quantitative method. Our results indicate that TMR analysis is a potential alternative for TBR analysis. However, TMR analysis has some limitations related to the uptake of ^{18}F -FMISO in the posterior muscles of the neck, which is seen in most people. Therefore, the accuracy of TMR analysis should be investigated in another study.

The present study has several limitations. The major limitation is that the number of patients was small. Although our data were limited in this regard, it was important to promptly report the high reproducibility of ^{18}F -FMISO uptake to advance ^{18}F -FMISO investigations. Another study with a larger number of patients may establish not only reproducibility but also a definition of the hypoxic area. Second, the hypoxic volume in the present study was smaller than that in a previous study (10) because our study included early-stage cases (stage I). Although our data could not provide enough evidence of reproducibility over a large hypoxic area, we were able to demonstrate high reproducibility even in small hypoxic lesions. Third, the present study did not include women. We believe that this factor is incidental because many head and neck cancers (e.g., nasopharyngeal, oropharyngeal, and laryngeal cancers) occur mostly in men. Additionally, we did not compare the reproducibilities of ^{18}F -FMISO images at 2 and 4 h after tracer administration or 2-dimensional and 3-dimensional acquisitions with the same PET camera.

CONCLUSION

The reproducibility of quantitative evaluation of tumor hypoxia by ^{18}F -FMISO PET was high. Such high reproducibility in terms of hypoxic location and area is promising for the accurate delineation of dose painting in dose escalation radiotherapy with ^{18}F -FMISO PET.

DISCLOSURE

The costs of publication of this article were defrayed in part by the payment of page charges. Therefore, and solely to indicate this fact, this article is hereby marked "advertisement" in accordance with 18 USC section 1734. No potential conflict of interest relevant to this article was reported.

ACKNOWLEDGMENTS

We thank radiologic technologists Hidehiko Omote, Yamato Munakata, Kazumi Kawanabe, and Junya Katahata for their excellent technical assistance and PET scanning. We also thank Ken-ichi Nishijima and Norifumi Abo for synthesis of ^{18}F -FMISO and Shuichi Takinami for performance of ^{18}F -FMISO PET.

REFERENCES

- Pajonk F, Vlashi E, McBride WH. Radiation resistance of cancer stem cells: the 4 R's of radiobiology revisited. *Stem Cells*. 2010;28:639–648.
- Nordsmark M, Bentzen SM, Rudat V, et al. Prognostic value of tumor oxygenation in 397 head and neck tumors after primary radiation therapy: an international multi-center study. *Radiother Oncol*. 2005;77:18–24.
- Rajendran JG, Schwartz DL, O'Sullivan J, et al. Tumor hypoxia imaging with [F-18] fluoromisonidazole positron emission tomography in head and neck cancer. *Clin Cancer Res*. 2006;12:5435–5441.
- Rischin D, Peters L, Fisher R, et al. Tirapazamine, cisplatin, and radiation versus fluorouracil, cisplatin, and radiation in patients with locally advanced head and neck cancer: a randomized phase II trial of the Trans-Tasman Radiation Oncology Group (TROG 98.02). *J Clin Oncol*. 2005;23:79–87.
- Koh WJ, Bergman KS, Rasey JS, et al. Evaluation of oxygenation status during fractionated radiotherapy in human nonsmall cell lung cancers using [F-18] fluoromisonidazole positron emission tomography. *Int J Radiat Oncol Biol Phys*. 1995;33:391–398.
- Eschmann SM, Paulsen F, Reimold M, et al. Prognostic impact of hypoxia imaging with ^{18}F -misonidazole PET in non-small cell lung cancer and head and neck cancer before radiotherapy. *J Nucl Med*. 2005;46:253–260.
- Lin Z, Mechalakos J, Nehmeh S, et al. The influence of changes in tumor hypoxia on dose-painting treatment plans based on ^{18}F -FMISO positron emission tomography. *Int J Radiat Oncol Biol Phys*. 2008;70:1219–1228.
- Dirix P, Vandecaveye V, De Keyser F, et al. Dose painting in radiotherapy for head and neck squamous cell carcinoma: value of repeated functional imaging with ^{18}F -FDG PET, ^{18}F -fluoromisonidazole PET, diffusion-weighted MRI, and dynamic contrast-enhanced MRI. *J Nucl Med*. 2009;50:1020–1027.
- Lee NY, Mechalakos JG, Nehmeh S, et al. Fluorine-18-labeled fluoromisonidazole positron emission and computed tomography-guided intensity-modulated radiotherapy for head and neck cancer: a feasibility study. *Int J Radiat Oncol Biol Phys*. 2008;70:2–13.
- Nehmeh SA, Lee NY, Schröder H, et al. Reproducibility of intratumor distribution of ^{18}F -fluoromisonidazole in head and neck cancer. *Int J Radiat Oncol Biol Phys*. 2008;70:235–242.
- Gagel B, Reinartz P, Dimartino E, et al. pO₂ polarography versus positron emission tomography ([^{18}F]fluoromisonidazole, [^{18}F]-2-fluoro-2'-deoxyglucose): an appraisal of radiotherapeutically relevant hypoxia. *Strahlenther Onkol*. 2004;180:616–622.
- Jakoby BW, Bercier Y, Conti M, Casey ME, Bendriem B, Townsend DW. Physical and clinical performance of the mCT time-of-flight PET/CT scanner. *Phys Med Biol*. 2011;56:2375–2389.
- Panin VY, Kehren F, Michel C, Casey M. Fully 3-D PET reconstruction with system matrix derived from point source measurements. *IEEE Trans Med Imaging*. 2006;25:907–921.

14. Pluim JP, Maintz JB, Viergever MA. Mutual-information-based registration of medical images: a survey. *IEEE Trans Med Imaging*. 2003;22:986–1004.
15. Snedecor GW, Cochran WG. *Statistical Methods*. 7th ed. Ames, IA: The Iowa State University Press; 1980:190–191.
16. Bland JM, Altman DG. Statistical methods for assessing agreement between two methods of clinical measurement. *Lancet*. 1986;1:307–310.
17. Thorwarth D, Eschmann SM, Paulsen F, Alber M. A kinetic model for dynamic [¹⁸F]-Fmiso PET data to analyse tumour hypoxia. *Phys Med Biol*. 2005;50:2209–2224.
18. Abolmaali N, Haase R, Koch A, et al. Two or four hour [¹⁸F]FMISO-PET in HNSCC: when is the contrast best? *Nuklearmedizin*. 2011;50:22–27.
19. Cherry SR, Woods RP, Hoffman EJ, Mazziotta JC. Improved detection of focal cerebral blood flow changes using three-dimensional positron emission tomography. *J Cereb Blood Flow Metab*. 1993;13:630–638.
20. Lodge MA, Badawi RD, Gilbert R, Dibos PE, Line BR. Comparison of 2-dimensional and 3-dimensional acquisition for ¹⁸F-FDG PET oncology studies performed on an LSO-based scanner. *J Nucl Med*. 2006;47:23–31.
21. Bayer C, Shi K, Astner ST, Maftai CA, Vaupel P. Acute versus chronic hypoxia: why a simplified classification is simply not enough. *Int J Radiat Oncol Biol Phys*. 2011;80:965–968.
22. Mönnich D, Troost EG, Kaanders JH, Oyen WJ, Alber M, Thorwarth D. Modelling and simulation of the influence of acute and chronic hypoxia on [¹⁸F]fluoromisonidazole PET imaging. *Phys Med Biol*. 2012;57:1675–1684.
23. Choi W, Lee SW, Park SH, et al. Planning study for available dose of hypoxic tumor volume using fluorine-18-labeled fluoromisonidazole positron emission tomography for treatment of the head and neck cancer. *Radiother Oncol*. 2010;97:176–182.
24. Hendrickson K, Phillips M, Smith W, Peterson L, Krohn K, Rajendran J. Hypoxia imaging with [F-18] FMISO-PET in head and neck cancer: potential for guiding intensity modulated radiation therapy in overcoming hypoxia-induced treatment resistance. *Radiother Oncol*. 2011;101:369–375.
25. Yasuda K, Onimaru R, Okamoto S, et al. [¹⁸F]fluoromisonidazole and a new PET system with semiconductor detectors and a depth of interaction system for intensity modulated radiation therapy for nasopharyngeal cancer. *Int J Radiat Oncol Biol Phys*. 2013;85:142–147.
26. Koh WJ, Rasey JS, Evans ML, et al. Imaging of hypoxia in human tumors with [F-18]fluoromisonidazole. *Int J Radiat Oncol Biol Phys*. 1992;22:199–212.
27. Rasey JS, Koh WJ, Evans ML, et al. Quantifying regional hypoxia in human tumors with positron emission tomography of [¹⁸F]fluoromisonidazole: a pretherapy study of 37 patients. *Int J Radiat Oncol Biol Phys*. 1996;36:417–428.
28. Rajendran JG, Wilson DC, Conrad EU, et al. [¹⁸F]FMISO and [¹⁸F]FDG PET imaging in soft tissue sarcomas: correlation of hypoxia, metabolism and VEGF expression. *Eur J Nucl Med Mol Imaging*. 2003;30:695–704.



The Journal of
NUCLEAR MEDICINE

High Reproducibility of Tumor Hypoxia Evaluated by ^{18}F -Fluoromisonidazole PET for Head and Neck Cancer

Shozo Okamoto, Tohru Shiga, Koichi Yasuda, Yoichi M. Ito, Keiichi Magota, Katsuhiko Kasai, Yuji Kuge, Hiroki Shirato and Nagara Tamaki

J Nucl Med. 2013;54:201-207.

Published online: January 15, 2013.

Doi: 10.2967/jnumed.112.109330

This article and updated information are available at:

<http://jnm.snmjournals.org/content/54/2/201>

Information about reproducing figures, tables, or other portions of this article can be found online at:


<http://jnm.snmjournals.org/site/misc/permission.xhtml>

Information about subscriptions to JNM can be found at:

<http://jnm.snmjournals.org/site/subscriptions/online.xhtml>

The Journal of Nuclear Medicine is published monthly.
SNMMI | Society of Nuclear Medicine and Molecular Imaging
1850 Samuel Morse Drive, Reston, VA 20190.
(Print ISSN: 0161-5505, Online ISSN: 2159-662X)

© Copyright 2013 SNMMI; all rights reserved.

 SOCIETY OF
NUCLEAR MEDICINE
AND MOLECULAR IMAGING