

Initial Clinical Comparison of ^{18}F -Florbetapir and ^{18}F -FDG PET in Patients with Alzheimer Disease and Controls

Andrew B. Newberg¹, Steven E. Arnold², Nancy Wintering¹, Barry W. Rovner¹, and Abass Alavi²

¹Thomas Jefferson University and Hospital, Philadelphia, Pennsylvania; and ²University of Pennsylvania, Philadelphia, Pennsylvania

The purpose of this study was to determine how clinical interpretations of the ^{18}F -amyloid tracer florbetapir compares diagnostically with ^{18}F -FDG PET when evaluating patients with Alzheimer disease (AD) and controls. **Methods:** Nineteen patients with a clinical diagnosis of AD and 21 elderly controls were evaluated with both ^{18}F -florbetapir and ^{18}F -FDG PET scans. Scans were interpreted together by 2 expert readers masked to any case information and were assessed for tracer binding patterns consistent with AD. The criteria for interpreting the ^{18}F -florbetapir scan as positive for AD was the presence of binding in the cortical regions relative to the cerebellum. ^{18}F -FDG PET scans were interpreted as positive if they displayed the classic pattern of hypometabolism in the temporoparietal regions. Scans were interpreted as either positive or negative for AD. In addition, a relative scoring system was used to assess the degree of either hypometabolism or amyloid binding in specified regions. The metabolism and amyloid binding scores for each region were compared across subjects. An overall ratio was calculated on the basis of values in regions expected to be affected by AD and those not expected to be affected. The metabolic ratio and amyloid ratio were then correlated with the mini-mental status examination (MMSE) score. **Results:** The sensitivity and specificity, compared with the clinical diagnosis of AD or controls, for the ^{18}F -florbetapir scans were 95% and 95%, respectively, and for the ^{18}F -FDG scans 89% and 86%, respectively. When a comparison with MMSE scores was made, ^{18}F -FDG significantly correlated with MMSE when both controls and AD patients were included ($r = 0.79$, $P < 0.0001$) and in AD patients alone ($r = 0.70$, $P = 0.001$). The ^{18}F -florbetapir scores significantly correlated with MMSE scores only when both controls and AD patients were included ($r = 0.62$, $P < 0.001$) but not in the AD group alone ($r = 0.12$, $P = 0.66$). **Conclusion:** Overall, both scans performed well in detecting AD in patients with known clinical AD. Both scans correlated well with cognitive status as determined by MMSE when the entire cohort of controls and AD patients was evaluated. However, only the ^{18}F -FDG scans correlated with cognitive status when AD patients were evaluated separately.

Key Words: amyloid imaging; fluorodeoxyglucose; positron emission tomography; Alzheimer disease

J Nucl Med 2012; 53:902–907

DOI: 10.2967/jnumed.111.099606

Alzheimer disease (AD) is a brain disorder of older adults, with symptoms of progressive decline in memory and other cognitive functions. A definitive diagnosis of AD can be established only by demonstrating the presence of abundant senile plaques and neurofibrillary tangles in post-mortem brain sections (1,2). During life, most patients are diagnosed by clinical criteria that imperfectly track with postmortem pathologic findings. The criteria for the diagnosis of AD were defined by the Working Group of the National Institute of Neurologic and Communicative Disorders and Stroke and the Alzheimer Disease and Related Disorders Association in 1984 (3). By most diagnostic criteria in use today, AD is a diagnosis of exclusion based on evidence of chronic, progressive cognitive and functional decline of insidious onset in middle-aged and elderly patients with no identifiable alternative explanations, such as major stroke, tumor, or systemic disease. Unfortunately, although it is possible to make an accurate diagnosis of dementia in most patients with moderate or severe disease, it can be difficult to differentiate between AD and other dementing disorders in patients with early or mild disease (4,5). Molecular or functional neuroimaging studies with PET should help establish an earlier and more accurate diagnosis of AD and help monitor disease progression. These goals are particularly relevant to current and future clinical trials of disease-modifying treatments for AD, in which recruitment of participants who are at high risk of developing or who already have prodromal AD increases trial efficiency, offers the opportunity to follow disease progression and response to therapy, and determines specific patterns of pathology in AD.

Since the 1980s, ^{18}F -FDG PET has been considered one of the most accurate nuclear medicine imaging tests for detecting AD. Initial ^{18}F -FDG PET studies, comparing cerebral metabolic rate for glucose consumption (CMRGlc) in patients with AD with age-matched, healthy controls, showed that there is a 20%–30% decrease in whole-brain CMRGlc values in patients with AD when compared with healthy age-matched controls (6). Other studies showed that patients with AD have decreased CMRGlc, whereas the bilateral parietal and temporal lobes are particularly affected (7–9). In general, this classic pattern of temporoparietal lobe hypometabolism has demonstrated a sensitivity and specificity of approximately 80%–90% (10–13).

Received Oct. 17, 2011; revision accepted Jan. 12, 2012.

For correspondence contact: Andrew B. Newberg, Thomas Jefferson University and Hospital, 1015 Chestnut St., Ste. 412, Philadelphia, PA 19107.

E-mail: Andrew.newberg@jefferson.edu

Published online May 10, 2012.

COPYRIGHT © 2012 by the Society of Nuclear Medicine, Inc.

Because the definitive diagnosis of AD requires the presence of abundant amyloid- β deposits throughout the cerebral cortex of AD patients, *in vivo* imaging agents that are specific and sensitive for detecting amyloid plaques would be extremely useful for the molecular diagnosis of AD (14,15). The early development of such imaging agents includes several ^{11}C - and ^{18}F -labeled tracers such as 6-OH-BTA-1 ([*N*-methyl]-2-(4'-methylaminophenyl)-6-hydroxybenzothiazole (16), SB-13 (4-*N*-methylamino-4'-hydroxystilbene) (17,18), and FDDNP (2-(1-{6-[(2- ^{18}F -fluoroethyl)(methyl)amino]2-naphthyl} ethylidene)malononitrile) (19), and there have been several studies evaluating their ability to accurately diagnose AD.

^{18}F -florbetapir has been studied in several completed phase I and phase II clinical trials and ongoing phase III clinical trials (20,21). It has been shown to accurately detect amyloid in the brain and help differentiate patients with AD from controls (22,23).

Because ^{18}F -FDG is still the most widely used PET agent for the evaluation of dementia patients, comparison with ^{18}F -FDG is appropriate for newer radiopharmaceuticals that bind to pathophysiologic molecules in the brain such as amyloid plaques. Such a precedent has already been set with the evaluation of ^{11}C -Pittsburgh compound B (^{11}C -PIB), in which the first human studies compared uptake of ^{11}C -PIB with cerebral metabolism. The findings showed a relatively strong inverse correlation between the ^{11}C -PIB uptake and hypometabolism in various cortical areas, particularly the parietal lobes. In fact, a recent study comparing ^{18}F -FDG and ^{11}C -PIB PET scans for 7 AD patients and 14 controls demonstrated a good concordance of hypometabolism and amyloid binding, particularly in the frontal, parietal, and temporal cortices (24). Thus, an adequate evaluation of amyloid tracers should include a comparison with clinical ^{18}F -FDG PET to assess the extent of correlation between the 2 scans and their ability to differentiate AD patients from cognitively normal controls.

There have been no direct comparisons between ^{18}F -florbetapir and ^{18}F -FDG PET in the same subjects. The purpose of this study was to compare ^{18}F -florbetapir and ^{18}F -FDG PET results in the same AD and control subjects to determine diagnostic accuracy and also to compare metabolism with amyloid burden. The current paper presents the initial results based on qualitative evaluations by expert readers. Although future studies will likely compare computer-based semiquantitative measures of metabolism or plaque burden, most nuclear medicine scans are qualitatively interpreted by radiologists or nuclear medicine physicians, and therefore, it is important to determine the utility of these scans in such a clinical setting as well.

MATERIALS AND METHODS

Subject Selection

Nineteen patients with a clinical diagnosis of AD (8 men and 11 women; mean age \pm SD, 73 \pm 9 y) and 21 elderly cognitively normal controls (13 men and 8 women; mean age \pm SD, 67 \pm 13 y) were evaluated with both ^{18}F -florbetapir and ^{18}F -FDG PET scans. The patients were given the diagnosis of probable AD on the basis of the criteria of the National Institute of Neurologic and Communicative

Disorders and Stroke and the Alzheimer Disease and Related Disorders Association Work Group and had no other underlying disease process that could have caused or maintained the dementia. All subjects were given a mini-mental status examination (MMSE), with possible scores of 0 (severely demented) to 30 (normal). The mean MMSE was 20 \pm 7 for the AD patients and 29 \pm 1 for the controls.

^{18}F -FDG PET

^{18}F -FDG PET was done according to the Alzheimer's Disease Neuroimaging Initiative protocol (25). Briefly, an intravenous catheter was inserted. The patient's eyes were open, ears were unoccluded, and ambient noise was kept to a minimum during the study. The patients were then injected with 185 MBq (5 mCi) of ^{18}F -FDG. Scanning was initiated 30 min after the administration of ^{18}F -FDG. Images were obtained over 30 min, followed by a transmission scan for attenuation correction. The head was fixed in place throughout the study by a head holder, and the correct position was monitored by an investigator or technologist. At the completion of the scanning, the images were reconstructed in the transaxial planes using an iterative reconstruction process (26).

^{18}F -Florbetapir PET

^{18}F -florbetapir PET was performed according to the prior protocols (20). Briefly, an intravenous catheter was inserted. The patients were then injected with 370 MBq (10 mCi) of ^{18}F -florbetapir. Scanning was initiated 50 min after the administration of ^{18}F -FDG. Images were obtained over 10 min, followed by a transmission scan for attenuation correction. The head was fixed in place throughout the study by a head holder, and the correct position was monitored by an investigator or technologist. At the completion of the scanning, the images were reconstructed in the transaxial planes using an iterative reconstruction process.

Image Interpretation

All PET scans were interpreted by 2 board-certified nuclear medicine physicians with extensive experience interpreting brain PET scans. The reviewers interpreted all the scans together by consensus in a randomized order for both the ^{18}F -FDG and the ^{18}F -florbetapir scans. This study was not designed to assess how different readers perform when evaluating these 2 different PET scans, but rather for them to make an optimal visual evaluation of the 2 scans and compare the ability of the scans to diagnose Alzheimer disease. The reviewers were masked to any clinical information. Future studies with a larger sample size will be needed to better evaluate interreader reliability and consistency.

Two assessments were made for the interpretation of each PET scan. The first assessment yielded a categorical determination of AD or not AD based on the pattern of activity observed on the 2 scans. For the ^{18}F -FDG PET scans, a pattern of temporoparietal hypometabolism was used to distinguish AD from controls. For the ^{18}F -florbetapir scan, the presence of uptake in the cortical regions, compared with the cerebellum, was used to distinguish AD from controls.

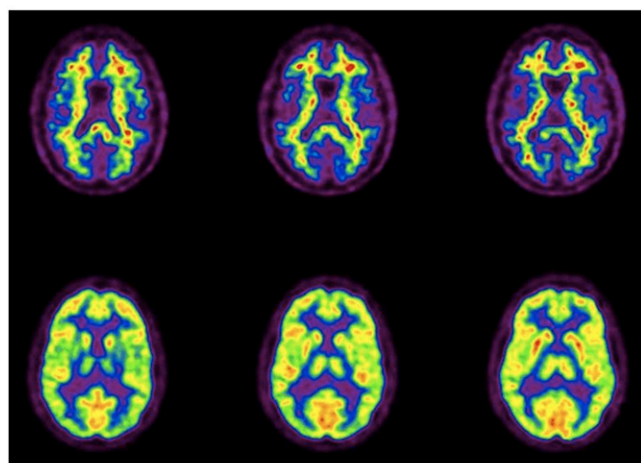
The second assessment was to qualitatively rate the activity in 3 major cortical brain regions, the frontal, temporal, and parietal lobes, for both the ^{18}F -FDG and the ^{18}F -florbetapir scans. The metabolic activity of each anatomic structure on the PET scan was given a score of 4 for normal activity, 3 for mildly decreased activity, 2 for moderately decreased activity, 1 for severely decreased activity, and 0 for no activity. ^{18}F -florbetapir PET images were assessed visually using a similar semiquantitative score ranging from 0 (no amyloid) to 4 (high levels of cortical amyloid). This approach was similar to that in a recent comparison study of

^{18}F -florbetapir to neuropathologic diagnosis (20). The sum of the values obtained for each of the cortical areas was compared between scans and also with the severity of cognitive impairment as determined by the MMSE.

Data Analysis

The diagnoses based on the ^{18}F -FDG and ^{18}F -florbetapir PET scans were compared with the clinical diagnoses. Sensitivity and specificity were determined. Linear regression models were used to compare the sum of the uptake scores in the frontal, temporal, and parietal regions with the MMSE for the entire cohort of AD and control subjects and just for AD subjects. Similarly, linear regression models were used to compare the sum of the amyloid uptake in the same regions with the MMSE for the entire cohort of AD and control subjects as well as just for AD subjects. Finally, the uptake for the ^{18}F -FDG and ^{18}F -florbetapir scans was compared with each other for specific regions of the frontal, temporal, and parietal lobes as well as the overall sum, using regression models.

A



B

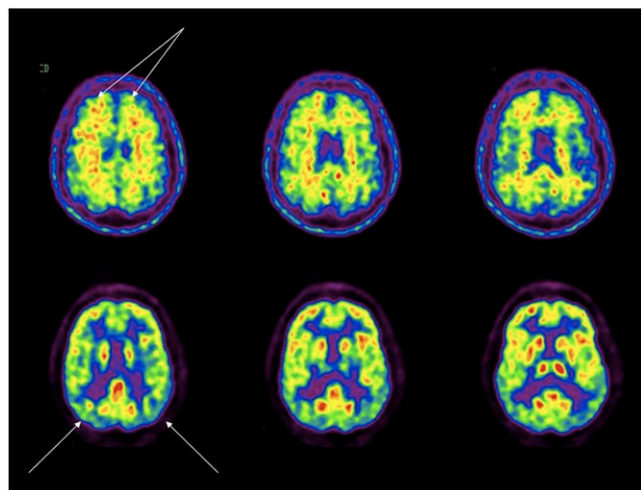


FIGURE 1. ^{18}F -florbetapir (top) and ^{18}F -FDG (bottom) images of control subject with negative findings on both scans (A) and control subject with positive findings on both scans (B) (arrows on ^{18}F -florbetapir scan points to uptake in frontal cortex and arrows on the ^{18}F -FDG scan show mildly decreased metabolism in temporoparietal regions).

RESULTS

The sensitivity and specificity, compared with the clinical diagnosis of AD or controls, were 95% and 95%, respectively, for the ^{18}F -florbetapir scans and 89% and 86%, respectively, for the ^{18}F -FDG scans. ^{18}F -florbetapir PET disagreed with the clinical diagnosis in only 2 subjects. In a single control subject, ^{18}F -florbetapir PET was rated as positive—interestingly, this subject also had an ^{18}F -FDG scan rated as positive for AD (Fig. 1). In addition, in a single probable-AD subject, ^{18}F -florbetapir PET was negative (Fig. 2). This patient was found on follow-up clinical evaluation to have symptoms that might suggest a frontotemporal dementia. In this patient, the ^{18}F -FDG PET scan (interpreted as positive for AD) did reveal a temporoparietal pattern, although the frontal lobes also had decreased metabolism.

When a comparison with MMSE scores was made (Fig. 3), ^{18}F -FDG significantly correlated with MMSE when both controls and AD patients were compared ($r = 0.79$, $P < 0.0001$) and when AD patients were compared separately ($r = 0.90$, $P = 0.0001$). The ^{18}F -florbetapir results significantly correlated with MMSE scores when both controls and AD patients were compared ($r = 0.64$, $P < 0.0001$) but not when only AD patients were compared separately ($r = 0.26$, $P = 0.34$).

When the ^{18}F -FDG and ^{18}F -florbetapir scans were compared for the entire group of patients, the following correlations were obtained. There were significant inverse correlations between ^{18}F -FDG uptake and ^{18}F -florbetapir uptake in the frontal, parietal, and temporal lobes, consistent with the notion that areas of amyloid deposition have decreased metabolism (Table 1). However, when ^{18}F -FDG and ^{18}F -florbetapir scans were compared only in the AD patients, there was a trend toward an inverse correlation in the frontal lobes (right frontal lobe, $R = 0.44$, $P = 0.06$, and left frontal lobe, $R = 0.47$, $P = 0.04$), but no significant correlations were observed in the other brain regions. This

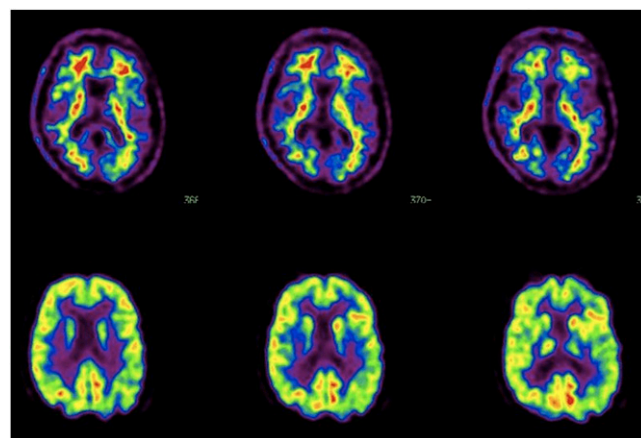


FIGURE 2. ^{18}F -florbetapir (top) and ^{18}F -FDG (bottom) images of patient initially diagnosed with probable AD, which was negative on ^{18}F -florbetapir scan and mildly positive on ^{18}F -FDG scan (mildly decreased metabolism in temporoparietal area is shown with arrows). However, this patient, on longer follow-up, was suspected of having frontotemporal dementia instead.

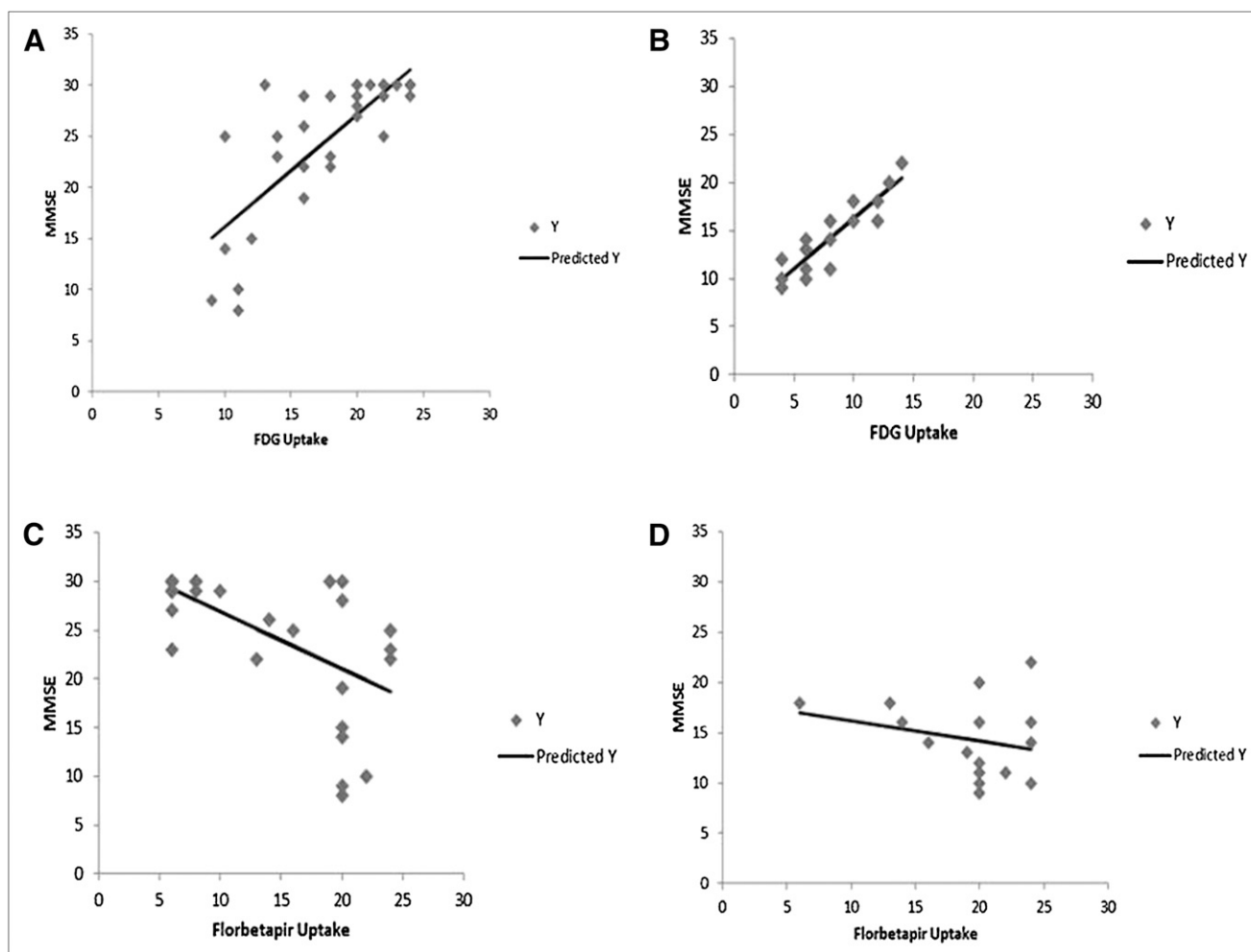


FIGURE 3. Correlation analysis for MMSE vs. ^{18}F -FDG and ^{18}F -florbetapir uptake scores. Graphs show correlation between MMSE and ^{18}F -FDG uptake scores summed for temporal, parietal, and frontal cortical regions for entire set of AD and control subjects (A); correlation between MMSE and ^{18}F -FDG uptake scores summed for temporal, parietal, and frontal cortical regions for AD subjects only (B); correlation between MMSE and ^{18}F -florbetapir uptake scores summed for temporal, parietal, and frontal cortical regions for entire set of AD and control subjects (C); and correlation between MMSE and ^{18}F -florbetapir uptake scores summed for temporal, parietal, and frontal cortical regions for AD subjects only.

is consistent with the above findings in which ^{18}F -FDG uptake correlated better with severity of disease in AD patients. Thus, amyloid deposition correlates with decreased metabolism, but the amount of amyloid binding by ^{18}F -florbetapir does not correlate with the amount of metabolic deficit in the AD patients, particularly as it relates to cognitive impairment.

TABLE 1

Correlation Between ^{18}F -FDG Uptake and ^{18}F -Florbetapir Binding in Major Cortical Regions

Region	<i>R</i>	<i>P</i>
Right frontal	−0.53	0.0003
Left frontal	−0.49	0.0010
Right parietal	−0.54	0.0003
Left parietal	−0.51	0.0006
Right temporal	−0.63	>0.0001
Left temporal	−0.57	>0.0001

DISCUSSION

Encouraging results reported with amyloid tracers in AD patients suggest that development of imaging agents for mapping amyloid plaques in the living human brain may be extremely useful for detecting disease. Further, it is hoped that amyloid imaging may be useful for detecting changes in amyloid plaque burden, especially as it pertains to treatment approaches that attempt to target amyloid plaque burden. However, this is the first study, to our knowledge, to directly compare ^{18}F -florbetapir with ^{18}F -FDG PET.

For almost 2 decades, ^{18}F -FDG PET has been available and clinically used for helping with the diagnosis of AD. In fact, since 1980, many studies have used ^{18}F -FDG PET in the assessment of patients with AD (27–29). These studies showed that the bilateral parietal and temporal lobes and the posterior cingulate gyrus are particularly hypometabolic in patients with AD (7,8). This temporoparietal hypometabolism is often referred to as representing the typical pattern

of AD and may be particularly pronounced in patients with an age less than 65 y (30). Physiologically, this temporoparietal hypometabolism represents neuronal dysfunction resulting from the disease process in AD. Several recent studies, including a metaanalysis of 15 studies using ^{18}F -FDG PET in the diagnosis of AD, showed a sensitivity and specificity of approximately 86% for this temporoparietal hypometabolism pattern (12,13). The results from this current study are consistent with these previous ^{18}F -FDG PET findings. Such findings have led to ^{18}F -FDG PET being used and reimbursed by payers (including the Centers for Medicare and Medicaid Services) for the clinical diagnosis of AD and its differentiation from frontal lobe dementia. However, the temporoparietal hypometabolism pattern is not pathognomonic for AD and may be seen in patients with Parkinson disease, bilateral parietal subdural hematomas, bilateral parietal stroke, and bilateral parietal radiation ports (31). Other areas (e.g., the sensorimotor and visual cortices, subcortical nuclei, brain stem, and cerebellum) have more preserved CMRGlC but can also be abnormal in patients with specific neuropsychologic deficits (32–34). Thus, ^{18}F -FDG PET has its limitations from a diagnostic perspective.

Considering several other issues with ^{18}F -FDG PET, including medication effects and sensory stimulation that can interfere with metabolism, it seems appropriate to try to find other radiopharmaceuticals that are more specific for detecting the pathophysiologic hallmarks of AD such as amyloid burden. This need led to the development of compounds such as ^{18}F -florbetapir, but it is also clear that the ability of ^{18}F -florbetapir to diagnose AD must be compared with the same ability of ^{18}F -FDG PET. In this initial study, it appears that ^{18}F -florbetapir has a higher sensitivity and specificity for AD. This result is expected given the more disease-specific association of the ^{18}F -florbetapir.

This is the first study, to our knowledge, to compare these 2 imaging tracers head to head in the same subjects. This initial study sought to assess the ability of visual clinical interpretations by expert reviewers to assess the scans for the diagnosis of AD and also to help assess severity of disease. Although future studies will likely compare computer-based semiquantitative measures of metabolism or plaque burden, most nuclear medicine scans are qualitatively interpreted by radiologists or nuclear medicine physicians. Therefore, it is important to determine the utility of these scans in such a clinical setting, focusing on the qualitative interpretation. One of the current issues that has arisen with the interpretation of ^{18}F -florbetapir scans is the determination of interreader reliability. This particular issue was not evaluated in the current study and will need to be assessed in a larger sample of patients.

The results of the current study are similar to those of previous single-radiopharmaceutical studies in terms of the ability of ^{18}F -FDG or ^{18}F -florbetapir to diagnose AD. However, this is the first time the 2 tracers have been compared head to head in the same subjects. Although the cohort is relatively small, the sensitivity and specificity obtained in

this study for ^{18}F -FDG were 89% and 86%, respectively, similar to previous reports. The sensitivity and specificity of ^{18}F -florbetapir scan results were 95% and 95%, respectively. This is the first report in the literature of these values when compared with the clinical diagnosis, although a previous comparison of ^{18}F -florbetapir uptake demonstrated a 96% concordance with amyloid plaque observed on post-mortem neuropathologic evaluation (20).

Another important aspect of different tracers is not only to determine their diagnostic accuracy but also to assess their ability to correlate with disease severity. Several earlier studies have shown that the magnitude and extent of hypometabolism observed on ^{18}F -FDG PET scans generally correlate with the severity of the dementia symptoms (35). The more severe the metabolic abnormalities, the worse the patient generally functions both on cognitive tests and on measures of activities of daily living. Longitudinal studies have shown that CMRGlC values decrease more rapidly over time in patients with AD than in age-matched control subjects, and therefore, ^{18}F -FDG PET may be a useful marker for disease progression over time (36). One study observed this association in 120 AD patients undergoing ^{18}F -FDG PET (37), in which there was a significant correlation between cerebral metabolism and the Clinical Dementia Rating score. A comparison of amyloid imaging tracers with ^{18}F -FDG PET can provide an additional measure of disease severity and would help demonstrate the ability of ^{18}F -florbetapir to correlate with the disease severity.

In the current study, ^{18}F -FDG PET results again correlated well with disease severity as measured by MMSE. The correlation was strongest when the entire cohort of AD patients and controls was compared. This strong correlation is anticipated because of the expected normal metabolism in control subjects and abnormal uptake in AD patients. However, ^{18}F -FDG uptake also did well when compared with MMSE for only the AD patients, suggesting that cerebral glucose metabolism as measured by ^{18}F -FDG is strongly correlated with disease severity. ^{18}F -florbetapir values correlated significantly with disease severity when the entire cohort of controls and AD patients was evaluated. However, the correlation between amyloid binding and MMSE did not hold when evaluated only in the AD patients. This result suggests that amyloid binding does not increase as clinical measures of disease severity worsen and is expected given the currently observed clinical relationship between pathologic amyloid binding and disease progression. However, a larger database with quantitative analysis of the ^{18}F -florbetapir will be needed to confirm this finding.

Although the scans were not analyzed quantitatively, we evaluated the metabolism and amyloid binding by providing a qualitative score based on the interpretation for the frontal, temporal, and parietal regions. There were significant correlations in these regions when we compared the entire cohort of both AD and control subjects. Thus, the greater the amyloid binding, the lower the metabolism in these regions—consistent with a recent study comparing

^{18}F -FDG scans with ^{11}C -PIB PET scans in subjects with AD and mild cognitive impairment and controls (38). We also compared the amyloid binding with metabolism in controls and AD subjects as well as AD subjects alone. When ^{18}F -florbetapir binding and ^{18}F -FDG uptake were compared within the AD patients only, no significant correlations were found. This result is consistent with the finding that ^{18}F -FDG uptake correlated with disease severity in the AD patients whereas ^{18}F -florbetapir uptake did not. This is also similar to the findings reported when comparing ^{11}C -PIB with ^{18}F -FDG (38).

CONCLUSION

Future studies should more effectively quantify the results from the 2 scans, but the purpose of this initial evaluation was to base the findings as much as possible using the manner that would typically be used in a clinical setting.

DISCLOSURE STATEMENT

The costs of publication of this article were defrayed in part by the payment of page charges. Therefore, and solely to indicate this fact, this article is hereby marked "advertisement" in accordance with 18 USC section 1734.

ACKNOWLEDGMENTS

This work was supported in by NIH grant AG028688. No other potential conflict of interest relevant to this article was reported.

REFERENCES

- Ginsberg SD, Schmidt ML, Crino PB, Eberwine JH, Lee VM-Y, Trojanowski JQ. Molecular pathology of Alzheimer's disease and related disorders. In: Peters A, Morrison JH, eds. *Cerebral Cortex: Neurodegenerative and Age-Related Changes In Structure and Function of Cerebral Cortex*. New York, NY: Kluwer Academic/Plenum. 1999:603–654.
- Selkoe DJ. The origins of Alzheimer disease: A is for amyloid. *JAMA*. 2000;283:1615–1617.
- McKhann G, Drachman D, Folstein M, Katzman R, Price D, Stadlan EM. Clinical diagnosis of Alzheimer's disease: report of the NINCDS-ADRDA Work Group under the auspices of Department of Health and Human Services Task Force on Alzheimer's Disease. *Neurology*. 1984;34:939–944.
- Tierney MC, Gisher RH, Lewis AJ, et al. The NINCDS-ADRDA Workgroup criteria for the clinical diagnosis of probable Alzheimer's disease: a clinical pathological study of 57 cases. *Neurology*. 1988;38:359–364.
- Joachim CL, Morris JH, Selkoe DJ. Clinically diagnosed Alzheimer's disease: autopsy results in 150 cases. *Ann Neurol*. 1988;24:50–56.
- Alavi A, Reivich M, Ferris S, et al. Regional cerebral glucose metabolism in aging and senile dementia as determined by ^{18}F -deoxyglucose and positron emission tomography. *Exp Brain Res*. 1982;(suppl 5):187–195.
- Heiss WD, Kessler J, Szekely B, et al. Positron emission tomography in the differential diagnosis of organic dementias. *J Neural Transm Suppl*. 1991;33:13–19.
- Kumar A, Schapiro MB, Grady C, et al. High-resolution PET studies in Alzheimer's disease. *Neuropsychopharmacology*. 1991;4:35–46.
- Bonte FJ, Hom J, Tinter R, Weiner MF. Single photon tomography in Alzheimer's disease and the dementias. *Semin Nucl Med*. 1990;20:342–352.
- Friedland RP, Budinger TF, Brant-Zawadzki M, et al. The diagnosis of Alzheimer-type dementia: a preliminary comparison of positron emission tomography and proton magnetic resonance. *JAMA*. 1984;252:2750–2752.
- Herholz K, Salmon E, Perani D, et al. Discrimination between Alzheimer dementia and controls by automated analysis of multicenter FDG PET. *Neuroimage*. 2002;17:302–316.
- Silverman DH, Small GW, Chang CY, et al. Positron emission tomography in evaluation of dementia: regional brain metabolism and long-term outcome. *JAMA*. 2001;286:2120–2127.
- Patwardhan MB, McCrory DC, Matchar DB, Samsa GP, Rutschmann OT. Alzheimer disease: operating characteristics of PET: a meta-analysis. *Radiology*. 2004;231:73–80.
- Selkoe DJ. Imaging Alzheimer's amyloid. *Nat Biotechnol*. 2000;18:823–824.
- Hardy J, Selkoe DJ. The amyloid hypothesis of Alzheimer's disease: progress and problems on the road to therapeutics. *Science*. 2002;297:353–356.
- Mathis CA, Wang Y, Holt DP, Huang G-F, Debnath ML, Klunk WE. Synthesis and evaluation of ^{11}C -labeled 6-substituted 2-arylbenzothiazoles as amyloid imaging agents. *J Med Chem*. 2003;46:2740–2754.
- Ono M, Kung M-P, Hou C, Kung HF. Benzofuran derivatives as A β -aggregate-specific imaging agents for Alzheimer's disease. *Nucl Med Biol*. 2002;29:633–642.
- Wilson A, Nobrega J, Houle S, et al. Radiosynthesis and evaluation of potential β -amyloid imaging radiotracer for PET. *J Labelled Comp Radiopharm*. 2003;46: S61–S65.
- Shoghi-Jadid K, Small GW, Agdeppa ED, et al. Localization of neurofibrillary tangles and beta-amyloid plaques in the brains of living patients with Alzheimer disease: binding characteristics of radiofluorinated 6-dialkylamino-2-naphthylethylidene derivatives as positron emission tomography imaging probes for beta-amyloid plaques in Alzheimer disease. *Am J Geriatr Psychiatry*. 2002;10:24–35.
- Clark CM, Schneider JA, Bedell BJ, et al. Use of florbetapir-PET for imaging beta-amyloid pathology. *JAMA*. 2011;305:275–283.
- Lin KJ, Hsu WC, Hsiao IT, et al. Whole-body biodistribution and brain PET imaging with [^{18}F]AV-45, a novel amyloid imaging agent: a pilot study. *Nucl Med Biol*. 2010;37:497–508.
- Wong DF, Rosenberg PB, Zhou Y, et al. In vivo imaging of amyloid deposition in Alzheimer disease using the radioligand ^{18}F -AV-45 (florbetapir [corrected] F 18). *J Nucl Med*. 2010;51:913–920.
- Fleisher AS, Chen K, Liu X, et al. Using positron emission tomography and florbetapir F18 to image cortical amyloid in patients with mild cognitive impairment or dementia due to Alzheimer disease. *Arch Neurol*. 2011;68:1404–1411.
- Shin J, Tsui W, Lee S-Y, et al. Resting-state glucose metabolism level is associated with the regional pattern of amyloid pathology in Alzheimer's disease. *Inter J Alz Dis*. 2011;2011:759780.
- Langbaum JB, Chen K, Lee W, et al. Categorical and correlational analyses of baseline fluorodeoxyglucose positron emission tomography images from the Alzheimer's Disease Neuroimaging Initiative (ADNI). *Neuroimage*. 2009;45:1107–1116.
- Chang LT. A method for attenuation correction in radionuclide computed tomography. *IEEE Trans Nucl Sci*. 1978;25:638–643.
- Friston KJ, Frackowiak RS. Cerebral function in aging and Alzheimer's disease: the role of PET. *Electroencephalogr Clin Neurophysiol Suppl*. 1991;42:355–365.
- Friedland RP, Jagust WJ, Huesman RH, et al. Regional cerebral glucose transport and utilization in Alzheimer's disease. *Neurol (Tokyo)*. 1989;39:1427–1434.
- Jagust WJ, Friedland RP, Budinger TF, Koss E, Ober B. Longitudinal studies of regional cerebral metabolism in Alzheimer's disease. *Neurology*. 1988;38:909–912.
- Ichimiya A, Herholz K, Mielke R, et al. Difference of regional cerebral metabolic pattern between presenile and senile dementia of the Alzheimer type: a factor analytic study. *J Neurol Sci*. 1994;123:11–17.
- Mazziotta JC, Frackowiak RSJ, Phelps ME. The use of positron emission tomography in the clinical assessment of dementia. *Semin Nucl Med*. 1992;22:233–246.
- Kushner M, Tobin M, Alavi A, et al. Cerebellar glucose consumption in normal and pathologic states using fluorine-FDG and PET. *J Nucl Med*. 1987;28:1667–1670.
- Chase TN, Foster NL, Fedio P, et al. Regional cortical dysfunction in Alzheimer's disease as determined by positron emission tomography. *Ann Neurol*. 1984;15:S170–S174.
- McGeer EG, Peppard RP, McGeer PL, et al. 18-Fluorodeoxyglucose positron emission tomography studies in presumed Alzheimer cases. *Can J Neurol Sci*. 1990;17:1–11.
- Drzezga A, Lautenschlager N, Siebner H, et al. Cerebral metabolic changes accompanying conversion of mild cognitive impairment into Alzheimer's disease: a PET follow-up study. *Eur J Nucl Med Mol Imaging*. 2003;30:1104–1113.
- Alexander GE, Chen K, Pietrini P, Rapoport SI, Reiman EM. Longitudinal PET evaluation of cerebral metabolic decline in dementia: a potential outcome measure in Alzheimer's disease treatment studies. *Am J Psychiatry*. 2002;159:738–745.
- Kim EJ, Cho SS, Jeong Y, et al. Glucose metabolism in early onset versus late onset Alzheimer's disease: an SPM analysis of 120 patients. *Brain*. 2005;128:1790–1801.
- Cohen AD, Price JC, Weissfeld LA, et al. Basal cerebral metabolism may modulate the cognitive effects of A β in mild cognitive impairment: an example of brain reserve. *J Neurosci*. 2009;29:14770–14778.



The Journal of
NUCLEAR MEDICINE

Initial Clinical Comparison of ^{18}F -Florbetapir and ^{18}F -FDG PET in Patients with Alzheimer Disease and Controls

Andrew B. Newberg, Steven E. Arnold, Nancy Wintering, Barry W. Rovner and Abass Alavi

J Nucl Med. 2012;53:902-907.

Published online: May 10, 2012.

Doi: 10.2967/jnumed.111.099606

This article and updated information are available at:

<http://jnm.snmjournals.org/content/53/6/902>

Information about reproducing figures, tables, or other portions of this article can be found online at:


<http://jnm.snmjournals.org/site/misc/permission.xhtml>

Information about subscriptions to JNM can be found at:

<http://jnm.snmjournals.org/site/subscriptions/online.xhtml>

The Journal of Nuclear Medicine is published monthly.
SNMMI | Society of Nuclear Medicine and Molecular Imaging
1850 Samuel Morse Drive, Reston, VA 20190.
(Print ISSN: 0161-5505, Online ISSN: 2159-662X)

© Copyright 2012 SNMMI; all rights reserved.

 SOCIETY OF
NUCLEAR MEDICINE
AND MOLECULAR IMAGING