

Clinically Significant Abnormal Findings on the “Nondiagnostic” CT Portion of Low-Amperage-CT Attenuation-Corrected Myocardial Perfusion SPECT/CT Studies

Sibyll Goetze, Harpreet K. Pannu, and Richard L. Wahl

Russell H. Morgan Department of Radiology and Radiological Science, Johns Hopkins University, Baltimore, Maryland

Attenuation correction is recommended to optimize the performance of cardiac SPECT. The 2.5-mA CT commonly used for this purpose in myocardial perfusion SPECT is generally considered “nondiagnostic” in quality. In other areas of cardiac and hybrid imaging, diagnostically relevant abnormal findings on higher-quality CT studies have been described. The purpose of this study was to establish the frequency and significance of abnormal findings on low-amperage-CT cardiac SPECT/CT scans and to assess whether a systematic review of the nondiagnostic CT findings should be recommended. **Methods:** Two hundred consecutive patients who underwent clinical low-amperage-CT attenuation-corrected myocardial perfusion studies acquired on a SPECT/CT system were included in the study. The cardiac CT images were reviewed in consensus by both an experienced CT reader and a nuclear medicine resident less experienced in CT. Abnormal CT findings of varying significance were recorded. **Results:** Eighty-one patients had no abnormal CT findings. In the remaining 119 patients, 234 abnormalities were detected. Twenty-five major findings (in 21 patients) were seen, and 16 of these had been previously unrecognized. Sixty-four minor and 131 minimal findings were noted. Fourteen findings were labeled as equivocal (i.e., the CT findings were not definite). **Conclusion:** Potentially significant abnormal findings on the nondiagnostic-CT portion of the cardiac SPECT/CT examination were detected in 10.5% of our patients. These data suggest that, in addition to the review of the emission image dataset, low-amperage-CT findings should routinely be assessed for major diagnostic abnormalities.

Key Words: SPECT/CT; tomography; incidental findings; myocardial perfusion imaging

J Nucl Med 2006; 47:1312–1318

Myocardial perfusion SPECT is a well-established clinical tool that provides diagnostic and prognostic infor-

mation about coronary artery disease. Attenuation correction is now recommended to improve the diagnostic accuracy of myocardial perfusion SPECT (1). Attenuation maps are usually obtained with a transmission scan from a radioactive line or point source or with CT. The method using CT has the potential advantage of producing a higher-quality attenuation map because it has higher photon-flux, better resolution, and lower noise than do radionuclide transmission sources (2). At present, the low-amperage-CT component of myocardial perfusion SPECT/CT is used almost exclusively for attenuation correction, and only recently have recommendations to review the attenuation maps for quality control purposes been published (1).

Diagnostically relevant abnormal findings on the higher-energy, diagnostic-quality CT portion of the study have been described in other areas of cardiac imaging, especially coronary artery calcium scoring (3–5), and in other areas of fusion imaging such as PET/CT (6). Osman et al. (6) showed important diagnostic findings on the CT portion for 3% of patients referred for oncologic PET/CT examinations using a multislice (80 mA) CT scanner with a 0.8-s rotation. Most cardiac SPECT/CT systems provide only a low-power (2.5 mA) CT scan and have a slow gantry rotation requiring a relatively long time for scan acquisition. The value of independent CT interpretation is not clear, because the diagnostic value of the CT used by the hybrid SPECT/CT systems is obviously limited by the much lower power settings and lower speed than are used with standard CT and by lack of the contrast material used with standard CT. These factors degrade the CT image quality.

We sought to establish the frequency and significance of abnormal anatomic findings on CT attenuation-corrected cardiac SPECT/CT scans to assess whether a systematic routine diagnostic review of the CT portion should be recommended.

MATERIALS AND METHODS

Patients

We retrospectively evaluated the images from 200 patients (103 female and 97 male; mean age, 55 ± 14 y; range, 17–87 y) who

Received Jan. 19, 2006; revision accepted Apr. 21, 2006.

For correspondence or reprints contact: Richard L. Wahl, MD, Division of Nuclear Medicine/PET, 601 N. Caroline St., Room 3223, Baltimore, MD 21287-0817.

E-mail: rwahl@jhmi.edu

COPYRIGHT © 2006 by the Society of Nuclear Medicine, Inc.

TABLE 1

Characteristics of CT Used for Attenuation Correction in Our Study and of Typical Diagnostic Thoracic Spiral CT at Our Institution

Characteristic	Study CT	Typical CT
X-ray tube current (mA)	2.5	80
X-ray tube voltage (kVp)	140	120
Slice width (mm)	10	3
Field of view	Left ventricle (ascending aorta to apex)	Entire thorax
Scan time	5 min (13-cm average field of view)	8–10 s
Axial resolution (mm)	10	0.7
Breath-hold	No (tidal breathing)	Yes
Use of intravenous contrast material	No	Yes (unless contraindicated)
Radiation	<1 mSv	5–6 mSv

consecutively underwent CT-attenuation-corrected myocardial perfusion studies during 2 periods of approximately 1 mo each (6/10/04 to 7/13/04 and 4/1/05 to 4/26/05). The studies were

acquired on a Millennium VG Hawkeye SPECT/CT system (GE Healthcare), and all patients had been referred for the clinical evaluation of coronary artery disease. SPECT at rest and stress was performed according to standard clinical protocols for myocardial perfusion imaging. In our practice (based on 112 of the included patients), most patients (87%) have both arms above the head for SPECT/CT, 9% have the right arm at the side and left arm above the head, and 4% have both arms at the side. The retrospective image review was approved by the institutional review committee, and the need for informed consent was waived.

CT Scanning

The single-slice nonspiral CT scanner (x-ray tube current, 2.5 mA; voltage, 140 kVp) has a slice thickness (and axial resolution) of 10 mm with a scan time of more than 5 min for a typical 13-cm field of view. The field of view was chosen to fully include the heart (from the ascending aorta to the apex) based on the CT scout image. CT attenuation correction was performed twice for each patient: once for the resting images and once for the stress images. Both were obtained immediately after the acquisition of the SPECT images. The patients received no special breathing instructions (tidal breathing). Table 1

TABLE 2

Summary of Major and Minor Abnormal Findings

Classification	Location	Finding	Number	Known	Not known
Major finding	Cardiovascular	Dilated ascending aorta	2	1	1
		Calcified coronaries	8	6	2
		Pericardial effusion	1		1
	Lung	Lung nodule	6	1	5
		Lung infiltrate	2	1	1
		Lung mass	2	1	1
		Pleural effusion	1		1
		Consolidation/atelectasis	1		1
	Breast	Breast calcification	1		1
	Soft tissue	Anterior mediastinal mass (likely pericardial cyst)	1		1
	Total		25	10	15
Minor finding	Skeletal	Sclerotic bone (focal and diffuse)	2	1	1
	Breast	Dense breasts (for age)	1	1	
	Cardiovascular	Calcified aortic root or valve	2	1	1
		Calcified mitral valve annulus	3	1	2
		Calcified aorta	18	13	5
		Cardiomegaly	3	2	1
		Bullet	1	1	
	Abdomen	Liver cysts	3	3	
		Other liver lesions	2	1	1
		Nodular liver	2	1	1
	Lung	Prominence of common bile duct	1		1
		Splenic cyst or hemangioma	1		1
		Renal cyst	1	1	
		Pleural abnormality (thickening/small effusion/plaque)	6	1	5
		Atelectasis and infiltrate	6	3	3
		Emphysema/bulla	1		1
		Bronchiectasis	1	1	
		Scar and air trapping	1		1
		Likely pulmonary arteriovenous malformation	1		1
		Hiatal hernia	6	3	3
	Chest (other)	Prominent thymus	1		1
		Enlarged axillary lymph nodes	1		1
	Total		64	34	30

TABLE 3
Summary of Minimal and Equivocal Abnormal Findings

Classification	Location	Finding	Number
Minimal finding	Skeletal	Osteophytes	66
		Healed rib fracture	1
	Breast/ soft tissue	Breast implants	2
		Mastectomy with or without reconstruction	2
		Gynecomastia	1
		Asymmetric breast	1
		Lipoma	1
	Iatrogenic (other)	Pacemaker	7
		Sternotomy	17
		Aortic valve replacement	1
		Central line	2
		Nephrectomy clips	1
		Cholecystectomy clips	1
	Granulomatous disease	Calcified lymph nodes (hilar and mediastinal)	19
		Liver granuloma	2
		Spleen granuloma	1
		Lung granuloma	2
	Chest (other)	Volume loss after resection, right lung	1
		Elevated hemidiaphragm	1
	Abdomen (other)	Ventral hernia	1
		Gallstones	1
	Total		131
Equivocal finding	Cardiovascular	Coronary calcification	1
		Pericardial effusion	1
	Lung	Pleural thickening	2
		Pulmonary nodule	1
	Abdomen	Emphysema	2
		Splenic cyst	1
		Liver cyst	1
		Liver cyst or hemangioma	1
		Pneumobilia	1
	Musculoskeletal	Fracture vs. calcified muscle	2
	Other	Calcified mediastinal lymph node	1
	Total		14

summarizes the characteristics of the CT scans used for attenuation correction.

Analysis

The CT scans were retrospectively and independently reviewed at a workstation (Xeleris; GE Healthcare) by an expert in body CT (R1) and by a nuclear medicine resident who had not yet received formal training in CT (R2). Each scan was reviewed at 3 different window settings, including a lung window, a soft-tissue window,

and a bone window. The SPECT/CT system provided preset values for each of these windows, and the reader manually optimized the window in each case.

Abnormal findings on CT were recorded and rated as to their significance. The clinical significance was judged to be major when it was thought to require further testing or follow-up or would be important in a patient with symptoms and signs of cardiovascular disease, especially someone suspected to have coronary artery disease. Other findings were classified as minor (less significant than major findings but deemed of some clinical significance and such as would have been mentioned on standard CT) or minimal (less significant than minor findings; possibly of minimal or no clinical significance or of no added value to a standard clinical history). In addition, some findings could be classified only as equivocal (i.e., the CT findings were not definite). After the review of the CT portion of the SPECT/CT study, the patient's electronic medical record was reviewed to decide whether the minor and major findings had been known or unknown at the time of SPECT/CT.

For a subset of 50 patients, both the rest and stress CT studies were reviewed routinely to establish how many findings were seen during only one of the test conditions. For the remaining 150 patients, only the rest CT study was reviewed routinely; stress CT was reviewed when deemed necessary (to distinguish between findings and possible artifacts, all "equivocal" findings). Of note, all types of findings were recorded as 1 finding: For example, the presence of multiple osteophytes in the spine or of multiple calcified mediastinal lymph nodes was recorded as 1 finding. The 2 reviewers then read the scans together, and in virtually all instances, the less experienced reviewer concurred with the more experienced reviewer. Thus, the following results represent the consensus CT interpretation.

RESULTS

All CT scans had some degree of breathing artifacts, likely because of the relatively long scanning time. These were not noted as abnormalities.

Number of Findings

Eighty-one patients had no abnormal CT findings. In the remaining 119 patients, 234 abnormalities were detected. There was an average of 2 findings per patient. Most patients had only 1 finding (58 patients) or 2 findings (36 patients). Ten patients had 3 findings, 7 had 4 findings, 6 had 5 findings, 1 had 6 findings, and 1 had 10 findings.

Significance of Findings

The potential clinical significance of findings was classified as major, minor, minimal, or equivocal (Tables 2 and 3). There were 25 potentially major findings (e.g., pulmonary mass or infiltrates, dilated aorta, or coronary calcification) (Table 4; Figs. 1–5). In addition, there were 64 minor findings (e.g., vascular calcifications or liver lesions) and 131 minimal findings (e.g., osteophytes, calcified lymph nodes, or a pacemaker). Fourteen findings were classified as equivocal because the CT findings were not definite and no corroborative information could be extracted from the patient's record. Because 3 patients had more than 1 major finding, a total of 21 patients had 25 major findings. Most

TABLE 4
Characteristics of Patients with Major Findings

Patient no.	Age (y)	Sex	CT finding	Known	Other imaging findings and prior history	Follow-up
1	81	F	Dilated ascending aorta	Yes	CT, TTE: aortic dilatation	No
2	51	M	Mass in RLL	No	CT: "consolidation" in RLL confirmed; possible early pneumonia; follow-up recommended	No
3	48	M	Infiltrate in RLL	No	CXR 1 d earlier: negative	No
4	73	F	Right pulmonary nodule (Fig. 1)	No	CXR/CT 18 mo later: mass in right lung	Adenocarcinoma of right lung diagnosed 1.5 y later; patient underwent resection
			Anterior mediastinal mass (Fig. 1)	No		Mediastinal cyst confirmed at time of surgery
5	70	M	Dilated ascending aorta	No	Later TTE: aortic dilatation confirmed	No
6	73	M	Coronary calcification	Yes	Coronary angiography 3 y earlier: coronary calcification/CAD	Yes
7	78	M	Pulmonary nodule	No	CXR at same visit: negative	No
8	58	F	Pulmonary nodule	No	CXR 2 y earlier: negative	No
9	58	F	Mass in RLL (Fig. 5)	Yes	CT at same admission: mass in RLL confirmed	No
10	81	M	Pericardial effusion (Fig. 3)	No	Prior CXR: small pleural effusion only; CT (and TTE) days later: large pericardial effusion (no tamponade), pleural effusion, and consolidation confirmed; TTE: "blood clot" within pericardial fluid	Patient treated for congestive heart failure; anticoagulation stopped; follow-up imaging showed (near) resolution of findings
			Large pleural effusion (Fig. 3)	No		
			Consolidation/atelectasis (Fig. 3)	No		
11	54	M	Pulmonary infiltrate (Fig. 4)	Yes	CXR 9 d earlier: RLL infiltrate (pneumonia)	Patient treated with antibiotics; CXR 6 wk later: resolution of pneumonia
12	52	M	Coronary calcification	Yes	Abnormal calcium score (CT)	Patient later underwent coronary angiography and CABG
13	77	F	Coronary calcification	No	None	No
14	62	M	Coronary calcification	Yes	Patient has diagnosis of CAD	No
			Pulmonary nodule	No	CXR 1 d earlier: negative; no CT	No
15	49	F	Breast calcification	No	None	No
16	55	F	Pulmonary nodule	No	CT and CXR 10 mo earlier: negative	CXR 11 mo later: negative; no follow-up CT
17	57	M	Coronary calcification	No	MPI: ischemia in inferior wall; coronary angiography: calcified LAD, 3-vessel CAD	Medical management
18	82	M	Coronary calcification	Yes	Patient has diagnosis of CAD; MPI: ischemia	Medical management
19	47	M	Right pulmonary nodule	Yes	CT 2 wk earlier: right pulmonary nodules	CXR 11 mo later: atelectasis (right); no follow-up CT
20	83	M	Coronary calcification (Fig. 2)	Yes	Patient has diagnosis of CAD	No
21	58	F	Coronary calcification	Yes	CT 8 mo earlier: coronary calcification	No

TTE = transthoracic echocardiography; RLL = right lower lobe; CXR = chest radiograph; CABG = coronary artery bypass grafting; CAD = coronary artery disease; MPI = myocardial perfusion imaging; LAD = left anterior descending coronary artery.

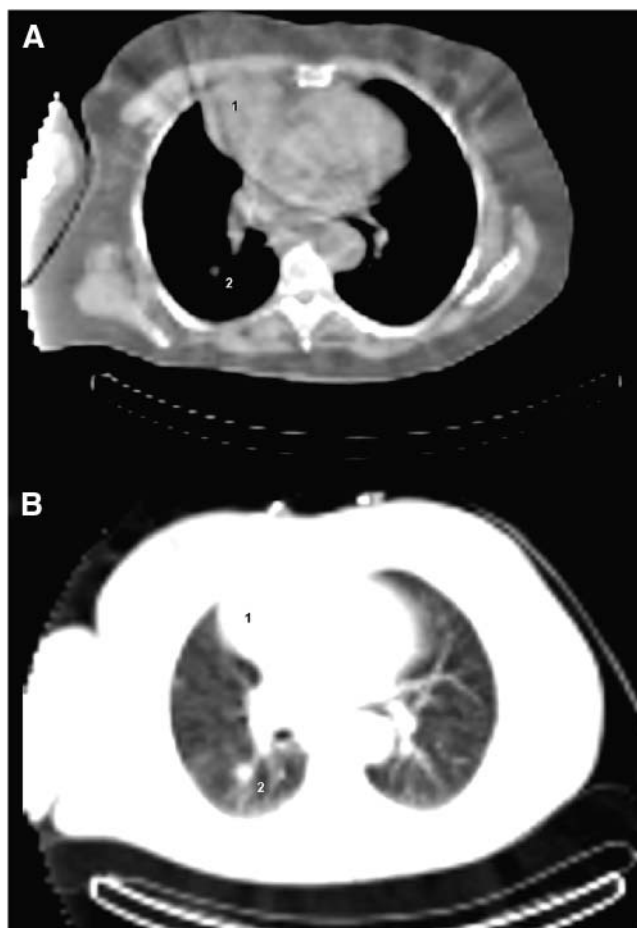


FIGURE 1. Transaxial CT slice of 73-y-old woman with fatigue and exertional dyspnea. Images were obtained with soft-tissue window (A) and with lung window (B). Myocardial perfusion SPECT findings were normal. Large anterior mediastinal mass (1) and lung nodule (2) are seen on CT portion of images. Mediastinal mass is likely pericardial cyst. Both findings were unknown, and there were no follow-up studies for over 1.5 y. Patient was then diagnosed with adenocarcinoma of right lung and underwent resection. Mediastinal cyst was confirmed at surgery.

of the equivocal findings ($n = 9$) were seen in the first 50 patients.

One Versus Two CT Studies

A total of 77 findings were seen in the 50 patients for whom both stress and rest CT findings were systematically reviewed. One finding (major: pulmonary nodule) was apparent on stress imaging but was not seen on rest imaging because of the less cranial field of view of the latter.

Known Versus Unknown Findings

Sixty percent (15/25) of the major findings and 48% (30/62) of the minor findings were unknown at the time of SPECT/CT. However, of the 8 patients with coronary calcifications, all had been referred for myocardial perfusion

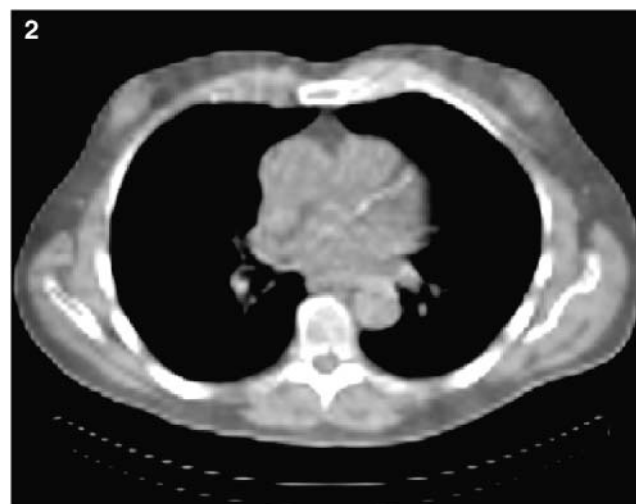


FIGURE 2. Transaxial CT slice of 83-y-old man with coronary artery disease and atypical chest pain. Calcification of left anterior descending artery is seen. In patient with established diagnosis of coronary artery disease, finding is of doubtful clinical significance.

imaging and 6 (75%) were known to have coronary artery disease or calcifications. Incidentally identified coronary calcifications are probably less significant in these patients than in those referred for other reasons (Fig. 2).

DISCUSSION

Myocardial perfusion scintigraphy is a well-established and commonly used technique for the evaluation of coronary artery disease. Its use continues to grow, given the continued increase in cardiovascular disease. In the United States, the current recommendation is to use attenuation correction (1) to process the images. An increasingly popular approach to attenuation correction is a low-amperage (in our case, 2.5 mA) slow-speed CT scan of the heart, or mid to lower thorax. This CT scan, covering about 13 cm in about 5 min, is often blurred by respiratory motion and, given the relatively low photon flux, is generally considered nondiagnostic. To our knowledge, the diagnostic relevance of the findings on this nondiagnostic low-amperage CT scan obtained for attenuation correction has not been systematically studied.

We observed a total of 234 findings in 200 patients, of which 25 findings were classified as having potentially major clinical significance. Significant abnormal findings on the CT portion of the cardiac SPECT/CT study were detected in 10.5% (21/200 patients) of our population. Potentially significant unknown findings ($n = 15$) were seen in 6% of the patients ($n = 12$). In general, the stress and rest scans had nearly identical findings. Because we had a subjective impression of slightly less motion degradation on the CT scan obtained at rest, examining the rest study alone should be adequate. The field of view is guided by the

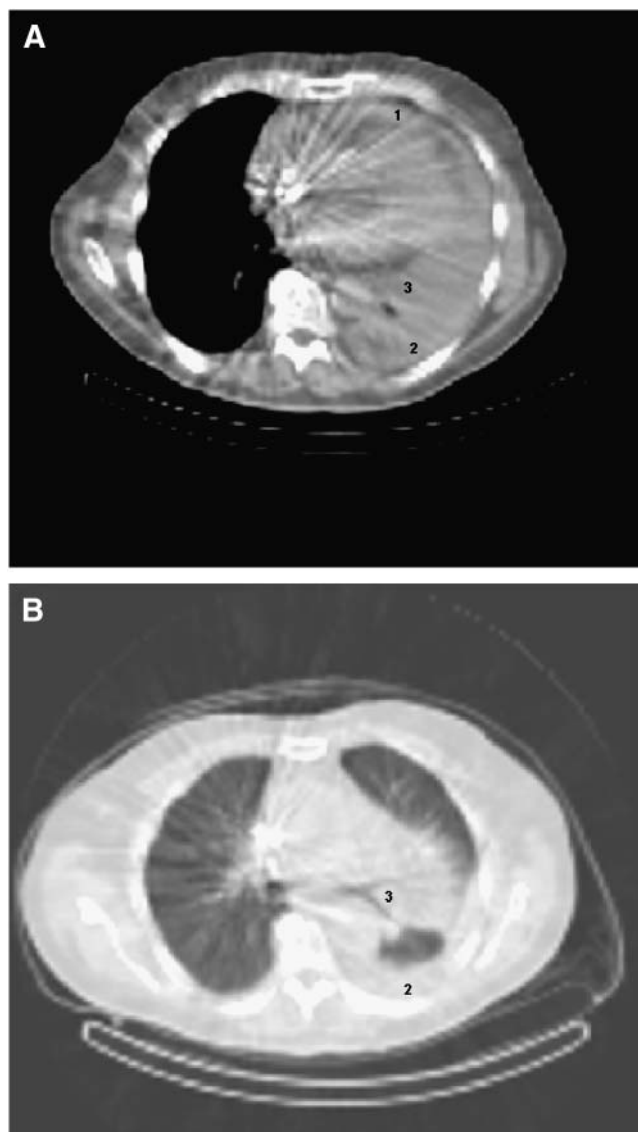


FIGURE 3. Selected transaxial CT slices of 81-y-old man with dilated ischemic cardiomyopathy and substernal chest pain, fatigue, and anorexia. Images were obtained with soft-tissue window (A) and with lung window craniad to soft-tissue window (B). Chest radiography 4 d before SPECT/CT showed small left-sided pericardial effusion. SPECT/CT shows large pericardial effusion (1), at least moderate-sized left-sided pleural effusion (2), and significant compressive atelectasis and consolidation (3). These findings were later confirmed by chest radiography and transthoracic echocardiography. Metal artifact from automatic implantable cardioverter-defibrillator is noted as well.

scout CT images, which are rich in anatomic information and allow the technologist to choose similar fields of view between the rest and stress images. Because stress images are obtained at 30–60 min after exercise, a similar lung volume was expected for both stress and rest images. In the 50 patients in whom both stress CT and rest CT were systematically reviewed, there was 1 additional finding that was apparent only on the stress study. Therefore, review of

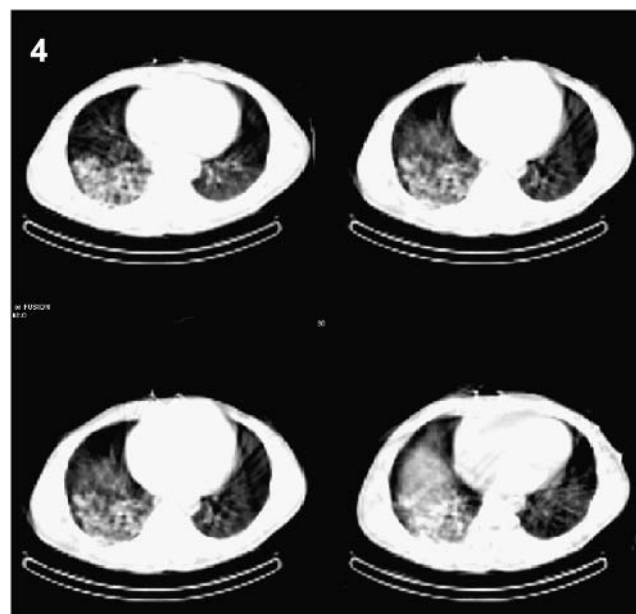


FIGURE 4. Four separate CT slices 1 cm apart of 54-y-old man with dyspnea and exertional substernal chest pain. Chest radiography 9 d before SPECT/CT showed large consolidation in right lower lobe appearing compatible with pneumonia. This finding is also seen on SPECT/CT. Follow-up chest radiography approximately 6 wk later showed resolution after antibiotic treatment.

both sets of images probably will provide a modest improvement over review of 1 set of images in a few patients if the field of view is consistent between rest and stress imaging.

The higher percentage of significant findings, compared with that found by Osman et al (6), who evaluated 250 patients with PET/CT, could be explained by their exclusion of coronary calcifications and lung nodules smaller than 7 mm. We believe that these findings were significant in our population (especially in the patients without known coronary artery disease) because the population was referred for cardiovascular (and not oncologic) evaluation. Further, the size of a lung nodule imaged at a 1-cm CT slice thickness could easily be underestimated. In 3 other studies evaluating electron-beam CT for noncardiac or noncoronary abnormalities (3–5), the detection rates for abnormalities ranged from 20% to 53% for all findings and were 4.2%, 7.8%, and 9.3% for significant or important findings. This range seems to be due to differences in the way lesions and significant lesions were defined; in the precise methods of CT acquisition, including the use of intravenous contrast material for CT angiography; and, likely, in the patient populations.

The mean age of our patient population (which consisted of patients referred from the emergency room for evaluation of a variety of types of chest pain and outpatients with known or suspected coronary artery disease) might have been less than that of centers having a larger fraction of patients with known coronary artery disease, and the rate

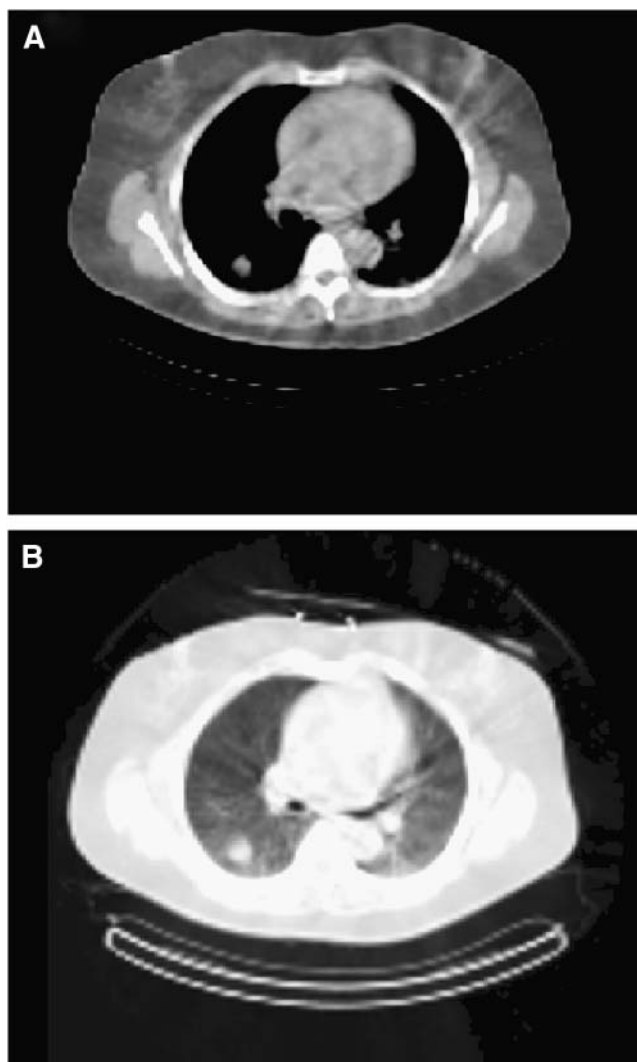


FIGURE 5. Transaxial CT slice of 58-y-old woman with atypical chest pain. Images were obtained with soft-tissue window (A) and lung window (B) and demonstrate mass in right lower lobe of lung. Five days before SPECT/CT, patient underwent diagnostic CT with intravenous contrast material to rule out pulmonary embolism. CT showed mass or masslike infiltrate in right lower lung. Follow-up was recommended but was not performed so far.

and characteristics of incidental findings may vary depending on the practice.

The importance of examining the CT scan used for attenuation correction will certainly increase as higher-quality CT scanners, with attendant improvements in CT image quality, are integrated into SPECT/CT systems.

CONCLUSION

Potentially significant abnormal findings on the non-diagnostic low-amperage-CT portion of the cardiac SPECT/CT study were detected in 10.5% (21/200 patients) of our population. We recommend that the CT used for attenuation correction be assessed for major abnormalities of the lung, vascular structures, and soft tissues. As higher-quality CT components are added to SPECT/CT systems, such a review will likely become even more important.

ACKNOWLEDGMENT

Preliminary results of this study were presented at the 2005 annual meeting of the Society of Nuclear Medicine.

REFERENCES

1. Heller GV, Links J, Bateman TM, et al. American Society of Nuclear Cardiology and Society of Nuclear Medicine joint position statement: attenuation correction of myocardial perfusion SPECT scintigraphy. *J Nucl Cardiol.* 2004;11:229–230.
2. Tonge CM, Manoharan M, Lawson RS, Shields RA, Prescott MC. Attenuation correction of myocardial SPECT studies using low resolution computed tomography images. *Nucl Med Commun.* 2005;26:231–237.
3. Horton KM, Post WS, Blumenthal RS, Fishman EK. Prevalence of significant noncardiac findings on electron-beam computed tomography coronary artery calcium screening examinations. *Circulation.* 2002;106:532–534.
4. Hunold P, Schmermund A, Seibel RM, Groenemeyer DH, Erbel R. Prevalence and clinical significance of accidental findings in electron-beam tomographic scans for coronary artery calcification. *Eur Heart J.* 2001;22:1748–1758.
5. Schragin JG, Weissfeld JL, Edmundowicz D, Strollo DC, Fuhrman CR. Noncardiac findings on coronary electron beam computed tomography scanning. *J Thorac Imaging.* 2004;19:82–86.
6. Osman MM, Cohade C, Fishman EK, Wahl RL. Clinically significant incidental findings on the unenhanced CT portion of PET/CT studies: frequency in 250 patients. *J Nucl Med.* 2005;46:1352–1355.



The Journal of
NUCLEAR MEDICINE

Clinically Significant Abnormal Findings on the "Nondiagnostic" CT Portion of Low-Amperage-CT Attenuation-Corrected Myocardial Perfusion SPECT/CT Studies

Sibyll Goetze, Harpreet K. Pannu and Richard L. Wahl

J Nucl Med. 2006;47:1312-1318.

This article and updated information are available at:
<http://jnm.snmjournals.org/content/47/8/1312>

Information about reproducing figures, tables, or other portions of this article can be found online at:
<http://jnm.snmjournals.org/site/misc/permission.xhtml>

Information about subscriptions to JNM can be found at:
<http://jnm.snmjournals.org/site/subscriptions/online.xhtml>

The Journal of Nuclear Medicine is published monthly.
SNMMI | Society of Nuclear Medicine and Molecular Imaging
1850 Samuel Morse Drive, Reston, VA 20190.
(Print ISSN: 0161-5505, Online ISSN: 2159-662X)

© Copyright 2006 SNMMI; all rights reserved.