

The Detection of Bone Metastases in Patients with High-Risk Prostate Cancer: ^{99m}Tc -MDP Planar Bone Scintigraphy, Single- and Multi-Field-of-View SPECT, ^{18}F -Fluoride PET, and ^{18}F -Fluoride PET/CT

Einat Even-Sapir, MD, PhD^{1,2}; Ur Metser, MD^{1,2}; Eyal Mishani, PhD³; Gennady Lievshitz, MD¹; Hedva Lerman, MD¹; and Ilan Leibovitch, MD^{2,4}

¹Department of Nuclear Medicine, Tel Aviv Sourasky Medical Center, Tel Aviv, Israel; ²Sackler Faculty of Medicine, Tel Aviv University, Tel Aviv, Israel; ³Cyclotron Unit, Hadassah University Hospital, Jerusalem, Israel; and ⁴Department of Urology, Meir Medical Center, Kfar Saba, Israel

The aim of this study was to compare the detection of bone metastases by ^{99m}Tc -methylene diphosphonate (^{99m}Tc -MDP) planar bone scintigraphy (BS), SPECT, ^{18}F -Fluoride PET, and ^{18}F -Fluoride PET/CT in patients with high-risk prostate cancer.

Methods: In a prospective study, BS and ^{18}F -Fluoride PET/CT were performed on the same day in 44 patients with high-risk prostate cancer. In 20 of the latter patients planar BS was followed by single field-of-view (FOV) SPECT and in 24 patients by multi-FOV SPECT of the axial skeleton. Lesions were interpreted separately on each of the 4 modalities as normal, benign, equivocal, or malignant. **Results:** In patient-based analysis, 23 patients had skeletal metastatic spread (52%) and 21 did not. Categorizing equivocal and malignant interpretation as suggestive for malignancy, the sensitivity, specificity, positive predictive value, and negative predictive value of planar BS were 70%, 57%, 64%, and 55%, respectively, of multi-FOV SPECT were 92%, 82%, 86%, and 90%, of ^{18}F -Fluoride PET were 100%, 62%, 74%, and 100%, and of ^{18}F -Fluoride PET/CT were 100% for all parameters. Using the McNemar test, ^{18}F -Fluoride PET/CT was statistically more sensitive and more specific than planar or SPECT BS ($P < 0.05$) and more specific than ^{18}F -Fluoride PET ($P < 0.001$). SPECT was statistically more sensitive and more specific than planar BS ($P < 0.05$) but was less sensitive than ^{18}F -Fluoride PET ($P < 0.05$). In lesion-based analysis, 156 lesions with increased uptake of ^{18}F -Fluoride were assessed. Based on the corresponding appearance on CT, lesions were categorized by PET/CT as benign ($n = 99$), osteoblastic metastasis ($n = 46$), or equivocal when CT was normal ($n = 11$). Of the 156 ^{18}F -Fluoride lesions, 81 lesions (52%), including 34 metastases, were overlooked with normal appearance on planar BS. SPECT identified 62% of the lesions overlooked by planar BS. ^{18}F -Fluoride PET/CT was more sensitive and more specific than BS ($P < 0.001$) and more specific than PET alone ($P <$

0.001). **Conclusion:** ^{18}F -Fluoride PET/CT is a highly sensitive and specific modality for detection of bone metastases in patients with high-risk prostate cancer. It is more specific than ^{18}F -Fluoride PET alone and more sensitive and specific than planar and SPECT BS. Detection of bone metastases is improved by SPECT compared with planar BS and by ^{18}F -Fluoride PET compared with SPECT. This added value of ^{18}F -Fluoride PET/CT may beneficially impact the clinical management of patients with high-risk prostate cancer.

Key Words: PET-CT; ^{18}F -Fluoride; SPECT; bone metastases; prostate cancer

J Nucl Med 2006; 47:287–297

Prostate cancer is the most common malignancy in men. Clinical nomograms based on prostate-specific-antigen (PSA) levels, Gleason score at biopsy, and clinical stage at presentation have been generated for pretreatment risk stratification and prediction of the probability for local recurrence or distant metastatic spread. On the basis of these parameters, patients are categorized at diagnosis as having low-risk or high-risk primary cancer (1–3). Patients with low-risk cancer are unlikely to have metastatic bone involvement. Therefore, the routine use of bone scintigraphy (BS) for primary staging in all patients with newly diagnosed prostate cancer has been discouraged (3–6). BS is mainly reserved for patients with high-risk cancer, elevated serum alkaline phosphatase levels, bone pain, or equivocal bone lesions on other imaging modalities (3,4,7,8). As the disease evolves, patients may experience biochemical progression, local recurrence, or metastatic spread. The most frequent sites of metastasis are lymph nodes and bone; 90% of patients who die of prostate cancer harbor bone metastases (2,9). The extent of osseous metastatic

Received Sep. 4, 2005; revision accepted Oct. 31, 2005.

For correspondence or reprints contact: Einat Even-Sapir, MD, PhD, Department of Nuclear Medicine, Tel Aviv Sourasky Medical Center, 6 Weizman St., Tel Aviv, 64239 Israel.

E-mail: evensap@tasmc.health.gov.il

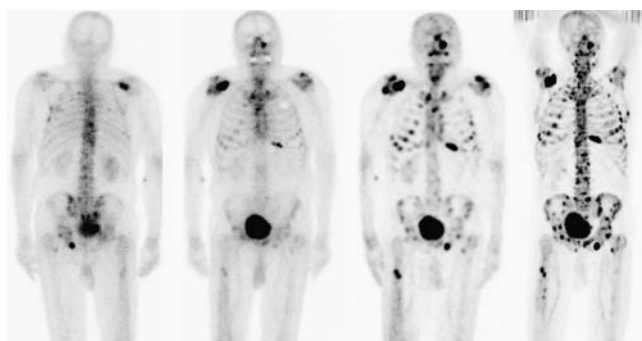


FIGURE 1. An 82-y-old patient with numerous bone metastases. From left to right: posterior and anterior planar BS, multi-FOV SPECT, and ^{18}F -Fluoride PET images. More lesions are detected on SPECT compared with planar images and on ^{18}F -Fluoride PET compared with SPECT images.

disease from prostate cancer is an independent prognostic factor (10,11).

BS has been the most widely used method for evaluating skeletal metastases of prostate cancer. However, the results of more recent reports have raised doubts whether BS is as effective for confirming metastatic bone disease as was previously perceived (12–14). The addition of SPECT to planar acquisition has been reported to improve the diagnostic accuracy of BS for detecting malignant bone involvement and to allow for a straightforward comparison with other tomography-based techniques such as CT and MRI (15–18).

Tumor detection using PET, and more recently PET/CT technology, is rapidly growing. The role of ^{18}F -FDG PET in patients with prostate cancer is still under investigation (3,18–22). Other PET tracers suggested for assessment of patients with prostate cancer include ^{11}C - or ^{18}F -labeled choline and acetate, ^{11}C -methionine, ^{18}F -fluorodihydrotestosterone, and ^{18}F -Fluoride (3). The latter was reported to be highly sensitive for detecting bone metastases in oncologic patients (13,23). Increased ^{18}F -Fluoride uptake in malignant bone lesions reflects the increase in regional blood flow and bone turnover characterizing these lesions (16,24,25). Taking advantage of both the favorable characteristics of

^{18}F -Fluoride and the better performance of PET, ^{18}F -Fluoride PET has been reported to be more sensitive for detection of metastases than $^{99\text{m}}\text{Tc}$ -methylene diphosphonate ($^{99\text{m}}\text{Tc}$ -MDP) BS (12,13,16,17,25,26). A previous study on the initial experience with ^{18}F -Fluoride PET/CT for detection of malignant bone involvement in oncologic patients with various human malignant diseases revealed encouraging results. It appeared that ^{18}F -Fluoride PET/CT may take advantage of the high sensitivity of ^{18}F -Fluoride PET, reducing the risk of false-positive rate by determining the morphology of the scintigraphic lesions on the CT data of the PET/CT study (27).

The purpose of the current study was to prospectively compare the diagnostic accuracy of planar, single, and multifield-of-view (multi-FOV) SPECT, ^{18}F -Fluoride PET, and ^{18}F -Fluoride PET/CT in detection of bone metastases in prostate cancer patients with high-risk for bone metastases.

MATERIALS AND METHODS

Patients

This is a prospective study. $^{99\text{m}}\text{Tc}$ -MDP BS and ^{18}F -Fluoride PET/CT were performed on the same day in 44 patients (mean age, 71.6 ± 8.8 y) with prostate cancer, high risk for bone metastases. Twenty-five patients were newly diagnosed, with Gleason score ≥ 8 or prostate-specific antigen (PSA) levels ≥ 20 ng/mL or nonspecific sclerotic lesions on CT (4,5). Nineteen patients were referred for evaluation of suspected recurrence or progression, later in the course of the disease. The study was approved by the local ethical committee, and all patients gave written consent to participate in this prospective study.

Planar and SPECT BS

BS was the first to be performed. Planar images of the entire skeleton were acquired 2–3 h after intravenous injection of 925 MBq (25 mCi) $^{99\text{m}}\text{Tc}$ -MDP using a dual-head camera (Discovery VH; GE Healthcare). In 20 patients, we performed single-FOV SPECT of the lower thoracic and lumbar spine region after a whole-skeleton planar acquisition. In the remaining 24 patients, SPECT of the entire axial skeleton was performed, consisting of 3- or 4-FOV SPECT. SPECT data were reconstructed on the Xeleris workstation (GE Healthcare), using a novel collimator–detector response (CDR) method (Evolution software package; GE Healthcare), which incorporates a quantitative model of CDR function of the acquisition system into an iterative reconstruction algorithm. Because collimator–detector blur is one of the main factors affecting the quality of reconstructed SPECT images, the resulting SPECT data obtained by the CDR method have improved resolution and signal-to-noise characteristics (28). Using this algorithm, a good-quality SPECT view may be acquired within 8 min of acquisition and SPECT of the axial skeleton within 24–32 min (Fig. 1).

^{18}F -Fluoride PET/CT Study

^{18}F -Fluoride preparation was previously reported in detail (27). No special preparations were needed before the ^{18}F -Fluoride PET/CT study. The PET/CT study was performed in the afternoon, on the same day as BS. Scanning was performed 60–90 min after intravenous administration of 296–444 MBq (8–12 mCi) ^{18}F -Fluoride using a Discovery LS PET/CT system (GE Healthcare).

TABLE 1

Comparison of Detection of Bone Metastases by $^{99\text{m}}\text{Tc}$ -MDP BS and by ^{18}F -Fluoride PET/CT

^{18}F -Fluoride PET/CT	$^{99\text{m}}\text{Tc}$ -MDP BS			
	Normal	Benign	Equivocal	Malignant
Normal	2	0	0	0
Benign	0	12	4	3
Equivocal	0	2	1	0
Malignant	0	3	8	9

$^{99\text{m}}\text{Tc}$ -MDP BS includes planar and a single-FOV SPECT in 20 patients and planar and multi-FOV SPECT in 24 patients.

TABLE 2
Assessment of Skeletal Metastatic Spread by Planar ^{99m}Tc -MDP BS, Planar and SPECT BS, ^{18}F -Fluoride PET, and ^{18}F -Fluoride PET/CT: Patient-Based Analysis in 44 Patients with High-Risk Prostate Cancer

Modality	Final diagnosis									
	Spread of metastases ($n = 23$)			No metastases ($n = 11$)			Interpretation*			
	M	E	B/N	M	E	B/N	Sensitivity (%)	Specificity (%)	PPV (%)	NPV (%)
Planar BS	8	5	10	1	8	12	57 (35)	57 (95)	59 (89)	55 (44)
Planar + SPECT [†]	9	9	5	3	4	14	78 (39)	67 (86)	72 (75)	74 (31)
^{18}F -Fluoride PET	11	12	0	1	7	13	100 (48)	62 (95)	74 (92)	100 (63)
^{18}F -Fluoride PET/CT	20	3	0	0	0	21	100 (87)	100 (100)	100 (100)	100 (87)

*Analysis considering equivocal reading as positive for malignancy. In parentheses, analysis considering equivocal results as negative for malignancy.

[†] ^{99m}Tc -MDP BS including planar and a single-FOV SPECT in 20 patients and planar and multi-FOV SPECT in 24 patients.

M = malignant; E = equivocal; B/N = benign or normal.

Low-dose CT acquisition was performed first with 140 kV, 80 mA, 0.8 s per CT rotation, a pitch of 6, and a table speed of 22.5 mm/s, without any specific breath-holding instructions. A PET emission scan was performed immediately after acquisition of the CT, without changing the patient's positioning. From 5 to 9 bed positions were performed with an acquisition time of 3 min for each, imaging the skeleton from skull to mid thigh. PET images were reconstructed using an ordered-subsets expectation maximization algorithm. CT data were used for attenuation correction. Studies were interpreted on a Xeleris workstation.

Image Interpretation and Analysis of Findings

Planar, SPECT, ^{18}F -Fluoride PET, and ^{18}F -Fluoride PET/CT images were interpreted blindly and separately. The interpretation of ^{99m}Tc -MDP BS was made as a consensus reading of 2 nuclear medicine physicians and that of the PET/CT as a consensus reading of a nuclear medicine physician and a radiologist.

Each site of abnormally increased uptake of ^{99m}Tc -MDP or ^{18}F -Fluoride was recorded and categorized as normal (no increased uptake), benign, malignant, or equivocal. Scintigraphic lesions were categorized as benign when they appeared as hot

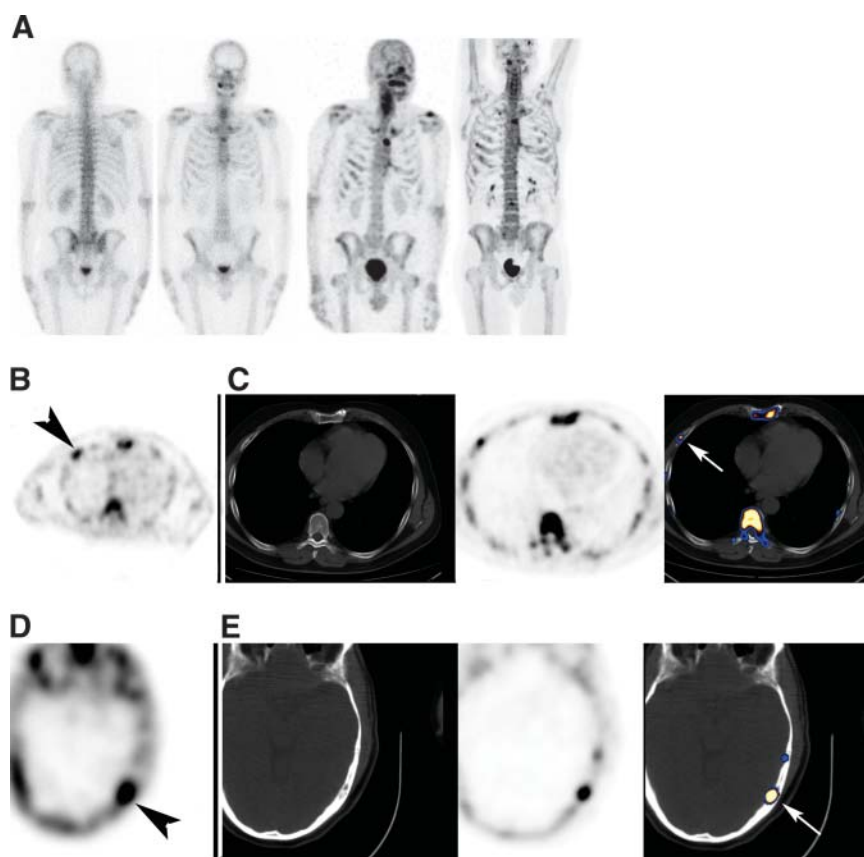


FIGURE 2. Early metastatic spread missed on planar BS in 57-year-old patient with prostate cancer at diagnosis. (A) From left to right: posterior and anterior planar BS, multi-FOV SPECT, and ^{18}F -Fluoride PET images. Planar BS was interpreted as negative for bone metastases. (B and C) Osteoblastic rib metastasis on SPECT (B) and on ^{18}F -Fluoride PET/CT (C). From left to right: SPECT (metastasis marked by arrowhead), CT, ^{18}F -Fluoride PET, and fused ^{18}F -Fluoride PET/CT (metastasis marked by arrow). (D and E) Osteoblastic metastasis in skull on SPECT (D) and on ^{18}F -Fluoride PET/CT (E). From left to right: SPECT (metastasis marked by arrowhead), CT, ^{18}F -Fluoride PET, and fused ^{18}F -Fluoride PET/CT (metastasis marked by arrow).

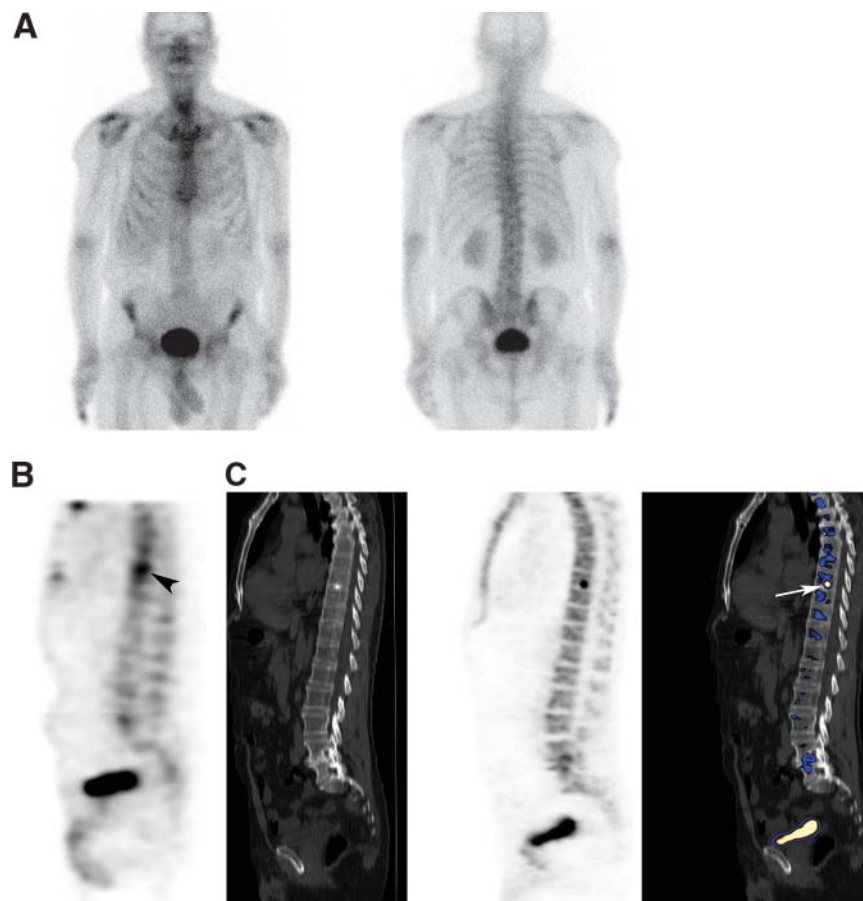


FIGURE 3. A single metastasis missed on planar BS in 63-y-old patient with prostate cancer at diagnosis. (A) Anterior and posterior planar BS, which was interpreted as negative for bone metastases. (B and C) Osteoblastic metastasis in D8 vertebra identified on SPECT (B) and on ^{18}F -Fluoride PET/CT (C). From left to right: SPECT (metastasis marked by arrowhead), CT, ^{18}F -Fluoride PET, and fused ^{18}F -Fluoride PET/CT (metastasis marked by arrow).

osteophytes or when they were located around joints. Vertebral lesions were considered malignant when they involved the posterior aspect of the vertebral body and pedicle or when they involved the vertebra extensively (15,29). Rib lesions were categorized as malignant when they presented as elongated uptake, categorized as benign (fractures) when vertically they involved several ribs, and as equivocal otherwise. Based on the corresponding morphology on the CT data of PET/CT, lesions were diagnosed as benign when degenerative changes, fractures, or other benign bone lesions such as bone cysts were detected at the corresponding location on CT. Lesions were diagnosed as metastases if they were associated with characteristic osteoblastic metastases on CT. If neither blastic nor benign abnormalities were found on CT at the corresponding location with the PET abnormality, the PET/CT lesion was categorized as equivocal. Patients were monitored for at least 6 mo (mean, 10 ± 3 mo; range, 6–15 mo), and their medical records were reviewed with an attempt to get a final diagnosis of equivocal lesions.

Statistical Analysis

Patient-based and lesion-based analyses were performed. For each of the modalities the sensitivity, specificity, positive predictive value (PPV), and negative predictive value (NPV) were determined for the differentiation of malignant bone involvement from benign. Comparison of the detection of bone metastases by planar BS, SPECT, ^{18}F -Fluoride PET, and ^{18}F -Fluoride PET/CT was performed using the McNemar test with $P < 0.05$ being statistically significant.

RESULTS

Patient-Based Analysis

Of the 44 study patients, 23 had bone metastases (52%) based on definitive PET/CT findings, biopsy, and imaging follow-up. PET/CT clearly identified malignant bone involvement, detecting skeletal lesions with increased uptake of ^{18}F -Fluoride on the PET data and corresponding osteoblastic metastases on the CT data in 20 of the 23 patients. In the remaining 3 patients, PET/CT was categorized as equivocal because one or two ^{18}F -Fluoride lesions were detected with normal CT. MRI was also not definitive. The diagnosis of osseous metastases was established by a rib biopsy in 1 patient and by progression of osseous metastases by clinical and imaging follow-up in 2 other patients. In spite of the fact that these patients with equivocal ^{18}F -Fluoride PET/CT were found to have metastases, for the purpose of assessing the accuracy of imaging techniques in detection of bone metastases at a given time point, we analyzed the results twice: categorizing the equivocal reading as suggestive for malignancy and, again, categorizing the equivocal reading as benign.

Nineteen patients had benign bone lesions on scintigraphic imaging but no metastases. The benign nature of the lesions was determined by detection of benign findings in the corresponding location on the CT part of PET/CT. In

TABLE 3
Detection of Bone Metastases in 24 Study Patients Who Had Multi-FOV Axial-Body SPECT

Modality	Final diagnosis									
	Spread of metastases (<i>n</i> = 13)			No metastases (<i>n</i> = 11)			Interpretation*			
	M	E	B/N	M	E	B/N	Sensitivity (%)	Specificity (%)	PPV (%)	NPV (%)
Planar BS	6	3	4	0	4	7	69 (46)	64 (100)	69 (100)	64 (61)
SPECT†	6	6	1	0	2	9	92 (46)	82 (100)	86 (100)	90 (61)
¹⁸ F-Fluoride PET	6	7	0	0	2	9	100 (46)	82 (100)	87 (100)	100 (61)
¹⁸ F-Fluoride PET/CT	11	2	0	0	0	11	100 (85)	100 (100)	100 (100)	100 (85)

*Analysis considering equivocal results as positive for malignancy. In parentheses, analysis considering equivocal results as negative for malignancy.

†Multi-FOV SPECT composed of 3 or 4 FOVs covering the axial skeleton.

M = malignant; E = equivocal; B/N = benign or normal.

2 additional patients scintigraphic studies were normal. Follow-up of patients included monitoring of PSA and alkaline phosphatase levels and imaging follow-up by BS and diagnostic CT. All 21 patients who were negative for bone metastases on ¹⁸F-Fluoride PET/CT had no clinical or imaging evidence of metastatic spread for at least the 6-mo follow-up period. Table 1 summarizes the comparison in detection of bone metastases by BS (planar and single-FOV or multi-FOV SPECT) and ¹⁸F-Fluoride PET/CT. In 20 of the 44 study patients (45%), the definition of malignant bone involvement by PET/CT and by ^{99m}Tc-MDP BS did not correlate. In 7 patients with benign PET/CT, BS was interpreted as equivocal or malignant, and in 13 patients with metastatic spread on PET/CT, BS was interpreted as benign or equivocal. Table 2 summarizes the sensitivity, specificity, PPV, and NPV of planar BS, combined planar and SPECT BS (a single-FOV SPECT in 20 patients and multi-FOV SPECT in 24), ¹⁸F-Fluoride PET, and ¹⁸F-Fluoride PET/CT in the 44 study patients. Using the McNemar comparison test, sensitivity of ¹⁸F-Fluoride PET/CT was significantly better than that of BS when equivocal reading was categorized as malignant or when categorized as benign ($P < 0.05$ and $P < 0.001$, respectively). Specificity of ¹⁸F-Fluoride PET/CT was significantly better when

equivocal reading was categorized as malignant ($P < 0.05$). It was higher (100% vs. 82%) but not statistically significant when equivocal reading was categorized as benign. Sensitivity of ¹⁸F-Fluoride PET and ¹⁸F-Fluoride PET/CT was the same. Specificity of PET/CT was significantly higher compared with PET alone ($P < 0.001$).

Twenty-two of the study patients, 13 patients with bone metastases and 11 without, had axial SPECT composed of 3 or 4 FOVs. In this subgroup of patients it was possible to assess the impact of tomography comparing the detection of metastases by SPECT with that of planar BS and to assess the impact of the different radiopharmaceutical (^{99m}Tc-MDP vs. ¹⁸F-Fluoride) and the different technology (SPECT vs. PET) comparing the detection of metastases by SPECT with that of ¹⁸F-Fluoride (Figs. 1–3). Table 3 summarizes this comparison. SPECT was statistically more sensitive ($P < 0.05$) and more specific ($P < 0.05$) than planar BS for detection of bone metastases. ¹⁸F-Fluoride PET was significantly more sensitive than SPECT BS in detecting metastases ($P < 0.05$). Specificity of ¹⁸F-Fluoride PET and of SPECT BS was identical.

Lesion-Based Analysis

One hundred fifty-six sites of increased ¹⁸F-Fluoride uptake were assessed. Three of the patients with positive PET/CT had extensive spread with countless metastases and, therefore, could not be included in a lesion-based analysis (Fig. 1).

Location and final diagnosis of 156 lesions with increased ¹⁸F-Fluoride uptake are summarized in Table 4. A benign abnormality in a corresponding location with the scintigraphic lesions was identified on the CT part of the PET/CT study for 99 lesions (64% of lesions). Forty-six lesions (29% of lesions) showed characteristic osteoblastic metastases and 11 lesions (7% of lesions) were equivocal because of normal CT. Of the 11 equivocal PET/CT lesions, 1 lesion was a biopsy-proven metastasis and 4 lesions appeared as clear osteoblastic metastasis on follow-up CT. The remaining 6 equivocal lesions were not further assessed

TABLE 4
Location and Final Diagnosis of 156 Skeletal Lesions with Increased ¹⁸F-Fluoride Uptake

Body region	No. of lesions	Diagnosis		
		Malignant	Equivocal	Benign
Skull	8	3	4	1
Cervical spine	14	2	1	11
Upper thoracic spine	12	3	0	9
Lower thoracic spine	22	6	0	16
Lumbar spine	40	5	0	35
Pelvis	27	14	1	12
Rib cage	25	12	4	9
Long bones	8	1	1	6

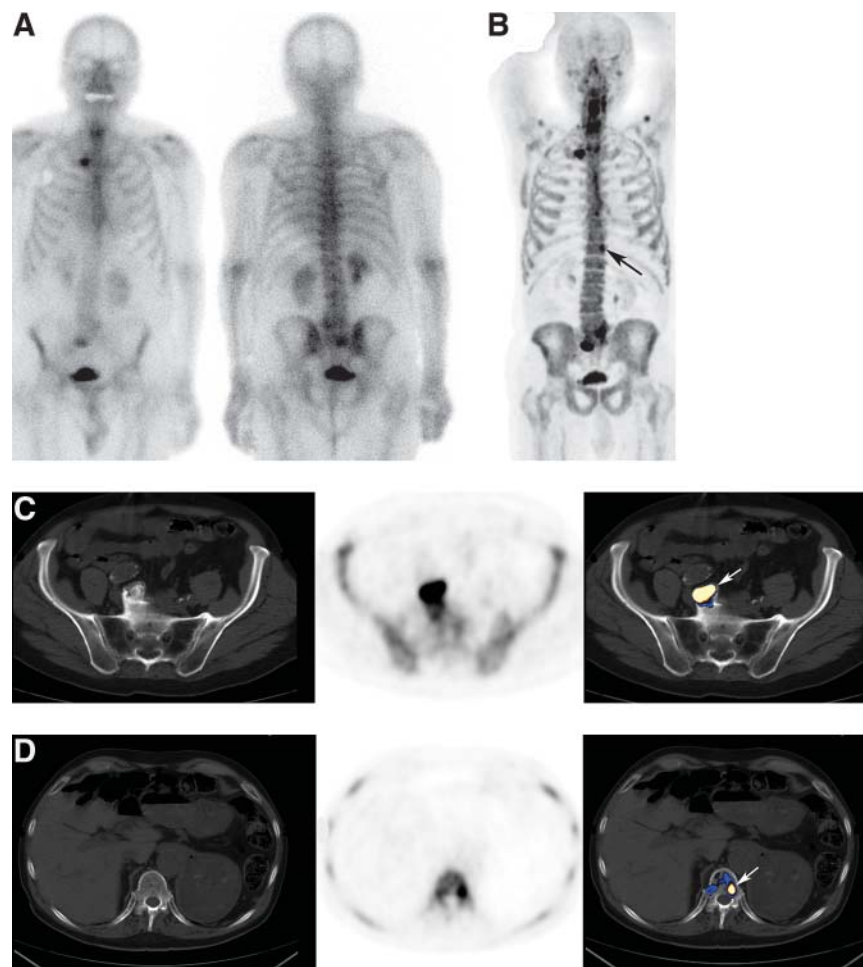


FIGURE 4. A single metastasis overlooked by planar images in 81-y-old patient with suspected recurrence because of rising PSA levels. (A) On planar bone images, increased uptake is detected in sacrum and right sternoclavicular joint. Degenerative findings are based on correlation with CT. (B) ^{18}F -Fluoride PET maximum-intensity-projection image detecting additional site of uptake in left aspect of D12 (arrow). (C) Lesion identified by planar images is an osteophyte (marked by arrow). From left to right: CT, ^{18}F -Fluoride PET, and fused ^{18}F -Fluoride PET/CT. (D) Metastasis (marked by arrow) overlooked by planar images. From left to right: CT, ^{18}F -Fluoride PET, and fused ^{18}F -Fluoride PET/CT.

as the patients had clear evidence of bone metastases in other sites. The 5 proven metastases, which presented as increased ^{18}F -Fluoride uptake and normal CT, led us to categorize all 11 lesions showing this pattern as metastases in the analysis.

Of the 156 lesions with increased ^{18}F -Fluoride uptake, abnormal uptake of $^{99\text{m}}\text{Tc}$ -MDP was reported on planar BS in only 75 of the sites (48%). The remaining 81 ^{18}F -Fluoride sites showed no increased $^{99\text{m}}\text{Tc}$ -MDP and were interpreted as normal on BS, including 34 metastases and 47 benign lesions (skull, 6; cervical spine, 8; upper thoracic spine, 9; lower thoracic spine, 11; lumbar spine, 19; pelvis, 12; ribs, 11; long bones, 5) (Figs. 4–6). Fifty-two of the 81 sites missed by planar BS were included in a SPECT FOV, which identified abnormalities in 32 (62%) of these lesions and missed 20. SPECT was available for 24 of the 34 metastases overlooked because of their normal appearance on planar images, identifying abnormal uptake of $^{99\text{m}}\text{Tc}$ -MDP in 14 and missing 10. Of the 47 benign lesions, SPECT was available in 28, identifying abnormal uptake of $^{99\text{m}}\text{Tc}$ -MDP in 18 and missing 10.

Table 5 summarizes the sensitivity, specificity, PPV, and NPV of BS, ^{18}F -Fluoride PET, and ^{18}F -Fluoride PET/CT as assessed for 156 bone lesions, once by categorizing equiv-

ocal findings as suggestive for malignancy and again by categorizing equivocal reading as benign.

Using the McNemar comparison test, sensitivity of ^{18}F -Fluoride PET/CT was significantly better than that of BS when equivocal reading was categorized as malignant or when categorized as benign ($P < 0.001$ and $P < 0.001$, respectively). Specificity of ^{18}F -Fluoride PET/CT was significantly better when equivocal reading was categorized as malignant ($P < 0.001$).

Sensitivity of ^{18}F -Fluoride PET and ^{18}F -Fluoride PET/CT was identical when equivocal reading was categorized as suggestive for malignancy. However, specificity of PET/CT was significantly higher compared with PET alone ($P < 0.001$). Categorizing equivocal reading as benign, sensitivity of PET/CT was significantly higher than that of PET alone ($P < 0.001$).

One-hundred twelve of the 156 lesions comprised of 41 metastases and 71 benign lesions were included in a SPECT FOV. Table 6 summarizes the comparison of metastases detection in the latter 112 lesions, by planar BS, SPECT BS, ^{18}F -Fluoride PET, and ^{18}F -Fluoride PET/CT. Categorizing equivocal reading as suggestive for malignancy, SPECT had a significantly higher sensitivity than planar BS ($P < 0.001$) and a similar specificity. ^{18}F -Fluoride PET

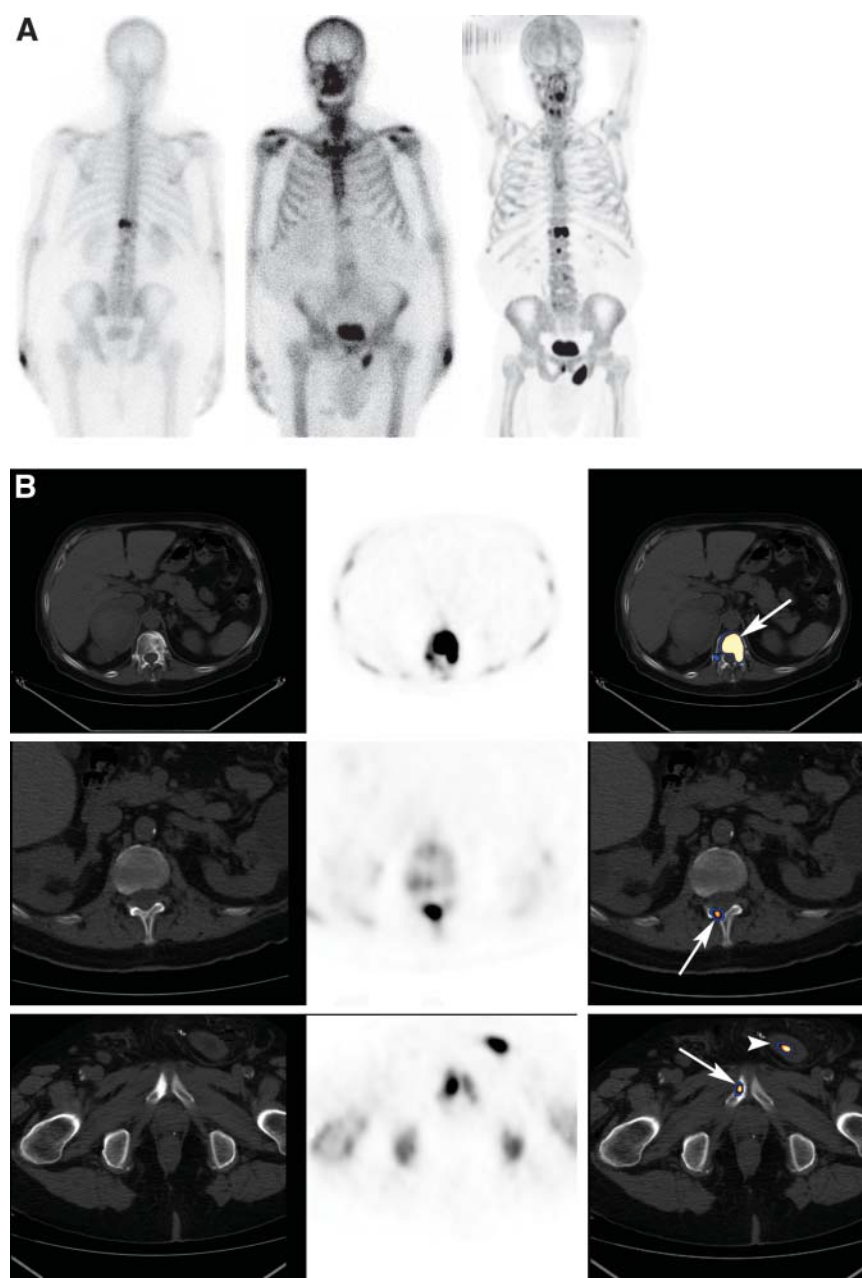


FIGURE 5. Bone metastases overlooked by planar images in 72-y-old patient with suspected recurrence because of rising PSA levels. (A) From left to right: posterior and anterior planar BS and ^{18}F -Fluoride PET maximum-intensity-projection image. (B) From left to right on each row: CT, ^{18}F -Fluoride PET, and fused ^{18}F -Fluoride PET/CT. Top row illustrates a metastatic thoracic vertebra, which was also detected on planar BS (arrow). Middle row illustrates a metastasis in right posterior elements of L1, overlooked by planar BS (arrow). Bottom row illustrates a metastasis in right pubis, barely seen on planar scintigraphy (arrow). Increased site of uptake marked on PET/CT image (arrowhead) is urinary bladder located within an inguinal hernia.

had a significantly higher sensitivity compared with SPECT ($P < 0.01$) and a similar specificity. ^{18}F -Fluoride PET/CT was significantly more specific than ^{18}F -Fluoride PET alone ($P < 0.01$).

Table 7 is a summary of detection of bone metastases by planar BS, multi-FOV SPECT, and ^{18}F -Fluoride PET/CT in 23 study patients with malignant bone involvement.

Correlation Between ^{18}F -Fluoride PET/CT Findings and Patient Management

Among the 25 patients with newly diagnosed disease, ^{18}F -Fluoride PET/CT accurately identified or suggested the presence of metastatic bone spread in 11 and excluded bone metastases in 14 patients, 6 of whom had nonspecific sclero-

rotic bone changes on CT with no corresponding increased uptake of ^{18}F -Fluoride, probably bone islands. In 5 of the 11 patients with newly diagnosed disease, previously unknown bone metastases were identified on scintigraphic assessment and patient management was altered to systemic therapy with androgen withdrawal and bisphosphonate therapy, withholding local therapy approach with external beam radiotherapy. In 3 of the latter patients, early malignant bone involvement was identified by ^{18}F -Fluoride PET/CT but was overlooked by planar BS (scintigraphic data of 2 of the latter patients are illustrated in Figs. 2 and 3). In the remaining 6 newly diagnosed patients with bone metastases, ^{18}F -Fluoride PET/CT findings did not modify the treatment approach as the patients had known osseous or

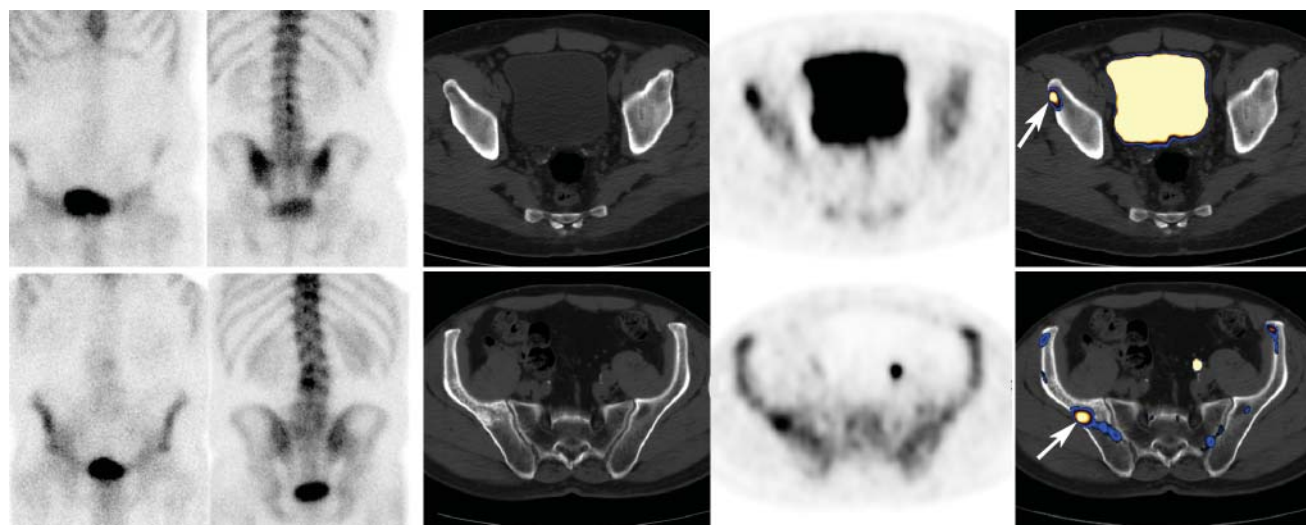


FIGURE 6. Two examples of bone metastases in pelvic bone, missed by planar images and seen by ^{18}F -Fluoride PET/CT. Each row is separate and includes examples from left to right: CT, ^{18}F -Fluoride PET, and fused ^{18}F -Fluoride PET/CT. Metastases are marked by arrows.

soft-tissue metastases based on other assessment. Local therapy was given only to newly diagnosed patients in whom metastatic spread was excluded. Among the 19 patients with suspected recurrence or disease progression, ^{18}F -Fluoride PET/CT identified bone metastases in 12 patients and excluded bone metastases as the cause for rising PSA levels in 7 patients. The latter patients maintained their previous therapy. On the basis of detection of bone metastases by ^{18}F -Fluoride PET/CT and not by planar BS, 2 patients were referred for chemotherapy, and in 2 other patients androgen withdrawal therapy was modified (Fig. 4).

DISCUSSION

Early detection or exclusion of bone metastases is of a high clinical importance in management of patients with high-risk prostate cancer. Newly diagnosed patients with

localized disease and no metastases may benefit from radical localized curative treatment, in contrast with patients who bear metastases, in whom early initiation of androgen withdrawal and bisphosphonate therapy and withholding of unnecessary radical therapy such as radiotherapy is the appropriate treatment approach. Later in the course of the disease, the detection of bone metastases in patients with advanced hormone-refractory disease may indicate the need to modify therapy or treat with chemotherapy. The primary goal of scintigraphic assessment in patients with high-risk prostate cancer is therefore to detect, as early as possible, the presence of bone metastases. Exclusion of bone metastases by negative scintigraphy is another goal, particularly when nonspecific equivocal bony lesions have been detected on CT. Despite adverse clinical parameters, exclusion of metastases allows offering radiotherapy or radical prostatectomy with a curative intent to high-risk

TABLE 5
Assessment of Skeletal Metastatic Spread by Planar $^{99\text{m}}\text{Tc}$ -MDP BS, Planar and SPECT BS, ^{18}F -Fluoride PET, and ^{18}F -Fluoride PET/CT: Lesion-Based Analysis of 156 Lesions

Modality	Final diagnosis									
	Metastases (<i>n</i> = 57)			No metastases (<i>n</i> = 99)			Interpretation*			
	M	E	B/N	M	E	B/N	Sensitivity (%)	Specificity (%)	PPV (%)	NPV (%)
Planar BS	13	9	35	2	15	82	39 (23)	83 (98)	56 (87)	70 (69)
Planar and SPECT†	12	23	22	3	10	86	61 (21)	87 (97)	73 (80)	80 (81)
^{18}F -Fluoride PET	19	38	0	3	18	78	100 (33)	79 (96)	73 (86)	100 (100)
^{18}F -Fluoride PET/CT	46	11	0	0	0	99	100 (81)	100 (100)	100 (100)	100 (90)

*In results analysis, normal and benign interpretation was considered nonmalignant. Equivocal and malignant interpretation was considered malignant. In parentheses, results analysis with normal, benign, and equivocal interpretation being considered nonmalignant.

†Planar and SPECT interpretation of 112 lesions and planar interpretation alone for the remaining 44 lesions, which were not included in SPECT FOV.

M = malignant; E = equivocal; B/N = benign or normal.

TABLE 6
Lesion-Based Analysis of 112 Lesions with Increased ^{18}F -Fluoride for Which SPECT Was Available

Modality	Final diagnosis									
	Metastases (<i>n</i> = 41)			No metastases (<i>n</i> = 71)			Interpretation*			
	M	E	B/N	M	E	B/N	Sensitivity (%)	Specificity (%)	PPV (%)	NPV (%)
Planar BS	10	6	25	2	13	56	39 (24)	79 (97)	52 (83)	64 (69)
SPECT	10	19	12	3	8	60	71 (24)	85 (96)	73 (77)	83 (69)
¹⁸ F-Fluoride PET	14	27	0	2	8	61	100 (34)	86 (96)	80 (88)	100 (72)
¹⁸ F-Fluoride PET/CT	32	9	0	0	0	71	100 (78)	100 (100)	100 (100)	100 (89)

*In results analysis, normal and benign interpretation was considered nonmalignant. Equivocal and malignant interpretation was considered malignant. In parentheses, results analysis with normal, benign, and equivocal interpretation being considered nonmalignant. M = malignant; E = equivocal; B/N = benign or normal.

patients who otherwise would be managed in a palliative approach (30).

In the current prospective study on 44 patients with high-risk prostate cancer, we compared the detection of bone metastases by $^{99\text{m}}\text{Tc}$ -MDP planar BS, $^{99\text{m}}\text{Tc}$ -MDP SPECT, ^{18}F -Fluoride PET, and ^{18}F -Fluoride PET/CT. Bone metastases were found in 52% of the study patients, at least 10

times the prevalence of bone metastases among low-risk patients with prostate cancer (4,5).

^{18}F -Fluoride PET has been found to be more sensitive than $^{99\text{m}}\text{Tc}$ -MDP BS, particularly when compared with planar images but also when compared with SPECT. ^{18}F -Fluoride, a bone-seeking positron-emitting agent, is characterized by a 2-fold higher bone uptake than $^{99\text{m}}\text{Tc}$ -MDP,

TABLE 7
Detection of Bone Metastases on Planar BS and on Multi-FOV SPECT in 23 Patients with Metastatic Bone Involvement on ^{18}F -Fluoride PET/CT: Patient-Based and Lesion-Based Analysis*

Patient no.	^{18}F -Fluoride PET/CT (no. of metastases)	Planar BS images		Multi-FOV SPECT images	
		Final diagnosis [†]	No. of metastases	Final diagnosis	No. of metastases
1	Numerous	True positive	Numerous	True positive	Numerous
2	Numerous	True positive	Numerous	True positive	Numerous
3	Numerous	True positive	Numerous	True-positive	Numerous
4	5	True positive	4	True positive	5
5	6	True positive	4	True positive	4
6	3	True positive	1	True positive	2
7	4	True positive	2	True positive	3
8	4	True positive	1	True positive	2
9	5	True positive	3	NA [‡]	
10	4	True positive	3	NA [‡]	
11	3	True positive	2	NA [‡]	
12	2	True positive	2	NA [‡]	
13	2	True positive	1	NA [‡]	
14	2	False negative		True positive	2
15	4	False negative		True positive	4
16	2	False negative		True positive	2
17	1	False negative		True positive	1
18	1	False negative		False negative	
19	3	False negative		NA [‡]	
20	3	False negative		NA [‡]	
21	1	False negative		NA [‡]	
22	1	False negative		NA [‡]	
23	1	False negative		NA [‡]	

*Equivocal findings were considered suggestive of a bone metastasis on the 3 modalities.

[†]Final diagnosis regarding the presence of bone metastases.

[‡]Multi-FOV SPECT was not available in these patients.

a faster blood clearance, and a better target-to-background ratio (6,16,25,31). In the current study the better sensitivity of ^{18}F -Fluoride PET was reflected by the detection of metastases, which were overlooked by $^{99\text{m}}\text{Tc}$ -MDP BS. In extreme cases, patient management was altered on the basis of identification of malignant bone involvement solely by ^{18}F -Fluoride PET.

^{18}F -Fluoride is, however, not tumor specific and, therefore, prone to a high false-positive rate (6,31). Differentiation between benign and malignant lesions is obtained by further validation by CT or MRI. As was previously reported, correlation of ^{18}F -Fluoride lesions with CT can be easily made using integrated PET/CT systems with higher specificity of ^{18}F -Fluoride PET/CT compared with ^{18}F -Fluoride PET (27). In the current study, 46 of 57 metastases identified by increased ^{18}F -Fluoride uptake were associated with corresponding osteoblastic changes on the CT part of the study. The remaining 11 metastases presented with increased ^{18}F -Fluoride uptake and normal CT. It should be borne in mind that when assessing tumor detection by a new imaging modality, some suggestive tumor sites cannot be fully characterized, and the more sensitive technique will provide its own standard of criteria. That was the case with proven metastases presenting with increased uptake of ^{18}F -Fluoride and normal CT, reflecting the higher sensitivity of the former (17). The detection of fractures, cysts, or degenerative changes on CT, in corresponding location with increased ^{18}F -Fluoride uptake, has determined the benign nature of other scintigraphic lesions. Nonspecific equivocal sclerotic CT lesions with no corresponding increased ^{18}F -Fluoride uptake reflected benign lesions such as bone islands. The morphologic characterization of scintigraphic lesions by PET/CT resulted in a lower percentage of equivocal interpretations compared with interpretation of $^{99\text{m}}\text{Tc}$ -MDP BS or ^{18}F -Fluoride PET alone, both on patient-based analysis and on lesion-based analysis.

Schirrmeyer et al. reported superiority of ^{18}F -Fluoride PET for detection bone metastases over BS in patients with various human malignancies, including prostate cancer (12,13,17). It was noted that ^{18}F -Fluoride PET was of a higher value when compared with planar BS than when compared with bone SPECT, reflecting the potential benefit of tomographic techniques. A single SPECT view, however, provides tomographic data of only limited skeletal region, whereas several SPECT views with prolonged acquisition protocol can be performed in only a small number of patients (13,32). In 24 of the study patients we used a novel multi-FOV SPECT technology with 3 or 4 SPECT views of the axial skeleton being acquired within 24–32 min (28). The sensitivity of BS on a patient-based analysis improved from 69% for planar images to 92% for multi-FOV SPECT. Similarly, on a lesion-based analysis, sensitivity improved from 39% to 71%. In 13 patients with bone metastases, multi-FOV SPECT was available for correlation, identifying metastases in 12. Planar images were positive in only 8 of the latter 13 patients. Improved lesion detection by

SPECT was previously reported primarily for lesions located at the lower thoracic and lumbar vertebral column (14,15,29,32,33). In the current study, the performance of SPECT on the entire axial skeleton resulted in detection of metastases in other locations, including the skull, upper vertebral column, rib cage, pelvis, and long bones (Figs. 2–6).

In spite of the high sensitivity and specificity found for ^{18}F -Fluoride PET/CT, the latter is the most expensive and less available modality among the techniques assessed in the current study. For one to be able to draw a conclusion whether ^{18}F -Fluoride PET/CT should be introduced as a routine imaging approach of metastatic bone survey in cancer patients who are at high-risk for bone metastases, a meticulous cost-effective analysis is required. This was not done in the current study, which is a major limitation. However, because the availability of PET and PET/CT systems, of high-quality SPECT algorithms, and the cost of radiopharmaceuticals may vary in different sites, such an analysis might not be applicable universally. Thus, until precise conclusive indications will be widely available, it might be valuable to exploit the high sensitivity and specificity of ^{18}F -Fluoride PET/CT in selected cases in which the presence of bone metastasis cannot be definitely confirmed or equally excluded by other imaging modalities.

CONCLUSION

^{18}F -Fluoride PET/CT is a highly sensitive and specific modality for detection of bone metastases in patients with high-risk prostate cancer. It is more specific than ^{18}F -Fluoride PET alone and more sensitive and specific than planar and SPECT BS. Detection of bone metastases is improved by SPECT compared with planar BS and by ^{18}F -Fluoride PET compared with SPECT. This added value of ^{18}F -Fluoride PET/CT may beneficially impact the clinical management of patients with high-risk prostate cancer.

ACKNOWLEDGMENT

The study was supported, in part, by a grant of the Israeli Cancer Research. The authors thank Avishay Sella, MD, for referring patients and reviewing the manuscript.

REFERENCES

1. Hricak H, Schoder H, Pucar D, et al. Advances in imaging in the postoperative patient with a rising prostate-specific antigen level. *Semin Oncol*. 2003;30:616–634.
2. Han M, Partin AW, Zahurak M, et al. Biochemical (prostate specific antigen) recurrence probability following radical prostatectomy for clinically localized prostate cancer. *J Urol*. 2003;169:517–523.
3. Schoder H, Larson SM. Positron emission tomography for prostate, bladder, and renal cancer. *Semin Nucl Med*. 2004;34:274–292.
4. Abuzallouf S, Dayes I, Lukka H. Baseline staging of newly diagnosed prostate cancer: a summary of the literature. *J Urol*. 2004;171:2122–2127.
5. Lee N, Fawaaz R, Olsson CA, et al. Which patients with newly diagnosed prostate cancer need a radionuclide bone scan? An analysis based on 631 patients. *Int J Rad Oncol Biol Phys*. 2000;48:1443–1446.

6. Fogelman I, Cook G, Israel O, et al. Positron emission tomography and bone metastases. *Semin Nucl Med*. 2005;35:135–142.
7. Wymenga LFA, Boomsma JHB, Groenier K, et al. Routine bone scans in patients with prostate related to serum prostate-specific antigen and alkaline phosphatase. *BJU Int*. 2001;88:226–230.
8. Yap VK, Choo R, Klotz L, et al. Are serial bone scans useful for the follow-up of clinically localized, low to intermediate grade prostate cancer managed with watchful observation alone? *BJU Int*. 2003;91:613–617.
9. Gomez P, Manoharan M, Kim SS, et al. Radionuclide bone scintigraphy in patients with biochemical recurrence after radical prostatectomy: when is it indicated? *BJU Int*. 2004;94:299–302.
10. Sabbatini P, Larson SM, Kremer A. Prognostic significance of extent of disease in bone in patients with androgen-independent prostate cancer. *J Clin Oncol*. 1999;17:948–957.
11. Rigaud J, Tiguert R, Le Normand L. Prognostic value of bone scan in patients with metastatic prostate cancer treated initially with androgen deprivation therapy. *J Urol*. 2002;168:1423–1426.
12. Schirrmeyer H, Guhlmann A, Elsner K, et al. Sensitivity in detecting osseous lesions depends on anatomic localization: planar bone scintigraphy versus ^{18}F PET. *J Nucl Med*. 1999;40:1623–1629.
13. Schirrmeyer H, Glatting G, Hetzel J, et al. Prospective evaluation of clinical value of planar bone scan, SPECT and ^{18}F -labeled NaF PET in newly diagnosed lung cancer. *J Nucl Med*. 2001;42:1800–1804.
14. Jacobson AF, Fogelman I. Bone scanning in clinical oncology: does it have a future? *Eur J Nucl Med*. 1998;25:1219–1223.
15. Gates GF. SPECT bone scanning of the spine. *Semin Nucl Med*. 1998;28:78–94.
16. Cook GJ, Fogelman I. The role of positron emission tomography in skeletal disease. *Semin Nucl Med*. 2001;31:50–61.
17. Schirrmeyer H, Guhlmann A, Kotzerke J, et al. Early detection and accurate description of extent of metastatic bone disease in breast cancer with fluoride ion and positron emission tomography. *J Clin Oncol*. 1999;17:2381–2389.
18. Ghanem N, Uhl M, Brink I, et al. Diagnostic value of MRI in comparison to scintigraphy, PET, MS-CT and PET/CT for the detection of metastases of bone. *Eur J Radiol*. 2005;55:41–55.
19. Shreve PD, Grossman HB, Gross MD, et al. Metastatic prostate cancer: initial finding of PT 2-deoxyglucose-[F-18]fluoro-D-glucose. *Radiology*. 1996;199:751–756.
20. Morris MJ, Akhurst T, Osman I, et al. Fluorinated deoxyglucose positron emission tomography imaging in progressive metastatic prostate cancer. *Urology*. 2002;59:913–918.
21. Fricke E, Machtens S, Hofmann M, et al. Positron emission tomography with ^{11}C -acetate and ^{18}F -FDG in prostate cancer patients. *Eur J Nucl Med Mol Imaging*. 2003;30:607–611.
22. Schoder H, Herrmann K, Gonen M, et al. 2-[^{18}F]Fluoro-2-deoxyglucose positron emission tomography for the detection of disease in patients with prostate-specific antigen relapse after radical prostatectomy. *Clin Cancer Res*. 2005;11:4761–4769.
23. Oyen WJG, Witjes JA, Corstens FHM. Nuclear medicine techniques for the diagnosis and therapy of prostate carcinoma. *Eur Urol*. 2001;40:294–299.
24. Hawkins RA, Choi Y, Huang SC, et al. Evaluation of skeletal kinetics of fluorine 18-fluoride ion and PET. *J Nucl Med*. 1992;33:633–642.
25. Schiepers C, Nuytes J, Bormans G, et al. Fluoride kinetics of the axial skeleton measured in vivo with fluorine-18-fluoride PET. *J Nucl Med*. 1997;38:1970–1976.
26. Hoergerle S, Juengling F, Otte A, et al. Combined FDG and F-18-fluoride whole body PET: a feasible two-in-one approach to cancer imaging. *Radiology*. 1998;209:253–258.
27. Even-Sapir E, Metser U, Flusser G, et al. Assessment of malignant skeletal disease with ^{18}F -fluoride PET/CT. *J Nucl Med*. 2004;45:272–278.
28. Song X, Segars WP, Du Y, et al. Fast modeling of the collimator-detector response in Monte Carlo simulation of SPECT imaging using the angular response function. *Phys Med Biol*. 2005;21:1791–1804.
29. Even-Sapir E, Martin RH, Barnes DC, et al. Role of SPECT in differentiating malignant from benign lesions in the lower thoracic and lumbar vertebrae. *Radiology*. 1993;187:193–198.
30. Thuraijara R, McFarlane J, Traill Z, et al. State-of-the-art approaches to detecting early bone metastasis in prostate cancer. *BJU Int*. 2004;94:268–271.
31. Blake GM, Park-Holman SJ, Cook GJR, et al. Quantitative studies of bone with the use of F18-fluoride and Tc99m-methylene diphosphonate. *Semin Nucl Med*. 2001;1:28–49.
32. Uematsu T, Yuen S, Yukisawa S, et al. Comparison of FDG PET and SPECT for detection of bone metastases in breast cancer. *AJR*. 2005;184:1266–1273.
33. Savelli G, Maffioli L, Maccauro M, et al. Bone scintigraphy and the added value of SPECT (single photon emission tomography) in detecting skeletal lesions. *Q J Nucl Med*. 2001;45:27–37.



The Journal of
NUCLEAR MEDICINE

The Detection of Bone Metastases in Patients with High-Risk Prostate Cancer: ^{99m}Tc -MDP Planar Bone Scintigraphy, Single- and Multi-Field-of-View SPECT, ^{18}F -Fluoride PET, and ^{18}F -Fluoride PET/CT

Einat Even-Sapir, Ur Metser, Eyal Mishani, Gennady Lievshitz, Hedva Lerman and Ilan Leibovitch

J Nucl Med. 2006;47:287-297.

This article and updated information are available at:
<http://jnm.snmjournals.org/content/47/2/287>

Information about reproducing figures, tables, or other portions of this article can be found online at:
<http://jnm.snmjournals.org/site/misc/permission.xhtml>

Information about subscriptions to JNM can be found at:
<http://jnm.snmjournals.org/site/subscriptions/online.xhtml>

The Journal of Nuclear Medicine is published monthly.
SNMMI | Society of Nuclear Medicine and Molecular Imaging
1850 Samuel Morse Drive, Reston, VA 20190.
(Print ISSN: 0161-5505, Online ISSN: 2159-662X)

© Copyright 2006 SNMMI; all rights reserved.

 SOCIETY OF
NUCLEAR MEDICINE
AND MOLECULAR IMAGING