

# PET/CT in Lymphoma: Prospective Study of Enhanced Full-Dose PET/CT Versus Unenhanced Low-Dose PET/CT

Beatriz Rodríguez-Vigil<sup>1</sup>, Nieves Gómez-León<sup>1</sup>, Inmaculada Pinilla<sup>1</sup>, Dolores Hernández-Maraver<sup>2</sup>, Juan Coya<sup>3</sup>, Luis Martín-Curto<sup>3</sup>, and Rosario Madero<sup>4</sup>

<sup>1</sup>Department of Radiology, University Hospital La Paz, Madrid, Spain; <sup>2</sup>Department of Haematology, University Hospital La Paz, Madrid, Spain; <sup>3</sup>Department of Nuclear Medicine, University Hospital La Paz, Madrid, Spain; and <sup>4</sup>Department of Statistics, University Hospital La Paz, Madrid, Spain

PET/CT combines functional and morphologic data and increases diagnostic accuracy in a variety of malignancies. This study prospectively compares the agreement between contrast-enhanced full-dose PET/CT and unenhanced low-dose PET/CT in lesion detection and initial staging of Hodgkin's disease and non-Hodgkin's lymphoma. **Methods:** Forty-seven biopsy-proven lymphoma patients underwent a <sup>18</sup>F-FDG PET/CT study that included unenhanced low-dose CT and enhanced full-dose CT for initial staging. Patients who had undergone previous diagnostic CT for initial staging were excluded. For every patient, each modality of PET/CT images was evaluated by either of 2 pairs of readers, with each pair comprising 1 experienced radiologist and 1 experienced nuclear physician. While evaluating one of the 2 types of PET/CT, the readers were unaware of the results of the other type. Lesion detection, number of sites affected in each anatomic region, and disease stage were assessed. Agreement between techniques was determined by the  $\kappa$ -statistic, and discordances were studied by the McNemar test. Clinical, analytic, histopathologic, diagnostic CT, and PET data; data from other imaging techniques; and follow-up data constituted the reference standard. **Results:** For region-based analysis, no significant differences were found between unenhanced low-dose PET/CT and contrast-enhanced full-dose PET/CT, although full-dose PET/CT showed fewer indeterminate findings and a higher number of extranodal sites affected than did low-dose PET/CT. Agreement between the 2 types of PET/CT was almost perfect for disease stage ( $\kappa = 0.92$ ;  $P < 0.001$ ). **Conclusion:** Our study showed a good correlation between unenhanced low-dose PET/CT and contrast-enhanced full-dose PET/CT for lymph node and extranodal disease in lymphomas, suggesting that unenhanced low-dose PET/CT might suffice in most patients as the only imaging technique for the initial staging of lymphomas, reserving diagnostic CT for selected cases.

**Key Words:** PET/CT; PET; CT; lymphoma; staging

**J Nucl Med 2006; 47:1643–1648**

Received Apr. 23, 2006; revision accepted Jun. 26, 2006.  
For correspondence or reprints contact: Beatriz Rodríguez-Vigil, MD, Department of Radiology, University Hospital La Paz, Paseo de la Castellana 261, 28046 Madrid, Spain.  
E-mail: beatrizrodriguezvigil@yahoo.es  
COPYRIGHT © 2006 by the Society of Nuclear Medicine, Inc.

**H**odgkin's disease (HD) and non-Hodgkin's lymphoma (NHL) are lymphoproliferative disorders representing fewer than 8% of all malignancies but whose incidence has recently been rising by 3%–5% per year (1). These malignancies are potentially curable with current treatment modalities, even in advanced or recurrent disease. The prognosis and survival of patients with lymphoma depend on 3 key points, 2 of which are determined at the moment of diagnosis: histologic grade and clinical stage. The third is response to treatment. Precise staging is crucial to the proper selection of therapy for these patients, to prevent over- or under-treatment.

CT has been the main imaging technique used for the staging and follow-up of lymphoma (2). The fact that CT assessment of disease is based on anatomic criteria of size and shape and on abnormal contrast enhancement implies limitations in the depiction of pathologic changes in normal-sized lymph nodes and in the assessment of extranodal disease. PET with <sup>18</sup>F-FDG provides functional information, but its main drawback of showing few anatomic landmarks impedes precise localization of sites of pathologic <sup>18</sup>F-FDG uptake. In addition, there are some issues regarding specificity, because <sup>18</sup>F-FDG is taken up not only by many malignant tumors but also by sites of active inflammation and physiologically by some organs (3,4).

These shortcomings may be overcome by PET/CT, a method that produces precisely coregistered molecular and morphologic images by allowing them to be obtained on the same scanner without moving the patient (5–7). Controversy exists about whether to perform PET/CT using unenhanced low-dose CT (for attenuation correction and anatomic localization of PET uptake only) or using contrast-enhanced full-dose CT (for diagnostic CT information also) (8). To our knowledge, no prospective study has compared unenhanced low-dose fused PET/CT with contrast-enhanced full-dose fused PET/CT in lymphoma staging.

The purpose of this prospective study was to determine the agreement between unenhanced low-dose PET/CT and

contrast-enhanced full-dose PET/CT in lesion detection and initial staging of HD and NHL to establish the most appropriate protocol of study for this new technique.

## MATERIALS AND METHODS

### Patients

Between May 2004 and August 2005, 47 consecutive patients (29 women and 18 men; mean age, 50 y; range, 15–83 y) with biopsy-proven and untreated lymphoma were included in this prospective study for initial staging. Sixteen had HD and 31 NHL. The patients' characteristics are summarized in Table 1. Because our purpose was to establish a PET/CT protocol for the initial staging of lymphoma, and to avoid unnecessary additional radiation, patients who had previously undergone diagnostic CT for initial staging were excluded. Other exclusion criteria were renal, hepatic, or other oncologic disease; HIV infection; a history of allergic reaction to iodinated contrast media; or pregnancy. All patients underwent a PET/CT study that included unenhanced low-dose CT for PET attenuation correction, the PET study, and contrast-enhanced full-dose CT. The institutional review board of the University Hospital La Paz approved the study, and written informed consent was obtained from all patients.

### PET/CT Protocol

All data were acquired with a combined PET/CT in-line system (Discovery LS; GE Healthcare) that integrates a 4-detector-row spiral CT scanner (LightSpeed Plus; GE Healthcare) with a PET scanner (Advance NXi; GE Healthcare).

Patients fasted for at least 6 h before undergoing scanning, and blood sugar levels were checked to ensure that there was no hyperglycemia (levels > 150 mg/dL). To prevent muscular radiotracer uptake, we instructed the patients to avoid strenuous activity and to sit without speaking in a dimly lit room before the examination and after injection of the radioisotope. Though not routinely administered, oral benzodiazepines were given to nervous patients. A standard dose of 370 MBq of  $^{18}\text{F}$ -FDG was intravenously injected 45–60 min before imaging. In addition, 1,500 mL of an

oral CT contrast agent (diatrizoate meglumine/diatrizoate sodium, 3%) were administered, starting immediately after injection of the  $^{18}\text{F}$ -FDG. Scanning was performed from the base of the skull through the mid thigh while the patients were supine with arms above the head, when tolerated. Patients unable to keep their arms up for the entire study were scanned with arms by the sides. To obtain a precise anatomic correlation between PET and CT images, whole-body scanning was performed with the arms in the same position for both PET and CT. Patients were instructed to breathe shallowly during acquisition of both the CT and the PET images.

Initially, unenhanced low-dose CT was performed with the following parameters: 140 kV, 80 mA, a gantry rotation time of 0.5 s, a collimator width of  $2 \times 5$  mm, and a section thickness of 5 mm (to match the PET section thickness). PET emission scanning was performed immediately after the low-dose CT, with the identical transverse field of view and in the caudocranial direction. The acquisition time for PET was 5 min per table position. Finally, diagnostic contrast-enhanced full-dose CT was performed with the same parameters as for unenhanced low-dose CT, except that the current varied automatically (maximum, 300 mA) with the patient's weight, and 140 mL of an iodinated contrast agent (Xenetix 300, iobitridol [300 mg of iodine per milliliter]; Guerbet) were first administered intravenously at 3 mL/s using an automated injector (model XD 5500; Ulrich Medical Systems).

The CT data were resized from a  $512 \times 512$  matrix to a  $128 \times 128$  matrix to match the PET data so that the scans could be fused and CT-based transmission maps could be generated. PET datasets were reconstructed iteratively with an ordered-subsets expectation maximization algorithm and segmented attenuation correction and the CT data.

Coregistered scans were displayed using eNTEGRA or Xeleris software (GE Healthcare).

### Image Evaluation

The images were evaluated by 2 pairs of readers, with each pair comprising a nuclear medicine physician and a radiologist who interpreted the PET/CT images in consensus. All readers had 3 y of experience in PET/CT technique. For every patient, each modality of PET/CT was given randomly to either of the 2 pairs of readers, who evaluated the findings without knowledge of the findings for the other type of PET/CT. In this way, each of the 2 pairs of specialists interpreted the low-dose or the full-dose PET/CT study of each patient.

The possibility of nodal and extranodal disease was considered when lesions were clearly present on PET/CT images according to the combined morphologic CT and  $^{18}\text{F}$ -FDG uptake criteria. Abnormal  $^{18}\text{F}$ -FDG uptake was defined as radiotracer accumulation thought to be outside the normal anatomic structures and of greater intensity than background activity inside the normal structures, excluding uptake considered physiologic because it was symmetric or typically located. Only if no pathologic  $^{18}\text{F}$ -FDG uptake was seen were CT criteria of lymphomatous disease—based on nodal size, abnormal extranodal enhancement (on full-dose PET/CT), or structural changes—used alone to consider lymphomatous disease. These CT criteria were especially important in types of lymphoma with low or no  $^{18}\text{F}$ -FDG uptake.

Lesion detection with each modality was estimated for nodal and extranodal sites separately. For the analysis, lymph node chains were grouped into 3 broad anatomic regions: cervical, thoracic, and abdominal/groin. For each group, the number of sites affected was assessed (Table 2). The following extranodal sites

**TABLE 1**  
Patients' Characteristics

Characteristic	NHL	HD
<i>n</i>	31	16
M:F	9:22	10:6
Mean age (y)	59	34
Age range (y)	15–83	20–61
Pathologic subtype		
	Follicular, 2	Nodular sclerosis, 11
	Burkitt's, 1	Mixed cellularity, 2
	DLBCL, 17	Lymphocyte predominant, 3
	MCL, 1	
	MZL, 6	
	SLL, 1	
	PTCL, 2	
	ATCL, 1	

DLBCL = diffuse large B-cell lymphoma; MCL = mantle cell lymphoma; MZL = marginal zone lymphoma; SLL = small lymphocytic lymphoma; PTCL = peripheral T-cell lymphoma; ATCL = anaplastic T-cell lymphoma.

**TABLE 2**  
Number of Anatomic Sites

Nodal chain			
Cervical	Thoracic	Abdominal/groin	Extranodal
Right submandibular	Superior mediastinal	Celiac trunk	Bone marrow
Left submandibular	Anterior mediastinal	Mesenteric	Spleen
Right jugular	Posterior mediastinal	Retroperitoneal	Liver
Left jugular	Right paratracheal	Right iliac	Gastric
Right posterior cervical	Left paratracheal	Left iliac	Intestinal
Left posterior cervical	Right axillary	Right inguinal	Genitourinary
Right supraclavicular	Left axillary	Left inguinal	Lung
Left supraclavicular	Right hilar		Bone
	Left hilar		Other

were evaluated: lung, liver, spleen, gastrointestinal and genitourinary tracts, bone, bone marrow, and other. The findings for each of these sites were graded as positive (2), indeterminate (1), or negative (0) for lymphomatous infiltration. Findings were considered indeterminate when the observers were not sure that lymphoma was present. The number of sites affected in each of the 4 anatomic sites (the 3 nodal chains and the extranodal site) on unenhanced low-dose PET/CT was compared with that on enhanced full-dose PET/CT.

For each patient, the true clinical stage according to the modified Ann Arbor system was determined using the reference standard. Then, the CT and PET data of the reference standard were replaced by the low-dose PET/CT and full-dose PET/CT data, and both new staging algorithms were obtained and compared with each other.

### Reference Standard

Although all lymphomas were histologically proven, it is neither feasible nor ethical to systematically subject all patients with lymphadenopathies and other lesions to biopsy for staging. We defined the standard of reference as the sum of many factors: clinical history, physical examination, laboratory work-up (cell blood count, serum creatinine, urea, liver function tests, lactate dehydrogenase,  $\beta$ 2 microglobulin, and viral serologies), imaging findings (contrast-enhanced full-dose CT, PET, and MRI when necessary), iliac crest bone marrow biopsy, endoscopy, lumbar puncture, other diagnostic tests, biopsies, surgery when clinically indicated, response to treatment, and follow-up data. Follow-up PET/CT data after 3 cycles of treatment were available for all patients, excepting one who died before that time.  $^{18}\text{F}$ -FDG uptake similar on follow-up to that seen previously was defined as a nonresponse to chemotherapy, a reduction of  $^{18}\text{F}$ -FDG uptake on follow-up was defined as a partial response to chemotherapy, and the disappearance of  $^{18}\text{F}$ -FDG uptake was defined as a complete or full response to chemotherapy. If no pathologic uptake had been seen on the initial staging study, follow-up criteria were based on CT findings (reduction of nodal size or disappearance of extranodal lesions).

### Statistical Analysis

Statistical analysis was done with SPSS software (release 9.0; SPSS Inc.) for Windows (Microsoft). Quantitative data were described as mean, minimum, and maximum; qualitative data were described as counts and percentages. Indeterminate findings were classified as negative for the analysis of agreement and discordances. Agreement among techniques was studied by the  $\kappa$ -statistic. The McNemar test was used to analyze symmetry. Differences among

techniques for the number of anatomic sites detected were studied by the Wilcoxon signed-rank test. Two-sided tests were used, and a  $P$  value of less than 0.05 was considered statistically significant.

## RESULTS

### Region-Based Analysis of Nodal and Extranodal Disease

The results for region-based nodal disease and extranodal disease are shown in Table 3. Complete agreement was found between low-dose PET/CT and full-dose PET/CT for the cervical nodal region ( $\kappa = 1$ ;  $P < 0.001$ ), although in 1 patient both techniques were indeterminate for cervical nodal disease. This patient had a  $^{18}\text{F}$ -FDG PET-negative marginal zone lymphoma that, on PET/CT images, showed clear abdominal adenomegalies and splenic disease, as well as cervical lymph node uptake in the upper limit of normal, which was considered indeterminate but was proven positive on the basis of the reference standard.

**TABLE 3**  
Number and Percentage of Patients with Regional Disease on Unenhanced Low-Dose PET/CT and on Contrast-Enhanced Full-Dose PET/CT

Counts (%)	Low-dose PET/CT	Full-dose PET/CT
<b>Cervical</b>		
Negative	15 (31.9)	15 (31.9)
Indeterminate	1 (2.1)	1 (2.1)
Positive	31 (66.0)	31 (66.0)
<b>Thoracic</b>		
Negative	11 (23.4)	11 (23.4)
Indeterminate	1 (2.1)	0 (0.0)
Positive	35 (74.5)	36 (76.6)
<b>Abdominal</b>		
Negative	19 (40.4)	19 (40.4)
Indeterminate	1 (2.1)	0 (0.0)
Positive	27 (57.4)	28 (59.6)
<b>Extranodal</b>		
Negative	10 (21.3)	10 (21.3)
Indeterminate	0 (0.0)	0 (0.0)
Positive	37 (78.7)	37 (78.7)

Data in parentheses are percentages.

In 2 patients, low-dose PET/CT showed indeterminate findings for the thoracic and the abdominal lymph nodes because of low-uptake infraclavicular and splenic hilum adenopathies, respectively, that were difficult to detect on low-dose PET/CT but were clearly identified on full-dose PET/CT and on the basis of the reference standard. Thus, contrast-enhanced full-dose PET/CT showed no indeterminate findings in these nodal regions.

For detecting extranodal involvement, no discrepancies were found between the 2 PET/CT modalities. Both found that 78.7% of the patients had extranodal disease, and this finding agreed with the reference standard.

#### Number of Anatomic Sites

No statistically significant differences between unenhanced low-dose PET/CT and enhanced full-dose PET/CT were found in the number of nodal and extranodal sites detected, although for extranodal involvement, more sites were detected on full-dose PET/CT than on low-dose PET/CT in 4 of the 47 patients ( $P = 0.063$ ). These 4 patients had gastric, renal, colonic, or pancreatic lymphomatous disease that was seen as an enhanced mass or area within the viscera on enhanced full-dose PET/CT but not on unenhanced low-dose PET/CT. These cases were confirmed by the reference standard (the renal involvement by biopsy, and the others by clinical data, other imaging findings, and follow-up studies).

#### Initial Clinical Staging

Agreement in staging was almost perfect between low-dose PET/CT and full-dose PET/CT ( $\kappa = 0.92$ ;  $P < 0.001$ ) (Table 4). Differences in clinical stage between the 2 new algorithms were found in only 1 case, which was correctly upstaged by full-dose PET/CT from stage II to stage III because of subsequently confirmed abdominal nodal in-

**TABLE 4**  
Comparisons of Disease Clinical Stage Between Unenhanced Low-Dose PET/CT and Contrast-Enhanced Full-Dose PET/CT

Low-dose PET/CT	Full-dose PET/CT			
	I	II	III	IV
I	3	—	—	—
II	—	7	1	—
III	—	—	6	—
IV	—	—	—	30

volvement (Figs. 1 and 2). No cases were downstaged with PET/CT, compared with the reference standard.

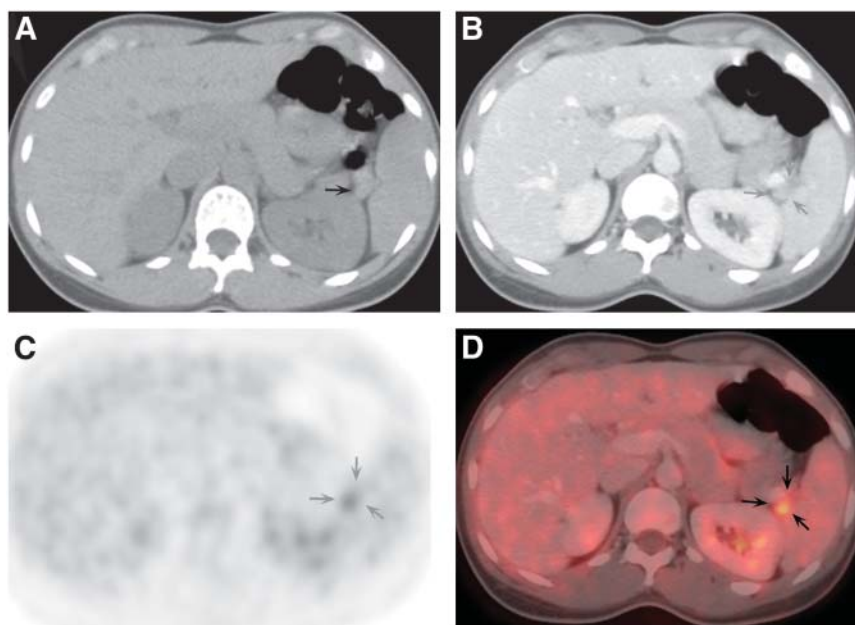
#### Incidental Findings


A small endometrial carcinoma, which was histologically proven, and 1 case of jugular thrombosis were detected on contrast-enhanced full-dose PET/CT but not on unenhanced low-dose PET/CT.

#### DISCUSSION

Since the first prototype PET/CT scanner was built in 1998 (5–7), several studies have demonstrated the superiority of PET/CT over PET and CT alone in the staging and restaging of cancer (7,9–17). Some of these studies included a small number of lymphomas within a heterogeneous series of different malignancies (7,9–11). Several reports analyzed the role of PET/CT in the staging and restaging of lymphoma (18–20). None of these studies of lymphomas were prospective, and none compared unenhanced low-dose PET/CT with enhanced full-dose PET/CT. However, the optimal protocol of PET/CT is not yet determined, and controversy remains regarding the acquisition of the CT component of this

**FIGURE 1.** 27-year-old woman with HD (nodular sclerosis) who underwent PET/CT for initial staging. (A) Axial low-dose unenhanced CT showed no pathologic findings in upper abdomen. Small finding in splenic hilum (arrow) was considered to be vessel or accessory spleen. (B) Axial full-dose contrast-enhanced CT at same level demonstrated small lymphadenopathy at splenic hilum that, because of its small diameter (arrows), was not considered pathologic. No other abnormalities were seen in abdomen or pelvis. (C) Axial PET at same level showed, next to splenic hilum, a small, focal area of increased  $^{18}\text{F}$ -FDG uptake whose anatomic origin and location were difficult to determine (arrows). (D) Axial full-dose enhanced PET/CT clearly demonstrated that pathologic uptake corresponded to small adenopathy in splenic hilum (arrows). Mediastinal and cervical disease were also assessed (not shown). Because no other abdominal or pelvic disease was found, full-dose PET/CT led to upstaging from stage II to stage III.





**FIGURE 2.** Same patient as in Figure 1, after 3 cycles of chemotherapy. (A) Axial contrast-enhanced CT at level of splenic hilum showed no abnormalities. (B) Axial PET at same level demonstrated no pathologic  $^{18}\text{F}$ -FDG uptake. (C) Findings on axial PET/CT image were also normal. Supra- and infradiaphragmatic nodal disease responded well to treatment, and response was complete at end of chemotherapy (not shown).

diagnostic modality. One school of thought believes that CT image data should be used only for attenuation correction of PET, reduction of acquisition time, and localization of hypermetabolic lesions, whereas others advocate the need to perform contrast-enhanced and high-resolution CT (8,21,22). Among the latest discussions, there still have been 2 different opinions (23): The work group of Pittsburgh University Medical Center, and others, begins the PET/CT study with the acquisition of contrast-enhanced and diagnostic CT and posteriorly acquires PET images covering the same axial extent, using the CT data for both attenuation correction and fused PET/CT images (6,24–28). In contrast, other authors obtain 2 CT scans, low- or intermediate-dose unenhanced CT for attenuation correction and, if required, diagnostic intravenous contrast-enhanced CT at the end of the study (8,29). These authors affirm that intravenous iodinated contrast material produces high-density regions on CT that, when applied as transmission images, lead to artifactual hot spots on the attenuation-corrected image or quantitative overestimation of  $^{18}\text{F}$ -FDG activity (30,31). Nevertheless, recent reports (25,26) have shown that the presence of intravenous contrast material at normal concentrations actually has little effect on the CT-based attenuation correction factors. Likewise, the use of oral contrast material at large intestinal volumes and a wide range of concentrations could lead to overcorrection of the PET data. However, some studies have also demonstrated that there is only a small, clinically irrelevant effect on the standardized uptake value (32,33). In fact, some have advocated the use of oral and intravenous contrast materials to improve the diagnostic capacity of the combined PET/CT study (27).

Hany et al., in a prospective study of 53 different tumors (including 2 lymphomas), compared the accuracy of PET alone with that of PET/CT in tumor staging and restaging (7). Fused PET/CT was performed using unenhanced CT at 10, 40, 80, and 120 mA. They demonstrated a higher accuracy for PET/CT than for PET alone regarding lesion type and localization but no significant differences when the different currents were used. With the use of a higher CT current, only minor diagnostic improvements were seen, so they decided from then on to use only 80-mA CT for transmission

correction. However, in that study, pathologic correlation was not available in all cases and the gold standard for staging was not clearly specified, nor did the study specify whether previous diagnostic CT had been performed (increasing the global radiation dose). According to the literature reports, the use of CT contrast agents in PET/CT is still controversial. However, the standard of care for CT generally dictates the use of either intravenous or oral contrast material, or both as in the case of lymphoma studies, as well as the use of a diagnostic current. In our series, no significant artifacts or diagnostic problems resulting from the use of oral or intravenous contrast material were identified when PET/CT images were analyzed.

We did not find statistically significant differences between unenhanced low-dose PET/CT and enhanced full-dose PET/CT in the depiction of region-based nodal and extranodal disease or in the number of positive anatomic sites detected. However, full-dose PET/CT showed fewer indeterminate nodal lesions (1 patient) than did low-dose PET/CT (3 patients), which may, in our opinion, increase the radiologist's confidence in lesion detection.

Although, in our study, contrast-enhanced full-dose PET/CT detected a larger number of extranodal sites involved by lymphoma than did unenhanced low-dose PET/CT, this difference did not reach statistical significance. Overall, in only 8 patients (17%) did the diagnostic enhanced-CT component of the full-dose PET/CT study provide additional information (2 nodal lesions, 4 extranodal lesions, and 2 incidental findings) that was attributed to the use of iodinated endovenous contrast material. Furthermore, these additional findings led to a change in stage in only 1 patient (upstaged by full-dose PET/CT). Consequently, in our prospective study, agreement for initial staging was statistically significant and almost perfect between the 2 PET/CT techniques, and the enhanced-CT component seemed to add little to the ultimate management of these patients.

Our study had some limitations. The main shortcoming was that our series included relatively few patients because of the strict inclusion criteria needed to achieve our main purpose: that is, to establish the optimal protocol for PET/CT studies. Second, because we did not have histopathologic

confirmation for all lesions detected, some findings had to be evaluated on the basis of follow-up imaging and clinical data. Third, the contrast-enhanced full-dose PET/CT was performed during shallow breathing, to obtain a precise anatomic correlation between CT and PET images. However, this method was not typical for diagnostic thoracic CT, and some small lung lesions could have been missed in the initial staging studies. In our hospital, we require additional thoracic diagnostic CT when doubtful lung lesions are found on the PET/CT study, although such additional imaging was not necessary for any patient in our small series.

## CONCLUSION

This study showed a good correlation between low-dose unenhanced PET/CT and full-dose contrast-enhanced PET/CT for lymph node and extranodal disease in lymphomas, raising questions about the need for performing enhanced PET/CT on these patients. Our data suggest that, in most patients, PET/CT performed with low-dose CT and without intravenous iodinated contrast material might suffice as the only imaging technique for the initial staging of HD and NHL, reducing unnecessary additional radiation exposure in this population. Diagnostic CT could be reserved for selected cases. Another approach could be to perform enhanced PET/CT at initial staging and, unless the study shows  $^{18}\text{F}$ -FDG PET-negative lymphoma, continue performing unenhanced PET/CT on follow-up. However, these are preliminary results, and further studies on a larger number of patients are needed to determine the role of PET/CT in the initial staging of lymphomas and to establish the most appropriate protocol.

## ACKNOWLEDGMENTS

We thank Dr. Elena Andradas for her helpful advice and the Laín Entralgo Agency for its substantial work in defining the effectiveness, security, and indications of PET/CT technique. This work was financially supported by the Fondo de Investigaciones Sanitarias Project 03/0149.

## REFERENCES

- Segall GM. FDG PET imaging in patients with lymphoma: a clinical perspective. *J Nucl Med*. 2001;42:609–610.
- Lu P. Staging and classification of lymphoma. *Semin Nucl Med*. 2005;35:160–164.
- Shreve PD, Anzai Y, Wahl RL. Pitfalls in oncologic diagnosis with FDG PET imaging: physiologic and benign variants. *Radiographics*. 1999;19:61–77.
- Barrington SF, O'Doherty MJ. Limitations of PET for imaging lymphoma. *Eur J Nucl Med Mol Imaging*. 2003;30(suppl):S117–S127.
- Beyer T, Townsend DW, Brun T, et al. A combined PET/CT scanner for clinical oncology. *J Nucl Med*. 2000;41:1369–1379.
- Townsend DW, Beyer T. A combined PET/CT scanner: the path to true image fusion. *Br J Radiol*. 2002;75(suppl):S24–S30.
- Hany TF, Steinert HC, Goerres GW, Buck A, von Schulthess GK. PET diagnostic accuracy: improvement with in-line PET-CT system: initial results. *Radiology*. 2002;225:575–581.
- Wiley G. Disruptive technology: the conflict over PET/CT. *Imaging Economics*. 2005;1:1–10.
- Beyer T, Townsend DW, Blodgett TM. Dual-modality PET/CT tomography for clinical oncology. *Q J Nucl Med*. 2002;46:24–34.
- Israel O, Mor M, Gaitini D, et al. Combined functional and structural evaluation of cancer patients with hybrid camera-based PET/CT system using  $(^{18}\text{F})\text{FDG}$ . *J Nucl Med*. 2002;43:1129–1136.
- Charron M, Beyer T, Bohnen NN, et al. Image analysis in patients with cancer studied with a combined PET and CT scanner. *Clin Nucl Med*. 2000;25:905–910.
- Bristow RE, del Carmen MG, Pannu HK, et al. Clinically occult recurrent ovarian cancer: patient selection for secondary cytoreductive surgery using combined PET/CT. *Gynecol Oncol*. 2003;90:519–528.
- Makhija S, Howden N, Edwards R, Kelley J, Townsend DW, Meltzer CC. Positron emission tomography/computed tomography imaging for the detection of recurrent ovarian and fallopian tube carcinoma: a retrospective review. *Gynecol Oncol*. 2002;85:53–58.
- Patel PV, Cohade C, Chin BB. PET/CT localizes previously undetectable metastatic lesions in recurrent fallopian tube carcinoma. *Gynecol Oncol*. 2002;87:323–326.
- Bar-Shalom R, Yefremov N, Guralnik L, et al. Clinical performance of PET/CT in evaluation of cancer: additional value for diagnostic imaging and patient management. *J Nucl Med*. 2003;44:1200–1209.
- Antoch G, Statta J, Nemat AT, et al. Non-small cell lung cancer: dual-modality PET/CT in preoperative staging. *Radiology*. 2003;229:526–533.
- Ell PJ. The contribution of PET/CT to improved patient management. *Br J Radiol*. 2006;79:32–36.
- Freudenberg LS, Antoch G, Schütt P, et al. FDG-PET/CT in re-staging of patients with lymphoma. *Eur J Nucl Med Mol Imaging*. 2004;31:325–329.
- Raanani P, Shasha T, Perry C, et al. Is CT scan still necessary for staging in Hodgkin and non-Hodgkin lymphoma patients in the PET/CT era? *Ann Oncol*. 2006;17:117–122.
- Schaefer NG, Hany TF, Taverna C, et al. Non-Hodgkin lymphoma and Hodgkin disease: coregistered FDG PET and CT at staging and restaging—do we need contrast enhanced CT? *Radiology*. 2004;232:823–829.
- Czernin J, Schelbert H. PET/CT imaging: facts, opinions, hopes, and questions. *J Nucl Med*. 2004;45(suppl):1S–3S.
- Antoch G, Freudenberg LS, Beyer T, Bockisch A, Debatin JF. To enhance or not to enhance?  $^{18}\text{F}$ -FDG and CT contrast agents in dual-modality  $^{18}\text{F}$ -FDG PET/CT. *J Nucl Med*. 2004;45(suppl):S56–S65.
- Coleman ER, Delbeke D, Guiberteau MJ, et al. Concurrent PET/CT with an integrated imaging system: intersociety dialogue from the joint working group of the American College of Radiology, the Society of Nuclear Medicine, and the Society of Computed Body Tomography and Magnetic Resonance. *J Nucl Med*. 2005;46:1225–1239.
- Townsend DW, Beyer T, Blodgett TM. PET/CT scanners: a hardware approach to image fusion. *Semin Nucl Med*. 2003;33:193–204.
- Yau YY, Chan WS, Tam YM, et al. Application of IV contrast in PET/CT: does it really introduce significant attenuation correction error? *J Nucl Med*. 2005;46:283–291.
- Beyer T, Antoch G, Bockisch A, Statta J. Optimized intravenous contrast administration for diagnostic whole-body  $^{18}\text{F}$ -FDG PET/CT. *J Nucl Med*. 2005;46:429–435.
- Antoch G, Freudenberg LS, Statta J, et al. Whole-body positron emission tomography-CT: optimized CT using oral and IV contrast materials. *AJR*. 2002;179:1555–1560.
- Antoch G, Beyer T, Freudenberg S, Müller SP, Bockisch A, Debatin JF. PET/CT or CT/PET? A radiologist's perspective. *Electromedica*. 2003;71:64–69.
- Cohade C, Wahl RL. Applications of positron emission tomography/computed tomography image fusion in clinical positron emission tomography: clinical use, interpretation methods, diagnostic improvements. *Semin Nucl Med*. 2003;33:228–237.
- Nakamoto Y, Chin BB, Kraitchman DL, Lawler LP, Marshall LT, Wahl RL. Effects of non-ionic intravenous contrast agents at PET/CT imaging: phantom and canine studies. *Radiology*. 2003;227:817–824.
- Cook GJ, Wegner EA, Fogelman I. Pitfalls and artifacts in  $^{18}\text{F}$ FDG PET and PET/CT oncologic imaging. *Semin Nucl Med*. 2004;34:122–133.
- Dizendorf E, Hany TF, Buck A, Von Schulthess GK, Burger C. Cause and magnitude of the error induced by oral CT contrast agent in CT-based attenuation correction of PET emission studies. *J Nucl Med*. 2003;44:732–738.
- Dizendorf EV, Treyer V, Von Schulthess GK, Hany TF. Application of oral contrast media in coregistered positron emission tomography-CT. *AJR*. 2002;179:477–481.



The Journal of  
NUCLEAR MEDICINE

## **PET/CT in Lymphoma: Prospective Study of Enhanced Full-Dose PET/CT Versus Unenhanced Low-Dose PET/CT**

Beatriz Rodríguez-Vigil, Nieves Gómez-León, Inmaculada Pinilla, Dolores Hernández-Maraver, Juan Coya, Luis Martín-Curto and Rosario Madero

*J Nucl Med.* 2006;47:1643-1648.

---

This article and updated information are available at:  
<http://jnm.snmjournals.org/content/47/10/1643>

---

Information about reproducing figures, tables, or other portions of this article can be found online at:  
<http://jnm.snmjournals.org/site/misc/permission.xhtml>

Information about subscriptions to JNM can be found at:  
<http://jnm.snmjournals.org/site/subscriptions/online.xhtml>

*The Journal of Nuclear Medicine* is published monthly.  
SNMMI | Society of Nuclear Medicine and Molecular Imaging  
1850 Samuel Morse Drive, Reston, VA 20190.  
(Print ISSN: 0161-5505, Online ISSN: 2159-662X)

© Copyright 2006 SNMMI; all rights reserved.