

MIBG and Somatostatin Receptor Analogs in Children: Current Concepts on Diagnostic and Therapeutic Use

Farzana D. Pashankar, MD, MRCP¹; M. Sue O'Dorisio, MD, PhD¹; and Yusuf Menda, MD²

¹Department of Pediatrics, University of Iowa Carver College of Medicine, Iowa City, Iowa; and ²Department of Radiology, University of Iowa Carver College of Medicine, Iowa City, Iowa

Nuclear imaging techniques such as bone scans, metaiodobenzylguanidine (MIBG) scans, and ¹¹¹In-diethylenetriaminepenta-acetic acid-octreotide scans have greatly increased the sensitivity and specificity of both diagnostic and follow-up protocols for pediatric solid tumors. Molecular targets that are specific for certain pediatric tumors are now being developed. Targets include cell membrane receptors targeted by specific ligands, subcellular organelles targeted by false transmitters, and cellular proteins targeted by antibodies. This review focuses on the use of MIBG (which is a false transmitter) and octreotide (which is a ligand for G protein receptor) in the diagnosis and treatment of solid tumors that affect children and young adults.

Key Words: metaiodobenzylguanidine; molecular targets; pediatric tumors

J Nucl Med 2005; 46:55S–61S

Neuroblastoma is the most common extracranial malignant solid tumor in childhood. It constitutes approximately 8%–10% of pediatric cancers. The annual incidence is 10 cases per million in white children and about 8 per million in children of African descent. Approximately 600 new cases are seen in the United States each year. Neuroblastomas occur mainly in young children, with 50% occurring by 2 y and 75% by 4 y of age (1). They arise from neural crest derivatives in the adrenal medulla or the sympathetic nervous system, with 65% of primary tumors found in the adrenals and the remainder originating anywhere along the sympathetic nervous chain. Neuroblastoma is usually staged according to the categories of the International Neuroblastoma Staging System (2). Stage IVS and stage I neuroblastoma can spontaneously regress, whereas stage IV neuroblastoma is highly malignant, with more than 50% of such

children having metastases at the time of presentation and a 5-y survival rate of only 30%–40%.

Pheochromocytomas are rare in children under the age of 6 y and are seen primarily in adolescence or young adulthood. These tumors arise from chromaffin cells, a neural crest derivative. More than 85% occur in the adrenal medulla, with the remainder arising in extraadrenal sites, such as the organ of Zuckerkandl and sympathetic ganglia surrounding the kidney. Pheochromocytoma is associated with several familial syndromes: multiple endocrine neoplasias (MENIIA and IIB), von Hippel–Landau syndrome, and neurofibromatosis (NF-1). These tumors usually manifest clinically with hypertension, palpitations, headaches, pallor, and tremors caused by catecholamine excess. Elevated levels of plasma and urinary catecholamines are diagnostic. Pheochromocytomas are generally very slow-growing tumors and, if tumors are completely excised before becoming metastatic, patients have complete recovery. However, a small percentage of these tumors, particularly the extra-adrenal pheochromocytomas, metastasize, and, with limited current treatment options, these patients eventually die of the disease (3).

MIBG USE IN CHILDREN

Metaiodobenzylguanidine (MIBG) was first developed at the University of Michigan (4). It is an aralkylguanidine, which is structurally similar to norepinephrine. It concentrates within secretory granules of catecholamine-producing cells (5–7). Once iodinated, MIBG can be used for localization of neural crest tumors such as neuroblastoma and pheochromocytoma. The first report of localization of pheochromocytoma with ¹³¹I-MIBG was published in 1981 (8). Positive localization of neuroblastoma with ¹³¹I-MIBG was subsequently reported (9). In addition to its utility for imaging, MIBG is used in therapy of neuroblastoma and pheochromocytoma.

MIBG is radioiodinated with ¹²³I or ¹³¹I. The ¹²³I is a pure γ -emitter with a short half-life of 13 h and principal photon energy of 159 keV, which is highly suitable for γ -camera imaging. In comparison, ¹³¹I-MIBG emits β -particles and high-energy γ -rays with a main γ -emission energy of 364

Received Jul. 3, 2004; revision accepted Oct. 25, 2004.

For correspondence or reprints contact: M. Sue O'Dorisio, MD, PhD, University of Iowa Foundation Professor, Director Pediatric Hematology/Oncology, 2560, JPP, University of Iowa Hospital, 200 Hawkins Drive, Iowa City, IA 52242.

E-mail: sue-odorisio@uiowa.edu

keV and a long half-life of 8.05 d. The whole-body radiation dose for ^{123}I -MIBG is approximately 5% that of ^{131}I -MIBG (10). The favorable dosimetry and better imaging characteristics, including high-quality SPECT capability, make ^{123}I -MIBG the agent of choice, despite its higher cost (11). Unfortunately, only ^{131}I -MIBG is commercially available in the United States, and the availability of ^{123}I -MIBG is limited to only a few centers that produce their own radiopharmaceutical for local use under an Investigational New Drug exemption approved by the U.S. Food and Drug Administration (12). In Europe, ^{123}I -MIBG is widely available. There is no published data comparing the sensitivities and specificities of ^{131}I - and ^{123}I -MIBG imaging in neuroblastoma. A recent case report described an extra-adrenal pheochromocytoma in the bladder that was detected by ^{123}I -MIBG but missed by ^{131}I -MIBG scintigraphy (13).

The uptake of MIBG in adrenomedullary tissue occurs by a type I amine uptake mechanism (6,7,10). Once inside the cell, the majority of MIBG remains within the cytoplasm in neuroblastoma cells, whereas in pheochromocytoma cells, MIBG is actively transported into the granules. The majority of ^{131}I -MIBG is excreted unchanged through the urinary tract (40%–55% in 24 h; 70%–90% in 96 h). Small fractions are excreted in the gut.

Medications, including many antihypertensives, sympathomimetics, tricyclic antidepressants, and antipsychotics reduce uptake and storage of MIBG (14). These medications are rarely used in children. The most common medications that may interfere with visualization include nonprescription cough and cold preparations containing pseudoephedrine. Cardiac drugs, including calcium channel blockers (nifedipine) and angiotensin-converting enzyme inhibitors (captopril, enalapril), may interfere with visualization, and special attention should be paid to these agents when imaging patients with pheochromocytoma (15).

Patient Preparation

On the day of the procedure, patients and parents should be asked about exposure to potential interfering agents. If none is noted, a peripheral intravenous line is established. The dose of MIBG is administered by slow intravenous injection over at least 5 min. Potential adverse effects of MIBG injection (vomiting, tachycardia, pallor, abdominal pain) are rare when slow injection is used. Injection via central venous catheters should be avoided if possible.

Another important consideration is radiation exposure to the thyroid gland from free radioiodide that forms as a result of in vivo deiodination of MIBG. To reduce the uptake of free radioiodide in the thyroid, patients scheduled to undergo a ^{131}I -MIBG scan are given a saturated solution of potassium iodide, beginning preferably the day before the injection of the radiopharmaceutical and continuing for 1 wk after the administration of MIBG. Recommended doses are 32 mg of potassium iodide daily for children ages 1 mo

to 3 y, 65 mg for those 3 to 13 y, and 130 mg for those older than 13 y. For newborns, the recommended dose is 16 mg only on the day before tracer injection (11).

For patients receiving ^{131}I -MIBG therapy, a single dose of thyroxine (100 mcg/m²) and 2 doses 12 h apart of methimazole (0.25 mg/kg/dose) should be added to the previously described potassium iodide regimen (16).

Imaging Protocol

The administered dose of ^{131}I -MIBG is 0.52 MBq/kg (3.7–37 MBq). Imaging is performed at 24, 48, and 72–96 h. With ^{131}I -MIBG, most centers acquire spot images covering the whole body, usually 20 min or 100,000 counts per spot image, as in Figures 1 and 2. The administered dose of ^{131}I -MIBG is 7.4 MBq/kg (37–370 MBq), with images obtained at 24 and 48 h, 10 min per spot image, with additional SPECT as necessary.

Knowledge of the normal biodistribution of MIBG is important in order to avoid misinterpretation. Uptake of MIBG normally occurs in the liver, spleen, myocardium, salivary glands, and normal adrenals. In infants, myocardial uptake may be particularly high. Other organs, including skeletal muscles, nasal mucosa, lungs, bladder, and colon, may demonstrate some uptake. Uptake of radioiodine in the thyroid will depend on the level of thyroid blockade (17–19).

MIBG SCINTIGRAPHY

The scope of MIBG scintigraphy has expanded considerably in recent years. It is used not only to diagnose and stage neuroblastoma but also at follow-up to assess response to therapy, exclude a subclinical relapse, and plan MIBG therapy. The specificity of MIBG scintigraphy approaches 100%, whereas sensitivity for staging has been reported to be 90%–95% in various studies (11,20–24). In some patients, neuroblastoma may present with a paraneoplastic syndrome in which the primary is occult. In these cases, MIBG scans may be helpful in screening the entire patient for an occult primary.

The prognosis in neuroblastoma is highly dependent on staging. It is important, then, to accurately localize the full extent of disease before initiating therapy. Traditional staging investigations include CT and MR imaging, bone scan, and bone marrow aspiration biopsy. On most current Children's Oncology Group protocols, MIBG is not required for staging. However, MIBG scanning is required on the latest Children's Oncology Group protocol for high-risk neuroblastoma. Several studies have looked at the utility of MIBG for staging and have compared MIBG with bone scans, MR imaging, and bone marrow biopsies (25–27). Studies comparing MIBG scans with bone scans have produced equivocal results. Gordon et al. (25) compared ^{123}I -MIBG and $^{99\text{m}}\text{Tc}$ -methylene diphosphonate ($^{99\text{m}}\text{Tc}$ -MDP) bone scans in 44 children. They reported 8 false-negative ^{123}I -MIBG scans for skeletal involvement (4 at diagnosis, 4 at follow-up). In contrast, Shulkin et al. (26) compared ^{131}I -MIBG and bone

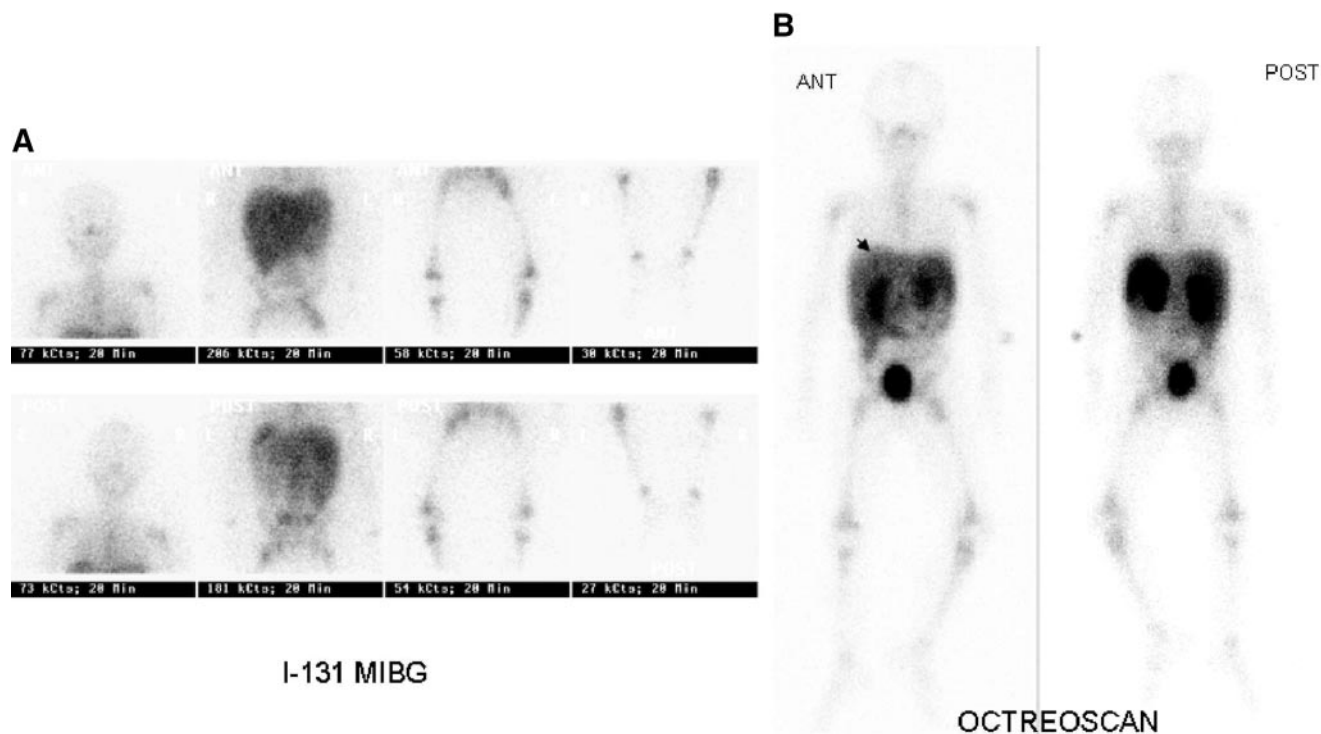


FIGURE 1. ^{131}I -MIBG and ^{111}In -DTPA-octreotide images of patient with neuroblastoma. (A) ^{131}I -MIBG images at 48 h demonstrate diffuse abnormal bone marrow uptake in proximal upper and lower extremities and in spine. (B) ^{111}In -DTPA-octreotide images at 24 h show abnormal bone marrow uptake in a similar distribution. ^{111}In -DTPA-octreotide also shows subtle focus at superior aspect of right lobe of liver, which is not appreciated on MIBG scan (arrowhead). Bone marrow disease was confirmed with biopsy. CT of the abdomen showed multiple liver lesions.

scans in 77 patients and observed no false-negative ^{131}I -MIBG scans. Instead, they identified a greater number (almost 2-fold) of skeletal lesions on ^{131}I -MIBG scanning. It appears that to detect skeletal neuroblastoma both MIBG and $^{99\text{m}}\text{Tc}$ -MDP bone scans may be useful. MIBG provides a better idea of extent of disease, whereas $^{99\text{m}}\text{Tc}$ -MDP bone scans are needed because of the problem of false-negative MIBG scans. Studies comparing MIBG scans with single bone marrow aspiration biopsy have concluded that MIBG scintigraphy indicated bone marrow infiltration by neuroblastoma in considerably more patients than did bone marrow aspiration biopsy (28).

Apart from usefulness in diagnosis and staging, MIBG scans may help in predicting overall response and event-free survival in neuroblastoma. Suc et al. (29) devised a scoring system based on MIBG uptake in 7 different body segments. They found that patients with an initial MIBG score <4 had a higher probability of achieving complete response after induction. Using another scoring system, Ady et al. (30) evaluated sequential ^{123}I -MIBG scans performed at the beginning, midcourse, and end of induction chemotherapy and found that the midcourse score strongly correlated with complete remission at the end of induction. Matthay et al. (31) used the same scoring system as in the initial study by Ady et al. but extended the study to show a correlation with

both overall response and bone marrow response after all pretransplantation therapy, before final myeloablative therapy, and with ultimate event-free survival. They found that the probability of having a complete response before transplantation was significantly higher if the relative score after 2 cycles was ≤ 0.5 , or, if after 4 cycles, the relative score was ≤ 0.24 . This correlated with improved event-free survival. In 90 patients treated with dose-intensive therapy since diagnosis, Kushner et al. (32) found that the use of MIBG scintigraphy increased the recognition of minimal residual disease from 15.5% to 20%.

MIBG THERAPY

^{131}I -MIBG has been used as a therapeutic agent in neuroblastoma in Europe and in a few centers in the United States (31). ^{131}I -MIBG is suitable for targeted radiotherapy, because its uptake is tissue specific and a prolonged intracellular concentration is maintained at tumor sites in contrast to normal tissues. There are several published reports on ^{131}I -MIBG therapy for pheochromocytoma in adults; however, data in children are quite limited (33,34).

In treating neuroblastoma, ^{131}I -MIBG is currently used either as a single agent in progressive or recurrent neuroblastoma after conventional therapy or more recently in

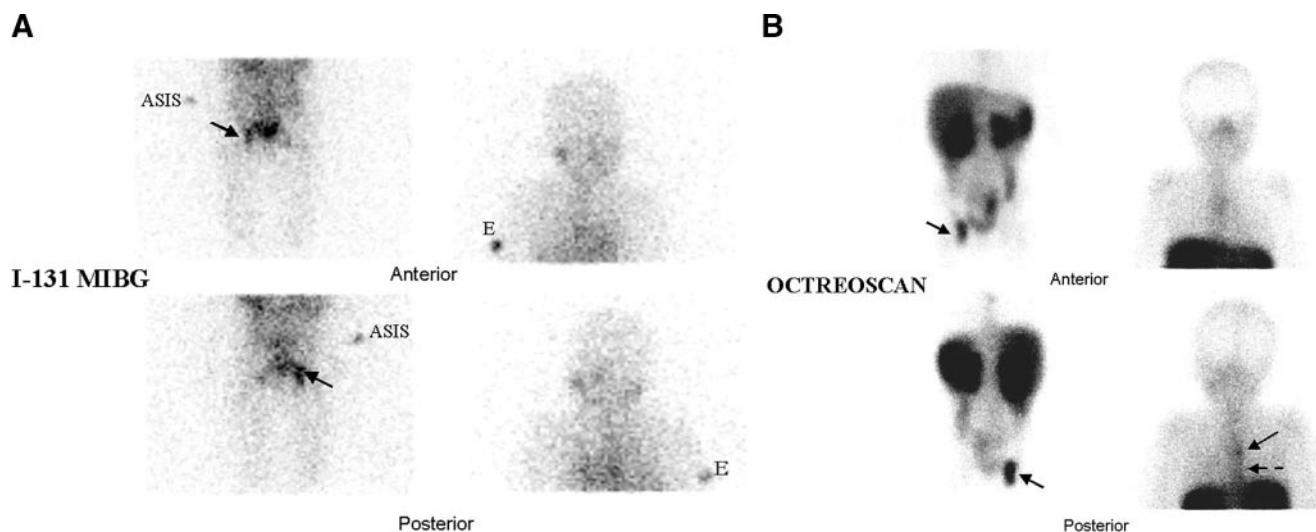


FIGURE 2. ^{131}I -MIBG and ^{111}In -DTPA-octreotide images of a patient with neuroblastoma. Patient, complaining of right hip pain, was imaged for recurrence 1 y after chemotherapy and bone marrow transplant. (A) ^{131}I -MIBG showed abnormal uptake in right hip (arrow). Markers at level of elbow (E) and anterior superior iliac spine (ASIS). No abnormal uptake of ^{131}I -MIBG noted in spine. (B) ^{111}In -DTPA-octreotide showed abnormal uptake in right hip (arrow), diffuse uptake in marrow of thoracic and lumbar spine (dashed arrow), and focal uptake in midthoracic spine (arrow). Bone marrow biopsy confirmed recurrent disease. MR imaging showed increased enhancement posterior to right acetabulum.

combination with myeloablative therapy before autologous bone marrow transplantation (ABMT). ^{131}I -MIBG therapy has also been used preoperatively at the start of treatment protocol for inoperable stage III and IV disease and in combination with hyperbaric oxygen therapy (35–39).

Single-Agent ^{131}I -MIBG Therapy for Progressive or Recurrent Neuroblastoma

Single-agent ^{131}I -MIBG therapy has been administered to children with recurrent or metastatic neuroblastoma failing conventional therapy since the mid 1980s (40). In a phase II study in The Netherlands, 53 patients (49 children, aged 1–12 y, and 4 adults, aged 22–27 y) received a fixed dose of 100–200 mCi of ^{131}I -MIBG. Objective response was seen in 56% (7 complete and 23 partial responses). An impressive palliative effect was also noted (41). In a German multicenter study involving 47 patients, 112 treatment courses were administered. The mean ^{131}I -MIBG dose was 8.8 ± 6.66 mCi/kg. Objective response was seen in 47% (9 complete and 13 partial responses) (42). Matthay et al. (43) treated 11 patients with refractory neuroblastoma with 100–400 mCi/m²/course and noted 2 patients with partial responses and 2 patients with stable disease. A phase I dose-escalation study of 30 patients with advanced neuroblastoma showed that 80% of patients who received 12 or more mCi/kg experienced grade 4 thrombocytopenia or neutropenia. Dose-limiting hematologic toxicity was reached at 15 mCi/kg. One patient developed secondary leukemia, and 3 became hypothyroid. Responses were seen in 37% of patients, with 1 complete response, 10 partial responses, 3 mixed responses, 10 with stable disease, and 6 with progressive disease. The minimum dose for the 10 of 11 responders was 12 mCi/kg (44). Weiss et al. (45) pub-

lished a report of 3 patients who developed secondary myelodysplasia/leukemia after ^{131}I -MIBG therapy. Hematologic toxicity was again documented in a recent phase I/II study using ^{131}I -MIBG at 18 mCi/kg (46). Of 53 patients, 70% experienced neutropenia, 91% required red cell transfusions, and 96% required platelet transfusion. Autologous stem cell reconstitution was required in 19 patients, and, thus, the current phase II protocol requires the availability of stem cells before beginning therapy.

^{131}I -MIBG Therapy as a Component of Multiagent Chemotherapy

In an attempt to improve survival of patients with metastatic/refractory neuroblastoma ^{131}I -MIBG has been used in combination with multiagent chemotherapy. Corbett et al. (47) treated 5 patients with ^{131}I -MIBG followed by high-dose therapy and ABMT 14–32 d later. Two children relapsed and died, 1 died of septicemia, and 2 are alive at 17 and 41 mo after ABMT. Gaze et al. (48) combined ^{131}I -MIBG with high-dose chemotherapy and total body irradiation. Of 5 patients, 1 was alive without relapse at 32 mo, and 4 patients relapsed. Klingebiel et al. (49) treated 11 children, after induction therapy with ^{131}I -MIBG and high-dose chemotherapy, with peripheral blood stem cell transplant support followed by anti-GD2 antibody. Three patients achieved a complete response, and 1 experienced a partial response. Yanik et al. (50) treated 12 patients (5 after relapse, 7 after induction chemotherapy). All patients received MIBG followed by melphalan, carboplatin, etoposide, and ABMT. Of the 8 patients with metastatic disease, 3 achieved complete remission and 2 achieved partial remission with acceptable toxicity.

¹³¹I-MIBG Therapy at Diagnosis

Preoperative ¹³¹I-MIBG therapy has been used in children presenting with advanced/inoperable neuroblastoma, with an objective of reducing tumor volume to enable surgical resection without inducing early drug resistance and toxicity (36,38). De Kraker et al. (35) reported results in 33 patients with untreated advanced-stage neuroblastoma treated with preoperative ¹³¹I-MIBG. There were 18 partial responses and 1 complete response; 11 patients experienced stable disease, and 3 had progressive disease. Twenty-one patients underwent surgery, and 17 of these had tumor resection of more than 95%. Mastrangelo et al. (37) treated 3 patients with stage III neuroblastoma and described the complete disappearance of tumor in 1 patient and significant reduction in the other 2.

MIBG AND ¹¹¹IN-DTPA-OCTREOTIDE

Procedure guidelines for ¹¹¹In-diethylenetriaminepentaacetic acid (DTPA)-octreotide scintigraphy in children outlining patient preparation, imaging protocol, and clinical applications have been published (51). In children, several studies have compared MIBG with ¹¹¹In-DTPA-octreotide scintigraphy for imaging of neuroblastoma (Table 1) (52–55). The sensitivity of ¹¹¹In-DTPA-octreotide scintigraphy ranged from 55% to 70% compared with 83% to 94% for MIBG scintigraphy. However, the majority of studies compared ¹¹¹In-DTPA-octreotide with ¹²³I-MIBG scintigraphy, with only 1 study comparing it with the more readily available ¹³¹I-MIBG scintigraphy. Most of these studies used only planar imaging for ¹¹¹In-DTPA-octreotide scintigraphy, thus reducing the sensitivity of the study. Figure 1 compares ¹³¹I-MIBG scintigraphy with ¹¹¹In-DTPA-octreotide scintigraphy in 2 patients with neuroblastoma at our institution. The recent introduction of SPECT/CT has greatly improved the sensitivity of ¹¹¹In-DTPA-octreotide scintigraphy in our limited studies (56,60). Figures 1 and 2 demonstrate the sensitivity of ¹¹¹In-DTPA-octreotide compared with ¹³¹I-MIBG in neuroblastoma. Several of the studies cited here also showed that positive ¹¹¹In-DTPA-octreotide scintigraphy correlated with a more favorable clinical outcome (53–55).

Studies have evaluated the correlation of somatostatin 2 (SST2) expression with survival. Two independent groups

found that high levels of SST2 receptor expression correlated with a better survival, independent of N-Myc amplification, and that in vitro SST2 gene expression was positively related to in vivo determination of SST2 receptors by ¹¹¹In-DTPA-octreotide scintigraphy (57,58). Schilling et al. (59) found that SST2 receptor expression was related to genetic features, which correlated with prognosis. This group found that no tumor with 1p 36 deletion and di/tetra DNA content showed SST2 expression. Juweid et al. (60) compared bone scintigraphy with ¹¹¹In-DTPA-octreotide scintigraphy and found that ¹¹¹In-DTPA-octreotide scintigraphy was positive in only 1 of 9 patients. Overall, ¹¹¹In-DTPA-octreotide scintigraphy showed a greater number of bone metastases (30 versus 7). The conclusion from these studies is that ¹²³I-MIBG scintigraphy is more sensitive than ¹¹¹In-DTPA-octreotide scintigraphy for neuroblastoma. However, ¹¹¹In-DTPA-octreotide scintigraphy yields prognostic information and is as sensitive as ¹³¹I-MIBG in detecting metastatic disease.

Central nervous system tumors in childhood can also be characterized using ¹¹¹In-DTPA-octreotide scintigraphy. Early studies suggested that the integrity of the blood–brain barrier (not SST2 expression) was the primary determinant in whether or not any brain tumor was visualized using ¹¹¹In-DTPA-octreotide scintigraphy (61). These authors concluded that although both gliomas and meningiomas express SST2, meningiomas are ¹¹¹In-DTPA-octreotide-positive because they are outside the blood–brain barrier. Subsequent investigations demonstrated SST2 receptors by immunohistochemistry on gliomas of all grades, I–IV, but ¹¹¹In-DTPA-octreotide scintigraphy was positive only in higher grade tumors in which the blood–brain barrier was disrupted as evidenced by ^{99m}Tc-DTPA uptake (62). Other investigators have also concluded that although nearly all gliomas express somatostatin receptors, only high-grade gliomas with associated blood–brain barrier disruption have significant uptake of ¹¹¹In-DTPA-octreotide (63). ¹¹¹In-DTPA-octreotide was useful, however, in differentiating glioma from medulloblastoma and in differentiating recurrent meningioma from scar tissue (63,64). The observation that medulloblastoma, which is quite rare in adults, could be distinguished from glioma using a nonsurgical technique prompted investigations of ¹¹¹In-DTPA-octreotide in diag-

TABLE 1
Results of Studies Comparing ¹¹¹In-DTPA-Octreotide Scintigraphy with MIBG Scintigraphy for Neuroblastoma*

Authors (reference)	Radionuclides	Patients	Sensitivity	
			MIBG	¹¹¹ In-DTPA-octreotide
Limouris et al. (53)	¹²³ I-MIBG and ¹¹¹ In-DTPA	7	83%	55%
Shalaby Rana et al. (54)	¹³¹ I-MIBG and ¹¹¹ In-DTPA	7	86%	57%
Kropp et al. (55)	¹²³ I-MIBG and ¹¹¹ In-DTPA	22	85%	70%
Schilling et al. (56)	¹²³ I-MIBG and ¹¹¹ In-DTPA	88	94%	64%

*No ¹¹¹In-DTPA-octreotide SPECT imaging was performed in these studies.

nosis and follow-up of pediatric brain tumors. Medulloblastoma is one of the most common brain tumors in children, and its high expression of somatostatin receptors allows it to be distinguished from pilocytic astrocytoma, the most frequent glioma in children (65). Medulloblastoma is considered to be a primitive neuroectodermal tumor (PNET), and it is similar on histologic examination to supratentorial PNET. Not surprisingly, the supratentorial PNET has also been demonstrated to express high levels of SST2 (66). ^{111}In -DTPA-octreotide scintigraphy is a very sensitive technique for follow-up of both medulloblastoma and supratentorial PNET, in some cases identifying early recurrence before either clinical symptoms are reported or tumor growth is observed on MR imaging (65,66).

A phase I trial in children with refractory solid tumors that are somatostatin receptor-positive as evidenced by positive ^{111}In -DTPA-octreotide scan is currently ongoing in the United States. While awaiting FDA approval of ^{90}Y -1,4,7,10-tetraazacyclododecane- N,N',N'',N''' -tetraacetic acid (DOTA)-Tyr³-octreotide (DOTATOC) for treatment of somatostatin receptor-expressing malignancies in the United States, this innovative treatment is available in only 3 institutions: Erasmus University (Rotterdam, The Netherlands), the University of Basel (Switzerland), and the University of Iowa (Iowa City; for children only). The pediatric trial is a dose-escalation trial beginning at 30 mCi/m² and is enrolling children with any ^{111}In -DTPA-octreotide-positive tumor, including brain tumors. In Basel, brain tumors are being treated with intratumoral injection of ^{90}Y -DOTATOC, thus eliminating the potential problem of blood-brain barrier penetration and also decreasing the radiation dose to the kidneys (67). It is hoped that early success in treatment of neuroendocrine tumors with ^{90}Y -DOTATOC as a single agent will be followed shortly by incorporation of this molecular-targeted therapy into combination therapies that will provide cures for patients with these enigmatic malignancies.

CONCLUSION

Both ^{111}In -DTPA-octreotide and ^{123}I -MIBG are sensitive indicators of neural crest tumors. ^{111}In -DTPA-octreotide is the best initial procedure in carcinoid, gastroenteropancreatic neuroendocrine tumors, and paraganglioma, whereas ^{123}I -MIBG scintigraphy (when it is available) remains the best initial procedure for pheochromocytoma and malignant paraganglioma. ^{111}In -DTPA-octreotide scintigraphy is an extremely sensitive technique for pediatric brain tumors, especially medulloblastoma and supratentorial PNET.

Neuroblastoma can be imaged by either ^{111}In -DTPA-octreotide or MIBG, depending on local expertise. ^{111}In -DTPA-octreotide scintigraphy correlates with prognosis in neuroblastoma, suggesting a complementary role for both tracers in initial diagnostic workup.

^{131}I -MIBG therapy is effectively used for the treatment of several neural crest tumors. ^{90}Y -DOTATOC therapy for

neural crest tumors and neuroepithelial tumors of the central nervous system (CNS) has been introduced in the last several years. It is available in Europe for treatment of adult neuroendocrine tumors and selected CNS tumors. A phase I trial of ^{90}Y -DOTATOC (or Tyr³) in childhood malignancies is ongoing in the United States.

REFERENCES

1. Brodeur GM, Maris JM. Neuroblastoma. In: Pizzo PA, Poplack DG, eds. *Principles and Practice of Pediatric Oncology*. Philadelphia, PA: Lippincott Williams & Wilkins; 2001:895–937.
2. Brodeur GM, Pritchard J, Berthold F, et al. Revisions of the international criteria for neuroblastoma diagnosis, staging, and response to treatment. *J Clin Oncol*. 1993;11:1466–1477.
3. Koch CA, Pacak K, Chrousos GP. Endocrine tumors. In: Pizzo PA, Poplack DG, eds. *Principles and Practice of Pediatric Oncology*. Philadelphia, PA: Lippincott Williams & Wilkins; 2001:1115–1148.
4. Wieland DM, Swanson DP, Brown LE, Beierwaltes WH. Imaging the adrenal medulla with an I-131-labeled antiadrenergic agent. *J Nucl Med*. 1979;20:155–158.
5. Jaques S Jr, Tobes MC, Sisson JC, Baker JA, Wieland DM. Comparison of the sodium dependency of uptake of meta-iodobenzylguanidine and norepinephrine into cultured bovine adrenomedullary cells. *Mol Pharmacol*. 1984;26:539–546.
6. Smets LA, Loesberg C, Janssen M, Metwally EA, Huiskamp R. Active uptake and extravesicular storage of m-iodobenzylguanidine in human neuroblastoma SK-N-SH cells. *Cancer Res*. 1989;49:2941–2944.
7. Smets LA, Janssen M, Metwally E, Loesberg C. Extragranular storage of the neuron blocking agent meta-iodobenzylguanidine (MIBG) in human neuroblastoma cells. *Biochem Pharmacol*. 1990;39:1959–1964.
8. Sisson JC, Frager MS, Valk TW, et al. Scintigraphic localization of pheochromocytoma. *N Engl J Med*. 1981;305:12–17.
9. Geatti O, Shapiro B, Sisson JC, et al. Iodine-131 metaiodobenzylguanidine scintigraphy for the location of neuroblastoma: preliminary experience in ten cases [abstract]. *J Nucl Med*. 1985;26:736–742.
10. Shulkin BL, Shapiro B. Current concepts on the diagnostic use of MIBG in children. *J Nucl Med*. 1998;39:679–688.
11. Olivier P, Colarinha P, Fettich J, Fischer S, et al. Guidelines for radioiodinated MIBG scintigraphy in children. *Eur J Nucl Med Mol Imaging*. 2003;30:B45–B50.
12. Miller L. Food and Drug Administration grants approval for ^{131}I -MIBG. *J Nucl Med*. 1994;35:13N–17N.
13. Nakatani T, Hayama T, Uchida J, Nakamura K, Takemoto Y, Sugimura K. Diagnostic localization of extra-adrenal pheochromocytoma: comparison of (123)I-MIBG imaging and (131)I-MIBG imaging. *Oncol Rep*. 2002;9:1225–1227.
14. Khafagi FA, Shapiro B, Fig LM, Mallette S, Sisson JC. Labetalol reduces iodine-131 MIBG uptake by pheochromocytoma and normal tissues. *J Nucl Med*. 1989;30:481–489.
15. Hoefnagel CA. Metaiodobenzylguanidine and somatostatin in oncology: role in the management of neural crest tumours. *Eur J Nucl Med*. 1994;21:561–581.
16. van Santen HM, de Kraker J, van Eck BL, de Vijlder JJ, Vulsma T. Improved radiation protection of the thyroid gland with thyroxine, methimazole, and potassium iodide during diagnostic and therapeutic use of radiolabeled metaiodobenzylguanidine in children with neuroblastoma. *Cancer*. 2003;98:389–396.
17. Lumbroso J, Giammarile F, Hartmann O, Bonnin F, Parmentier C. Upper clavalicular and cardiac meta-[^{123}I]iodobenzylguanidine uptake in children. *Q J Nucl Med*. 1995;39(suppl):17–20.
18. Bonnin F, Lumbroso J, Tenenbaum F, Hartmann O, Parmentier C. Refining interpretation of MIBG scans in children. *J Nucl Med*. 1994;35:803–810.
19. Nakajo M, Shapiro B, Copp J, et al. The normal and abnormal distribution of the adrenomedullary imaging agent m-[I-131]iodobenzylguanidine (I-131 MIBG) in man: evaluation by scintigraphy. *J Nucl Med*. 1983;24:672–682.
20. Gelfand MJ. Meta-iodobenzylguanidine in children. *Semin Nucl Med*. 1993;23:231–242.
21. Lumbroso JD, Guermazi F, Hartmann O, et al. Meta-iodobenzylguanidine (mIBG) scans in neuroblastoma: sensitivity and specificity, a review of 115 scans. *Prog Clin Biol Res*. 1988;271:689–705.
22. Parisi MT, Greene MK, Dykes TM, Moraldo TV, Sandler ED, Hattner RS. Efficacy of metaiodobenzylguanidine as a scintigraphic agent for the detection of neuroblastoma. *Invest Radiol*. 1992;27:768–773.
23. Perel Y, Conway J, Kletzel M, et al. Clinical impact and prognostic value of

- metaiodobenzylguanidine imaging in children with metastatic neuroblastoma. *J Pediatr Hematol Oncol.* 1999;21:13–18.
24. Claudiani F, Stimamiglio P, Bertolazzi L, et al. Radioiodinated meta-iodobenzylguanidine in the diagnosis of childhood neuroblastoma. *Q J Nucl Med.* 1995;39(suppl):21–24.
 25. Gordon I, Peters AM, Gutman A, Morony S, Dicks-Mireaux C, Pritchard J. Skeletal assessment in neuroblastoma—the pitfalls of iodine-123-MIBG scans. *J Nucl Med.* 1990;31:129–134.
 26. Shulkin BL, Shapiro B, Hutchinson RJ. Iodine-131-metaiodobenzylguanidine and bone scintigraphy for the detection of neuroblastoma. *J Nucl Med.* 1992;33:1735–1740.
 27. Hadj-Djilani NL, Lebtahi NE, Delaloye AB, Laurini R, Beck D. Diagnosis and follow-up of neuroblastoma by means of iodine-123 metaiodobenzylguanidine scintigraphy and bone scan, and the influence of histology. *Eur J Nucl Med.* 1995;22:322–329.
 28. Osmanagaoglu K, Lippens M, Benoit Y, Obrie E, Schelstraete K, Simons M. A comparison of iodine-123 meta-iodobenzylguanidine scintigraphy and single bone marrow aspiration biopsy in the diagnosis and follow-up of 26 children with neuroblastoma. *Eur J Nucl Med.* 1993;20:1154–1160.
 29. Suc A, Lumbroso J, Rubie H, et al. Metastatic neuroblastoma in children older than one year: prognostic significance of the initial metaiodobenzylguanidine scan and proposal for a scoring system. *Cancer.* 1996;77:805–811.
 30. Ady N, Zucker JM, Asselain B, et al. A new ¹²³I-MIBG whole body scan scoring method—application to the prediction of the response of metastases to induction chemotherapy in stage IV neuroblastoma. *Eur J Cancer.* 1995;31A:256–261.
 31. Matthay KK, Edeline V, Lumbroso J, et al. Correlation of early metastatic response by ¹²³I-metaiodobenzylguanidine scintigraphy with overall response and event-free survival in stage IV neuroblastoma. *J Clin Oncol.* 2003;21:2486–2491.
 32. Kushner BH, Yeh SD, Kramer K, Larson SM, Cheung NK. Impact of metaiodobenzylguanidine scintigraphy on assessing response of high-risk neuroblastoma to dose-intensive induction chemotherapy. *J Clin Oncol.* 2003;21:1082–1086.
 33. Troncone L, Rufini V, Montemaggi P, Danza FM, Lasorella A, Mastrangelo R. The diagnostic and therapeutic utility of radioiodinated metaiodobenzylguanidine (MIBG). 5 years of experience. *Eur J Nucl Med.* 1990;16:325–335.
 34. Rose B, Matthay KK, Price D, et al. High-dose ¹³¹I-metaiodobenzylguanidine therapy for 12 patients with malignant pheochromocytoma. *Cancer.* 2003;98:239–248.
 35. De Kraker J, Hoefnagel CA, Caron H, et al. First line targeted radiotherapy, a new concept in the treatment of advanced stage neuroblastoma. *Eur J Cancer.* 1995;31A:600–602.
 36. Hoefnagel CA, de Kraker J, Valdes Olmos RA, Voute PA. ¹³¹I-MIBG as a first-line treatment in high-risk neuroblastoma patients. *Nucl Med Commun.* 1994;15:712–717.
 37. Mastrangelo R, Lasorella A, Lavarone A, et al. Critical observations on neuroblastoma treatment with ¹³¹I-metaiodobenzylguanidine at diagnosis. *Med Pediatr Oncol.* 1993;21:411–415.
 38. Hoefnagel CA, de Kraker J, Voute PA, Valdes Olmos RA. Preoperative ¹³¹I-metaiodobenzylguanidine therapy of neuroblastoma at diagnosis (“MIBG de novo”). *J Nucl Biol Med.* 1991;35:248–251.
 39. Voute PA, van der Kleij AJ, de Kraker J, Hoefnagel CA, Tiel-van Buul MM, Van Gennip H. Clinical experience with radiation enhancement by hyperbaric oxygen in children with recurrent neuroblastoma stage IV. *Eur J Cancer.* 1995;31A:596–600.
 40. Hoefnagel CA, Voute PA, de Kraker J, Marcuse HR. Radionuclide diagnosis and therapy of neural crest tumors using iodine-131 metaiodobenzylguanidine. *J Nucl Med.* 1987;28:308–314.
 41. Hoefnagel CA, Voute PA, de Kraker J, Valdes Olmos RA. ¹³¹I-metaiodobenzylguanidine therapy after conventional therapy for neuroblastoma. *J Nucl Biol Med.* 1991;35:202–206.
 42. Klingebiel T, Berthold F, Treuner J, et al. Metaiodobenzylguanidine (mIBG) in treatment of 47 patients with neuroblastoma: results of the German Neuroblastoma Trial. *Med Pediatr Oncol.* 1991;19:84–88.
 43. Matthay KK, Huberty JP, Hattner RS, et al. Efficacy and safety of ¹³¹I-metaiodobenzylguanidine therapy for patients with refractory neuroblastoma. *J Nucl Biol Med.* 1991;35:244–247.
 44. Matthay KK, DeSantes K, Hasegawa B, et al. Phase I dose escalation of ¹³¹I-metaiodobenzylguanidine with autologous bone marrow support in refractory neuroblastoma. *J Clin Oncol.* 1998;16:229–236.
 45. Weiss B, Vora A, Huberty J, Hawkins RA, Matthay KK. Secondary myelodysplastic syndrome and leukemia following ¹³¹I-metaiodobenzylguanidine therapy for relapsed neuroblastoma. *J Pediatr Hematol Oncol.* 2003;25:543–547.
 46. DuBois SG, Messina J, Maris JM, et al. Hematologic toxicity of high-dose iodine-131-metaiodobenzylguanidine therapy for advanced neuroblastoma. *J Clin Oncol.* 2004;22:2452–2460.
 47. Corbett R, Pinkerton R, Tait D, Meller S. ¹³¹I-metaiodobenzylguanidine and high-dose chemotherapy with bone marrow rescue in advanced neuroblastoma. *J Nucl Biol Med.* 1991;35:228–231.
 48. Gaze MN, Wheldon TE, O'Donoghue JA, et al. Multi-modality megatherapy with ¹³¹I-meta-iodobenzylguanidine, high-dose melphalan and total body irradiation with bone marrow rescue: feasibility study of a new strategy for advanced neuroblastoma. *Eur J Cancer.* 1995;31A:252–256.
 49. Klingebiel T, Bader P, Bares R, et al. Treatment of neuroblastoma stage 4 with ¹³¹I-meta-iodo-benzylguanidine, high-dose chemotherapy and immunotherapy: a pilot study. *Eur J Cancer.* 1998;34:1398–1402.
 50. Yanik GA, Levine JE, Matthay KK, et al. Pilot study of iodine-131-metaiodobenzylguanidine in combination with myeloablative chemotherapy and autologous stem-cell support for the treatment of neuroblastoma. *J Clin Oncol.* 2002;20:2142–2149.
 51. Balon HR, Goldsmith SJ, Siegel BA, et al. Procedure guideline for somatostatin receptor scintigraphy with (111)In-pentetreotide. *J Nucl Med.* 2001;42:1134–1138.
 52. Limouris GS, Giannakopoulos V, Stavraka A, Toubanakis N, Vlahos L. Comparison of In-111 pentetreotide, Tc-99m (V)DMSA and I-123 mIBG scintigraphy in neural crest tumors. *Anticancer Res.* 1997;17:1589–1592.
 53. Shalaby-Rana E, Majd M, Andrich MP, Movassaghi N. In-111 pentetreotide scintigraphy in patients with neuroblastoma. Comparison with I-131 MIBG, N-Myc oncogene amplification, and patient outcome. *Clin Nucl Med.* 1997;22:315–319.
 54. Kropp J, Hofmann M, Bihl H. Comparison of MIBG and pentetreotide scintigraphy in children with neuroblastoma. Is the expression of somatostatin receptors a prognostic factor? *Anticancer Res.* 1997;17:1583–1588.
 55. Schilling FH, Bihl H, Jacobsson H, et al. Combined (111)In-pentetreotide scintigraphy and (123)I-mIBG scintigraphy in neuroblastoma provides prognostic information. *Med Pediatr Oncol.* 2000;35:688–691.
 56. Krausz Y, Keidar Z, Kogan I, et al. SPECT/CT hybrid imaging with ¹¹¹In-pentetreotide in assessment of neuroendocrine tumours. *Clin Endocrinol (Oxf).* 2003;59:565–573.
 57. Orlando C, Raggi CC, Bagnoni L, et al. Somatostatin receptor type 2 gene expression in neuroblastoma, measured by competitive RT-PCR, is related to patient survival and to somatostatin receptor imaging by indium-111-pentetreotide. *Med Pediatr Oncol.* 2001;36:224–226.
 58. Briganti V, Sestini R, Orlando C, et al. Imaging of somatostatin receptors by indium-111-pentetreotide correlates with quantitative determination of somatostatin receptor type 2 gene expression in neuroblastoma tumors. *Clin Cancer Res.* 1997;3:2385–2391.
 59. Schilling FH, Ambros PF, Bihl H, et al. Absence of somatostatin receptor expression in vivo is correlated to di- or tetraploid 1p36-deleted neuroblastomas. *Med Pediatr Oncol.* 2001;36:56–60.
 60. Juweid ME, Menda Y, O'Dorisio MS, et al. ¹¹¹In-pentetreotide versus bone scintigraphy in the detection of bony metastases of neuroblastoma. *Nucl Med Commun.* 2002;23:983–989.
 61. Haldemann AR, Rosler H, Barth A, et al. Somatostatin receptor scintigraphy in central nervous system tumors: role of blood-brain barrier permeability. *J Nucl Med.* 1995;36:403–410.
 62. Luyken C, Hildebrandt G, Scheidhauer K, Krisch B, Schicha H, Klug N. 111-Indium (DTPA-octreotide) scintigraphy in patients with cerebral gliomas. *Acta Neurochir (Wien).* 1994;127:60–64.
 63. Schmidt M, Scheidhauer K, Luyken C, et al. Somatostatin receptor imaging in intracranial tumours. *Eur J Nucl Med.* 1998;25:675–686.
 64. Cervera P, Videau C, Viollet C, et al. Comparison of somatostatin receptor expression in human gliomas and medulloblastomas. *J Neuroendocrinol.* 2002;14:458–471.
 65. Muller HL, Fruhwald MC, Scheubeck M, et al. A possible role for somatostatin receptor scintigraphy in the diagnosis and follow-up of children with medulloblastoma. *J Neurooncol.* 1998;38:27–40.
 66. Fruhwald MC, Rickert C, O'Dorisio MS, et al. Somatostatin receptor subtype (sst2) is expressed by supratentorial primitive neuroectodermal tumors (stPNETs) of childhood and can be targeted for somatostatin receptor imaging (SRI). *J Clin Oncol.* 2004;10:2997–3006.
 67. Held-Feindt J, Forstreuter F, Pufe T, Mentlein R. Influence of the somatostatin receptor sst2 on growth factor signal cascades in human glioma cells. *Brain Res Mol Brain Res.* 2001;87:12–21.



The Journal of
NUCLEAR MEDICINE

MIBG and Somatostatin Receptor Analogs in Children: Current Concepts on Diagnostic and Therapeutic Use

Farzana D. Pashankar, M. Sue O'Dorisio and Yusuf Menda

J Nucl Med. 2005;46:55S-61S.

This article and updated information are available at:
http://jnm.snmjournals.org/content/46/1_suppl/55S

Information about reproducing figures, tables, or other portions of this article can be found online at:
<http://jnm.snmjournals.org/site/misc/permission.xhtml>

Information about subscriptions to JNM can be found at:
<http://jnm.snmjournals.org/site/subscriptions/online.xhtml>

The Journal of Nuclear Medicine is published monthly.
SNMMI | Society of Nuclear Medicine and Molecular Imaging
1850 Samuel Morse Drive, Reston, VA 20190.
(Print ISSN: 0161-5505, Online ISSN: 2159-662X)

© Copyright 2005 SNMMI; all rights reserved.