

# Patterns of Lymphatic Drainage from the Skin in Patients with Melanoma\*

Roger F. Uren, MD<sup>1-3</sup>; Robert Howman-Giles, MD<sup>1-3</sup>; and John F. Thompson, MD<sup>3,4</sup>

<sup>1</sup>Nuclear Medicine and Diagnostic Ultrasound, RPAH Medical Centre, Sydney, New South Wales, Australia; <sup>2</sup>Department of Medicine, University of Sydney, Sydney, New South Wales, Australia; <sup>3</sup>Sydney Melanoma Unit, Royal Prince Alfred Hospital, Camperdown, New South Wales, Australia; and <sup>4</sup>Department of Surgery, University of Sydney, Sydney, New South Wales, Australia

An essential prerequisite for a successful sentinel lymph node biopsy (SLNB) procedure is an accurate map of the pattern of lymphatic drainage from the primary tumor site in each patient. In melanoma patients, mapping requires high-quality lymphoscintigraphy, which can identify the actual lymphatic collecting vessels as they drain into the sentinel lymph nodes. Small-particle radiocolloids are needed to achieve this goal, and imaging protocols must be adapted to ensure that all true sentinel nodes, including those in unexpected locations, are found in every patient. Clinical prediction of lymphatic drainage from the skin is not possible. The old clinical guidelines based on Sappey's lines therefore should be abandoned. Patterns of lymphatic drainage from the skin are highly variable from patient to patient, even from the same area of the skin. Unexpected lymphatic drainage from the skin of the back to sentinel nodes in the triangular intermuscular space and, in some patients, through the posterior body wall to sentinel nodes in the para-aortic, paravertebral, and retroperitoneal areas has been found. Lymphatic drainage from the head and neck frequently involves sentinel nodes in multiple node fields and can occur from the base of the neck up to nodes in the occipital or upper cervical areas or from the scalp down to nodes at the neck base, bypassing many node groups. The sentinel node is not always found in the nearest node field and is best defined as "any lymph node receiving direct lymphatic drainage from a primary tumor site." Lymphatic drainage can occur from the upper limb to sentinel nodes above the axilla. Drainage to the epitrochlear region from the hand and arm as well as to the popliteal region from the foot and leg is more common than was previously thought. Interval nodes, which lie along the course of a lymphatic vessel between a lesion site and a recognized node field, are not uncommon, especially in the trunk. Drainage across the midline of the body is quite common in the trunk and in the head and neck. Micrometastatic disease can be present in any sentinel node regardless of its location, and for the SLNB technique to be accurate, all true sentinel nodes must be biopsied in every patient.

**Key Words:** lymphatic drainage; skin melanoma

**J Nucl Med 2003; 44:570–582**

**T**his article has been prepared to complement the review of sentinel lymph node biopsy (SLNB) in melanoma written by Mariani et al. (1) and published in 2002. That review provided a detailed account of the technical aspects of SLNB in melanoma. In this article, we concentrate on the common and less common patterns of lymphatic drainage that are seen in melanoma patients. It is critically important for any unexpected drainage pattern to be detected in every such patient for the SLNB method to be accurate.

## LYMPHATIC MAPPING OF THE SKIN

Lymphatic mapping of the skin has been studied for several centuries. When Sappey published an elegant and comprehensive atlas in 1874, many believed that there was little more to discover on this topic (2). Sappey defined demarcation lines that passed down the midline front and back, along a horizontal line around the waist at the level of the umbilicus anteriorly, and to the level of the L2 vertebra posteriorly. It was Sappey's firm view that lymph channels did not cross these lines and that prediction of the direction of lymphatic drainage from the skin was quite simple if these rules were followed. Most clinicians were comfortable with this system, and it was followed in clinical practice for almost 100 y.

After the development of lymphoscintigraphy in the 1950s (3), however, interest in studying patterns of lymphatic drainage in patients with melanomas was rekindled. Researchers observed that Sappey's rules did not always prove to be correct (4,5). They found that there were "zones of ambiguity" close to Sappey's lines at which prediction of the direction of lymphatic drainage was not possible. This finding led to the concept that within a 10-cm region straddling Sappey's lines, lymphatic drainage was uncertain.

With this knowledge, clinicians began to use lymphoscintigraphy in patients with melanomas located in these ambiguous areas to identify lymph node fields that received

Received May 20, 2002; revision accepted Sep. 25, 2002.

For correspondence or reprints contact: Roger F. Uren, MD, Suite 206, RPAH Medical Centre, 100 Carillon Ave., Newtown, New South Wales 2042, Australia.

E-mail: [ruen@mail.usyd.edu.au](mailto:ruen@mail.usyd.edu.au)

\*NOTE: FOR CE CREDIT, YOU CAN ACCESS THIS ACTIVITY THROUGH THE SNM WEB SITE ([http://www.snm.org/education/ce\\_online.html](http://www.snm.org/education/ce_online.html)) THROUGH APRIL 2004.

lymphatic drainage before elective dissection (6–10). These were patients with melanomas near the midline, around the waist, and in the head and neck. The method proved very accurate in this role, and nodal recurrences rarely were seen outside the fields identified by lymphatic mapping.

The description by Morton and colleagues of the SLNB technique with blue dye injections for patients with melanomas (11) prompted others to search for simpler alternative approaches. Alex et al. (12) and Krag et al. (13) adapted the technique of Morton et al. by using a radiocolloid to label the sentinel node so that it could be found with a  $\gamma$ -detection probe. Lymphoscintigraphy was also quickly adapted to locate the sentinel node and thus became an important and integral part of the procedure (14). At present, preoperative lymphoscintigraphy is a routine part of the SLNB method practiced in most major centers. It is combined with blue dye injection before surgery and a  $\gamma$ -detection probe intraoperatively.

There is general agreement that this combination is the most accurate way to identify all true sentinel nodes in every patient. If the sentinel node is located accurately, then the benefits of SLNB, such as minimal surgery with low morbidity, will follow.

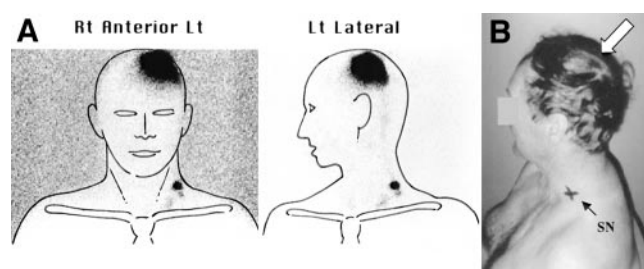
This approach, when combined with a more detailed histologic examination of sentinel nodes (15), will have a significant impact on staging patients with melanomas and ultimately may aid in the development of better therapies for patients who are truly node positive or node negative. It is quite possible that, in the past, many patients thought to be node negative were in fact node positive but that the true sentinel node was missed.

## SENTINEL NODE

“A sentinel lymph node is any lymph node which receives lymph drainage directly from a tumor site” (16).

A sentinel node is not just the first node seen on dynamic imaging, because there may be multiple separate lymph channels that have different rates of lymph flow. If these channels drain to different nodes, then all of these nodes are sentinel nodes, regardless of the time taken for the lymph containing the radiocolloid to reach them. A sentinel node is also not necessarily the node closest to the primary site. Lymphatic vessels can bypass many nodes before reaching the sentinel node (Fig. 1).

The best way to identify a sentinel node on lymphoscintigraphy is therefore to visualize the lymphatic collecting vessel on dynamic imaging as it drains directly into the sentinel node (Fig. 2). In order to achieve this goal, there must be adequate numbers of radiocolloid particles in the lymph fluid during the early dynamic phase; small-particle radiocolloids therefore must be used. This lymphatic collecting vessel is the same one that the surgeon sees staining blue in the operative field during sentinel node surgery.



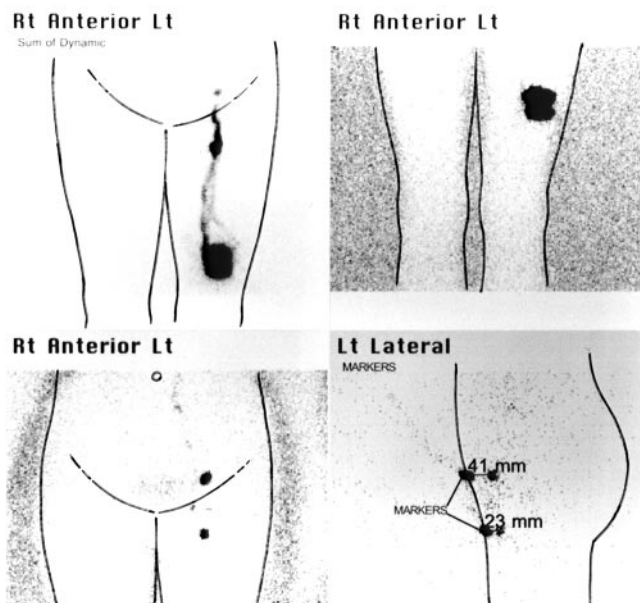
**FIGURE 1.** Patient with melanoma on vertex of scalp just to left of midline and lymphatic drainage down to left level V node at base of neck. (A) Lymphoscintigraphy findings on delayed imaging 2 h after injection of 7 MBq of  $^{99m}\text{Tc}$ -antimony sulfide colloid intradermally at 4 points around excision biopsy site. Anterior and left lateral views are shown, and lymphatic vessel can be faintly seen passing directly to sentinel node in left lateral view. Lt = left; Rt = right. (B) Patient at end of study. Sentinel node (SN) location is marked on skin with “X.” Injection site on scalp is indicated by thick arrow.

## LYMPHOSCINTIGRAPHY METHODS

Lymphoscintigraphy to locate sentinel lymph nodes in patients with melanomas involves the intradermal injection of a radiocolloid near the melanoma site or excision biopsy site (1,14). Injections of 5–10 MBq in a volume of 0.05–0.1 mL are used, and typically 4 injections are required, although the number of injections depends on the primary melanoma size. After tracer injection, dynamic imaging is performed to follow the course of the lymphatic collecting vessels until they reach the draining sentinel nodes. An image should be acquired as the vessels reach the node field so that sentinel nodes directly receiving the channels can be identified and distinguished from any second-tier nodes that may be seen. This phase of the study usually takes 10–20 min.

Delayed scans are performed 2–2.5 h later, at which time all regions that could possibly drain the primary melanoma site are examined with static images of 5–10 min. Appropriate lateral, posterior, oblique, or vertex views are also acquired as necessary to define the exact locations of all sentinel nodes. We routinely use a transmission source on all delayed images to highlight the body outline, and these images are especially useful for retrospective review of the images. We often repeat delayed scans without the transmission source, however, as in some patients a faint sentinel node in a new node field is obscured by the scattered activity from the source. Most of the images shown in this article were acquired without a transmission source for this reason, and the body outline was added later.

The surface locations of all sentinel nodes are marked on the overlying skin with an “X” of indelible ink; a permanent point tattoo of carbon black (Fig. 1) can also be applied and is a useful guide for clinical or ultrasound follow-up over subsequent years. The depth of the sentinel node from the skin mark is measured in an orthogonal view with a radioactive marker placed on the skin mark. The depth can then



**FIGURE 2.** Lymphoscintigraphy of patient with excision biopsy site on anterior left thigh above knee. Two lymphatic collecting vessels can be seen passing to left groin in 10-min summed dynamic image (top left). Medial channel can be seen draining to sentinel node in femoral area, whereas more lateral channel bypasses this node to reach another sentinel node higher in groin. Delayed images show these 2 bright sentinel nodes with faint second-tier activity between them. Depth of sentinel nodes beneath skin is shown in left lateral view with point source on skin marks (bottom right). Lt = left; Rt = right.

be measured from the film directly or by using electronic calipers. Some centers use a  $\gamma$ -probe in a nuclear medicine suite to further aid in the localization of sentinel nodes, but we have not found this procedure necessary. Regardless of how imaging data for a patient are presented to the surgeon, it is essential that the surgeon completely understands the presentation. The surgeon must be familiar with the appearance of the images in order to refer to them while searching for sentinel nodes during surgery. This very close communication with surgical colleagues is vital for the accuracy of the SLNB method.

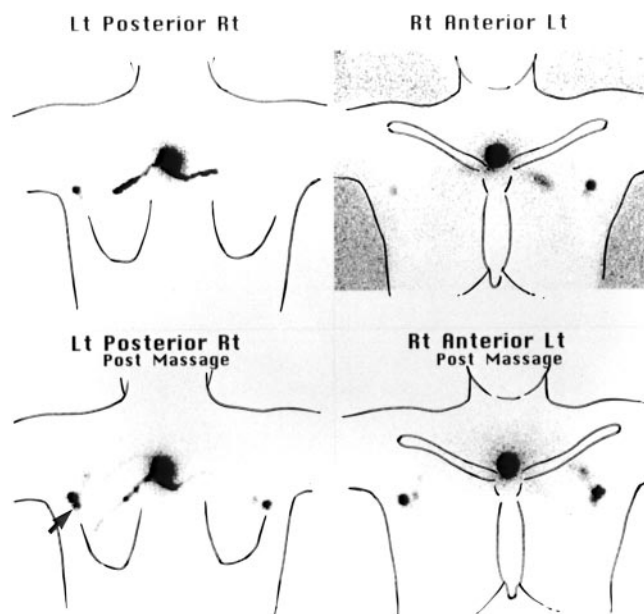
We have successfully used this protocol for over 3,000 patients with cutaneous melanomas. More detailed descriptions of our technique and imaging protocol can be found elsewhere (14,16).

If possible, lymphatic mapping should be done before wide local excision of the primary melanoma, as the latter disrupts lymph drainage pathways and may cause a lack of migration of the tracer or the identification of lymph nodes that are not true sentinel nodes.

A radiocolloid must gain access to the lumen of the initial lymphatic vessels under physiologic conditions to allow accurate mapping of lymphatic drainage. A brief consideration of the microanatomy of the lymphatic system is therefore relevant here.

## Physiology and Microanatomy of Cutaneous Lymphatics

The initial lymphatic capillaries are the terminal lymphatics and have no intraluminal valves. They also have an incomplete basement membrane and do not have a complete muscle layer (17,18). They are formed by overlapping endothelial cells, so that there are gaps of about 10–25 nm between the cells. Elastin fibrils on the outside of the endothelial cells are attached to collagen fibers in the interstitial matrix, so that the gaps between the lymphatic endothelial cells can be markedly widened by movement of the tissues, such as by exercise or massage. This action also increases the volume and flow of lymph. The entry of radiocolloid or blue dye into the lymphatic capillaries is thus increased significantly by massage or exercise of the part. External pressure, in contrast, markedly decreases lymph flow, and even quite light pressure has this effect (Fig. 3). This is the principle behind the current emergency treatment of snake bite, which includes the application of direct pressure over the site of the bite, rather than the use of a proximal tourniquet, as was previously recommended. The patient shown in Figure 3 was unusual because he had remained seated in our waiting area during the whole period after injection of the tracer. (Our patients normally ambulate for the 2-h delay.) Pooling of the tracer was seen in the medial part of the right lymph vessel and the inferior part of the 2 left vessels. Pressure from the seat back was the likely



**FIGURE 3.** Lymphoscintigraphy of patient with excision biopsy site on upper back close to midline. (Top row) Delayed images, obtained 2 h after injection of tracer, show faint right axillary sentinel node and brighter left axillary sentinel node. (Bottom row) Images taken immediately after 2 min of massage show that tracer has moved to second sentinel node in left axilla (arrow) and that right axillary sentinel node is much brighter. Even light external pressure significantly decreased lymph flow. Lt = left; Rt = right.



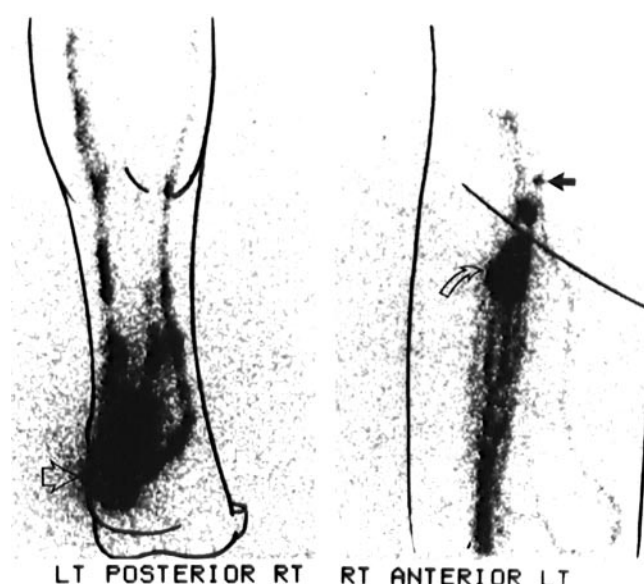
cause, and massage with a medial to lateral stroke was performed over both channels, causing the sentinel nodes in each axilla to brighten and a second sentinel node to appear in the left axilla. Lymph flow is also decreased by low temperatures, and the scanning room should be kept at an ambient temperature of at least 21°C. The lymphatic capillaries follow a tortuous course and frequently anastomose with each other but continue to have no intraluminal valves. They join together eventually to form lymphatic collecting vessels that have a 3-layer wall and that do have intraluminal valves.

The rates of lymph flow within lymphatic collecting vessels vary in different parts of the body (Table 1) (19). The most rapid flow occurs from the legs and feet, followed by that from the arms and hands. Flow from sites in the trunk is 3 to 4 cm/min on average, while the slowest flow occurs from the head, neck, and shoulder regions. The lymphatic vessels have an intrinsic pump mechanism maintaining steady lymph flow (20), but this mechanism responds to an increase in hydrostatic pressure by significantly increasing lymph flow (such as that which occurs in the legs during standing). Lymph flow is also increased by heat and inflammation, and although gravity affects the speed of flow through hydrostatic pressure, it does not influence the direction of flow. The intraluminal valves present in the lymphatic collecting vessels ensure that lymph flow is unidirectional toward the draining lymph nodes (17).

The paths taken by collecting vessels on their way to draining node fields vary from patient to patient and from skin site to skin site. These paths can sometimes be extremely complex and tortuous (Fig. 4) (16). Lymphatic vessels can converge to form fewer larger vessels (Fig. 5) but sometimes divide into multiple vessels, most commonly in the upper thigh. The collecting vessels usually pass through the subcutaneous fat layer and generally do not penetrate the deep fascia until a node field such as the groin or axilla is reached.

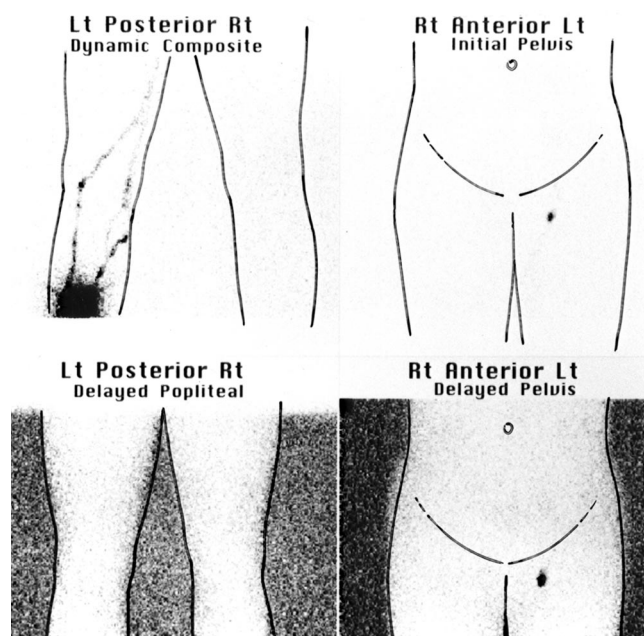
### Lymph Nodes

Lymph nodes trap radiocolloids by a complex physiologic process and do not act as simple mechanical filters. This process first involves opsonization, the mechanism by



**FIGURE 4.** Dynamic-phase lymphoscintigraphy of patient with melanoma excision biopsy site (open straight arrow) on right heel. Multiple lymphatic collecting vessels can be seen passing up leg to right groin. These vessels reach multiple sentinel nodes (curved arrow). Note tortuous path followed by 1 lymph vessel to faint sentinel node high in groin (solid straight arrow). LT = left; RT = right.

which the particles are recognized as foreign (1). Opsonization can occur in the lymph fluid or in the node itself and aids in later phagocytosis of the particles. A matrix of reticulin fibrils forms a complex lattice in the sinuses of



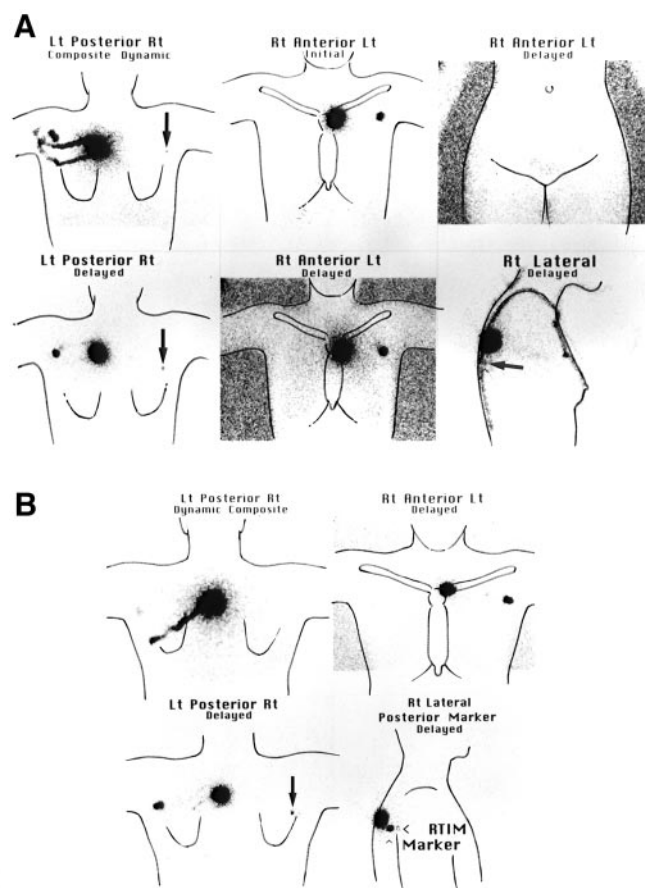
**FIGURE 5.** Lymphoscintigraphy of patient with excision biopsy site on posterior left calf. (Top row) Summed dynamic images show 3 lymphatic collecting vessels converging to single sentinel node in left groin. (Bottom row) Delayed images, obtained 2 h later, show single left groin sentinel node. Note that there are no second-tier nodes and that all tracer is retained in sentinel node. Lt = left; Rt = right.

**TABLE 1**  
Lymph Flow Rates

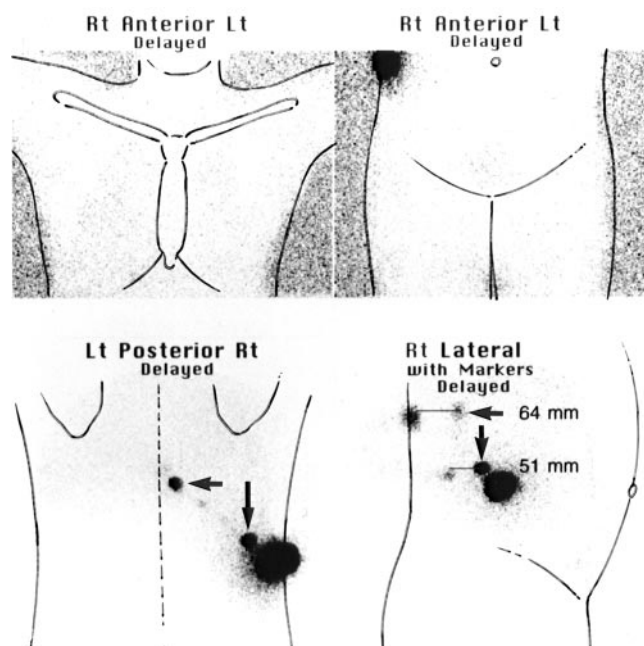
Region	Average flow (cm/min)
Head and neck	1.5
Anterior trunk	2.8
Posterior trunk	3.9
Arm and shoulder	2.0
Forearm and hand	5.5
Thigh	4.2
Leg and foot	10.2

lymph nodes and slows the movement of particles, such as radiocolloids, so that they can be phagocytosed by the macrophages and tissue histiocytes that line the sinuses (21). These phagocytic cells are most abundant in the sub-capsular sinus. Most of the tracer therefore is retained in this location.

Most of the radiocolloid that reaches a lymph node will be retained in the node by this process, regardless of the particle size, so that even when small-particle colloids, such as  $^{99m}\text{Tc}$ -antimony sulfide colloid, are used, the sentinel node is often the only radiolabelled node on delayed 2-h images (Figs. 2 and 5–11). A small percentage of the tracer can pass to second-tier nodes, regardless of the particle size, and we have found this characteristic to correlate directly with the speed of lymph flow in lymphatic collecting vessels (22). The higher the flow rate, the greater the incidence of



**FIGURE 6.** Lymphoscintigrams of 2 patients with excision biopsy sites on upper back close to midline. Each had sentinel node in left axilla, and summed dynamic image for each (top left) shows lymphatic collecting vessels reaching these sentinel nodes. (A) Faint sentinel node can be seen in right triangular intermuscular space (TIS) on dynamic image (arrow). (B) No TIS sentinel node can be seen on dynamic image. Delayed images show sentinel node in right TIS in both patients (arrows). This node is clearly seen in posterior and lateral views but is not seen in standard anterior views of axillae. Lt = left; Rt = right; RTIM = right triangular intermuscular space.

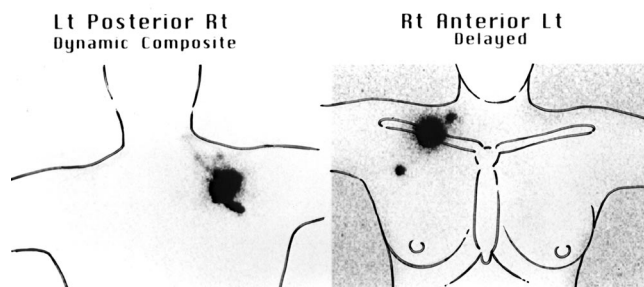


**FIGURE 7.** Delayed lymphoscintigraphy images of patient with melanoma excision biopsy site in posterolateral right loin area. Lymphatic channels passed directly through body wall to sentinel node in retroperitoneal area (vertical arrow) and sentinel node in right para-aortic region (horizontal arrow). There was no drainage to sentinel nodes in either axilla or groin. Depth of sentinel nodes is shown in right lateral view with point source on posterior skin mark. Nodes lay 5 and 6.5 cm deep relative to skin of back. Lt = left; Rt = right.

radiocolloid passing to second-tier nodes. This observation suggests that the physiologic process of phagocytosis that retains radiocolloid in the sentinel node can be overwhelmed if too many particles reach the node over a short time.

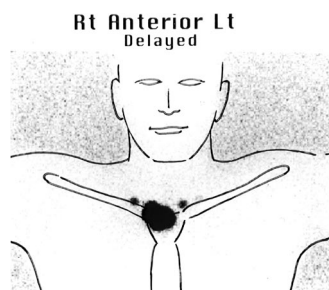
### Radiocolloids

The radiocolloids that best display lymphatic vessels and thus allow the identification of sentinel nodes are those that



**FIGURE 8.** Lymphoscintigraphy of patient with excision biopsy site on upper back to right of midline. (Left) Two lymph vessels can be seen on posterior summed dynamic image, 1 passing over shoulder to sentinel node in right supraclavicular fossa and 1 passing to sentinel node in right axilla. (Right) Both of these sentinel nodes are visible on anterior delayed image. However, sometimes neck nodes are obscured by activity at injection site in such patients, and vertical oblique views are then required to clarify situation. Lt = left; Rt = right.





**FIGURE 9.** Delayed lymphoscintigraphy of patient with excision biopsy site over manubrium. Drainage to sentinel node in supraclavicular fossa on each side can be seen; there is no drainage to either axilla. Lt = left; Rt = right.

readily enter the lymphatic capillaries; these are radiocolloids with particle sizes in the range of 5–50 nm (23,24). These particles easily enter the initial lymphatics under physiologic conditions, and their entry is enhanced by exercise or massage if movement is slow. With such small-particle radiocolloids, about 5%–8% of the injected dose will migrate from the injection site to the sentinel node or nodes (24). Appropriate small-particle radiocolloids are ultrafiltered  $^{99m}\text{Tc}$ -sulfur colloid (passed through a 100-nm filter),  $^{99m}\text{Tc}$ -nanocolloid of albumin, and  $^{99m}\text{Tc}$ -antimony sulfide colloid.

Large-particle radiocolloids (with particles of  $>200$  nm in diameter), such as unfiltered  $^{99m}\text{Tc}$ -sulfur colloid, have difficulty moving through the interstitial matrix and enter the lymphatic capillaries only in small numbers, even with exercise or massage. Lymphatic collecting vessels thus are usually not seen on dynamic imaging when large-particle colloids are used. Most of the injected dose remains at the injection site, despite exercise or massage, with only about 0.5% of the dose reaching the sentinel nodes (23). Identification of the sentinel nodes then becomes problematic; definitions based on count ratios relative to the background are relied upon. The problem with this approach is that sometimes one sentinel node has very low activity compared with another sentinel node and may not be identified as a sentinel node without dynamic imaging. These faint nodes are sometimes the only positive sentinel nodes in the node field (Fig. 12).

#### Lymphatic Mapping in Cutaneous Melanomas to Locate Sentinel Nodes

Since 1984, the Sydney Melanoma Unit has been performing lymphatic mapping with  $^{99m}\text{Tc}$ -antimony sulfide colloid to locate draining node fields in patients with intermediate-thickness melanomas located in the so-called ambiguous zones before elective dissection of the relevant node field. Over a 6-y period, we had performed about 200 studies (14).

As soon as Morton and colleagues described successful SLNB in melanoma patients by injection of blue dye (11), we began to apply the method described above to locate sentinel nodes by using lymphoscintigraphy on the day

before surgery. This meant that all patients with intermediate-thickness melanomas were studied regardless of the sites of the lesions on the skin. Since our examination required us to locate every sentinel node and not just to image in standard positions, we began to observe drainage to lymph nodes in completely unexpected places (16,25). Some were in new node fields not previously known to drain the skin. We quickly began to appreciate that there was unambiguous drainage from very few sites on the skin and that, without preoperative lymphoscintigraphy, accurate SLNB was simply not possible in many patients. This variability in lymph drainage and drainage to sentinel nodes in unexpected places has also been observed by others (9,26,27).

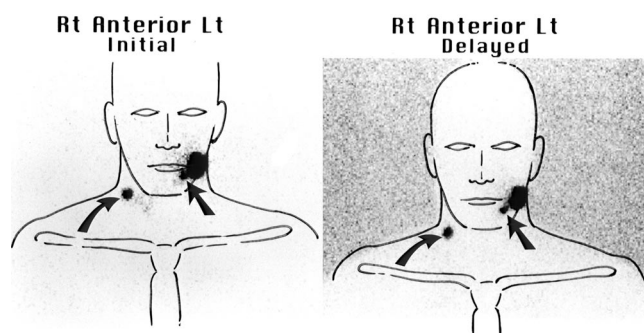
We have now performed lymphatic mapping for over 3,000 patients with cutaneous melanomas and have accumulated a large body of data relating to common and uncommon cutaneous lymphatic drainage pathways. All of these studies were performed by a small group of nuclear medicine physician consultants and were not done by trainees. The surgical correlation and SLNB procedures were all performed by a group of specialists in melanoma surgery. The following is a detailed description of the patterns of lymphatic drainage that we have observed.

#### PATTERNS OF LYMPHATIC DRAINAGE FROM SKIN

In the studied group of 3,059 patients, 7 showed no movement of tracer from the injection site over a 2.5-h period. These were older patients; 5 patients had melanoma sites on the head and neck, and 2 patients had melanoma sites on the trunk. Lymphatic drainage to sentinel nodes occurred in a single node field in 1,963 patients (64%), 2 node fields in 803 (26%), 3 node fields in 207 (7%), 4 node fields in 62 (2%), and 5 node fields in 7. The majority of skin sites thus drained to a single node field.

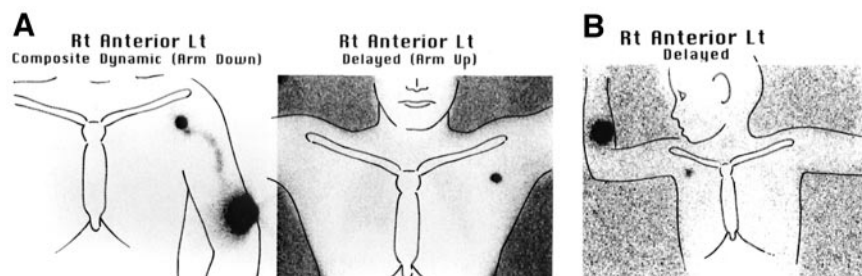
#### Posterior Trunk

The locations of sentinel nodes draining the posterior trunk are summarized in Table 2. This group includes 2



**FIGURE 10.** Dynamic and delayed lymphoscintigraphy of patient with excision biopsy site on left cheek. Sentinel node can be seen in left submandibular region (level I) (straight arrow). Another sentinel node can be seen in right midcervical area (level III) (curved arrow). Such contralateral drainage is not uncommon in head and neck. Lt = left; Rt = right.

**FIGURE 11.** (A) Adult with left-arm melanoma shows single channel on dynamic lymphoscintigraphy passing to single left axillary sentinel node, also seen on delayed scan. (B) Two-year-old child with melanoma on right forearm shows single right axillary sentinel node on delayed lymphoscintigraphy. Most upper limb melanomas include axillary sentinel node. Lt = left; Rt = right.



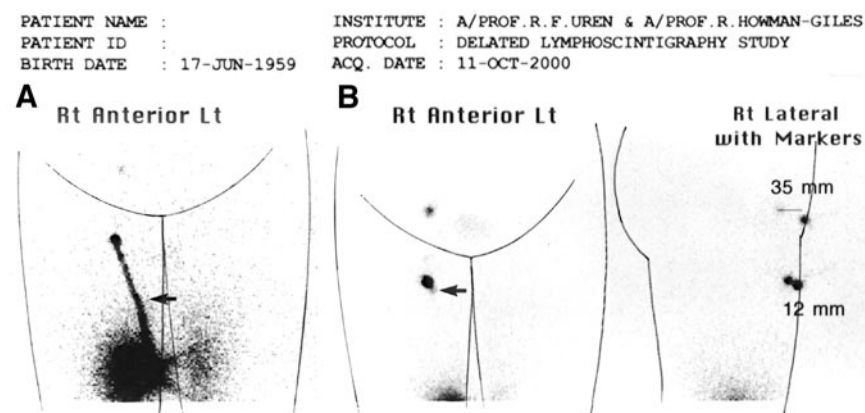
lymphatic drainage pathways that were completely unexpected and that, before our description, were not known to receive direct lymphatic drainage from the skin of the back. These lymphatic pathways drain to the triangular intermuscular space lateral to the scapula, behind the axilla (28), and pass through the posterior body wall directly to sentinel nodes in the retroperitoneal and paravertebral areas (29).

The more common of these 2 pathways is drainage from the skin of the back to the triangular intermuscular space (Figs. 6 and 13). We have observed this drainage pathway in 12% of our patients with back melanomas. Skin sites that we have found to drain to the triangular intermuscular space are shown in Figure 14. Sometimes 2 nodes in this space are seen one above the other, both lying just deep to the deep fascia, and the pathway then passes anteriorly, following the course of the circumflex scapular vessels into the posterior part of the axilla. Therefore, in some patients, the tracer will pass from a sentinel node in the triangular intermuscular space to a second-tier node in the axilla. We have seen this phenomenon occur in several patients. Without accurate lymphatic mapping by lymphoscintigraphy, this phenomenon could lead to a radiolabelled second-tier node being mistakenly identified as the sentinel node and removed from the axilla, while the true sentinel node in the triangular intermuscular space remains in the patient. Histologic examination of this radiolabelled axillary node will yield a false report of the lymph node status in the patient. This situation would occur if only a  $\gamma$ -probe were used to find and remove radiolabelled nodes from the axilla or if the lymphoscintigraphy imaging protocol were inadequate.

Older protocols called only for anterior views of the axilla, but posterior and lateral views are required to identify the sentinel nodes in this unexpected location, because attenuation of the photons as they pass through the patient's body means that nodes in the triangular intermuscular space may not be seen at all in an anterior view (Fig. 6). Drainage to a sentinel node in the triangular intermuscular space often occurs along with drainage to a sentinel node in another node field, but we have encountered 8 patients with exclusive drainage to a sentinel node in this unexpected location.


The second unexpected lymphatic drainage pathway that we have observed draining the skin of the back is one that involves direct passage through the posterior body wall to sentinel nodes in the paravertebral, para-aortic, or retroperitoneal areas. This drainage pattern usually involves intra-abdominal sites, but we have also seen paravertebral nodes in the thorax as sentinel nodes draining the skin of the back. The skin sites that may drain through this unexpected pathway are concentrated mainly in the posterior loin area (Fig. 15). We have observed this pathway in 4% of patients with back melanomas, making it much less common than the pathway draining to the triangular intermuscular space. If we consider only the posterior loin area, however, we find drainage through this pathway in 24% of patients. Again, drainage to sentinel nodes in these unexpected areas is usually accompanied by drainage to sentinel nodes in expected node fields (the axilla and groin); however, we have encountered 4 patients with exclusive drainage to sentinel nodes in these areas but with no drainage whatsoever to nodes in the axilla or groin (Fig. 7) (30). The importance of

**FIGURE 12.** Lymphoscintigraphy of patient with excision biopsy site on medial right thigh anteriorly. (A) Summed dynamic image shows bright lymphatic collecting vessel passing to right groin sentinel node. Very faint second vessel can be seen medial to this vessel (arrow). (B) Delayed image shows bright sentinel node and second faint sentinel node just medial to this node (arrow). Second-tier node higher in groin receives tracer from bright sentinel node and is actually "hotter" than faint sentinel node. At histologic examination, bright sentinel node was normal, but faint sentinel node contained micrometastasis. Lt = left; Rt = right.

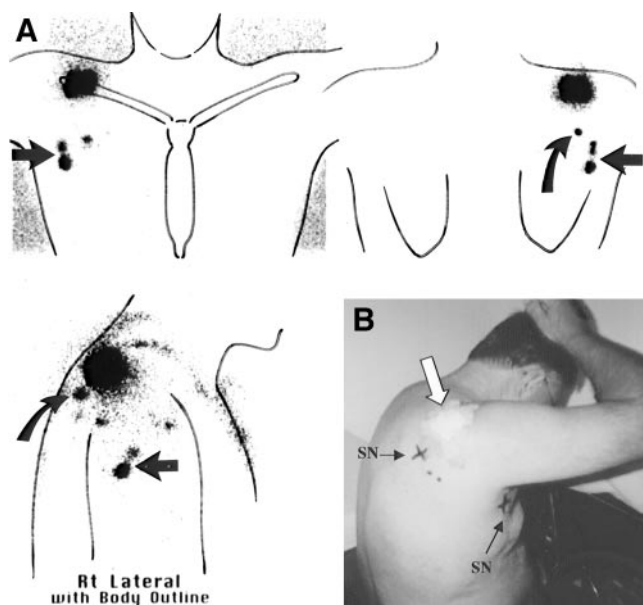


**TABLE 2**  
Locations of Sentinel Nodes (SN) for Melanomas of Trunk

Melanoma site	SN site		n	%
	Area	Location		
Anterior trunk (n = 211)				
Above umbilicus (n = 199)	Axilla	Ipsilateral	180	90
		Contralateral	31	16
		Bilateral	30	16
	Groin	Ipsilateral	19	9
		Contralateral	7	4
		Bilateral	3	1.5
	Cervical	Level II	1	0.5
		Level III	3	1.5
		Level IV	3	1.5
		Level V	6	3
	Supraclavicular		27	14
	Costal margin		6	3
	Internal mammary		2	1
	Interval node		17	8
Below umbilicus (n = 12)				
Axilla	Ipsilateral	4	33	
	Contralateral	0	0	
Groin	Ipsilateral	12	100	
	Contralateral	2	16	
Interval node	Bilateral	3	25	
		1	8	
Posterior trunk (n = 1,057)				
Above waist (n = 965)	Axilla	Ipsilateral	875	91
		Contralateral	292	30
		Bilateral	264	27
	Groin	Ipsilateral	34	3
		Contralateral	10	1
		Bilateral	4	0.5
	Triangular intermuscular space	Ipsilateral	88	9
		Contralateral	35	3
		Bilateral	11	1
	Cervical	Level II	1	
		Level III	4	0.5
		Level IV	15	1.5
		Level V	108	11
	Supraclavicular	Ipsilateral	104	11
		Contralateral	34	3
		Bilateral	15	1.5
	Postauricular		1	
	Occipital		4	0.5
	Paravertebral or para-aortic		21	2
	Retroperitoneal		8	1
	Interval node		118	12
Below waist (n = 92)				
Axilla	Ipsilateral	38	41	
	Contralateral	15	16	
Groin	Bilateral	9	10	
	Ipsilateral	71	77	
Interval node	Contralateral	24	26	
	Bilateral	21	23	
Paravertebral or para-aortic		1	1	
Retroperitoneal		1	1	
Interval node		12	13	



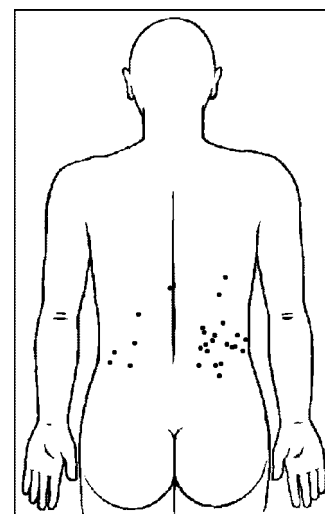




**FIGURE 13.** Patient with melanoma behind right shoulder. (A) Delayed lymphoscintigraphy images show 2 sentinel nodes in right axilla (straight arrow) and second-tier node in right axilla as well as sentinel node in right triangular intermuscular space (curved arrow). Lt = left; Rt = right. (B) Patient at end of study. "X" marks surface locations of right triangular intermuscular space sentinel node (SN) and 1 right axillary sentinel node. Melanoma site is indicated by thick arrow.

identifying drainage to sentinel nodes in the paravertebral, para-aortic, and retroperitoneal areas is that metastatic disease in one of these nodes represents locoregional metastasis, not systemic disease.

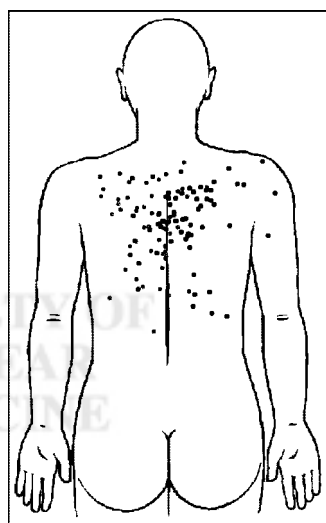
Most patients with melanoma sites on the posterior trunk do show drainage to sentinel nodes in the expected node fields, such as the axilla and groin, but drainage to combinations of node fields is also very common and will be



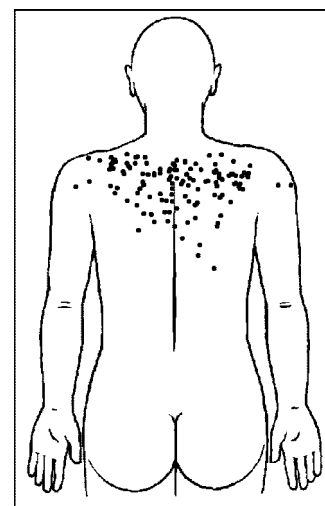
**FIGURE 15.** Location of skin sites draining directly through body wall to sentinel nodes in paravertebral, para-aortic, and retroperitoneal areas.

missed without preoperative lymphatic mapping by lymphoscintigraphy. It is also remarkable how often lymph drains from the upper back over the shoulder to nodes in the supraclavicular fossa or to other nodes in the neck (Figs. 8 and 16). Careful imaging including vertex or lateral oblique views is required to ensure that all sentinel nodes are identified around the base of the neck, since such nodes are often obscured by injection site activity in straight anterior or posterior views.

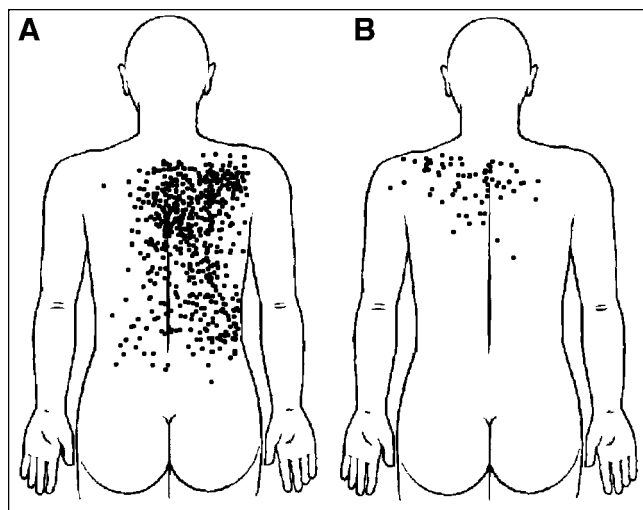
Sappey's vertical lines do not help predict lymph flow, and lymphatic vessels often cross the midline to reach contralateral sentinel nodes in expected and unexpected node fields (Fig. 17). For lesions at the level of the waist, lymph vessels may pass down to the groin or up to the axilla, although most pass up to the axilla. Occasionally, lymph vessels also cross the horizontal line of Sappey



**FIGURE 14.** Locations of all skin sites draining to sentinel node in right or left triangular intermuscular space.



**FIGURE 16.** Locations of skin sites on back draining to sentinel nodes in supraclavicular fossa.



**FIGURE 17.** Locations of skin sites on back draining to right axilla (A) and left supraclavicular fossa (B). Note that drainage from contralateral side of back is common in each case.

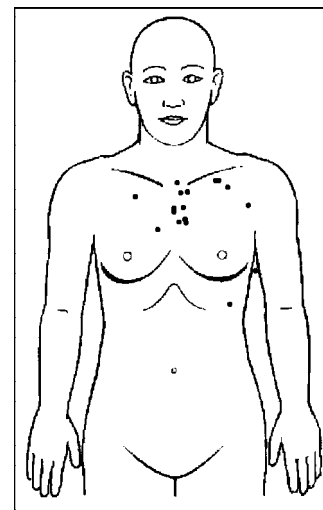
around the waist but usually do so to pass up to the axilla from below rather than to pass down to the groin from above the line of Sappey.

Interval nodes, which are nodes that lie along the course of a lymphatic collecting vessel between a primary site and a draining node field, have been seen as sentinel nodes more commonly on the back than elsewhere in our patients with melanomas (see below).

#### Anterior Trunk

Lymphatic drainage from the skin of the anterior trunk generally occurs to expected node fields, and there tends to be less passage of lymph vessels across the midline than in the posterior trunk (Table 2). Even on the anterior upper chest, vessels tend to pass to axillary nodes rather than up over the clavicle to neck nodes, although exceptions do occur (Fig. 9). Those that do pass to neck nodes arise from a more restricted area of the anterior upper chest than is seen on the upper back (Fig. 18). Drainage to interval nodes is also less common anteriorly than on the back.

We did detect a new unexpected drainage pathway that passes from the periumbilical skin to a node that lies in the subcutaneous fat over the costal margin (31). The lymphatic pathway then passes medially and through the chest wall to internal mammary nodes on the same side as the costal margin node. The pathway always meets a costal margin node first, however; therefore, the sentinel node in these patients is the costal margin node, and the internal mammary node receives drainage as a second-tier node. In fact, we have seen an internal mammary node as a sentinel node for the skin of the anterior trunk in only 2 patients. One had undergone lymph node dissection of the ipsilateral axilla 20 y earlier as a treatment for lymphoma. This procedure presumably caused an alternative lymphatic drainage pathway to appear. The other patient had undergone an extensive excision biopsy of a melanoma in the epigastrium and



**FIGURE 18.** Locations of skin sites on anterior trunk draining to right or left supraclavicular fossa. This drainage occurs from more restricted area than on back, but some patients do show such drainage from low in anterior chest.

showed drainage to a sentinel node in the right internal mammary chain as well as to a left axillary sentinel node.

#### Head and Neck

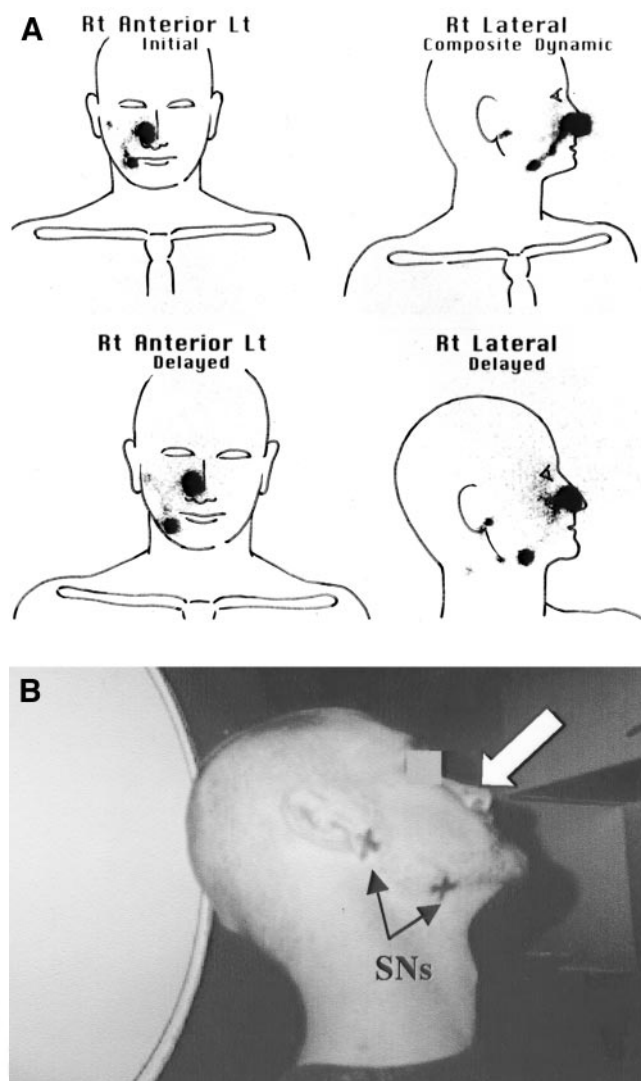
Details for lymphatic drainage from the skin of the head and neck are shown in Table 3. The head and neck are challenging areas for accurate lymphatic mapping, both for nuclear medicine physicians and for surgeons. Drainage to multiple sentinel nodes is common (16,32), and the nodes

**TABLE 3**  
Locations of Sentinel Nodes for Melanomas  
of Head and Neck

SN Site		n (total, 508)	%
Area	Location		
Parotid	Ipsilateral	171	34
	Contralateral	7	1
Ipsilateral cervical	Level I	84	16
	Level II	295	58
	Level III	62	12
	Level IV	47	9
	Level V	97	19
Supraclavicular	Ipsilateral	49	9
	Contralateral	19	4
Cervical	Level I	16	3
	Level II	17	3
	Level III	9	2
	Level IV	16	3
	Level V	4	1
Supraclavicular	Contralateral	4	1
Occipital	Ipsilateral	47	9
	Contralateral	15	3
Postauricular	Ipsilateral	83	16
	Contralateral	5	1
Axillary	Ipsilateral	7	1
	Contralateral	2	0.3
Interval node		25	5

are often small (Fig. 19). The draining sentinel nodes often lie very near or sometimes immediately beneath the melanoma site. Detection of such nodes by lymphoscintigraphy is thus extremely difficult and sometimes impossible. However, if care is taken and such limitations are understood, accurate lymphatic mapping and biopsy of sentinel nodes can be achieved in the head and neck just as elsewhere in the body.

Also, as we have found elsewhere, the clinical prediction of lymphatic drainage in the head and neck is unreliable, and 33% of patients show drainage to node sites that is discordant with the clinical prediction (32). Such drainage



**FIGURE 19.** Patient with excision biopsy site on right side of nose. (A) (Top row) Summed dynamic lymphoscintigraphy images. (Bottom row) Delayed lymphoscintigraphy images. Two separate lymphatic vessels reach 2 sentinel nodes, 1 in parotid region and 1 in right submandibular region. Lt = left; Rt = right. (B) Patient at end of study. Sentinel node (SNs) are marked on skin with "X." Melanoma site on nose is indicated by thick arrow. Multiple draining node fields are common in head and neck.

**TABLE 4**

Locations of Sentinel Nodes for Melanomas of Upper and Lower Limbs

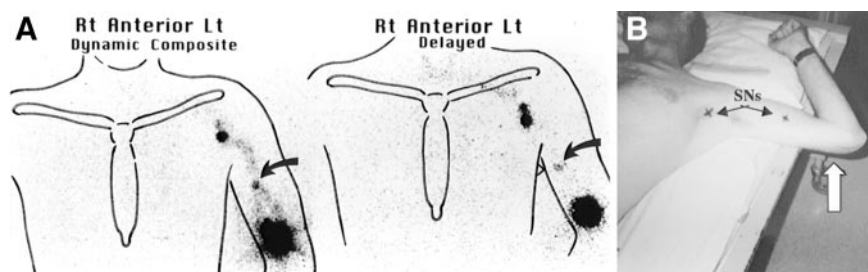
Melanoma site	SN Site	n	%
Upper limb (n = 571)	Axilla	563	99
	Epitrochlear	36	6
	Cervical (Level V)	3	0.5
	Supraclavicular	36	6
	Triangular intermuscular space	3	0.5
	Interpectoral	2	0.3
	Infraclavicular	1	0.2
	Interval node	23	4
Lower limb (n = 712)	Groin	712	100
	Popliteal	38	5
	Interval	4	0.5

often occurs to postauricular nodes from the skin of the face and anterior scalp. These nodes are not usually excised in elective neck dissections for melanoma. Drainage also occurs across the midline, and we have seen such drainage in 15% of patients with head and neck melanomas (Fig. 10). Such a contralateral node can occasionally be the only site of micrometastatic disease. Lymph drainage also quite often occurs from the base of the neck up to nodes in the upper cervical or occipital area. Again, for some patients with this pattern, the only positive node seen is an occipital node, even though other sentinel nodes are present in the axilla, upper cervical area, and lateral neck base. Drainage is also seen regularly from the upper scalp directly down to nodes at the base of the neck or in the supraclavicular region (Fig. 1). Lymphatic vessels reaching these nodes thus completely bypass all the nodes in the upper and middle cervical areas as well as the preauricular (parotid), occipital, and postauricular nodes. These findings reinforce the concept that the sentinel node is not simply the node closest to the primary melanoma site.

#### Upper Limb

Lymph drainage from the skin of the upper limb occurs to the axilla, as expected, in almost all patients (Fig. 11). However, this scenario is often not the complete picture (Table 4). Drainage to sentinel nodes in the epitrochlear region is more common than was previously thought, and we have observed drainage to this site in 36 of 218 patients (16%) with melanomas located on the forearm and hand. We have also detected direct drainage to sentinel nodes above the axilla in the supraclavicular region, interpectoral region, lateral neck base, and triangular intermuscular space in some patients (16). These patients also had a sentinel node in the axilla, and lymph drainage to these unexpected sites occurred through a separate, discrete lymph vessel. Relying exclusively on  $\gamma$ -probe-guided removal of axillary sentinel nodes in these patients would have missed these other sentinel nodes. Thus, accurate lymphatic mapping by lymphoscintigraphy is imperative.





**FIGURE 20.** Patient with excision biopsy site on left arm above and behind elbow. (A) Lymphoscintigraphy shows that channels pass to interval node (1 of the sentinel nodes in this patient) in medial arm (curved arrow) and to 2 sentinel nodes in left axilla. Lt = left; Rt = right. (B) Patient at end of study. Melanoma site is indicated by thick arrow. Sentinel nodes (SNs) are marked on skin with "X."

An interval node is regularly seen lying medially in the arm about halfway between the shoulder and the elbow (Fig. 20). We have seen one patient with drainage exclusively to this interval node in the middle inner arm, so that it was the only sentinel node.

### Lower Limb

The skin of the lower limb drains to the ipsilateral groin unless there has been prior surgery to the groin nodes. In this circumstance, drainage to the contralateral groin may occur, and we have found micrometastases in such contralateral groin sentinel nodes (33).

Lymph drainage from the foot and leg to the popliteal lymph nodes may also occur, and we have observed such drainage in 38 of 481 patients (8%) with melanomas in these areas. The melanoma sites draining to the popliteal nodes are quite variable, and it is not just the skin of the lateral heel that drains here, as was previously thought (34) (Fig. 21).

### Interval Nodes

Interval nodes can be sentinel nodes, and we have seen 10 patients for whom these nodes were the only sentinel nodes. When present, they must be detected and removed if an SNLB procedure is to be accurate. We have shown that these interval nodes, when sentinel nodes, contain micro-

metastases with the same incidence as sentinel nodes found in standard node fields (35). We found interval nodes in 7% of patients overall, and they were more common on the trunk (12% posterior trunk and 8% anterior trunk) than in the head and neck (5%) or upper limb (4%) and were rare in the lower limb (0.5%). In a large multicenter study, McMaster and colleagues (36) also found that in melanoma patients, interval nodes were positive for metastases at the same frequency as sentinel nodes in standard node fields. In their 13 patients with positive interval nodes, such nodes were the only positive sentinel nodes in 11 patients (85%).

Although interval nodes may be found at any point along the course of a lymphatic collecting vessel, they are more common in certain locations, such as the midaxillary line, the upper back, and the medial aspect of the middle upper arm.

Interval nodes remain "hot" on delayed scans because they retain the radiocolloid, although it is notable that much of the radiocolloid reaching interval nodes passes to second-tier nodes. They thus seem to be more "porous" to radiocolloids than sentinel nodes in standard node fields or unexpected node fields.

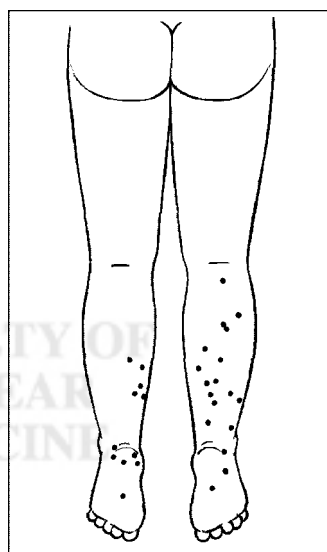
### Lymphatic Lakes

Unlike interval nodes, lymphatic lakes do not need to be examined during SLNB procedures. They are focal dilations of lymphatic collecting vessels. They are seen during lymphoscintigraphy as a focal area of increased tracer retention along the course of a lymphatic collecting vessel during the dynamic early postinjection phase of the study. The activity rapidly passes through the lymph vessel, however, so that these lymphatic lakes are not visible on delayed scans performed 2 h later. Lymphatic lakes should not be mistaken for interval nodes, which retain tracer and are therefore hot on delayed scans.

### CONCLUSION

Lymphatic drainage from the skin is highly variable from patient to patient, even when the same region of the body is being examined. The path taken by lymphatic collecting vessels is unpredictable, as is the ultimate location of the draining sentinel node or nodes, as several recent studies have confirmed (14,36–38).

Preoperative lymphoscintigraphy with small-particle radiocolloids allows these lymphatic vessels to be visualized draining directly to sentinel nodes. Careful imaging tech-



**FIGURE 21.** Locations of skin sites draining from posterior legs and feet to sentinel nodes in popliteal fossae.

niques will thus allow all true sentinel nodes to be identified in each patient, even if these nodes lie outside standard node fields or are interval nodes lying between the primary site and a node field. This information is an important contribution to the management of patients with melanomas, as it will lead to more accurate nodal staging of patients with high-risk melanomas.

We now know that the clinical prediction of the pattern of lymphatic drainage in an individual patient is unreliable and inaccurate. We also now know that we have an accurate method of mapping lymphatic drainage in every patient, making the difficulties associated with clinical prediction irrelevant. This technique, which provides an accurate map of lymphatic drainage in each patient, can thus have a direct and important impact on the clinical management of patients with melanomas.

## ACKNOWLEDGMENTS

We thank all of the excellent nuclear medicine technologists whose dedication has been so important to the success of our lymphatic mapping work, including Kim Ioannou, Nicholas Trpezanovski, Angelique Nguyen, Tracey Smith, Sally Raymond, and Ian Dyer. We thank the other nuclear medicine physicians who have added their enthusiasm to our work, including Drs. David Chung, Robert Mansberg, John Roberts, Reginald Hutcherson, and Elizabeth Bernard. We also thank the surgeons of the Sydney Melanoma Unit for referring their patients and providing the surgical correlation and validation of the lymphatic drainage patterns that we have documented, including Professor William McCarthy, Dr. Michael Quinn, Dr. Kirwin Shannon, Professor Christopher O'Brien, Dr. Andrew Spillane, Dr. Robyn Saw, and Dr. Jonathon Stretch.

## REFERENCES

- Mariani G, Gipponi M, Moresco L, et al. Radioguided sentinel lymph node biopsy in malignant cutaneous melanoma. *J Nucl Med*. 2002;43:811–827.
- Sappey MPC. *Anatomy, Physiology and Pathology of the Lymphatic Vessels in Man and Vertebrates* [in French]. DeLahaye A, Lecrosnier E, trans-ed. Paris, France; 1874.
- Sherman AI, Ter-Pogossian M, Tocus EC. Lymph node concentration of radioactive colloidal gold following interstitial injection. *Cancer*. 1953;6:1238–1240.
- Haagensen CD, Feind CR, Herter FP, et al. Lymphatics of the trunk. In: Haagensen CD, ed. *The Lymphatics in Cancer*. Philadelphia, PA: WB Saunders; 1972:437–458.
- Sugarbaker EV, McBride CM. Melanoma of the trunk: the results of surgical excision and anatomic guidelines for predicting nodal metastasis. *Surgery*. 1976; 80:22–30.
- Bergqvist L, Strand S, Hafstrom L, et al. Lymphoscintigraphy in patients with malignant melanoma: a quantitative and qualitative evaluation of its usefulness. *Eur J Nucl Med*. 1984;9:129–135.
- Fee HJ, Robinson DS, Sample WF, et al. The determination of lymph shed by colloidal gold scanning in patients with malignant melanoma: a preliminary study. *Surgery*. 1978;84:626–632.
- Meyer CM, Lecklitner ML, Logic JR, et al. Technetium-99m sulfur-colloid cutaneous lymphoscintigraphy in the management of truncal melanoma. *Radiology*. 1979;131:205–209.
- Norman J, Cruse W, Espinosa C, et al. Redefinition of cutaneous lymphatic drainage with the use of lymphoscintigraphy for malignant melanoma. *Am J Surg*. 1991;162:432–437.
- Sullivan DC, Croker BP Jr, Harris CC, Deery P, Seigler HF. Lymphoscintigraphy in malignant melanoma: <sup>99m</sup>Tc antimony sulfur colloid. *AJR*. 1981;137:847–851.
- Morton DL, Wen D-R, Wong JH, et al. Technical details of intraoperative lymphatic mapping for early stage melanoma. *Arch Surg*. 1992;127:392–399.
- Alex JC, Weaver DL, Fairbank JT, et al. Gamma-probe-guided lymph node localization in malignant melanoma. *Surg Oncol*. 1993;2:303–308.
- Krag DN, Meijer SJ, Weaver DL, et al. Minimal-access surgery for staging of malignant melanoma. *Arch Surg*. 1995;130:654–658.
- Uren RF, Howman-Giles RB, Shaw HM, et al. Lymphoscintigraphy in high risk melanoma of the trunk: predicting draining node groups, defining lymphatic channels and locating the sentinel node. *J Nucl Med*. 1993;34:1435–1440.
- Cochran AJ. The pathologist's role in sentinel lymph node evaluation. *Semin Nucl Med*. 2000;30:11–17.
- Uren RF, Thompson JF, Howman-Giles RB. *Lymphatic Drainage of the Skin and Breast: Locating the Sentinel Nodes*. Amsterdam, The Netherlands: Harwood Academic Publishers; 1999.
- Leak LV. Lymphatic vessels. In: Johannessen JV, ed. *Cardiovascular System, Lymphoreticular and Hematopoietic System*. New York, NY: McGraw-Hill; 1980:159–183.
- Ryan TJ. The lymphatics of the skin. In: Jarrett A, ed. *The Physiology and Pathophysiology of the Skin*. London, England: Academic Press; 1978:1755–1780.
- Uren RF, Howman-Giles RB, Thompson JF. Variation in cutaneous lymphatic flow rates. *Ann Surg Oncol*. 1997;4:279–280.
- Sjoberg T, Steen S. Contractile properties of lymphatics from the human lower leg. *Lymphology*. 1991;24:16–21.
- Nichols WS, Chisari FV. Structure and function of the lymphoid tissues. In: Williams WJ, Beutler E, Erslev AJ, et al., eds. *Hematology*. New York, NY: McGraw-Hill; 1990:49–50.
- Uren RF, Howman-Giles RB, Thompson JF. Demonstration of second tier lymph nodes during preoperative lymphoscintigraphy for melanoma: incidence varies with primary tumour site. *Ann Surg Oncol*. 1998;5:517–521.
- Bergqvist L, Strand S-E, Persson BRR. Particle sizing and biokinetics of interstitial lymphoscintigraphic agents. *Semin Nucl Med*. 1983;8:9–19.
- Strand SE, Persson BRR. Quantitative lymphoscintigraphy I: basic concepts for optimal uptake of radiocolloids in the parasternal lymph nodes of rabbits. *J Nucl Med*. 1979;20:1038–1046.
- Thompson JF, Uren RF, Shaw HM, et al. The location of sentinel lymph nodes in patients with cutaneous melanoma: new insights into lymphatic anatomy. *J Am Coll Surg*. 1999;189:195–206.
- Eberbach MA, Wahl RL. Lymphatic anatomy: functional nodal basins. *Ann Plast Surg*. 1989;22:25–31.
- Leong SP, Achtem TA, Habib FA, et al. Discordancy between clinical predictions vs lymphoscintigraphic and intraoperative mapping of sentinel lymph node drainage of primary melanoma. *Arch Dermatol*. 1999;135:1472–1476.
- Uren RF, Howman-Giles RB, Thompson JF, et al. Lymphatic drainage to triangular intermuscular space lymph nodes in melanoma on the back. *J Nucl Med*. 1996;37:964–966.
- Uren RF, Howman-Giles RB, Thompson JF. Lymphatic drainage from the skin of the back to intra-abdominal lymph nodes in melanoma patients. *Ann Surg Oncol*. 1998;5:384–387.
- Uren RF, Howman-Giles RB, Thompson JF, et al. Exclusive lymphatic drainage from a melanoma on the back to intraabdominal lymph nodes. *Clin Nucl Med*. 1998;23:71–73.
- Uren RF, Howman-Giles RB, Thompson JF, et al. Lymphatic drainage from peri-umbilical skin to internal mammary nodes. *Clin Nucl Med*. 1995;20:254–255.
- O'Brien CJ, Uren RF, Thompson JF, et al. Prediction of potential metastatic sites in cutaneous head and neck melanoma using lymphoscintigraphy. *Am J Surg*. 1995;170:461–466.
- Thompson JF, Saw RP, Colman MH, et al. Contralateral groin node metastasis from lower limb melanoma. *Eur J Cancer*. 1997;33:976–977.
- Clouse ME, Wallace S, eds. *Lymphatic Imaging: Lymphography, Computed Tomography, and Scintigraphy*. 2nd ed. Baltimore, MD: Williams & Wilkins; 1985.
- Uren RF, Howman-Giles R, Thompson JF, et al. Interval nodes: the forgotten sentinel nodes in patients with melanoma. *Arch Surg*. 2000;135:1168–1172.
- McMasters KM, Chao C, Wong SL, et al. Interval sentinel lymph nodes in melanoma. *Arch Surg*. 2002;137:543–549.
- O'Toole GA, Hettiaratchy S, Allan R, Powell BWEM. Aberrant sentinel nodes in malignant melanoma. *Br J Plast Surg*. 2000;53:415–417.
- Stadius Muller MG, Hennipman FA, van Leeuwen PAM, Pijpers R, Vuylsteke RJCLM, Meijer S. Unpredictability of lymphatic drainage patterns in melanoma patients. *Eur J Nucl Med*. 2002;29:255–261.



The Journal of  
NUCLEAR MEDICINE

## Patterns of Lymphatic Drainage from the Skin in Patients with Melanoma

Roger F. Uren, Robert Howman-Giles and John F. Thompson

*J Nucl Med.* 2003;44:570-582.

---

This article and updated information are available at:  
<http://jnm.snmjournals.org/content/44/4/570>


---

Information about reproducing figures, tables, or other portions of this article can be found online at:  
<http://jnm.snmjournals.org/site/misc/permission.xhtml>

Information about subscriptions to JNM can be found at:  
<http://jnm.snmjournals.org/site/subscriptions/online.xhtml>

*The Journal of Nuclear Medicine* is published monthly.  
SNMMI | Society of Nuclear Medicine and Molecular Imaging  
1850 Samuel Morse Drive, Reston, VA 20190.  
(Print ISSN: 0161-5505, Online ISSN: 2159-662X)

© Copyright 2003 SNMMI; all rights reserved.

 SOCIETY OF  
NUCLEAR MEDICINE  
AND MOLECULAR IMAGING