

Sigma Receptor Scintigraphy with *N*-[2-(1'-Piperidiny)Ethyl]-3-¹²³I-Iodo-4-Methoxybenzamide of Patients with Suspected Primary Breast Cancer: First Clinical Results

Vicky Caveliers, Pharm¹; Hendrik Everaert, MD, PhD¹; Christy S. John, PhD²; Tony Lahoutte, MD¹; and Axel Bossuyt, MD, PhD¹

¹Department of Nuclear Medicine, University Hospital, Free University of Brussels, Brussels, Belgium; and ²Department of Biochemistry and Molecular Biology, George Washington University Medical Center, Washington, DC

The aim of this study was to investigate the potential of a new iodobenzamide, *N*-[2-(1'-piperidiny)ethyl]-3-¹²³I-iodo-4-methoxybenzamide (P-¹²³I-MBA), to visualize primary breast tumor in humans in vivo. Tumor accumulation of benzamides is based on a preferential binding to sigma receptors that are overexpressed on breast cancer cells. **Methods:** P-¹²³I-MBA (148–185 MBq) was administered to 12 patients with a mammographically suspicious breast mass. Two hours after administration, whole-body and spot images of the healthy and the diseased breast were obtained. **Results:** A focal increased tracer accumulation was observed in 8 of 10 patients with histologically confirmed breast cancer (mean tumor-to-background ratio, 2.04). No uptake was seen in a case of lymphatic adenitis. **Conclusion:** This preliminary patient study shows that P-¹²³I-MBA accumulates in most breast tumors in vivo. Future work should focus on the relationship between P-¹²³I-MBA uptake and the proliferative activity of cells to anticipate use of this technique as a tool to noninvasively assess the degree of tumor proliferation.

Key Words: breast cancer; sigma receptors; iodobenzamides; proliferation

J Nucl Med 2002; 43:1647–1649

Sigma receptors are membrane-bound proteins that were originally classified as subtypes of the opiate receptors. Their function is not entirely understood, but an overexpression of sigma sites on cancer cells makes them an attractive target for the application of radiolabeled sigma binding-site ligands in oncology (1). In addition, there is adequate evidence that sigma-2 receptors are upregulated or downregulated according to the proliferative status of a tumor (2).

Demonstrating in vivo tumor cell proliferation during treatment could be an important prognostic factor for the patient and an indication to adapt the treatment strategy early.

Iodine-labeled benzamides express affinity for both sigma-1 and sigma-2 receptors. In vitro characterization of a new benzamide, *N*-[2-(1'-piperidiny)ethyl]-3-¹²³I-iodo-4-methoxybenzamide (P-¹²³I-MBA), demonstrated saturable binding to T47D human ductal breast cancer cells with values of the dissociation constant K_d in the nanomolar range. In vivo experiments using a rat mammary tumor model yielded tumor uptake for P-¹²³I-MBA that is comparable with that for ^{99m}Tc-sestamibi (3). To our knowledge, this is the first human study to evaluate in vivo the ability of an iodobenzamide, P-¹²³I-MBA, to localize sigma receptor overexpression in breast cancer.

MATERIALS AND METHODS

Radiosynthesis

Radioiodination was achieved by iododestannylation of the trimethylstannyl-PMBA precursor at room temperature using chloramine-T as oxidizing agent. Sodium ¹²³I-iodide (3.7 TBq/mg in 0.01N NaOH) was obtained from Nordion Europe (Fleurus, Belgium). C₁₈ Sep-Pak (Waters, Milford, MA) purification yielded 85% P-¹²³I-MBA with a radiochemical purity of >98%.

Patient Population

We studied 12 female patients (mean age, 65 y; age range, 44–82 y) with a breast mass on mammography that was highly suggestive of malignant disease. None of these patients had a prior history of breast cancer. Final diagnosis of the mass was based on histopathologic examination of tumor tissue obtained with needle biopsy or after surgical removal of the tumor. Tumor size was measured during surgery or was estimated during mammography or physical examination.

Scintigraphic Protocol

P-¹²³I-MBA (148–185 MBq) was injected intravenously after oral intake of sodium perchlorate to prevent thyroid uptake of free

Received Oct. 9, 2001; revision accepted Jul. 31, 2002.

For correspondence or reprints contact: Vicky Caveliers, Pharm, Department of Nuclear Medicine, University Hospital, Free University of Brussels (AZ-VUB), Laarbeeklaan 101, B-1090 Brussels, Belgium.

E-mail: vickycaveliers@tiscalinet.be

TABLE 1
Patient Characteristics and Scintigraphic Results of Lateral Breast Imaging with P-¹²³I-MBA

Patient no.	Age (y)	Histology	Localization	Tumor size (cm)	P- ¹²³ I-MBA	T/B ratio	Evaluation
1	60	Invasive ductal carcinoma	IEQ L	3.0	Positive	2.23	TP
2	63	Invasive ductal carcinoma	SEQ L	3.2	Positive	1.36	TP
3	76	Invasive ductal carcinoma	SEQ L	5.5	Negative		FN
4	82	Invasive ductal carcinoma	SEQ L	2.5	Positive	2.31	TP
5	73	Invasive lobular carcinoma	SEQ R	2.4	Positive	2.75	TP
6	77	Invasive ductal carcinoma; fibrocystic disease	SIQ R	1.4	Positive	1.69	TP
7	70	Invasive ductal carcinoma	SEQ R	2.5	Positive	2.28	TP
8	46	Invasive ductal carcinoma	SEQ R	2.4	Positive	1.84	TP
					Positive	2.08	FP
9	51	Invasive lobular carcinoma; fibrocystic disease	SIQ R	4.0	Negative		FN
10	44	Invasive ductal carcinoma	IEQ L	4.5		Indeterminate	
11	63	Invasive ductal carcinoma	SEQ L	4.0	Positive	1.80	TP
12	82	Adenitis			Negative		TN

T/B = tumor-to-background; IEQ = inferoexternal quadrant; TP = true-positive; SEQ = superoexternal quadrant; FN = false-negative; SIQ = superointernal quadrant; FP = false-positive; TN = true-negative.

iodide. Two hours after the tracer administration, planar whole-body anterior and posterior images were obtained with a dual-head gamma camera (MultiSPECT 2; Siemens, Hoffman Estates, IL) equipped with medium-energy collimators (photopeak, 159 keV; 20% window; scan speed, 15 cm/min). Subsequently, 5-min lateral spot images of the breasts were acquired. Therefore, the patient was repositioned in a prone position with her arms placed above the head. A dedicated foam cushion with 2 cutouts was used. To avoid cross-contamination from 1 breast to the contralateral breast, a lead shield was inserted between the 2 cutouts. This allowed simultaneous acquisition of both the healthy and the suspected diseased breast. Additional shielding was placed on each patient's back to reduce scatter activity from the liver.

The study protocol was approved by the Ethics Committee of the Free University of Brussels and the Institutional Review Board of the George Washington University Medical Center. All patients gave written informed consent.

Image Evaluation of Spot Images

A focal increased uptake of the tracer was considered pathologic, whereas a homogeneous distribution was characteristic of a normal scan. Tracer uptake was quantified by placing a small region of interest (ROI) on the lesion and on normal tissue (background) in the same breast. Ratios of the maximum counts per pixel in the lesion ROI versus mean counts per pixel in the background ROI were calculated.

RESULTS

The biodistribution pattern of P-¹²³I-MBA was characterized by low blood-pool activity and low accumulation in the brain and lungs. The tracer was taken up predominantly by the liver, although the kidneys and the bladder were also visualized as an important excretion route.

Patient specifications are summarized in Table 1. Histopathologic examination revealed 9 invasive ductal and 2

invasive lobular breast carcinomas. The size of the tumors varied from 1.4 to 5.5 cm. One patient (patient 10) was excluded from the data analysis because poor image quality did not allow correct image interpretation. Focal uptake of P-¹²³I-MBA was observed in 8 of 10 patients with confirmed breast cancer. The calculated tumor-to-normal tissue ratios ranged from 1.36 to 2.75, with a mean value of 2.04. Examples of lateral images are shown in Figure 1. Areas with an increased focal activity could be clearly identified on the lateral views. They were difficult to detect on anterior or posterior images—particularly, lesions in the right breast tend to be obscured by high background liver activity. No focal uptake was seen in a patient (patient 12) with necrotic adenitis. Bilateral uptake of P-¹²³I-MBA was observed in patient 8 (Fig. 2), whereas mammography revealed a mass in only 1 breast. The lesion that was interpreted as normal on the mammogram had a tumor-to-background ratio of 2.08. Follow-up of this patient up to 6 mo did not reveal any

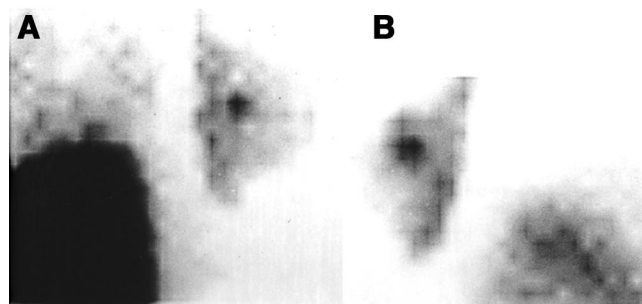


FIGURE 1. P-¹²³I-MBA scintigraphy in 2 patients with primary breast cancer of invasive ductal type. Tumor was localized in laterosuperior quadrant of right breast (A) and left breast (B).

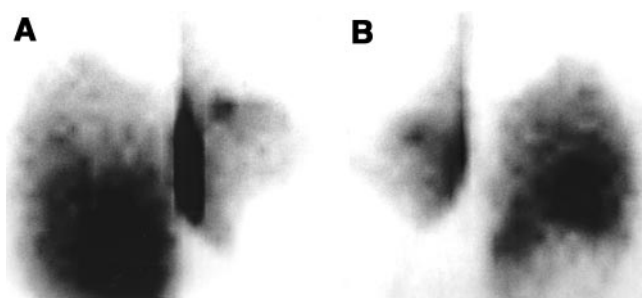


FIGURE 2. Right (A) and left (B) planar breast images of patient presenting bilateral uptake of P-¹²³I-MBA in superior part of breasts. Focal accumulation in left breast (B) did not correspond to known lesion on mammography and could not be confirmed as malignant after follow-up.

further malignancies. Except for this patient, a normal tracer distribution was observed for all contralateral breasts. No accumulation of P-¹²³I-MBA was seen in an invasive ductal carcinoma localized in the laterosuperior quadrant of the left breast (patient 3) and 1 invasive lobular carcinoma in the mediosuperior quadrant of the right breast (patient 9). In each case, quite a large tumor was involved (5.5 and 4.0 cm, respectively).

DISCUSSION

We demonstrated in a limited number of patients that P-¹²³I-MBA accumulates in breast tumors with an average tumor-to-background ratio of 2.04. Good quality images were obtained in most of the patients by lateral acquisition of the breasts. The objective of this preliminary study was not to evaluate the diagnostic value of P-¹²³I-MBA but rather to investigate the ability of the tracer to concentrate in breast tumor. All patients had a high probability of malignant disease and all tumors were >1.4 cm in size. However, no correlation was noted between P-¹²³I-MBA uptake and the tumor size ($r = 0.03$). If P-¹²³I-MBA indeed acts as a proliferation marker, we hypothesize that the uptake is proportional to the level of sigma receptor expression, which is not necessarily associated with the tumor size. Wheeler et al. (2) demonstrated either no correlation with tumor size or both the sigma receptors' density and the number of proliferative cells tended to decrease with increasing tumor size.

Interestingly, no uptake of radiolabeled P-¹²³I-MBA was found in a case of local inflammation of the breast and in 2 patients presented with fibrocystic disease. This is important

because the presence of fibrocystic tissue can seriously complicate physical and radiologic examinations.

In 2 cases of histopathologically confirmed breast cancer, no abnormal uptake of P-¹²³I-MBA was observed. Definite explanation for these false-negative results is lacking because receptor expression was not investigated in this study. It is identified though that different breast cancer cell types show differences in sigma receptor expression (4). Some cell lines express both sigma-1 and sigma-2 receptors, whereas others express only sigma-2 receptors.

Future studies will focus on the correlation between in vivo uptake of P-¹²³I-MBA and tumor proliferation. It has been demonstrated that proliferative cells express about 10 times more sigma-2 sites per cell compared with that of cells in the quiescent state (2). Sigma-2 receptor expression may thus be a marker for the proliferative activity of a tumor. On the other hand, sigma-1 receptor expression shows no correlation with proliferation (5). These differences between sigma-1 and sigma-2 receptors merit further investigation.

CONCLUSION

Sigma receptor scintigraphy with P-¹²³I-MBA allows in vivo visualization of breast cancer. The absence of focal uptake in patients with fibrocystic disease, local inflammation of the breast, and the healthy contralateral breast suggests a specific uptake mechanism of the tracer. More extensive studies are needed to assess the relationship between P-¹²³I-MBA uptake and cell proliferation. The availability of a PET or SPECT tracer that accumulates according to the proliferative activity of a tumor could offer a powerful tool to monitor the response to therapy in a noninvasive manner.

REFERENCES

1. Caveliers V, Everaert H, Lahoutte T, Dierickx LO, John CS, Bossuyt A. Labelled sigma receptor ligands: can their role in neurology and oncology be extended? *Eur J Nucl Med.* 2001;28:133–135.
2. Wheeler KT, Wang LM, Wallen CA, et al. Sigma-2 receptors as a biomarker of proliferation in solid tumours. *Br J Cancer.* 2000;82:1223–1232.
3. John CS, Bowen WD, Fisher SJ, et al. Synthesis, in vitro pharmacologic characterization, and preclinical evaluation of N-[2-(1'-piperidinyl)ethyl]-3-[¹²⁵I]iodo-4-methoxy-benzamide (P[¹²⁵I]MBA) for imaging breast cancer. *Nucl Med Biol.* 1999;26:377–382.
4. Vilner BJ, John CS, Bowen WD. Sigma-1 and sigma-2 receptors are expressed in a wide variety of human and rodent tumour cell lines. *Cancer Res.* 1995;55:408–413.
5. Simony-Lafontaine J, Esslimani M, Bribes E, et al. Immunocytochemical assessment of sigma-1 receptor and human sterol isomerase in breast cancer and their relationship with a series of prognostic factors. *Br J Cancer.* 2000;82:1958–1966.



The Journal of
NUCLEAR MEDICINE

Sigma Receptor Scintigraphy with *N*-[2-(1'-Piperidiny)Ethyl]-3-¹²³I-Iodo-4-Methoxybenzamide of Patients with Suspected Primary Breast Cancer: First Clinical Results

Vicky Caveliers, Hendrik Everaert, Christy S. John, Tony Lahoutte and Axel Bossuyt

J Nucl Med. 2002;43:1647-1649.

This article and updated information are available at:
<http://jnm.snmjournals.org/content/43/12/1647>

Information about reproducing figures, tables, or other portions of this article can be found online at:
<http://jnm.snmjournals.org/site/misc/permission.xhtml>

Information about subscriptions to JNM can be found at:
<http://jnm.snmjournals.org/site/subscriptions/online.xhtml>

The Journal of Nuclear Medicine is published monthly.
SNMMI | Society of Nuclear Medicine and Molecular Imaging
1850 Samuel Morse Drive, Reston, VA 20190.
(Print ISSN: 0161-5505, Online ISSN: 2159-662X)

© Copyright 2002 SNMMI; all rights reserved.

 SOCIETY OF
NUCLEAR MEDICINE
AND MOLECULAR IMAGING