

Impact of FDG PET on Patients with Differentiated Thyroid Cancer Who Present with Elevated Thyroglobulin and Negative ^{131}I Scan

Beate Schlüter, Karl H. Bohuslavizki, Wolfgang Beyer, Mykaylo Plotkin, Ralph Buchert, and Malte Clausen

Department of Nuclear Medicine, University Hospital Eppendorf, Hamburg, Germany

FDG PET is increasingly performed in patients with differentiated thyroid cancer who present with elevated human thyroglobulin (hTg) levels and negative ^{131}I scan. The aim of this study was to evaluate the impact of FDG PET on treatment in these patients. **Methods:** A total of 118 FDG PET studies were performed on 64 patients, and follow-up data were available for all patients. Whole-body images were acquired 1 h after intravenous injection of 370 MBq (10 mCi) FDG using a PET scanner with an axial field of view of 16.2 cm. Tumor-suspicious FDG PET studies were evaluated by histology, cytology, ^{131}I uptake, CT or MRI, and follow-up of hTg levels. The therapeutic consequence was noted for each patient. Moreover, results of FDG PET were correlated with hTg levels. **Results:** Forty-four patients had positive scans, which were proven to be true-positive in 34 patients, whereas 7 patients had false-positive findings. Two patients exhibited a secondary malignancy. One patient did not fit in any category, having true-positive, false-positive, and false-negative findings. On the other hand, 20 patients had negative scans. These were true-negative findings in 5 patients, whereas the remaining 15 patients had false-negative results. Accordingly, the positive predictive value of FDG PET was 83% (34/41), whereas the negative predictive value was 25% (5/20). Treatment was directly changed in 19 of 34 patients with true-positive PET studies: 18 patients had further surgery, and 4 patients were referred for external irradiation, 3 of them after incomplete removal of local recurrences. FDG PET showed widespread disease in 7 patients; thus, palliative treatment, rather than curative therapy, was initiated. True-positive FDG PET findings were correlated positively with increasing hTg levels (i.e., FDG PET was true-positive in 11%, 50%, and 93% of patients with hTg levels of <10, 10–20, and >100 $\mu\text{g/L}$, respectively). **Conclusion:** FDG PET is a valuable diagnostic tool in patients with differentiated thyroid cancer who present with increased hTg levels and negative ^{131}I scans because it permits selection of patients for surgery, which may be curative. FDG PET is most promising at hTg levels of >10 $\mu\text{g/L}$.

Key Words: thyroid cancer; FDG PET; treatment strategy

J Nucl Med 2001; 42:71–76

Elevated human thyroglobulin (hTg) levels and negative ^{131}I scans represent both diagnostic and therapeutic problems of patients with differentiated thyroid cancer. Although ^{131}I scanning has a very high specificity of 99%–100%, the amount of ^{131}I -positive recurrences is about 50%–60% in papillary and 64%–67% in follicular thyroid cancer only (1–3). Because progression in differentiated thyroid cancer occurs very slowly, patients have a relatively good prognosis to live for many years—even after metastatic disease has been detected—provided adequate treatment has been offered. However, patients with metastatic disease and negative ^{131}I scans are usually not treated with high-dose radioiodine. Thus, ^{131}I -negative metastases need to be removed surgically, provided they can be localized. Although metastases of differentiated thyroid cancer grow rather slowly, they consume a considerable amount of glucose compared with that of normal tissues. Consequently, FDG PET has been suggested for patients with negative ^{131}I scans and elevated hTg levels for the detection of both local recurrences and metastases of differentiated thyroid cancer (4–18). Moreover, the German interdisciplinary consensus conference recently classified FDG PET as a “1a-indication” in these patients (19,20).

However, the value of FDG PET for patient management is still unclear for patients with negative ^{131}I scans and elevated hTg levels. Therefore, the aim of this retrospective study was to evaluate the impact of FDG PET on both follow-up and treatment of these patients. Initial results have been published briefly elsewhere (21–25).

MATERIALS AND METHODS

Patients

A total of 118 FDG PET studies were performed on 64 patients (39 women, 25 men; age range, 21–81 y) with histologically proven differentiated thyroid cancer. FDG PET was performed repeatedly in 21 patients. All patients had a complete clinical history and physical examination. Most of them ($n = 48$) had negative ^{131}I scans and elevated hTg levels (hTg ≥ 2.0 $\mu\text{IU/mL}$) under thyroid-stimulating hormone (TSH) stimulation (TSH ≥ 30 $\mu\text{IU/mL}$), including 4 patients who had FDG PET later, when hTg levels were negative under TSH suppression (TSH ≤ 0.1 $\mu\text{IU/mL}$). In spite of a positive ^{131}I scan, additional tumor lesions were suspected in 7 patients with elevated hTg

Received Nov. 29, 1999; revision accepted Apr. 4, 2000.

For correspondence or reprints contact: Karl H. Bohuslavizki, MD, PhD, Department of Nuclear Medicine, University Hospital Eppendorf, Martini-strasse 52, D-20246 Hamburg, Germany.

levels. In the remaining 9 patients, thyroid cancer tissue was suspected because of findings on other imaging modalities (e.g., sonography, radiography of the chest, CT), although hTg levels were not elevated. Patients were followed-up at least until a decision was made concerning treatment strategy. Therefore, the follow-up interval amounted to 1–64 mo.

PET Scanning

Patients fasted for at least 12 h before PET scanning to minimize blood insulin levels and glucose use by normal tissue (26). Whole-body emission images were acquired without attenuation correction 60 min after intravenous injection of 370 MBq FDG using an ECAT EXACT 47 (921) PET scanner (Siemens/CTI, Knoxville, TN) with an axial field of view of 16.2 cm.

Patients were placed in the PET gantry in a supine position with both arms at the side of the body. Images were acquired for 8 min per bed position covering the neck down to the upper waist. The second set of images was acquired from the waist down to the upper legs. Before the second acquisition, patients were asked to empty the bladder (to decrease urine activity) and to raise their arms (to minimize photon attenuation in the abdomen). Emission data were reconstructed by filtered backprojection using a Hanning filter with a cutoff frequency of 0.4 unit of the Nyquist frequency. Transaxial spatial resolution was ~12-mm full width at half maximum. PET images were printed on x-ray films and since 1998 have been printed on transparency film (Helios 810; Sterling Diagnostic Imaging, Bad Homburg, Germany) using a linear gray scale with highest activity displayed in black (27). Note that FDG PET was performed under varying TSH levels.

Evaluation

To evaluate the results of FDG PET, suspicious findings were correlated with histology, cytology, ^{131}I uptake, CT, MRI, and hTg level. Because FDG PET was performed twice or multiple times on 20 patients, FDG PET was evaluated on a patient basis rather than on a study basis or a lesion basis. Thus, for each patient, the FDG PET study selected for evaluation was the one that influenced further treatment of the patient most. FDG PET was then classified as:

- true-positive, if pathologic FDG uptake was proven by histology, cytology, or correlative imaging techniques and, therefore, led to a change of therapy
- false-positive, if pathologic FDG uptake could not be verified and, therefore, had no clinical consequence
- true-negative if no FDG uptake was found and patients had

neither elevated hTg levels nor any evidence of recurrence in subsequent follow-up

- false-negative if no FDG uptake was found in spite of elevated hTg levels or positive findings in correlative imaging methods

Moreover, results of FDG PET were correlated with the respective hTg level of the patient at the time of the study. Intervals of <10, 10–20, 20–50, 50–100, and >100 $\mu\text{g/L}$ were chosen for serum hTg levels. Then, true-positive FDG PET studies at a certain hTg level were divided by the total number of patients investigated at that hTg level. The data for stimulated and suppressed TSH were analyzed separately.

RESULTS

Positive FDG PET

Forty-four of 64 patients had pathologic FDG uptake, and, thus, were classified as positive. In 2 patients (81-y-old man and 78-y-old woman), FDG PET revealed a second malignancy, which definitely changed the treatment strategy of these patients. A further patient (51-y-old woman) could not be classified according to the above criteria because FDG PET revealed true-positive as well as false-positive and false-negative findings, which changed the treatment strategy several times during follow-up. Therefore, these patients were excluded from the analysis, and the 41 remaining patients with positive findings on FDG PET were eligible for complete evaluation.

Validation of FDG PET findings and treatment strategy chosen is summarized in Table 1 and Table 2, respectively. FDG PET findings were true-positive in 34 of 41 patients. Treatment was directly changed in 19 of 34 patients with true-positive PET studies: 18 patients had further surgery (Fig. 1), and 4 patients were referred for external irradiation, 3 of them (57-y-old, 74-y-old, and 72-y-old women) after incomplete removal of local recurrences (Fig. 2). One of these patients (38-y-old woman) who presented with local recurrence underwent surgery in the same location 2 y later (data not included in Tables 1 and 2). Ten patients received ^{131}I therapy when a follow-up ^{131}I scan revealed a positive finding in the location of the FDG-positive lesions. ^{131}I therapy was performed on 2 of these patients after incom-

TABLE 1
Validation of FDG PET Findings by Various Methods Applied

FDG PET	n	Validation				
		Histology	Positive ^{131}I	CT or MRI	hTg follow-up	Cytology
True-positive	34	17	8	9	0	0
False-positive	7	2	0	2	2	1
True-negative	5	0	0	0	5	0
False-negative	15	2	1	1	11	0

n = number of patients.

TABLE 2
Treatment Strategy Drawn from Results of FDG PET

FDG PET	n	Treatment				
		Surgery	¹³¹ I therapy	External irradiation	NCTO	NTN
True-positive*	34	18	10	4	7	0
False-positive	7	2	0	0	0	5
True-negative	5	0	0	0	0	5
False-negative	15	3	1	0	11	0

* Figures in first line exceed number of patients because some patients got more than one treatment (e.g., surgery and external irradiation).

n = number of patients; NCTO = no curative treatment option available because of widespread disease; NTN = no treatment necessary.

plete resection of distant metastases (65-y-old and 64-y-old men). Note that the number of treatments summarized in line 1 in Table 2 ($n = 39$) exceeds the number of patients ($n = 34$) because of the 5 patients who had surgery and either external irradiation or ¹³¹I therapy. FDG PET showed widespread disease in 7 patients (e.g., in case of multiple pulmonary metastases); thus, palliative treatment, rather than curative therapy, was initiated.

In contrast, positive FDG PET imaging of the remaining 7 of 41 patients turned out to be false-positive (Table 1). This was confirmed by histology ($n = 2$), cytology ($n = 1$), CT or MRI ($n = 2$), and subsequent measurements of hTg levels during follow-up ($n = 2$). Consequently, further treatment was not justified in these patients. However, 2 of these 7 patients underwent surgery, and no pathologic findings were found (Table 2).

Negative FDG PET

A physiologic pattern of FDG uptake was found in 20 of 64 patients; thus, FDG PET was classified as negative. Findings in 5 of these patients were proven to be true-negative by negative hTg levels during further follow-up (Table 1); consequently, these patients did not receive any specific therapy (Table 2). FDG PET of the remaining 15 patients turned out to be false-negative (Table 1), as proven by CT or MRI ($n = 3$), ¹³¹I uptake ($n = 1$), or persistently

elevated or rising hTg levels ($n = 11$). The 3 patients who presented with positive CT or MRI findings were referred for surgery, and recurrent or metastatic disease of differentiated thyroid cancer was proven by histology in 2 of them thus far. One patient who had a positive ¹³¹I scan within the follow-up received ¹³¹I therapy. No specific treatment could be offered to the remaining 11 patients (Table 2) because CT, MRI, or ¹³¹I scanning did not reveal the origin of persistently elevated or rising hTg levels.

FDG PET and hTg Levels

The fraction of true-positive FDG PET was correlated positively with increasing hTg levels (Table 3). FDG PET findings were true-positive in 11%, 50%, and 93% of patients with hTg levels of <10, 10–20, and >100 μg/L, respectively. The fraction of true-positive FDG PET was independent of TSH level (i.e., whether hTg measurement was performed under TSH stimulation or suppression).

DISCUSSION

Most patients with differentiated thyroid cancer who present with ¹³¹I-accumulating metastases receive ¹³¹I treatment, which may be curative. Patients without ¹³¹I-avid (negative ¹³¹I scan) metastases lack this option. Nevertheless, curative treatment can be achieved in these patients,

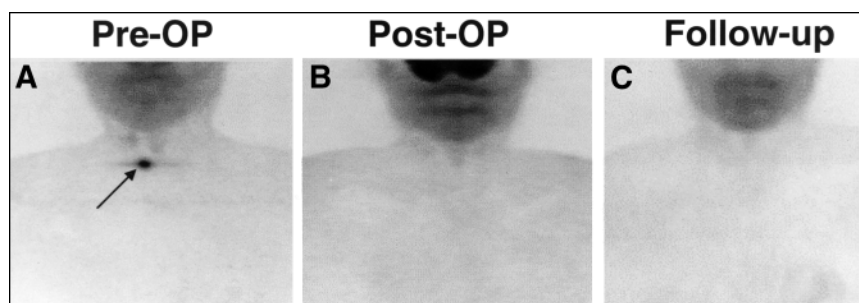


FIGURE 1. FDG-positive local recurrence (arrow) in 49-y-old man who presented with negative ¹³¹I scan after thyroidectomy and two courses of radioiodine treatment of papillary thyroid cancer initially staged as pT2bN0M0 (A). No tumor remnants were seen after further surgery (B) and during follow-up (C). Consequently, hTg levels dropped from 30 μg/L (preoperative) to 5 μg/L (postoperative) and 11 μg/L (follow-up). Images show maximum-intensity projections in anterior views.

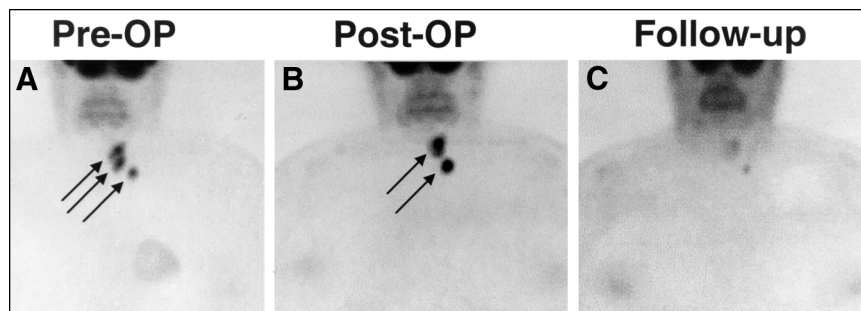


FIGURE 2. FDG-positive residual tumor and lymph node metastasis (arrows) in 57-y-old woman who presented after incomplete thyroidectomy and tumor resection of papillary thyroid cancer initially staged as pT4bN1Mx (A). FDG PET was performed to assess tumor extension and possible metastases before further surgery. Residual tumor masses were seen after additional surgery (B), and external irradiation yielded good response (C). After irradiation, hTg levels dropped from 24 to 1.5 $\mu\text{g/L}$. Images show maximum-intensity projections in anterior views.

provided tumor tissues are resected completely, before widespread metastatic disease occurs. Therefore, imaging methods that allow an accurate detection of recurrence or metastases (or both) of differentiated thyroid cancer in an early stage are crucial with respect to both prognosis and survival of the patients.

Imaging modalities that can be offered to a patient in this clinical setting (i.e., differentiated thyroid cancer, elevated hTg levels, and negative ^{131}I scan) include sonography of neck and abdomen, chest radiography, bone scanning, CT, and MRI. Apart from these procedures, PET with FDG has been used for several years in these patients. One of the first reports on FDG PET in three patients suffering from differentiated thyroid cancer was published by Joensuu and Ahonen (4) almost 13 y ago. Since that time, several studies have shown the ability of FDG PET for the detection of ^{131}I -negative lesions in differentiated thyroid cancer (6,16–18). This was confirmed by some studies with larger numbers of patients (5,9–11,14,15). In the meantime, FDG PET has been accepted as a valuable imaging method for patients with differentiated thyroid cancer who present with elevated hTg levels and negative ^{131}I scans. Consequently, an interdisciplinary consensus conference held in Germany in 1996 and 1997 on the use of FDG PET in oncology classified this as a “1a-indication,” meaning that FDG PET has been

shown to have “proven clinical value” in this clinical setting (19,20).

Although the value of FDG PET in the detection of thyroid cancer tissue is undeniable, the consequences of FDG-positive lesions in terms of clinical outcome are still under discussion. In general, FDG uptake and the concomitant loss of ^{131}I uptake are known as a functional sign of dedifferentiation (4,9,17). Lietzenmayer et al. (28) observed that the intensity of FDG uptake is correlated with progressive dedifferentiation. They quantified FDG uptake by standard uptake values and found that an intense FDG uptake with the concomitant loss of ^{131}I uptake indicates progress. Patients with an initially high standard uptake value had an unfavorable clinical course, whereas decreasing FDG uptake together with a persistent ^{131}I uptake was associated with a good prognosis. As the pathophysiologic basis for these observations, a correlation of the expression of the glucose transporter GLUT 1 and the grade of dedifferentiation of thyroid cancer was described by Schönberger et al. (29). However, one specific patient may exhibit either ^{131}I -avid lesions or FDG-avid lesions and even lesions that take up both radiotracers (16–18). Accordingly, in this study FDG uptake was also associated with a more aggressive behavior of metastatic lesions. Three patients with FDG-positive cervical tumor tissue underwent external irradiation after incomplete surgical resection (Fig. 2). In addition, FDG PET revealed extensive disease in seven patients, which changed the treatment regimen from a curative to a more palliative approach. On the other hand, it is important to note that four patients who underwent further surgery on the basis of locoregional findings had no signs for recurrence except for a slightly elevated hTg level later on (Table 3). Therefore, although FDG uptake can be considered as a sign of dedifferentiation, it does not automatically predict an unfavorable prognosis. Moreover, ^{131}I -avid tumor tissue developed in some patients in the same location as earlier FDG-positive findings and the patients received ^{131}I therapy later on. This observation is important because it indicates that further ^{131}I scans may be promising even if a finding is only FDG positive. Hence, FDG-positive recurrences and

TABLE 3
True-Positive FDG PET Findings with Respect to
hTg Level

hTg ($\mu\text{g/L}$)	TSH ($\mu\text{IU/mL}$)		Σ
	>30	≤ 0.1	
<10	2/12	0/7	2/19
10–20	3/6	1/2	4/8
20–50	6/8	2/2	8/10
50–100	4/7	1/1	5/8
>100	9/10	5/5	14/15

One patient could not be considered because his hTg level was unknown.

metastases may indicate dedifferentiated and more aggressive tumor tissue but do not automatically predict a worse outcome.

These conclusions are supported by observations relating to hTg production. Although thyroid cancer tissue has lost the ability of taking up and storing iodine, it is primarily able to produce hTg, which indicates only partial differentiation. In our patients, FDG PET was more promising when the hTg level rose as described by others (13,15,30). Accordingly, Sophocleous et al. (31) reported in 1997 that false-negative hTg levels under TSH stimulation are rare (i.e., in the range of 3%–4% of patients with recurrences). The most probable explanation for this finding is the tumor mass itself: hTg production rises with an increasing number of tumor cells, and at a certain size the lesion will be detected as FDG positive. Similar observations have been made relating to ^{131}I -avid tumor tissue. Arning et al. (32) found only a few patients with ^{131}I -avid metastases and low hTg levels. The well-known observation that maximum hTg levels decrease after ^{131}I therapy although ^{131}I scans are negative indicates ^{131}I -avid micrometastases, which are too small to be visualized by scintigraphy. Therefore, the ability to produce hTg is obviously maintained longer in the process of dedifferentiation than is the ability to take up ^{131}I . This can be explained by the fact that the mechanisms necessary for iodine storage (i.e., iodination, iodization, and synthesis of hTg) are much more complex than is the synthesis of hTg alone.

We found that the fraction of true-positive FDG PET was correlated positively with increasing hTg levels (Table 3). FDG PET findings were true-positive in 11%, 50%, and 93% of patients with hTg levels of <10, 10–20, and >100 $\mu\text{g/L}$, respectively. This observation is in accordance with Lubin et al. (2), who reported that a negative ^{131}I scan was seen predominantly when the hTg level was <10 $\mu\text{g/L}$ under TSH suppression. In addition, the cutoff level for determination of hTg as elevated is estimated to be between 1 and 10 $\mu\text{g/L}$ (33,34). Thus, our data indicate that FDG PET is worthwhile, especially at hTg levels of >10 $\mu\text{g/L}$.

CONCLUSION

FDG PET is a valuable diagnostic tool for patients with differentiated thyroid cancer who present with increased hTg levels and negative ^{131}I scans because it permits selection of patients for surgery, which may be curative. FDG PET is most promising at hTg levels of >10 $\mu\text{g/L}$.

REFERENCES

- Galloway RJ, Smallridge RC. Imaging in thyroid cancer. *Endocrinol Metab Clin North Am*. 1996;25:93–113.
- Lubin E, Mechlis-Frisch S, Zatz S, et al. Serum thyroglobulin and iodine-131 whole-body scan in the diagnosis and assessment of treatment for metastatic differentiated thyroid carcinoma. *J Nucl Med*. 1994;35:257–262.
- Samaan NA, Schultz PN, Haynie TP, Ordenez NG. Pulmonary metastasis of differentiated thyroid carcinoma: treatment results in 101 patients. *J Clin Endocrinol Metab*. 1985;60:376–380.
- Joensuu H, Ahonen A. Imaging of metastases of thyroid carcinoma with fluorine-18 fluorodeoxyglucose. *J Nucl Med*. 1987;28:910–914.
- Wang W, Macapinlac H, Larson SM, et al. [^{18}F]-2-fluoro-2-deoxy-D-glucose positron emission tomography localizes residual thyroid cancer in patients with negative diagnostic ^{131}I whole body scans and elevated serum thyroglobulin levels. *J Clin Endocrinol Metab*. 1999;84:2291–2302.
- Sisson JC, Ackermann RJ, Meyer MA, Wahl RL. Uptake of ^{18}F -fluoro-2-deoxy-D-glucose by thyroid cancer: implications for diagnosis and therapy. *J Clin Endocrinol Metab*. 1993;77:1090–1094.
- So Y, Chung JK, Lee DS, Lee MC, Cho BY, Koh CS. FDG-PET can localize metastatic sites of differentiated thyroid carcinoma in I-131 scan negative patients [abstract]. *J Nucl Med*. 1998;39(suppl):257P–258P.
- Uematsu H, Sadato N, Ohtsubo T, et al. Fluorine-18-fluorodeoxyglucose PET versus thallium-201 scintigraphy evaluation of thyroid tumors. *J Nucl Med*. 1998;39:453–459.
- Grünwald F, Schomburg A, Bender H, et al. Fluorine-18 fluorodeoxyglucose positron emission tomography in the follow-up of differentiated thyroid cancer. *Eur J Nucl Med*. 1996;23:312–319.
- Grünwald F, Menzel C, Bender H, et al. Comparison of ^{18}F -FDG-PET with ^{131}I iodine and $^{99\text{m}}\text{Tc}$ -sestamibi scintigraphy in differentiated thyroid cancer. *Thyroid*. 1997;7:327–335.
- Lawson MA, Seabold JE, Kirchner PT, et al. Strengths and weaknesses of F-18-FDG-PET in the follow-up of high-risk thyroid cancer patients with negative diagnostic I-131 scans [abstract]. *J Nucl Med*. 1998;39(suppl):19P.
- Altenvoerde G, Lerch H, Kuwert T, Matheja P, Schafers M, Schober O. Positron emission tomography with F-18-deoxyglucose in patients with differentiated thyroid carcinoma, elevated thyroglobulin levels, and negative iodine scans. *Langenbecks Arch Surg*. 1998;383:160–163.
- Adams S, Baum RP, Hertel A, et al. Fluorine-18-fluorodeoxyglucose (FDG) PET for detection of occultly metastasized thyroid carcinoma [in German]. In: Usadel KH, Weinheimer B, eds. *Schilddrüse 1995: Schilddrüsenerkrankungen in verschiedenen Lebensabschnitten*. Berlin, Germany: Walter de Gruyter; 1996:424–431.
- Dietlein M, Scheidhauer K, Voth E, Theissen P, Schicha H. Fluorine-18 fluorodeoxyglucose positron emission tomography and iodine-131 whole-body scintigraphy in the follow-up of differentiated thyroid cancer. *Eur J Nucl Med*. 1997;24:1342–1348.
- Dietlein M, Scheidhauer K, Voth E, Theissen P, Schicha H. Follow-up of differentiated thyroid cancer: what is the value of FDG and sestamibi in the diagnostic algorithm? *Nuklearmedizin*. 1998;37:6–11.
- Feine U, Lietzenmayer R, Hanke JP, Wöhrle H, Müller-Schauenburg W. ^{18}F -FDG whole body PET in differentiated thyroid carcinoma: flipflop in uptake patterns of ^{18}F -FDG and ^{131}I [in German]. *Nuklearmedizin*. 1995;34:127–134.
- Feine U, Lietzenmayer R, Hanke J-P, Held J, Wöhrle H, Müller-Schauenburg W. Fluorine-18-FDG and iodine-131-iodide uptake in thyroid cancer. *J Nucl Med*. 1996;37:1468–1472.
- Feine U. Fluor-18-deoxyglucose positron emission tomography in differentiated thyroid cancer. *Eur J Endocrinol*. 1998;138:492–496.
- Reske SN, Bares R, Büll U, Guhlmann A, Moser E, Wannenmacher MF. Clinical value of positron emission tomography (PET) in oncologic questions: results of an interdisciplinary consensus conference [in German]. *Nuklearmedizin*. 1996;35:42–52.
- Reske SN. Positron emission tomography in oncology [in German]. *Dtsch Ärzteblatt*. 1998;95:B-1495–B-1497.
- Schlüter B, Grimm-Riepe C, Beyer W, Schirren-Bumann K, Lübeck M, Clausen M. Histological verification of FDG-positive findings in differentiated thyroid carcinoma [in German; abstract]. *Nuklearmedizin*. 1997;36:A85.
- Schlüter B, Plotkin M, Beyer W, Mester J, Clausen M. Indication of FDG-PET in differentiated thyroid cancer [in German; abstract]. *Nuklearmedizin*. 1998;37:A66.
- Schlüter B, Grimm-Riepe C, Beyer W, Lübeck M, Schirren-Bumann K, Clausen M. Histological verification of positive fluorine-18 fluorodeoxyglucose findings in patients with differentiated thyroid cancer. *Langenbecks Arch Surg*. 1998;383:187–189.
- Schlüter B, Plotkin M, Klutmann S, et al. Influence of ^{18}F -FDG-PET on treatment in patients with differentiated thyroid cancer [abstract]. *J Nucl Med*. 1999;40(suppl):234P.
- Schlüter B, Klutmann S, Plotkin M, Beyer W, Mester J, Clausen M. Treatment consequence of FDG-PET in patients with differentiated thyroid carcinoma [in German; abstract]. *Nuklearmedizin*. 1999;38:A86.
- Minn H, Leskinen-Kallio S, Lindholm P, et al. [^{18}F]-fluorodeoxyglucose uptake in tumors: kinetic vs. steady-state methods with reference to insulin. *J Comput Assist Tomogr*. 1993;17:115–123.

27. Bleckmann C, Buchert R, Schulte U, et al. PET in oncology: image analysis using a computer monitor versus standardized film documentation [in German]. *Nuklearmedizin*. 1999;38:56–60.
28. Lietzenmayer R, Müller-Berg M, Thelen MH, Dohmen BM, Müller-Schauenburg W, Bares R. Follow-up after radioiodine treatment of differentiated thyroid cancer [in German; abstract]. *Nuklearmedizin*. 1998;37:A23.
29. Schönberger J, Rüschhoff J, Meyringer R, Marienhagen J, Hofstädter F, Eilles C. Over expression of glucose transporter 1 as a sign of increased malignancy in thyroid carcinoma: an immunohistochemical study [in German; abstract]. *Nuklearmedizin*. 1997;36:A97.
30. Adams S, Baum RP, Hertel A, Schumm-Dräger PM, Usadel KH, Hor G. Metabolic (PET) and receptor (SPET) imaging of well- and less well-differentiated tumours: comparison with the expression of the Ki-67 antigen. *Nucl Med Commun*. 1998;19:641–647.
31. Sophocleous S, Ehrenheim C, Fischer J, Hundeshagen H. Long-term follow-up and therapeutic results in patients with low-risk differentiated thyroid carcinoma [in German]. *Nuklearmedizin*. 1997;36:93–102.
32. Arning G, Ehrenheim C, Schober O, Hundeshagen H. ¹³¹I-accumulating pulmonary and bone metastases of differentiated thyroid cancer with low serum thyroglobulin levels: an exception in tumor follow-up [in German]? *Nuklearmedizin*. 1987;26:139–142.
33. Mazzaferri EL, Robyn J. Postsurgical management of differentiated thyroid carcinoma. *Otolaryngol Clin North Am*. 1996;29:637–662.
34. Ozata M, Suzuki S, Miyamoto T, Liu RT, Fierro-Renoy F, Degroot LJ. Serum thyroglobulin in the follow-up of patients with treated differentiated thyroid cancer. *J Clin Endocrinol Metab*. 1994;79:98–105.



The Journal of
NUCLEAR MEDICINE

Impact of FDG PET on Patients with Differentiated Thyroid Cancer Who Present with Elevated Thyroglobulin and Negative ^{131}I Scan

Beate Schlüter, Karl H. Bohuslavizki, Wolfgang Beyer, Mykaylo Plotkin, Ralph Buchert and Malte Clausen

J Nucl Med. 2001;42:71-76.

This article and updated information are available at:
<http://jnm.snmjournals.org/content/42/1/71>

Information about reproducing figures, tables, or other portions of this article can be found online at:
<http://jnm.snmjournals.org/site/misc/permission.xhtml>

Information about subscriptions to JNM can be found at:
<http://jnm.snmjournals.org/site/subscriptions/online.xhtml>

The Journal of Nuclear Medicine is published monthly.
SNMMI | Society of Nuclear Medicine and Molecular Imaging
1850 Samuel Morse Drive, Reston, VA 20190.
(Print ISSN: 0161-5505, Online ISSN: 2159-662X)

© Copyright 2001 SNMMI; all rights reserved.