

PET in Differentiation of Recurrent Brain Tumor from Radiation Injury*

Daniel D. Langleben and George M. Segall

Nuclear Medicine Service, Veterans Affairs Palo Alto Health Care System, Palo Alto, and Division of Nuclear Medicine, Stanford University School of Medicine, Stanford, California

The annual incidence of primary intracranial tumors is 7 to 19 cases per 100,000 people. The general approach to the treatment of brain neoplasms is surgical resection of solitary lesions or limited disease, followed by radiation therapy with or without chemotherapy. Multiple metastatic lesions are usually treated with whole-brain radiation. Radiation injury occurs in 5% to 37% of cases and can be difficult to differentiate from residual or recurrent malignancy by MRI. PET has been used to differentiate radiation injury from malignancy on the basis of differences in glucose uptake. Recent studies have reported the sensitivity and specificity of PET to be 81% to 86% and 40% to 94%, respectively. This article reviews the classification of primary brain tumors, the histologic changes associated with radiation injury, and the diagnostic and prognostic information provided by PET.

Key Words: PET; FDG; glioma; radiation injury; radiation necrosis
J Nucl Med 2000; 41:1861–1867

The annual incidence of primary intracranial tumors is 7 to 19 cases per 100,000 people (1,2). The incidence is 3.1 cases per 100,000 people at 0–4 y of age. The incidence decreases between 15 and 24 y and then increases steadily to a peak of 18 to 19 per 100,000 between 65 and 79 y. Primary central nervous system (CNS) neoplasms are the third leading cause of death between 15 and 35 y and the second leading neoplastic disease in children under 15 y (1). The World Health Organization (WHO) classification that relies on cellular origin is outlined in Table 1. Tumors of neuroepithelial origin are the most common, followed by tumors of meningeal, hematopoietic, and nerve sheath origin. In adults, most neuroepithelial tumors are from glial cells; common glial cells types are astrocytes, oligodendrocytes, ependymocytes, and subependymocytes. Tumors originating from the glia are collectively known as gliomas. Gliomas constitute over 90% of primary brain tumors in persons older than 20 y (3,4).

There have been numerous attempts to classify astrocyto-

mas, and there are several incongruous systems in use today, which sometimes contribute to the lack of clarity regarding which grade of tumor is being discussed (Table 2). Low- and high-grade astrocytoma refers to grades 1–2 and grades 3–4, respectively, of the Kernohan, Mayo, or WHO systems. The Mayo/St. Anne classification is based on nuclear atypia, mitoses, necrosis, and endothelial proliferation. Daumas-Duport et al. (5) and Black (6) reported a better reproducibility and correlation with survival using the Mayo/St. Anne system than its predecessors. The WHO grading system was introduced in 1979 in an attempt to provide a grading system that was based on morphology for all types of glioma (2,4). The system includes pilocytic astrocytoma, which is a posterior fossa tumor that occurs in children and has a better prognosis than astrocytoma in adults.

Neoplasms of ependymal origin are classified as ependymoma (WHO grade 2) and anaplastic ependymoma (WHO grade 3). Oligodendroglial neoplasms are classified as oligodendroglioma and anaplastic oligodendroglioma (WHO grades 2 and 3, respectively). Ependymomas and oligodendrogliomas rarely progress into highly malignant tumors with features of glioblastoma multiforme (i.e., high cellularity, necrosis, and endothelial proliferation) and are classified as WHO grade 4. Other primary brain tumors include neuroblastoma, retinoblastoma, lymphoma, and meningioma (4).

Brain metastases are up to 10 times more common than primary brain tumors and occur in 20% to 40% of patients with cancer. There are 170,000 new cases of brain metastases in the United States per year (7).

TREATMENT

The general approach for treating brain neoplasms is surgical resection of solitary lesions or limited disease, followed by radiation therapy with or without chemotherapy. Multiple metastatic lesions are usually treated with whole-brain radiation. Solitary primary and metastatic tumors may be treated with local field radiotherapy or stereotactic radiosurgery. The usual local field radiation dose for metastases is up to 40 Gy, for astrocytoma up to 50 Gy, and for glioblastoma multiform (GBM) up to 60 Gy. The dose is fractionated over 4 to 6 wk. Tumor response to treatment is proportionate to the dose in this range. Stereotac-

Received May 24, 2000; revision accepted Jul. 13, 2000.

For correspondence or reprints contact: George M. Segall, MD, Nuclear Medicine Service 115, VA Palo Alto Health Care System, 3801 Miranda Ave., Palo Alto, CA 94304.

*NOTE: FOR CE CREDIT, YOU CAN ACCESS THIS ACTIVITY THROUGH THE SNM WEB SITE (<http://www.snm.org>) UNTIL MAY 2001.

TABLE 1
WHO Classification of Primary Intracranial Tumors

| Classification | | | | | |
|----------------------|---------------------------|---------------------------|------------------------------------|---------------------|------------------------------|
| Neuroepithelial | Cranial and spinal nerves | Meninges | Lymphomas and hematopoietic tissue | Germ cell | Cysts and tumor-like lesions |
| Astrocytoma | Schwannoma | Meningioma (all variants) | Malignant lymphoma | Germinoma | Rathke cleft |
| Oligodendroglioma | Neurofibroma | Anaplastic meningioma | Plasmacytoma | Embryonal carcinoma | Epidermoid |
| Ependymoma | MPNST | Benign mesenchymal | Granulocytic sarcoma | Yolk sac | Dermoid |
| Mixed choroid plexus | | Malignant mesenchymal | Others | Choriocarcinoma | Colloid |
| Uncertain neuronal | | Primary melanocytic | | Teratoma | Enterogenous neuroglial |
| Pineal | | Uncertain | | Mixed germ cell | Granular cell |
| Embryonal | | | | | Hypothalamic |
| | | | | | Hamartoma |
| | | | | | Plasma cell |
| | | | | | Granuloma |

MPNST, malignant peripheral nerve sheath tumor.

tic radiosurgery is being used increasingly as an alternative to conventional radiotherapy or surgery. Radiosurgery uses a highly collimated beam of radiation that delivers a high dose to a lesion over a brief period of time (3,7,8).

RADIATION INJURY

Radiation injury to the brain is the major dose-limiting complication of radiotherapy. The term “radiation necrosis” is commonly used to describe radiation injury, but it is inaccurate because the pathology of radiation injury is not limited to necrosis (9,10). The incidence of radiation injury depends on the total dose and the rate of delivery (fractionation). Very young children are more susceptible than adults. Edema, vasculopathy, infection, and chemotherapy potentiate radiation injury. Some chemotherapy agents, such as nitrosurea, procarbazine, and vinca alkaloids, are directly neurotoxic. Other agents, such as adriamycin and methotrexate, potentiate radiation effects.

Radiation injury can be divided into acute, early-delayed, and late-delayed stages (Table 3). Late-delayed radiation injury (LDRI) occurs 4 mo to 10 y after radiation. Seventy percent of cases occur in the first 2 y. The primary mechanism of LDRI is vascular endothelial injury or direct damage to oligodendroglia (10). The white matter is affected

more than gray matter. The incidence of LDRI is 5% to 37% and increases with higher radiation doses (8,11). Symptoms of recurrent tumor and LDRI are similar. Both conditions can cause progressive deterioration and death. Treatment of LDRI ranges from conservative measures to control intracranial pressure to surgical excision of the edematous mass (1,2,7).

RADIOGRAPHIC EVALUATION

The typical appearance of brain tumors as well as LDRI is a contrast-enhancing mass, surrounded by edema and mass effect. Contrast enhancement with Gd diethylenetriamine pentaacetic acid (DTPA) on MRI or with iodine on CT depends on the disruption of the brain–blood barrier (BBB) by tumor or radiation. Steroid treatment can increase the integrity of the BBB and decrease the amount of contrast enhancement (12). There have not been any studies evaluating the sensitivity and specificity of CT and MRI for recurrent tumor, but there is general agreement in the literature that CT and MRI cannot reliably distinguish recurrent brain tumor from LDRI (13–16). The limitations of CT and MRI prompted us to search for more accurate noninvasive tests.

TABLE 2
Classification of Astrocytomas

| Kernohan (1940) | Mayo/St. Anne (1981/1988) | WHO grade (1979/1993) | WHO designation | Histopathology |
|-----------------|---------------------------|-----------------------|-------------------------|---|
| Grade 1 | Excluded | I | Pilocytic astrocytoma | Bipolar, piloid cells, Rosenthal fibers, eosinophilic granular bodies |
| Grade 1 | Grades 1 and 2 | II | Low-grade astrocytoma | Neoplastic fibrillary or gemistocytic astrocytes; nuclear atypia |
| Grade 2 | Grade 3 | III | Anaplastic astrocytoma | Neoplastic fibrillary or gemistocytic astrocytes; nuclear atypia mitotic activity |
| Grade 3 | Grade 4 | IV | Glioblastoma multiforme | Cellular anaplasia, nuclear atypia, mitoses, vascular proliferation, necrosis |
| Grade 4 | | | | |

Table modified from Kleihues (3) and Tatter (6).

TABLE 3
Clinical, Radiologic, and Pathologic Findings in Brain Radiation Injury

| Stage (time to onset) | Symptoms | MRI/CT | PET | Pathology |
|-------------------------------|---|---|----------------|--|
| Acute (hours to weeks) | Related to mass effect and ensuing increased ICP (headache, vomiting, altered consciousness) | Edema; enhancing tumor mass | Hypometabolism | Edema; demyelinating plaques; gray–white junction fibrin exudate; hemorrhagic coagulation necrosis and vascular proliferation |
| Early delayed (weeks to 4 mo) | Mixed 1 and 3 | White matter cyst formation | Hypometabolism | Mixed 1 and 3 |
| Late delayed (4 mo to years) | Focal neurologic deficits depending on the size and location of the lesion | Cortical atrophy Diffuse periventricular edema Expansile enhancing mass with focal hyperintensity on T2 and proton density images | Hypometabolism | Fibrinoid necrosis of the medium and small arteries with vascular proliferation; swollen gyri; hemorrhagic coagulation necrosis of the gray matter; white matter affected more than gray; axonal swelling, multifocal demyelination, hyalinization, and reactive gliosis |
| Chronic | Stable focal neurologic deficits as well as global effects causing personality changes and dementia | Vascular dystrophic calcification with cystic changes; cortical atrophy; telangiectasia | Hypometabolism | Reactive gliosis; subcortical cyst formation; vasculitis, arteritis, enhanced atherosclerosis, and vascular dystrophic calcification with cystic changes |

PET

Background

LDRI and a recurrent tumor have different rates of glucose metabolism. Areas of radiation injury have lower glucose metabolism than normal brain tissue because they are less cellular (17). Glucose metabolism can be measured by the uptake of 2-[¹⁸F] FDG. FDG is actively transported across the BBB into the cell, where it is phosphorylated by glucose hexokinase. FDG-6-phosphate is trapped in the cell because it is not susceptible to the G-6-phosphate dehydrogenase reaction, which is the next step in the glycolytic cycle. The amount of intracellular FDG is proportionate to the rate of glucose transport and intracellular phosphorylation. Malignant cells generally have high rates of aerobic glucose metabolism, although the metabolic rate of low-grade gliomas and some metastases may be less than normal cortex. FDG PET may be less sensitive in differentiating recurrence from radiation injury in these tumors. A few low-grade tumors, such as pilocytic astrocytoma (a posterior fossa tumor that usually occurs in children) and pituitary adenoma, may have high FDG uptake and are an exception. Janus et al. (18) suggested that a higher malignant grade may be associated with an increase in anaerobic metabolism and a false-negative scan. A reversible decrease in metabolic activity in viable tumors in the immediate postradiation period could also decrease glucose metabolism (12,19,20). In a controlled study on chemotherapy effects, researchers reported that all the false-negative scans occurred in patients who received accelerated fractionated radiotherapy (higher average dose in less time than the rest of the patients) (18). False-positive scans may be caused by radiation injury, which activates repair mechanisms that can increase aerobic glucose metabolism (18). Normal healing processes during the immediate postsurgical period (up to 3 mo) have also

caused false-positive scans (12). The optimal timing of an FDG PET scan in the postradiation period has not been determined. Other nonmalignant causes of elevated glucose uptake are seizure foci and abscesses (12,21).

Procedure

FDG (74–370 MBq depending on age and weight) was injected in a room with low ambient light and noise. Patients were asked to rest quietly with their eyes closed. An emission scan of the head was acquired 30–60 min after injection of FDG. Emission data were corrected for signal attenuation using a transmission scan, or an empiric uniform correction method in place of the transmission scan. The empiric method technique does not account for areas of nonwater attenuation, such as the sinuses, but is not susceptible to error from misregistration of emission and transmission data that is caused by patient movement. This method allows relative, but not absolute, quantitative measurement of regional glucose metabolism. Absolute quantification of regional cerebral glucose metabolism (rCMRGlu) requires tracer kinetic modeling and serial arterial blood sampling (22,23,24). Qualitative scan evaluation may be superior to quantitative analysis because accurate regions of interests may be difficult to define, and rCMRGlu of small, highly hypermetabolic foci within a larger, moderately hypermetabolic tumor may be underestimated by averaging over the entire tumor (24). Interpretation of PET is based on detection of abnormal hypometabolic or hypermetabolic foci compared with the surrounding tissue or the contralateral equivalent area (21). Availability of MRI or CT for anatomic correlation is important. Co-registration of PET with MRI or CT on a single computer may improve diagnostic accuracy of PET for lesions located in the cortex or at the border between the cortex and white matter. Improved localization

is particularly important in the regions that are anatomically distorted by surgery or radiation therapy.

Diagnostic Value

Studies conducted prior to 1990 (17,24–26) reported very high accuracy of FDG PET (Table 4). Patronas et al. (25) and Doyle et al. (26) studied very small samples, had limited correlation with pathology, and may have had patient selection bias. Di Chiro et al. (17) had the largest sample, with pathologic confirmation of PET diagnosis in all cases, although the timing of tissue confirmation of PET results was not discussed. Di Chiro et al. reported 100% sensitivity and specificity of PET in the diagnosis of radiation necrosis and recurrent tumor; however, 2 of the cases classified as true negative had mixed tumor and necrosis. In the study by Valk et al. (24), the results showed that the sensitivity and specificity of PET were 88% and 81%, respectively, on the basis of clinical course (24). Studies performed after 1990 also have shown that the sensitivity of FDG PET for identifying recurrent tumor is greater than 80%, but the reported specificity ranges from 40% to 94% (12,18,21,27,28). Ricci et al. (21) reported that the number of false-positive cases decreased when contralateral gray matter was used for comparison with the lesion instead of contralateral white matter. Some of the false-positive results in this study could have been from post-test bias because patients with negative PET were less likely to have a tissue diagnosis. Another study with a high rate of false-positive results had significant design limitations that included lack of pathologic correlation in most cases, up to an 18-mo lag between PET and the tissue diagnosis, and poor interrater reliability (28). Inflammatory activity may be a cause of FDG uptake in late-delayed radiation injury (LDRI). Fischman et al. reported a case of FDG avid radiation necrosis after radiotherapy of meningioma (20).

We reviewed 72 consecutive cases referred to us by the Palo Alto Veterans Affairs PET Center (Palo Alto, CA) from January 1995 through March 1999, with a request to differentiate recurrent tumor from DLRI as a cause of new clinical symptoms or increase in size or enhancement characteristics of a known brain abnormality. Eleven of 72

patients had a brain lesion tissue diagnosis by biopsy or surgery within 60 d after the PET scan. PET scans were true positive in 8 patients, false negative in 2 patients, and equivocal in 1 patient (sensitivity, 82%; Figures 1 and 2). One of the false-negative cases was a patient with a low-grade glioma, and the other patient had a well-differentiated adenocarcinoma of unknown primary origin.

Cross-Study Comparison and Study Design Considerations

Cross-study comparison was difficult because of the differences in study designs and tumor types included. There was no uniformity among studies in the important variables of chemotherapy, radiation therapy dose, time interval between PET and tissue diagnosis, and qualitative methods of scan interpretation. Some of these variables were not described in detail in some of the articles. All studies were subject to post-test bias because the decision for reoperation or stereotactic biopsy was influenced by PET. The validity of using the clinical course as a confirmation of tumor recurrence or LDRI in all or some patients is also questionable, because LDRI may have a clinical course that is indistinguishable from tumor recurrence. From the available data, we could not derive a single numerical value for the accuracy of PET in differentiating recurrent tumor from LDRI.

Prognostic Value

Di Chiro and Fulham (19) challenged the role of pathologic diagnosis as the best predictor of prognosis. They suggested that tumor biologic behavior and patient prognosis may be better predicted by tumor metabolic activity rather than histologic grade. Pathologic diagnosis is limited by the tendency of gliomas to progress to more malignant histologic types over time. Biopsy material is difficult to interpret because gliomas are not homogenous and could contain areas of necrosis and cells of variable degree of malignancy or even type (2). Ericson et al. (see Table 5) prospectively studied the survival of 31 patients with suspected recurrent brain metastases after stereotactic radiation (29). Fourteen patients had hypermetabolic foci at the tumor site, and 17 patients had hypometabolic foci. The

TABLE 4
Accuracy of PET in Differentiation of Radiation Injury from Tumor Recurrence

| Study | n | Pathology | Sensitivity | Specificity | PPV | NPV |
|----------------------|----|--------------------------------|-------------|-------------|-----|-----|
| Patronas et al. (25) | 5 | Low-grade glioma | 100 | 100 | | |
| Doyle et al. (26) | 9 | High-grade glioma | 100 | 100 | | |
| Di Chiro et al. (17) | 95 | Glioma + metastases | 100 | 100 | | |
| Valk et al. (24) | 38 | Glioma | 81 | 88 | 79 | 89 |
| Janus et al. (18) | 20 | Glioma | 83 | 63 | 77 | 71 |
| Davis et al. (12) | 35 | Glioma, lymphoma metastases | 83 | No data | | |
| Kahn et al. (28) | 19 | Glioma (n = 17), other (n = 2) | 81 | 40 | | |
| Kim et al. (27) | 33 | Glioma + metastases | 80 | 94 | 92 | 85 |
| Ricci et al. (21) | 31 | Glioma | 86 | 56 | 80 | 46 |

PPV, positive predictive values; NPV, negative predictive values.

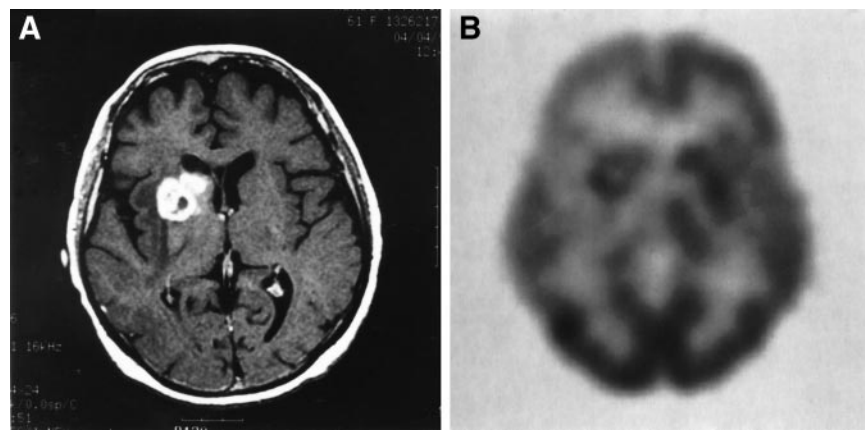


FIGURE 1. Sixty-year-old woman with stage IV ovarian cancer (diagnosed Sept. 1993) treated with surgery and chemotherapy until April 1994. (A) GdDTPA T1-weighted ($Tr = 766$, $TE = 13$) MRI scan (performed April 4, 1997) showing ring-enhancing lesions with central low signal in the right parietal cortex, the white matter of the right frontal lobe, and the right caudate head and anterior portion of the internal capsule. (B) PET scan (performed April 2, 1997) shows 2 right parietal cortical hypermetabolic lesions, hypometabolism in right frontoparietal area, and 2 areas of annular hypermetabolism with central hypometabolism: in the right frontal white matter and adjacent to the right caudate. In 1995, patient developed ataxia and right-sided hearing problems. MRI showed 2 right parietal metastases. Patient was treated with whole-brain radiation (30 Gy in 10 fractions) and dexamethasone and then with stereotactic radiosurgery (18 Gy to right parietal lesions). She developed seizures 8 mo later; MRI showed enlargement of 2 right parietal lesions. On April 4, 1997, she had stereotactic removal of the superficial lesions that were hypermetabolic on PET. Deeper lesions could not be removed because of location. Patient was lost to follow up after this procedure.

hypometabolic group had a median survival of 19.9 mo (40% increase) versus 12.3 mo in the hypermetabolic group. Barker et al. (30) studied a cohort of 55 previously treated patients with suspected recurrent high-grade glioma (73% grade 4; 22% grade 3). They reported a median survival time of 10 mo for patients with FDG uptake equal to or greater than the adjacent cortex and 20 mo for those with FDG uptake less than the adjacent cortex (30). DiChiro and Fulham also questioned the role of pathologic diagnosis as a

gold standard for FDG PET. They argued that the presence of morphologically intact tumor cells in a tissue sample did not indicate tumor recurrence, because the cells may be unable to proliferate after treatment (19). Valk et al. also presented evidence to support this argument (9,24): 19 patients had pathologic examination within 4 mo of PET. Nine of the 18 patients had PET evidence of tumor, whereas the other 9 patients showed radiation injury. The clinical course correlated better with PET than pathology. All

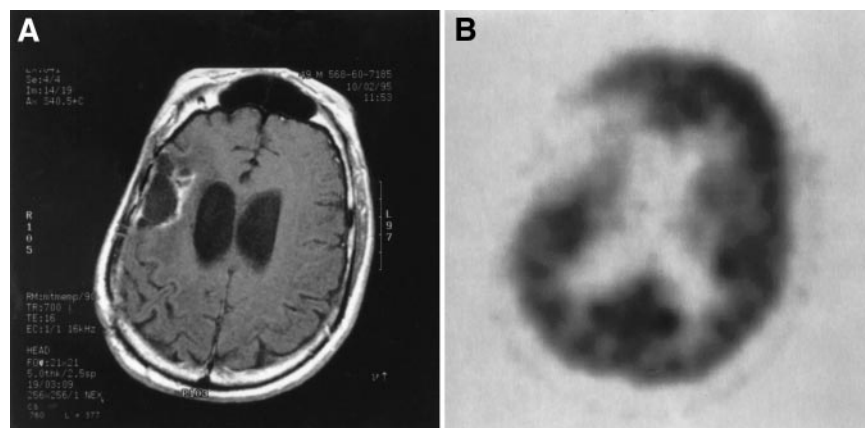


FIGURE 2. MR and PET scans of 50-year-old man, with a history of grade 2 right frontal oligodendroglioma, who presented with headaches and memory loss. (A) GdDTPA T1-weighted ($Tr = 700$, $TE = 16$) MR scan of 50-year-old man, showing an area of low signal in the right parietal lobe with predominantly peripheral contrast enhancement, edema, and focal areas of hemorrhage, which indicated the possibility of tumor or DLRI. (B) PET scan of patient's brain, showing hypometabolic right frontoparietal area consistent with changes after surgery and radiation. No hypermetabolic foci to suggest recurrent tumor. Tumor was resected on September 8, 1993, and treated with radiation therapy to the frontal and parietal lobes (total dose between September 29 and November 9, 1993 = 56 Gy). Patient continued to have mild cognitive deficits and psychosis. In 1995, patient developed new neurologic deficits and dementia worsened. MR showed progression of edema and enhancement in the right parietal lobe, next to the resection site. PET scan in November 1995 was negative for abnormal hypermetabolic foci; a second craniotomy was performed December 1995, and right frontoparietal cystic lesion without evidence of malignancy on a frozen section was removed. Histologic examination showed mixed astrocytoma and oligodendroglioma without mitotic activity, and with areas of focal necrosis. Patient died in February 1996.

TABLE 5
Median Survival with Negative or Positive FDG PET

| Study | n | Tumor type | Median survival | |
|----------------------|----|------------------|-----------------|---------------|
| | | | PET positive | PET negative |
| Patronas et al. (25) | 45 | Grade 3-4 glioma | 5 months | 19 months |
| Mogard et al. (31) | 11 | Metastases | 0% in 54 weeks | 80% 1.7 years |
| Ericson et al. (29) | 31 | Metastases | 12.3 months | 19.9 months |
| Barker et al. (30) | 55 | Grade 3-4 glioma | 10 months | 20 months |

patients in our small series also had some tumor cells, regardless of PET or MRI findings or the clinical course. The 2 patients with a false-negative FDG PET result survived 6 mo and 26 mo. Patients whose scans were true positive survived from 2 mo to more than 21 mo (5 of 9 patients were alive at the time of this writing). Most studies support the predictive value of FDG PET in suspected recurrent brain tumor. Prospective studies that excluded brain metastases from primary brain tumors confirmed earlier observations of DiChiro and Fulham (19) and Patronas et al. (25) of significantly longer survival in patients with a negative PET scan (29,30).

Impact on Management

The impact of a test on clinical management does not rest only on the scientific merit or even cost effectiveness. Availability and physician education are also important. The impact of a test may grow with increased physician awareness. At this time, the literature on the impact of PET in the clinical management of patients with brain tumor is limited, and the conclusions of the available studies are variable. In the largest review available to date, Deshmukh et al. (32) reviewed the effect of FDG PET on subsequent management in 89 patients with treated primary brain tumors. In 59% of cases, PET results contributed to a decision by the physician to withhold treatment and in 31%, PET results contributed to a decision to initiate new therapy or surgery. In a study by Janus et al. (18), treatment decisions were affected by PET in 24 of 50 patients. The high rate of agreement between GdDTPA MRI and FDG PET has been interpreted by some authors as an indication of limited added value of FDG PET (12,33).

Alternative and Emerging Diagnostic Modalities

Other modalities that may have a potential role in the differential diagnosis of recurrent brain tumor versus radiation injury are magnetic resonance spectroscopy (MRS); blood-volume imaging with echo-planar magnetic resonance; PET, using radiolabeled pyrimidine nucleosides (^{11}C thymidine) or amino acids (^{11}C -tyrosine and ^{11}C methionine); and ^{201}Tl or ^{123}I - α -methyl-L-tyrosine (IMT) SPECT (2,34–37). Amino acids and IMT uptake are markers of cellular proliferation. Pyrimidine nucleoside uptake is related to mitotic activity (38–40). Physiology of ^{201}Tl uptake may be related not only to disruption of the BBB but also to active transport of this potassium analog (28). Changes in choline, creatine, and n-acetyl aspartate ratios on MRS can

also serve as an indicator of tumor proliferation (38). Case reports and small studies of patients showing potential advantages over FDG PET in sensitivity, cost effectiveness, or additional information have been published for those modalities (16,28,40–43). Combining information derived from FDG PET with other modalities could improve the accuracy of FDG PET. At this time, experience with other modalities is still limited.

All studies reviewed here used dedicated PET cameras. Coincidence FDG imaging with gamma cameras for differentiation of brain tumor recurrence from radiation injury has not been evaluated (44).

CONCLUSION

FDG PET is useful in differentiating LDRI from recurrent high-grade glioma. The sensitivity of PET is 80%–90% and the specificity is 50%–90%. Tissue diagnosis may not be the gold standard for evaluation of the accuracy of FDG PET. Methods of analysis assuming absence of an external standard could be used to test the specificity and sensitivity of PET in the future (45,46). Causes of false-negative PET results include recent radiation therapy, low histologic grade, and small tumor volume. FDG PET may be false positive in nonmalignant inflammatory processes and sub-clinical seizure activity. The question of hypermetabolic foci of radiation injury as a cause of false-positive scans requires further investigation. Other issues requiring further study are the optimal timing of FDG PET after radiation and chemotherapy and the accuracy of FDG PET in tumors other than high-grade gliomas. FDG PET is also a valuable predictor of survival in high-grade recurrent glioma. Additional applications of FDG PET in the management of recurrent brain tumors are the selection of the best biopsy site in case of multiple lesions and determination of active tumor margins for local radiation therapy planning. GdDTPA MRI is an established modality that should be complementary to FDG PET in evaluation of patients with brain tumors. In the future, combining FDG PET and another imaging modality on the basis of different physiologic mechanisms (e.g., MRS, $\text{Tl}201$ or IMT SPECT, PET with radiolabeled amino acids, and nucleosides) could improve diagnostic accuracy.

REFERENCES

1. Levine VA, Leibel SA, Gutin PH. Neoplasms of the central nervous system. In: DeVita VT, Hellman S, Rosenberg SA, eds. *Cancer: Principles and Practice of Oncology* (4th ed.). Philadelphia, PA: J.B. Lippincott;1993:2022–2032.

2. Tatter SB, Wilson CB, Harsh GR IV. Neuroepithelial tumors of the adult brain. In: Youmans JR, ed. *Neurological Surgery, Fourth Edition, Vol. 4: Tumors*. Philadelphia, PA: W.B. Saunders; 1996:2612–2684.
3. Lantos PL, Vandenburg SR, Kleihues P: Tumours of the nervous system. In: Graham D, Lantos P, eds. *Greenfield's Neuropathology* (6th ed.). New York, NY: Oxford University Press; 1997:583–593.
4. Kleihues P, Soylemezoglu F, Schéauble B, Scheithauer BW, Burger PC. Histopathology, classification, and grading of gliomas. *Glia*. 1995;15:211–221.
5. Dumas-Duport C, Scheithauer B, O'Fallon J, Kelly P. Grading of astrocytomas: a simple and reproducible method. *Cancer*. 1988;62:2152–2165.
6. Black PM. Brain tumors: part 2. *N Eng J Med*. 1991;324:1555–1564.
7. Loeffler JS, Patchell RA, Sawaya R. Metastatic brain cancer. In: DeVita VT, Hellman S, Rosenberg SA, eds. *Cancer: Principles and Practice of Oncology* (4th ed.). Philadelphia, PA: J.B. Lippincott; 1993:2523–2536.
8. Chamberlain MC, Kormanik PA. Practical guidelines for the treatment of malignant gliomas. *West J Med*. 1998;168:114–120.
9. Valk PE, Dillon WP. Radiation injury of the brain. *AJNR*. 1991;12:45–62.
10. Boyko, OB. Neuroimaging of radiation injury to the central nervous system. *Neuroimag Clin N Am*. 1993;3:803–816.
11. Leibel SA, Sheline GE. Tolerance of the brain and spinal cord to conventional irradiation. In: Gutin PH, Leibel SA, Sheline GE, eds. *Radiation Injury to the Nervous System*. New York, NY: Raven Press; 1991:239–256.
12. Davis WK, Boyko OB, Hoffman JM, et al. [18F]2-fluoro-2-deoxyglucose-positron emission tomography correlation of gadolinium-enhanced MR imaging of central nervous system neoplasia. *AJNR*. 1993;14:515–523.
13. Doms GC, Hecht S, Brant-Zawadzki M, et al. Brain radiation lesions: MR imaging. *Radiology*. 1986;15:149–155.
14. Van Dellen JR, Danziger A. Failure of CT to differentiate between radiation necrosis and cerebral tumor. *S Afr Med J*. 1978;53:171–172.
15. Nelson DR, Yuh WT, Wen BC, Ryals TJ, Cornell SH. Cerebral necrosis simulating an intraparenchymal tumor. *AJNR*. 1990;11:211–212.
16. Nelson SJ, Huhn S, Vigneron DB. Volume MRI and MRSI techniques for the quantitation of treatment response in brain tumors: presentation of a detailed case study. *J Magn Reson Imaging*. 1997;7:1146–1152.
17. Di Chiro G, Oldfield E, Wright DC. Cerebral necrosis after radiotherapy and/or intraarterial chemotherapy for brain tumors: PET and neuropathologic studies. *AJR*. 1988;150:189–197.
18. Janus TJ, Kim EE, Tilbury R, Bruner JM, Yung WK. Use of [18F]fluorodeoxyglucose positron emission tomography in patients with primary malignant brain tumors. *Ann Neurol*. 1993;33:540–548.
19. DiChiro G, Fulham MJ. Virchow's shackles: can PET-FDG challenge tumor histology? *AJNR*. 1993;14:524–527.
20. Fischman AJ, Thornton AF, Frosch MP, et al. FDG hypermetabolism associated with inflammatory necrotic changes following radiation of meningioma. *J Nucl Med*. 1997;38:1027–1029.
21. Ricci PE, Karis JP, Heiserman JE, et al. Differentiating recurrent tumor from radiation necrosis: time for re-evaluation of positron emission tomography? *AJNR*. 1998;9:407–413.
22. Phelps ME, Huang SC, Hoffman EJ, et al. Tomographic measurement of local cerebral glucose metabolic rate in humans with (F-18)2-fluoro-2-deoxy-D-glucose: validation of method. *Ann Neurol*. 1979;6:371–388.
23. Huang SC, Phelps ME, Hoffman EJ, et al. Noninvasive determination of local cerebral metabolic rate of glucose in man. *Am J Physiol*. 1980;238:E69–E82.
24. Valk PE, Budinger TF, Levin VA, et al. PET of malignant cerebral tumors after interstitial brachytherapy: demonstration of metabolic activity and correlation with clinical outcome. *J Neurosurg*. 1988;69:830–838.
25. Patronas NJ, DiChiro G, Brooks RA, et al. Work in progress: [18F]fluorodeoxyglucose and positron emission tomography in the evaluation of radiation necrosis of the brain. *Radiology*. 1982;144:885–889.
26. Doyle WK, Budinger TF, Valk PE, Levin VA, Gutin PH. Differentiation of cerebral radiation necrosis from tumor recurrence by [18F]FDG and 82Rb positron emission tomography. *J Comp Assist Tomogr*. 1987;11:563–570.
27. Kim EE, Chung SK, Haynie TP, et al. Differentiation of residual or recurrent tumors from post-treatment changes with F-18 FDG PET. *Radiographics*. 1992;12:269–279.
28. Kahn D, Follett KA, Bushnell DL, et al. Diagnosis of recurrent brain tumor: value of 201TI SPECT vs 18F-FDG PET. *AJR*. 1994;163:1459–1465.
29. Ericson K, Kihlström L, Mogard J, et al. Positron emission tomography using 18F-FDG in patients with stereotactically irradiated brain metastases. *Stereotact Funct Neurosurg*. 1996;66:214–224.
30. Barker FG II, Chang SM, Valk PE, Pounds TR, Prados MD. 18-FDG uptake and survival of patients with suspected recurrent malignant glioma. *Cancer*. 1997;79:115–126.
31. Mogard J, Kihlström L, Ericson K, et al. Recurrent tumor vs. radiation effects after gamma knife radiosurgery of intracerebral metastases: diagnosis with PET-FDG. *J Comp Assist Tomogr*. 1994;18:177–181.
32. Deshmukh A, Scott JA, Palmer EL, et al. Impact of FDG positron emission tomography on the clinical management of patients with glioma. *Clin Nucl Med*. 1996;21:720–725.
33. Olivero WC, Dulebohn SC, Lister JR. The use of PET in evaluating patients with primary brain tumours: is it useful? *J Neurol Neurosurg Psychiatr*. 1995;58:250–252.
34. Ogawa T, Kanno I, Shishido F, et al. Clinical value of PET with 18F-fluorodeoxyglucose and L-methyl-11C-methionine for diagnosis of recurrent brain tumor and radiation injury. *Acta Radiol*. 1991;32:197–202.
35. Ogawa T, Shishido F, Kanno I, et al. Cerebral glioma: evaluation with methionine PET [see comments]. *Radiology*. 1993;186:45–53.
36. Roelcke U, Radéu EW, von Ammon K, et al. Alteration of blood-brain barrier in human brain tumors: comparison of [18F]FDG, [11C]methionine and rubidium-82 using PET. *J Neurol Sci*. 1995;132:20–27.
37. Shields AF, Mankoff DA, Link JM, et al. Carbon-11-thymidine and FDG to measure therapy response. *J Nucl Med*. 1998;39:1757–1762.
38. Yoshino E, Ohmori Y, Imahorri Y, et al. Irradiation effects on the metabolism of metastatic brain tumors: analysis by positron emission tomography and 1H-magnetic resonance spectroscopy. *Stereotact Funct Neurosurg*. 1996;66(suppl. 1):240–259.
39. Goldman S, Levivier M, Pirotte B, et al. Regional methionine and glucose uptake in high-grade gliomas: a comparative study on PET-guided stereotactic biopsy. *J Nucl Med*. 1997;38:1459–1462.
40. Weber W, Bartenstein P, Gross MW, et al. Fluorine-18-FDG PET and iodine-123-IMT SPECT in the evaluation of brain tumors. *J Nucl Med*. 1997;38:802–808.
41. Kaschten B, Stevenaert A, Sadzot B. Preoperative evaluation of 54 gliomas by PET with 18-FDG and/or carbon-11-methionine. *J Nucl Med*. 1998;39:778–785.
42. Pruim J, Willemsen AT, Molenaar WM, et al. Brain tumors: L-[1-C-11]tyrosine PET for visualization and quantification of protein synthesis rate. *Radiology*. 1995;197:221–226.
43. Coleman RE, Hoffman JM, Hanson MW, Sostman HD, Schold SC. Clinical application of PET for the evaluation of brain tumors. *J Nucl Med*. 1991;32:616–622.
44. Delbeke D, Patton JA, Martin WH, Sandler MP. FDG PET and dual head gamma camera positron coincidence detection imaging of suspected malignancies and brain disorders. *J Nucl Med*. 1999;40:110–117.
45. Schulzer M, Anderson DR, Drance SM. Sensitivity and specificity of a diagnostic test determined by repeated observations in the absence of external standard. *J Clin Epidemiol*. 1991;44:1167–1179.
46. Diamond GA, Berman A, Forrester JS, et al. A model for assessing the sensitivity and specificity of tests subject to selection bias. *J Chronic Diseases*. 1986;39:343–355.



The Journal of
NUCLEAR MEDICINE

PET in Differentiation of Recurrent Brain Tumor from Radiation Injury*

Daniel D. Langleben and George M. Segall

J Nucl Med. 2000;41:1861-1867.


This article and updated information are available at:
<http://jnm.snmjournals.org/content/41/11/1861>

Information about reproducing figures, tables, or other portions of this article can be found online at:
<http://jnm.snmjournals.org/site/misc/permission.xhtml>

Information about subscriptions to JNM can be found at:
<http://jnm.snmjournals.org/site/subscriptions/online.xhtml>

The Journal of Nuclear Medicine is published monthly.
SNMMI | Society of Nuclear Medicine and Molecular Imaging
1850 Samuel Morse Drive, Reston, VA 20190.
(Print ISSN: 0161-5505, Online ISSN: 2159-662X)

© Copyright 2000 SNMMI; all rights reserved.

 SOCIETY OF
NUCLEAR MEDICINE
AND MOLECULAR IMAGING