

# Gallbladder Fossa Abscess Masquerading as Cholecystitis After Cholecystectomy

Paul Rodrigue, Asif Fakhri, and Andrew Baumgartner

University at Buffalo, School of Medicine and Biomedical Sciences, Department of Nuclear Medicine, Buffalo, New York

We present a case of a 59-y-old woman who had undergone cholecystectomy and was subsequently found to have an abscess within the gallbladder fossa. A hepatobiliary scan using  $^{99m}\text{Tc}$ -diisopropyliminodiacetic acid demonstrated the characteristic rim sign, a photopenic defect surrounded by a rim of mildly increased activity immediately adjacent to the gallbladder fossa. The rim sign was thought to be the result of reactive inflammation in the hepatic tissue adjacent to a postoperative abscess within the gallbladder fossa.

**Key Words:** hepatic abscess; liver abscess; hepatobiliary abscess; correlative imaging

**J Nucl Med Technol 2015; 43:295–296**

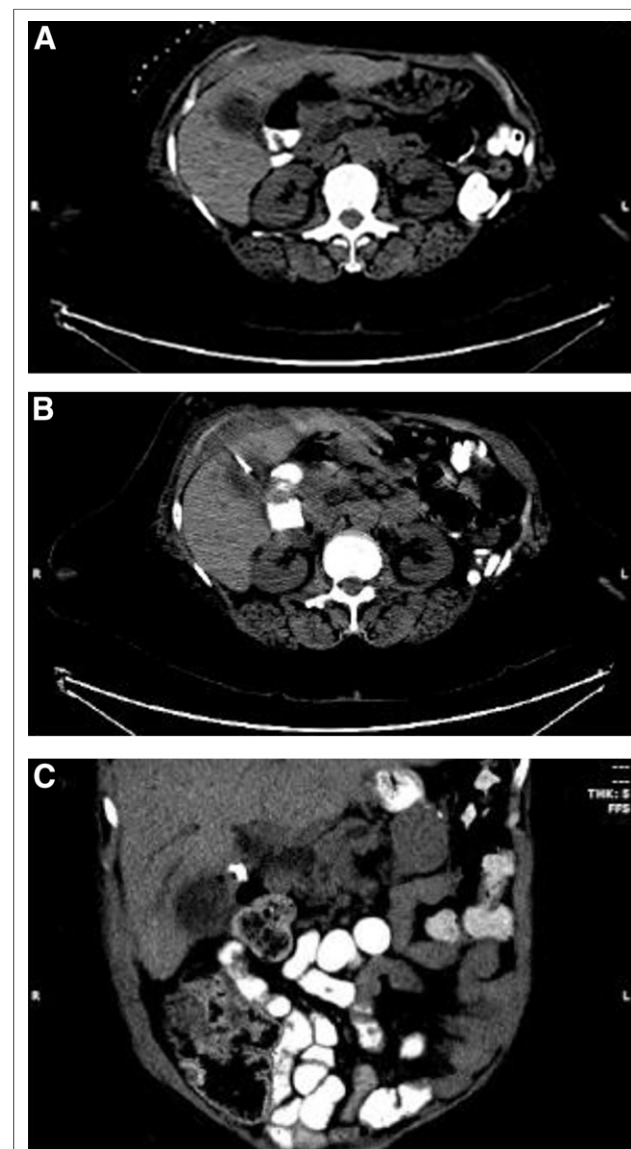DOI: 10.2967/jnmt.115.155606

**H**epatobiliary scintigraphy is a reliable noninvasive technique for the detection of postoperative bile leakage as well as other hepatobiliary disease. Visualization of the rim sign on hepatobiliary scintigraphy is a fairly specific finding for acute cholecystitis. Here, we present a case of postoperative abscess within the gallbladder fossa after cholecystectomy, resulting in the rim sign.

## CASE REPORT

A 59-y-old woman with a remote history of gastric bypass unsuccessfully underwent endoscopic retrograde cholangiopancreatography for suspected choledocholithiasis, followed by placement of a percutaneous cholecystostomy drain and subsequent cholecystectomy. Twenty-four days postoperatively, the patient was seen in her primary care physician's office and had persistent leukocytosis despite absence of abdominal pain or systemic symptoms. An ultrasound done the same day revealed pneumobilia, a common bile duct measuring 1.3 cm, and dilated intrahepatic and pancreatic ducts. Abdominal and pelvic CT performed with contrast material at an outside hospital showed a thick-walled,

heterogeneous, complex fluid collection within the gallbladder fossa that also contained small pockets of air (Fig. 1). The finding was thought to represent either a biloma or an abscess. Hepatobiliary scintigraphy was ordered to rule



**FIGURE 1.** Axial (A and B) and reformatted coronal (C) CT images demonstrating abscess in gallbladder fossa with adjacent surgical clips.

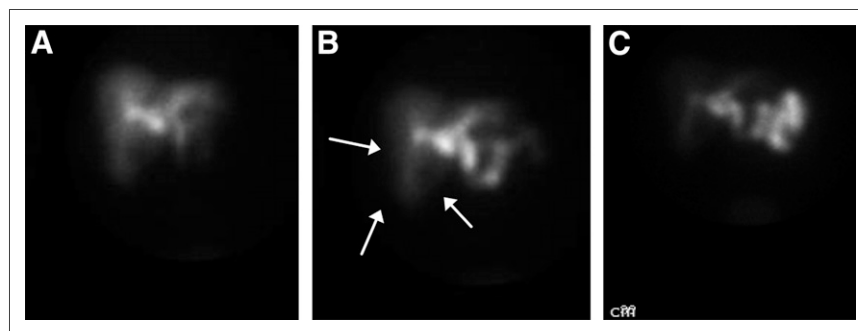
Received Feb. 9, 2015; revision accepted Apr. 28, 2015.

For correspondence or reprints contact: Asif Fakhri, University at Buffalo, School of Medicine and Biomedical Sciences, Department of Nuclear Medicine, 105 Parker Hall, 3435 Main St., Buffalo, NY 14214-3007.

E-mail: [asif.fakhri@gmail.com](mailto:asif.fakhri@gmail.com)

Published online Jun. 25, 2015.

COPYRIGHT © 2015 by the Society of Nuclear Medicine and Molecular Imaging, Inc.



**FIGURE 2.** Hepatobiliary scintigraphy images at 20 min (A), 30 min (B), and 60 min (C). Rim sign is indicated by arrows.

out the possibility of bile leakage, and images were obtained every 2 min after intravenous injection of 188.7 MBq (5.1 mCi) of  $^{99m}\text{Tc}$ -diisopropyliminodiacetic acid. The scan showed no evidence of biloma; however, a photopenic defect surrounded by a rim of mildly increased activity within the liver immediately adjacent to the gallbladder fossa was seen (Fig. 2), increasing the suspicion that an abscess was present. Percutaneous aspiration of the abscess revealed *Enterococcus faecalis*, a microbe commonly found in the lower gastrointestinal tract.

## DISCUSSION

Although hepatobiliary scintigraphy is typically used to evaluate disease or postprocedural iatrogenic injury of the biliary tree and gallbladder (1), it may also demonstrate any abnormality in hepatic parenchymal tissue. In the rim sign, a photopenic area in the gallbladder fossa does not show any filling with radiotracer and is surrounded by increased activity in the pericholecystic area. This sign is seen in approximately 32% of patients with acute cholecystitis and has a positive predictive value of 94% when seen in conjunction with nonvisualization of the gallbladder (2). The sign occurs secondary to several mechanisms such as increased blood flow and extraction of radiotracer by the liver, as well as decreased clearance from edema and inflammation of biliary canaliculi leading to bile stasis (3).

Because the rim sign is typically associated with a more emergent clinical picture, the importance of obtaining a proper patient history and correlative imaging cannot be underestimated. In our case, for example, if the patient had been septic and unresponsive, if the medical history had been unavailable, and if the interpreter had considered the scintigraphic findings in isolation, a case of acute cholecystitis may have erroneously been diagnosed. This diagnosis would, of course, have been impossible because of the prior

cholecystectomy, leaving bile leakage or hepatic abscess to be the much more likely possibilities in the differential diagnosis. On abdominal CT, a surgical clip was seen at the proximal cystic duct, hinting not only that a prior surgical procedure was performed but also that the gallbladder fossa contained air, thus making abscess the more probable diagnosis.

## CONCLUSION

Because the rim sign is not unique to acute cholecystitis and may be seen in hepatic abscess (4) or chronic cholecystitis as well (5), it is reasonable to believe that an abscess in the gallbladder fossa would cause reactive inflammatory findings in the adjacent hepatic tissue similar to the findings for an emphysematous or gangrenous gallbladder.

## DISCLOSURE

No potential conflict of interest relevant to this article was reported.

## REFERENCES

1. Hugh TB. Laparoscopic bile duct injury: some myths. *ANZ J Surg.* 2002;72:164–167.
2. Powell DK, Goldfarb RC, Ongseng F. Hepatobiliary rim sign: new implications for acute and complicated cholecystitis. *Nucl Med Commun.* 2013; 34:467–477.
3. Bushnell DL, Perlman SB, Wilson MA, et al. The rim sign: association with acute cholecystitis. *J Nucl Med.* 1986;27:353–356.
4. Gowda NK, Mohapatra T, Sharma S, Kumar R. 'Rim sign' in liver abscesses. *Clin Nucl Med.* 2006;31:349–351.
5. Morrison JC, Ramos-Gabatin A, Gelormini RG, et al. Prompt visualization of the gallbladder with a rim sign: acute or subacute cholecystitis? *J Nucl Med.* 1993;34: 1169–1171.



## Gallbladder Fossa Abscess Masquerading as Cholecystitis After Cholecystectomy

Paul Rodrigue, Asif Fakhri and Andrew Baumgartner

*J. Nucl. Med. Technol.* 2015;43:295-296.

Published online: June 25, 2015.

Doi: 10.2967/jnmt.115.155606

---

This article and updated information are available at:  
<http://tech.snmjournals.org/content/43/4/295>

---

Information about reproducing figures, tables, or other portions of this article can be found online at:  
<http://tech.snmjournals.org/site/misc/permission.xhtml>

Information about subscriptions to JNMT can be found at:  
<http://tech.snmjournals.org/site/subscriptions/online.xhtml>

*Journal of Nuclear Medicine Technology* is published quarterly.  
SNMMI | Society of Nuclear Medicine and Molecular Imaging  
1850 Samuel Morse Drive, Reston, VA 20190.  
(Print ISSN: 0091-4916, Online ISSN: 1535-5675)

© Copyright 2015 SNMMI; all rights reserved.