

Electrocardiography: A Technologist's Guide to Interpretation

Colin Tso, MBBS, PhD, FRACP, FCSANZ^{1,2}, Geoffrey M. Currie, BPharm, MMedRadSc(NucMed), MAppMngt(Hlth), MBA, PhD, CNMT^{1,3}, David Gilmore, ABD, CNMT, RT(R)(N)^{3,4}, and Hosen Kiat, MBBS, FRACP, FACP, FACC, FCCP, FCSANZ, FASNC, DDU^{1,2,3,5}

¹Faculty of Medicine and Health Sciences, Macquarie University, Sydney, New South Wales, Australia; ²Cardiac Health Institute, Sydney, New South Wales, Australia; ³Faculty of Science, Charles Sturt University, Wagga Wagga, New South Wales, Australia; ⁴Faculty of Medical Imaging, Regis College, Boston, Massachusetts; and ⁵Faculty of Medicine, University of New South Wales, Sydney, New South Wales, Australia

CE credit: For CE credit, you can access the test for this article, as well as additional JNMT CE tests, online at <https://www.snmlearningcenter.org>. Complete the test online no later than December 2018. Your online test will be scored immediately. You may make 3 attempts to pass the test and must answer 80% of the questions correctly to receive 1.0 CEH (Continuing Education Hour) credit. SNMMI members will have their CEH credit added to their VOICE transcript automatically; nonmembers will be able to print out a CE certificate upon successfully completing the test. The online test is free to SNMMI members; nonmembers must pay \$15.00 by credit card when logging onto the website to take the test.

The nuclear medicine technologist works with electrocardiography when performing cardiac stress testing and gated cardiac imaging and when monitoring critical patients. To enhance patient care, basic electrocardiogram interpretation skills and recognition of key arrhythmias are essential for the nuclear medicine technologist. This article provides insight into the anatomy of an electrocardiogram trace, covers basic electrocardiogram interpretation methods, and describes an example case typical in the nuclear medicine environment.

Key Words: cardiology; ECG; gating; interpretation

J Nucl Med Technol 2015; 43:247–252

DOI: 10.2967/jnmt.115.163501

Historically in nuclear medicine, the goal of monitoring the electrocardiogram by technical staff was either to detect changes in heart rate and rhythm or to use the electrocardiogram as a physiologic trigger for imaging (generate a prominent R wave). Changes in heart rate and rhythm are evaluated on the horizontal axis of the electrocardiogram and, like the R trigger for imaging, generally require only a single lead (1). Evaluation of changes in amplitude on the vertical axis and, indeed, interpretation of a 12-lead electrocardiogram was not a priority. Nonetheless, an increased demand for more detailed understanding of electrocardiogram interpretation has been driven by the more widespread use of electrocardiogram monitoring in patients undergoing cardiac imaging and in critical care inpatients undergoing other types of imaging, along with the greater emphasis on advanced practice and the extended role of the nuclear medicine technologist. This article provides a

foundation for understanding the science of electrocardiography and its interpretation.

THE HEART

The heart is a critical organ that is essentially a pump driven by electrical impulses generated and conducted by an internal system. The cardiac cycle begins with the contraction of both atria to actively fill the main pumping chamber, the ventricles (2,3). Once the ventricles are filled, they contract and drive the blood into the arterial system. They then relax to their baseline state, allowing passive filling of the chambers (2,3). This is followed by the next cardiac cycle.

Internally, the cardiac myocyte has a negative charge, which causes a voltage difference across the cell membrane (transmembrane potential) (2–4). Since the cardiac myocyte is excitable, it can be stimulated to allow ions to move through open channels in the cell membrane (2–4). The resultant cardiac action potential has 3 phases: depolarization, repolarization, and a resting phase (2–4). Depolarization and repolarization are electrical activities that cause muscle activity, with depolarization generating an action potential and myocardial contraction via an electrical impulse and repolarization bringing about a return to a resting state corresponding to myocardial relaxation. During depolarization, sodium channels open, allowing the positively charged sodium ions to enter the cell (2–4). The cardiac membrane potential returns to normal during repolarization via interactions involving sodium, potassium, and calcium, making contraction impossible (2–4). The resting phase is a period of no net movement of ions across the myocyte cell membrane (2–4). The duration of the action potential of the myocyte is longer than that of nerve or skeletal muscle because of the slow calcium channels, ensuring a regular cardiac rhythm (4).

The conduction system generates an electrical impulse as the cells spontaneously depolarize because of their specific membrane and ion channel properties (2,3). Contraction of

Received Jul. 8, 2015; revision accepted Aug. 17, 2015.
For correspondence or reprints contact: Geoffrey M. Currie, Charles Sturt University, P.O. Box U102, CSU, Wagga Wagga, NS, Australia 2650.
E-mail: gcurrie@csu.edu.au
Published online Oct. 15, 2015.
COPYRIGHT © 2015 by the Society of Nuclear Medicine and Molecular Imaging, Inc.

the myocardium is activated by these impulses. The myocardium relaxes as the cells repolarize in preparation for the next impulse.

The conduction system begins at the top of the right atrium with the sinoatrial node, which acts as a pulse generator because of the relatively high rate of spontaneous depolarization (2,3). The impulse spreads through the atria and causes both to contract simultaneously, filling the ventricles with expelled blood. The impulse then enters the ventricles via the atrioventricular node, which serves as the protective gateway to prevent the ventricles from being stimulated by excessive impulses (2,3). The atrioventricular node is inferior to the right atrium near the interventricular septum, and there the impulses are slowed before progressing to the ventricles (2,3). The impulses progress from the atrioventricular node, through the bundle of His, to the left and right bundle branches within the left and right ventricles, respectively (2,3). The Purkinje fibers carry impulses from the bundle branches to myocardial cells to ensure coordinated contraction of both ventricles (2,3).

THE ELECTROCARDIOGRAM

The 12-lead electrocardiogram is a quick, noninvasive method of conveying important information on cardiac activity by recording variations in membrane potential across the cardiac cycle (2,3,5). The standard 12-lead electrocardiogram utilizes 10 electrodes, which include 3 limb leads (I, II, and III), 3 augmented limb leads (aVR, aVL, and aVF), and 6 precordial leads (V1–V6). This arrangement records the cardiac activity from different directions and allows mapping of the electrical axis. The impulse that travels toward an electrode is recorded as an upright signal in that lead, whereas the impulse traveling away from an electrode is recorded as an inverted signal. The standard paper speed is 25 mm/s; thus, a single small square equals 40 ms and a single large square (5 small squares) equals 200 ms (Fig. 1). The PR interval is the period from onset of atrial depolarization until onset of ventricular depolarization, the ST segment is the period when the ventricles are depolarized, the T wave is the subsequent repolarization of the ventricles, the QRS complex corresponds to ventricular depolarization, and the R–R interval is the cycle from one ventricular contraction to the next (Fig. 1). A signal frequency of one large square is equal to a rate of 300/min. Calibration of the electrocardiogram equipment and accurate, consistent electrode positioning are crucial to interpretation (1). A detailed discussion of the lead theory is beyond the scope of this article but has been included in a publication of Horacek et al. (6).

The electrical activities of the normal cardiac cycle consist of a P wave followed by the QRS complex and then the T wave. The P wave is generated by atrial depolarization. Because the muscle mass of the atrium is small, the P wave is a relatively small signal. The QRS complex represents ventricular depolarization and is the dominant signal of the electrocardiogram because the ventricular mass is large. The T wave is associated with the return of ventricular activity to its resting state, that is, repolarization. The duration from the

beginning of the P wave to the beginning of the QRS complex is the PR interval, which normally ranges from 120 to 200 ms. The normal width of the QRS complex is less than 100 ms. The duration from the start of the QRS complex to the end of the T wave is the QT interval, which should be less than 440 ms when corrected to the heart rate (QTc). The normal heart rhythm is the sinus rhythm (Fig. 1). The normal heart rate is between 60–100 beats per minute (bpm) (Fig. 2A) and is characterized by the presence of a P wave before the QRS complex, with the P wave being inverted in aVR and upright in aVF/aVL. Tachycardia refers to a heart rate of more than 100 bpm (Fig. 2B) and bradycardia to a heart rate of less than 60 bpm.

Other than disease, several physiologic and technical factors can influence the electrocardiogram (1). Consequently, there is a need for technical staff in the medical radiation sciences to have a basic understanding of the interpretation of both pathophysiologic manifestations on an electrocardiogram and nonpathologic aberrations. Although the electrocardiogram can vary with sex, age, ethnicity, height, weight, and other patient variables, interpretation is on an individual patient basis rather than being a comparison between patients (1). From a technical perspective, several common issues can affect the electrocardiogram, including poor skin preparation or inadequate contact with the skin, which can decrease the cardiac signal and increase skin impedance (1). Noise in an electrocardiogram is associated with an aberrant signal or artifacts arising from several possible factors, such as muscle tremor, movement (including shivering), and electrical interference (1).

DYSFUNCTION OF SINOATRIAL NODE AND ATRIOVENTRICULAR CONDUCTION

Dysfunction of the sinoatrial node resulting in the slowing of impulse generation or even sinus node arrest is known as sick sinus syndrome, which can be due to degeneration of or damage to the sinoatrial node. In the event of sinoatrial node arrest, generation of the cardiac impulse may be taken over by other parts of the conduction system but at a slower rate. Bradycardia–tachycardia syndrome is a variant of sick sinus syndrome in which slow arrhythmias and fast arrhythmias alternate. It is often associated with ischemic heart disease.

In atrioventricular block, conduction between the atria and ventricles of the heart is impaired. First-degree atrioventricular block is defined as a PR interval of more than 200 ms, with every P wave being conducted (Fig. 3A). Second-degree atrioventricular block (Fig. 3B) is divided into Mobitz type I, also called Wenckebach, and Mobitz type II. In Mobitz type I block, the PR interval is progressively prolonged, eventually resulting in a dropped beat. In Mobitz type II block, the PR interval remains constant and a P wave suddenly fails to conduct. Third-degree atrioventricular block is known as complete heart block, with the P wave failing to conduct into the ventricle, thus resulting in atrioventricular dissociation (Fig. 3C). The ventricular rhythm is usually taken over

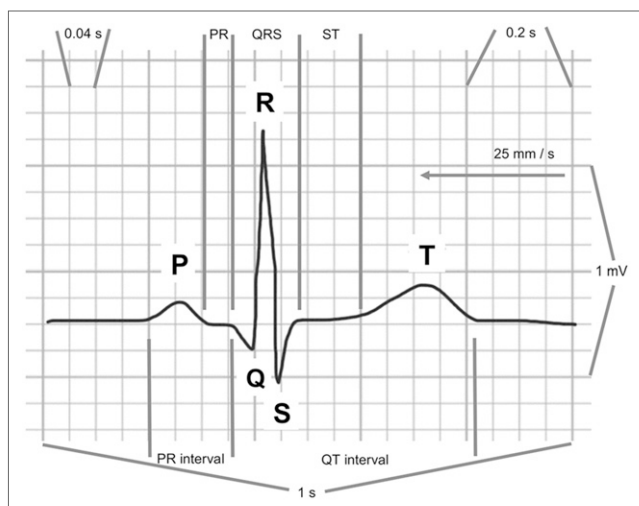


FIGURE 1. Electrocardiogram waveforms of single heart beat in sinus rhythm. Normal duration of PR interval is 120–200 ms. Width of normal QRS complex is <100 ms. Normal duration of QT interval corrected to heart rate is <440 ms. Standard electrocardiogram paper is 1-mm grid. As annotated, horizontally 1 small square is 0.04 s and 1 large square is 0.2 s; thus, 5 large boxes (25 small boxes) is 1 s. Trace moves at speed of 25 mm/s, and 10 small squares on vertical axis equates to 1 mV.

by a slower junctional rhythm. A conduction defect in the bundle branches, such as right or left bundle branch block, causes the QRS complex to widen. Left bundle branch block is important because the widened QRS is also associated with ST change, which may be mistaken for ischemia.

SUPRAVENTRICULAR ARRHYTHMIA

There are 3 main types of supraventricular tachyarrhythmias: those of sinoatrial origin (sinoatrial node reentrant tachycardia), those of atrial origin (atrial tachycardia [unifocal or multifocal], atrial fibrillation, or atrial flutter), and those of atrioventricular junctional origin (atrioventricular junctional reentrant tachycardia or accessory atrioventricular reentrant tachycardia, including Wolff-Parkinson-White syndrome).

Atrial fibrillation is characterized by chaotic electrical activity in the atrium, with the loss of synchronized atrial contraction. The typical electrocardiogram shows an irregular and rapid (>100 bpm) ventricular rate with no discrete P wave (Fig. 4A). A ventricular rate of less than 100 bpm during atrial fibrillation is considered well controlled.

Atrial flutter is caused by a large reentrant pathway within the atrium, typically at a frequency of 300/min. The electrocardiogram may show the sawtooth flutter wave, with the QRS conduction ratio varying from 4:1 to 2:1 (Fig. 4B). Atrial tachycardia is a relatively uncommon form of atrial arrhythmia. The impulse comes from within the atrium but not from the sinoatrial node. Atrial tachycardia may be associated with drug toxicity such as digoxin overdose. More rarely, atrial tachycardia can be due to a reentrant mechanism.

Atrial ectopic beats are associated with premature atrial contraction and manifest quite differently from premature ventricular contraction. Atrial ectopic beats cause an early QRS complex and a normal T wave that obscures the P wave. They result from premature depolarization that produces a normal QRS because atrioventricular node conduction is normal.

VENTRICULAR ARRHYTHMIA

Ventricular tachycardia (VT) is characterized by a wide QRS complex (>100 ms) (Fig. 2B). There may be atrioventricular dissociation during tachycardia, with the P wave bearing no relation to the QRS complex. VT is usually due to reentrance within the ventricle associated with ischemic heart disease or some types of cardiomyopathy. There are also hereditary forms of VT with normal cardiac structures, but these are relatively uncommon. VT is a life-threatening arrhythmia that leads to hemodynamic compromise and may degenerate into ventricular fibrillation (VF), a form of chaotic ventricular electrical activity (Fig. 4C) leading to an acute loss of pump function and death. This is the most common type of cardiac arrest.

Ventricular ectopic beats are associated with premature ventricular contraction. Typically, the electrocardiogram has a wide QRS complex that occurs earlier than expected and with a higher voltage (amplitude) and has an inverted T wave that obscures the P wave (Fig. 4D). Depolarization of the ventricles occurs prematurely outside the usual conduction pathway and, consequently, is slower, producing the wide

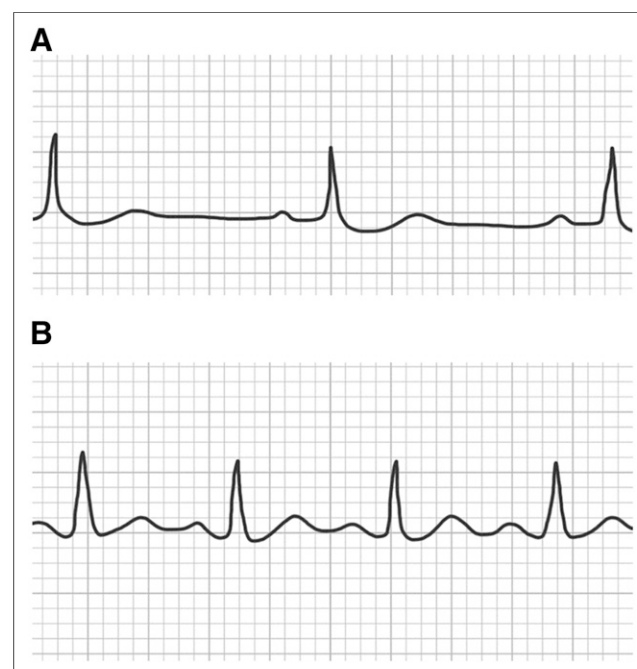


FIGURE 2. (A) Normal sinus rhythm with R-R interval of approximately 1 s (60 bpm). (B) Sinus tachycardia with R-R interval of approximately 2 s (>120 bpm). Approximately 2.2 large squares indicates that heart rate is 136 bpm (300/2.2).

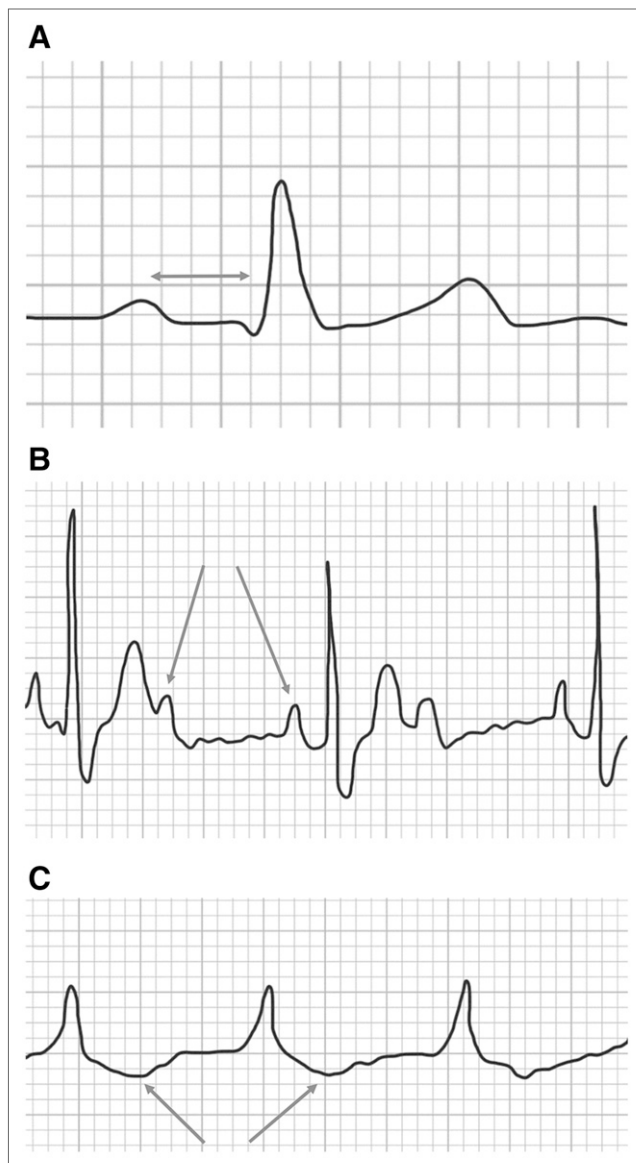


FIGURE 3. (A) Rhythm strip demonstrating first-degree atrioventricular block with PR interval of >200 ms. (B) Rhythm strip demonstrating second-degree atrioventricular block with progressive lengthening of PR interval and 2 P waves per R-R interval (arrows). (C) Rhythm strip demonstrating third-degree atrioventricular block. Atrioventricular dissociation results in no QRS but prominent P wave. Absence of Q wave allows visualization of repolarization of atria (arrow).

and unusually shaped QRS. This also results in less efficient ventricular contraction.

JUNCTIONAL REENTRANT TACHYCARDIA

Junctional tachycardia caused by a reentrant mechanism from a pathway close to the atrioventricular node is known as atrioventricular junctional reentrant tachycardia. Re-entrance through an additional pathway outside the atrioventricular node—an accessory pathway—may also cause junctional tachycardia. Junctional tachycardia is typically a

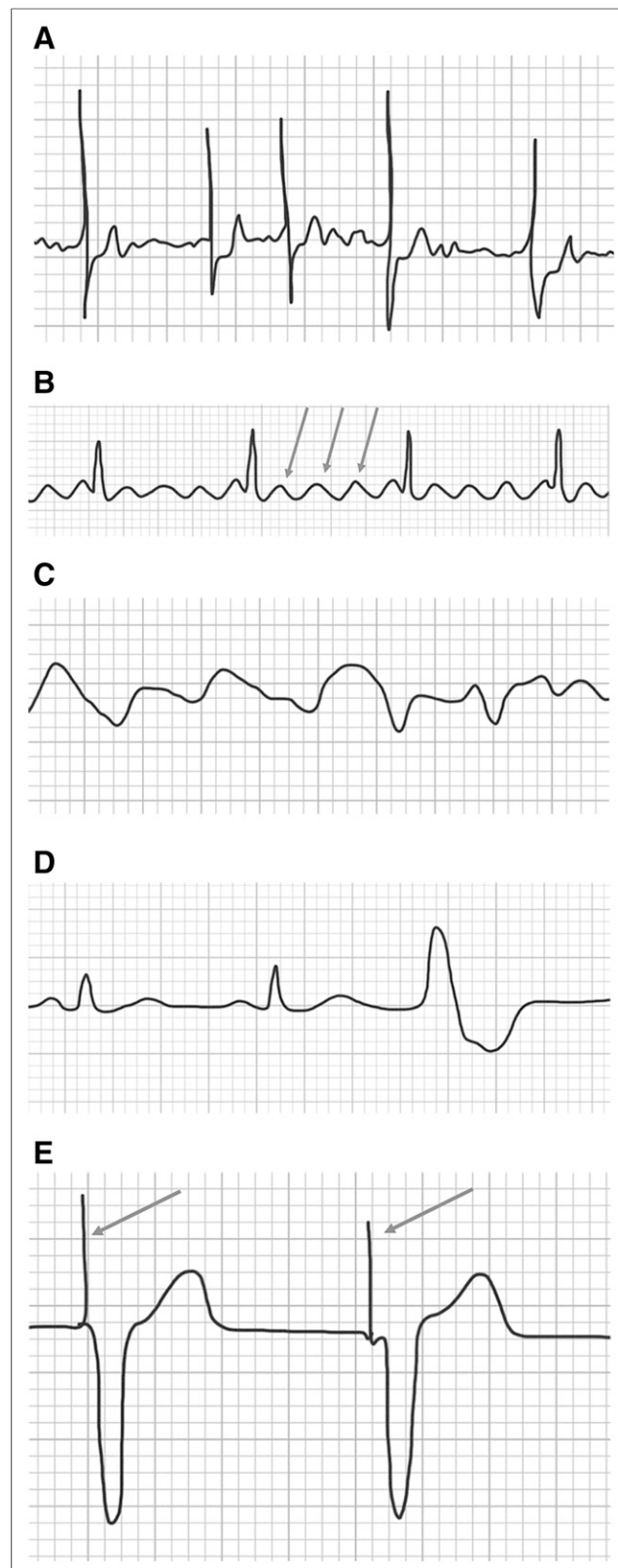


FIGURE 4. (A) Atrial fibrillation with rapid ventricular response. No P waves are seen, and ventricular rate is irregular and rapid. QRS complex is narrow. (B) Atrial flutter with sawtooth flutter wave (arrows). (C) VF with no organized QRS complex. (D) Ventricular ectopic beats. (E) Ventricular pacing spikes (arrow) and QRS morphology associated with left bundle branch block.

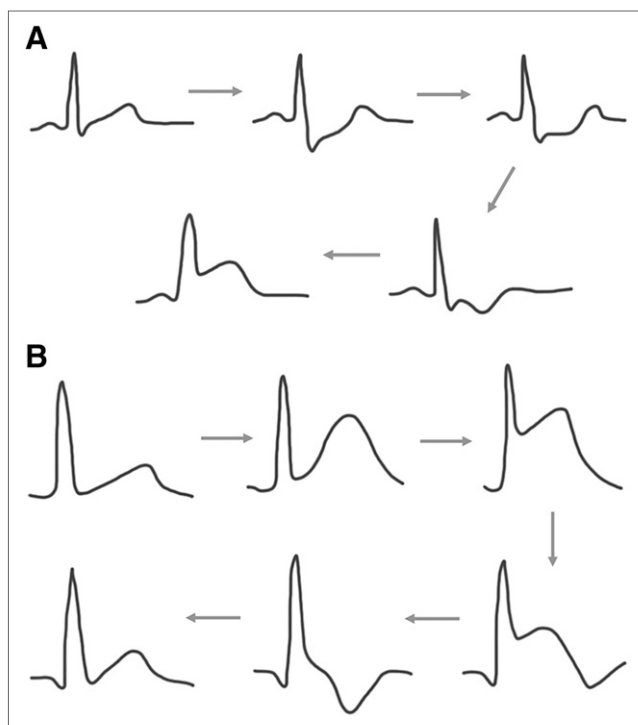


FIGURE 5. (A) Electrocardiogram appearance of myocardial ischemia spectrum. Clockwise: normal (P QRS T), upsloping ST depression (>1.5 mm); horizontal ST depression (>1 mm); downsloping ST depression (>1 mm); and ST elevation. (B) Electrocardiogram appearance of myocardial infarction spectrum. Clockwise: normal, hyperacute infarction (T wave); transmural infarction (ST elevation); necrosis (ST elevation, Q waves, and T wave inversion); necrosis/fibrosis (Q waves and T wave inversion); and fibrosis (Q wave and upright T wave).

narrow QRS complex tachycardia with a QRS width of less than 100 ms. The ventricular rate during junctional reentrant tachycardia is usually rapid, at more than 150 bpm. The P wave may not be visible or may follow closely behind the QRS complex. A resting electrocardiogram during sinus rhythm may be completely normal, but δ waves at the beginning of the QRS complex can occasionally be seen. The presence of the δ wave indicates an atrial-to-ventricular accessory conducting pathway.

BASICS OF ELECTROCARDIOGRAM INTERPRETATION

In electrocardiogram interpretation, one should first check the heart rate for bradycardia or tachycardia and then determine whether the rhythm is sinus by checking for the P wave. The presence of the P wave does not always mean sinus rhythm. The P wave vector must be checked in leads aVR, aVL, and aVF. A P wave arising from the sinoatrial node will be inverted in aVR and upright in aVL and aVF. In contrast, a P wave originating from the low atrium will be upright in aVR and inverted in aVF. If the P wave is upright in aVR and inverted in aVL, it is traveling from left to right, which is the opposite of the normal P vector. The limb lead placement should then be checked, as misplacement of the leads is the most common cause of this pattern. If the

rhythm is sinus, the relationship between the P wave and the QRS should be checked. Atrioventricular block is present if the P wave is not entirely conducted.

If the rhythm is not sinus and the P wave is absent, one should check whether the QRS rate is irregular, as would be the case in atrial fibrillation. One should also check the width of the QRS complex, for the sawtooth appearance of atrial flutter, and for right and left bundle branch block morphology. In cases of a widened QRS complex with a normal heart rate, one should check for ventricular pacing spikes because ventricular pacing causes a wide QRS complex with left bundle branch block morphology (Fig. 4E).

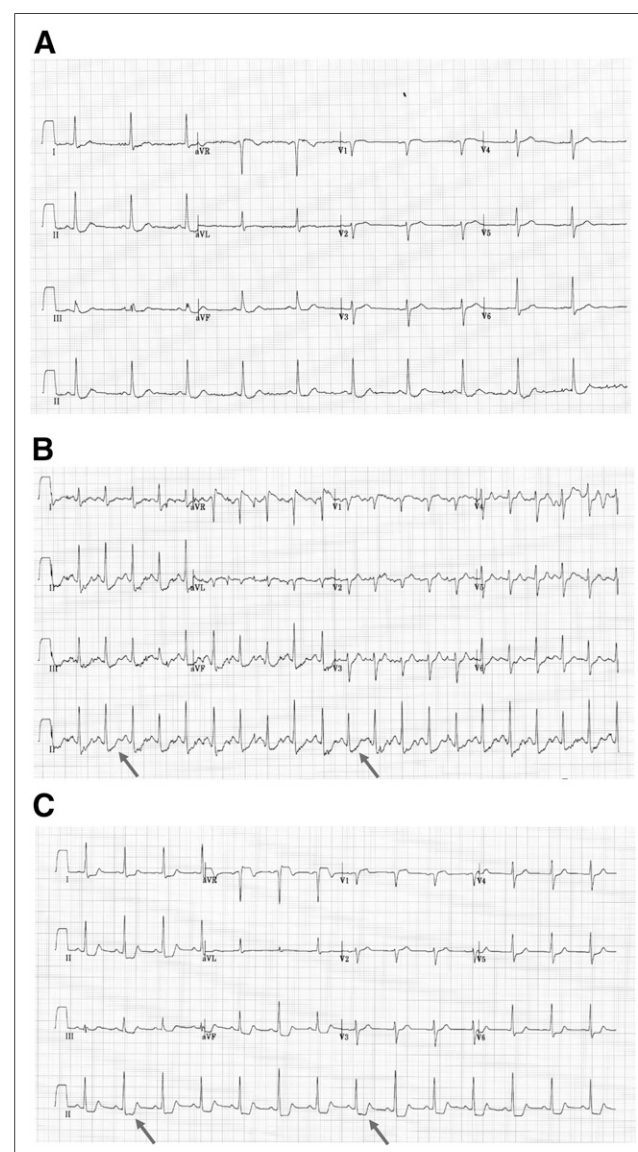


FIGURE 6. (A) Electrocardiogram appearance at baseline for patient with ischemic heart disease. (B) Stress electrocardiogram demonstrating inferolateral upsloping ST depression. (C) Poststress electrocardiogram demonstrating inferolateral horizontal ST depression, which indicates myocardial ischemia.

When the electrocardiogram shows a nonsinus tachyarrhythmia with a narrow and regular QRS complex, the main differential diagnoses are junctional reentrant tachycardia and atrial flutter. Wide-QRS-complex tachycardia is much more serious, as it can represent VT, which is life-threatening. Junctional reentrant tachycardia with aberrant conduction leading to wide-QRS-complex tachycardia may masquerade as VT. Distinguishing between VT and junctional reentrant tachycardia with aberrant conduction requires considerable experience. If in doubt, one should consider the tachyarrhythmia to represent VT until proven otherwise.

MYOCARDIAL ISCHEMIA

Other than cardiac arrhythmia, the electrocardiogram is a key diagnostic test for myocardial ischemia and acute myocardial infarction. Indeed, patients undergoing cardiac imaging in nuclear medicine often present with known or suspected ischemia or infarction. On the electrocardiogram, myocardial ischemia typically manifests as horizontal or downsloping ST segment depression (Fig. 5A). Patients presenting for cardiac imaging generally undergo stress testing in conjunction with imaging. These ischemic changes from baseline may be noted, and the increased heart rate should also be noted as stress-induced rather than tachycardia. An acute transmural myocardial infarction appears as an ST elevation of at least 1 mm (Fig. 5B). The group of leads that shows the ST elevation indicates the location of the infarct. An electrocardiogram showing ST elevation during a prolonged episode of chest pain is a key indicator for urgent coronary angiography with a view to revascularization. On the other hand, ST elevation may be seen in the relatively benign condition pericarditis. Pericarditic ST elevation has a different morphology from an acute myocardial infarct, and the ST changes tend to be widespread.

CASE EXAMPLE

A patient with a history of ischemic heart disease presented for a myocardial perfusion stress–rest SPECT

evaluation. The prestress electrocardiogram (Fig. 6A) provided a baseline. The stress test demonstrated upsloping ST depression in leads associated with the inferolateral wall (Fig. 6B). Because the ST depression was upsloping, it was not specifically indicative of myocardial ischemia. After stress, however, the ST depression became horizontal and as such was diagnostic of myocardial ischemia (Fig. 6C).

CONCLUSION

Monitoring an electrocardiogram is an essential role of the nuclear medicine technologist and is especially important in patients undergoing exercise or pharmacologic stress and in critical care patients. Although interpretation is generally beyond the scope of the nuclear medicine technologist, basic interpretive skills will allow recognition of potentially problematic or fatal arrhythmias, allowing for life-saving intervention.

DISCLOSURE

No potential conflict of interest relevant to this article was reported.

REFERENCES

1. Adams-Hamoda MG, Caldwell MA, Stotts NA, Drew BJ. Factors to consider when analyzing 12-lead electrocardiograms for evidence of acute myocardial ischemia. *Am J Crit Care*. 2003;12:9–16.
2. McCance KL, Huether SE. *Pathophysiology: The Biological Basis for Disease in Adults and Children*. 5th ed. St. Louis, MO: Mosby Elsevier; 2008.
3. Marieb EN. *Human Anatomy and Physiology*. 5th ed. New York, NY: Benjamin Cummings; 2001.
4. Chakrabarti S, Stuart AG. Understanding cardiac arrhythmias. *Arch Dis Child*. 2005;90:1086–1090.
5. Kligfield P, Gettes LS, Bailey JJ, et al. Recommendations for the standardization and interpretation of the electrocardiogram: part I: the electrocardiogram and its technology: a scientific statement from the American Heart Association Electrocardiography and Arrhythmias Committee, Council on Clinical Cardiology; the American College of Cardiology Foundation; and the Heart Rhythm Society: endorsed by the International Society for Computerized Electrocardiology. *Circulation*. 2007;115:1306–1324.
6. Horacek B. Lead theory. In: Macfarlane PW, Lawrie TDV, eds. *Comprehensive Electrocardiology: Theory and Practice in Health and Disease*. New York, NY: Pergamon Press; 1989:291–314.



Electrocardiography: A Technologist's Guide to Interpretation

Colin Tso, Geoffrey M. Currie, David Gilmore and Hosen Kiat

J. Nucl. Med. Technol. 2015;43:247-252.

Published online: October 15, 2015.

Doi: 10.2967/jnmt.115.163501

This article and updated information are available at:
<http://tech.snmjournals.org/content/43/4/247>

Information about reproducing figures, tables, or other portions of this article can be found online at:
<http://tech.snmjournals.org/site/misc/permission.xhtml>

Information about subscriptions to JNMT can be found at:
<http://tech.snmjournals.org/site/subscriptions/online.xhtml>

Journal of Nuclear Medicine Technology is published quarterly.
SNMMI | Society of Nuclear Medicine and Molecular Imaging
1850 Samuel Morse Drive, Reston, VA 20190.
(Print ISSN: 0091-4916, Online ISSN: 1535-5675)

© Copyright 2015 SNMMI; all rights reserved.