

# Use of SPECT/CT with $^{99m}\text{Tc}$ -MDP Bone Scintigraphy to Diagnose Symptomatic Os Acromiale

Zaid Al-faham and Prashant Jolepalem

Department of Diagnostic Radiology and Molecular Imaging, Oakland University William Beaumont School of Medicine and Health System, Royal Oak, Michigan

Os acromiale is an anatomic variant that in rare cases can cause pain.  $^{99m}\text{Tc}$ -methylene diphosphonate bone scintigraphy with SPECT/CT can play an important role in diagnosing this clinical entity. We present a male football player with shoulder pain secondary to a symptomatic os acromiale, and we demonstrate the findings on bone scanning with limited SPECT/CT that diagnosed this important clinical abnormality.

**Key Words:** bone; joint/muscle; SPECT/CT;  $^{99m}\text{Tc}$ -MDP; bone scintigraphy; os acromiale

**J Nucl Med Technol 2015; 43:236–237**

DOI: 10.2967/jnmt.114.150102

**I**n this report, we present a male football player with shoulder pain secondary to a symptomatic os acromiale. We demonstrate the findings on bone scanning with limited SPECT/CT that diagnosed this important clinical abnormality.

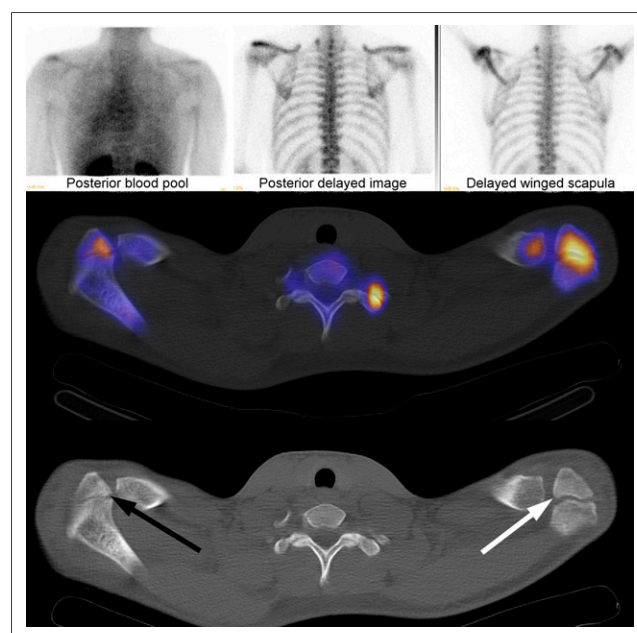
## CASE REPORT

An 18-y-old male American football player presented with persistent left shoulder pain and the inability to abduct his arm beyond  $45^\circ$  for the past 6 mo. Plain radiography was unremarkable, and MR imaging did not reveal a rotator cuff tear.  $^{99m}\text{Tc}$ -methylene diphosphonate bone scintigraphy was performed using 897.6 MBq (24.26 mCi) on a dual-head camera fitted with high-resolution, low-energy collimators. Blood-pool images were obtained shortly after injection, and delayed static images were obtained approximately 3 h after the initial injection. The images revealed asymmetric increased activity near the left acromion process on the early blood-pool and delayed static images. SPECT/CT was performed for further anatomic localization with the field of view restricted to the shoulders. The images demonstrated incomplete fusion of both acromion processes, which could be age-related in this patient. However, the ossification center in the left apophysis occurred at the meso-acromion rather than at the preacromion (as on the right side)

and was associated with more activity (Fig. 1), indicating ongoing osteoblastic activity likely from incomplete fusion. This finding was consistent with painful os acromiale.

## DISCUSSION

Os acromiale is an anatomic variant caused by the failure of the anterior acromial apophysis to fuse to the acromion process. Instead, it is joined to the scapular spine by fibrocartilaginous tissue rather than ossified bone (1). Os acromiale is typically an incidental finding that is present in about 8% of the population (1,2). It is rare for os acromiale to be symptomatic, but it has been implicated in shoulder impingement syndromes mimicking rotator cuff injuries (3). There are multiple cases that described painful os acromiale and were diagnosed with plain radiographs (4). However, this is the first time to our knowledge that painful os acromiale has been described on bone scintigraphy with SPECT/CT.



**FIGURE 1.** Top row shows static bone scan and blood-pool images, middle row images shows fused SPECT/CT images, and bottom row shows attenuation correction CT. Arrows are placed at ossification centers of apophyses. Center is at meso-acromion on left (white arrow) but at preacromion on right (black arrow). Right apophysis is nearly fused and has less activity than unfused apophysis of left acromion.

Received Oct. 14, 2014; revision accepted Dec. 15, 2014.  
For correspondence or reprints contact: Zaid Al-faham, William Beaumont Hospital, 3601 W. 13 Mile Rd., Royal Oak, MI 48073.  
E-mail: [zaidfaham@gmail.com](mailto:zaidfaham@gmail.com)  
Published online Feb. 5, 2015.  
COPYRIGHT © 2015 by the Society of Nuclear Medicine and Molecular Imaging, Inc.

After failure of conservative treatment including physical therapy, nonsteroidal antiinflammatory agents, and subacromial corticosteroid, these patients usually undergo surgical intervention (5). Our patient failed conservative management and was subsequently referred for surgical resection of the incompletely fused ossification center to relieve his pain.

## CONCLUSION

Os acromiale is an anatomic variant that in rare cases can cause pain.  $^{99m}\text{Tc}$ -methylene diphosphonate bone scintigraphy with SPECT/CT can play an important role in diagnosing this clinical entity.

## DISCLOSURE

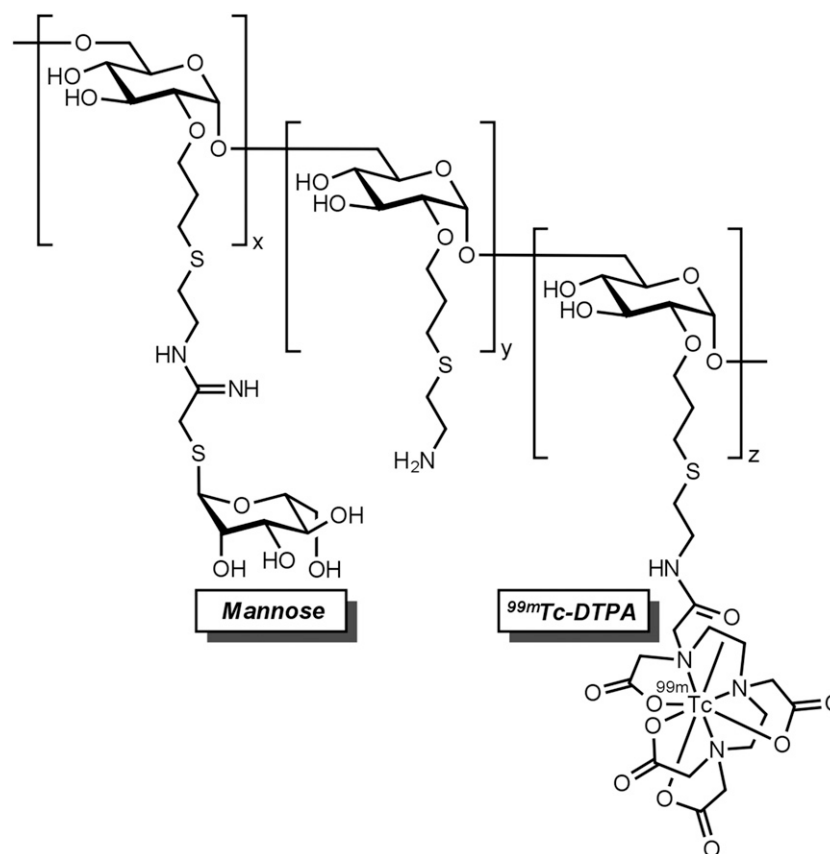
No potential conflict of interest relevant to this article was reported.

## REFERENCES

1. Kurtz CA, Humble BJ, Rodosky MW, Sekiya JK. Symptomatic os acromiale. *J Am Acad Orthop Surg*. 2006;14:12–19.
2. Sammarco VJ. Os acromiale: frequency, anatomy, and clinical implications. *J Bone Joint Surg Am*. 2000;82:394–400.
3. Burbank KM, Lemos MJ, Bell G, Lemos DW. Incidence of os acromiale in patients with shoulder pain. *Am J Orthop*. 2007;36:153–155.
4. Pagnani MJ, Mathis CE, Solman CG. Painful os acromiale (or unfused acromial apophysis) in athletes. *J Shoulder Elbow Surg*. 2006;15:432–435.
5. Ortiguera CJ, Buss DD. Surgical management of the symptomatic os acromiale. *J Shoulder Elbow Surg*. 2002;11:521–528.

## Erratum

In the article “ $^{99m}\text{Tc}$ -Tilmanocept: A Novel Molecular Agent for Lymphatic Mapping and Sentinel Lymph Node Localization,” by Surasi et al. (*J Nucl Med Technol*. 2015;43:87–91), the structure of  $^{99m}\text{Tc}$ -tilmanocept (Lymphoseek; Navidea) provided in Figure 1 is incorrect. The correct structure is shown below. The authors regret the error.





## Use of SPECT/CT with $^{99m}\text{Tc}$ -MDP Bone Scintigraphy to Diagnose Symptomatic Os Acromiale

Zaid Al-faham and Prashant Jolepalem

*J. Nucl. Med. Technol.* 2015;43:236-237.

Published online: February 5, 2015.

Doi: 10.2967/jnmt.114.150102

---

This article and updated information are available at:  
<http://tech.snmjournals.org/content/43/3/236>

---

Information about reproducing figures, tables, or other portions of this article can be found online at:  
<http://tech.snmjournals.org/site/misc/permission.xhtml>

Information about subscriptions to JNMT can be found at:  
<http://tech.snmjournals.org/site/subscriptions/online.xhtml>

*Journal of Nuclear Medicine Technology* is published quarterly.  
SNMMI | Society of Nuclear Medicine and Molecular Imaging  
1850 Samuel Morse Drive, Reston, VA 20190.  
(Print ISSN: 0091-4916, Online ISSN: 1535-5675)

© Copyright 2015 SNMMI; all rights reserved.