

Native Aortic and Prosthetic Vascular Stent Infection on ^{99m}Tc -Labeled White Blood Cell Scintigraphy

Seung Wook Ryu and Kevin C. Allman

Department of PET/Nuclear Medicine, Royal Prince Alfred Hospital, University of Sydney, Sydney, Australia

The value of ^{99m}Tc -labeled white blood cell scintigraphy for endovascular prosthetic infections is well known. In the unique case reported here, infection of the native aorta was detected in addition to an infected vascular prosthesis. The case demonstrates that ^{99m}Tc -labeled white blood cell scintigraphy can identify not only the more usual prosthetic stent/graft infection but also infection of the native aorta. When scrutinizing studies for infection of prosthetic material, readers should also carefully examine the native aorta.

Key Words: molecular imaging; vascular; aortic aneurysm; aortitis; vascular stent infection; white blood cell scintigraphy

J Nucl Med Technol 2014; 42:120–121

DOI: 10.2967/jnm.113.127704

The value of ^{99m}Tc -labeled white blood cell scintigraphy for endovascular prosthetic infections is well known. We report a unique case in which infection of the native aorta was detected in addition to an infected vascular prosthesis.

CASE REPORT

An 81-y-old man presented with lower abdominal pain and fever 4 wk after insertion of an endovascular stent for left iliac artery aneurysm. He had previously undergone multiple endovascular procedures for an infrarenal aortic aneurysm and a ruptured aortic aneurysm. A ^{99m}Tc -labeled white blood cell study was performed to assess for vascular stent infection in this patient with suspected aortic stent infection. An autologous buffy coat was obtained from a venous sample from the patient and labeled with ^{99m}Tc -colloid (stannous) (Radpharm Scientific). Quality control measures demonstrated labeling efficiency of 97%. Scintigraphic images were taken 3 h after injection with 1,040 MBq (28 mCi) of radiolabeled autologous leukocytes.

Received Jul. 1, 2013; revision accepted Nov. 11, 2013.
For correspondence or reprints contact: Seung Wook Ryu, Department of PET/Nuclear Medicine, Royal Prince Alfred Hospital, Building 63, Level A7, Missenden Rd., Camperdown, NSW, 2050, Australia.
E-mail: swk.ryu@gmail.com
Published online Feb. 20, 2014.
COPYRIGHT © 2014 by the Society of Nuclear Medicine and Molecular Imaging, Inc.

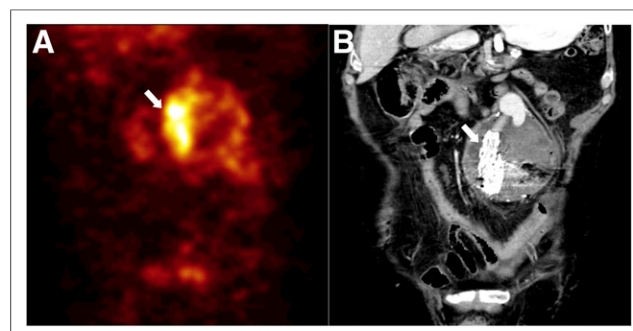


FIGURE 1. Coronal ^{99m}Tc -labeled white blood cell scintigraphy SPECT (A) and CT (B) images of abdomen, with arrows indicating deployed vascular stents in abdominal aorta.

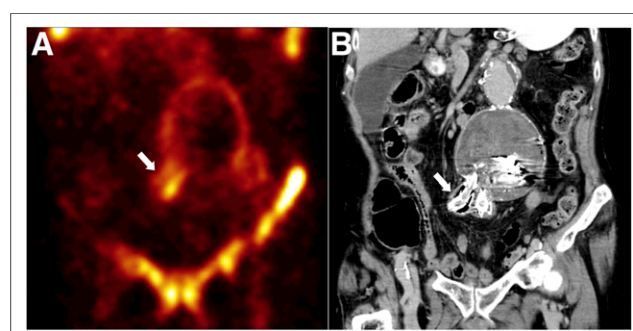


FIGURE 2. Coronal ^{99m}Tc -labeled white blood cell scintigraphy SPECT (A) and CT (B) images of abdomen, with arrows indicating deployed vascular stents in right common iliac artery.

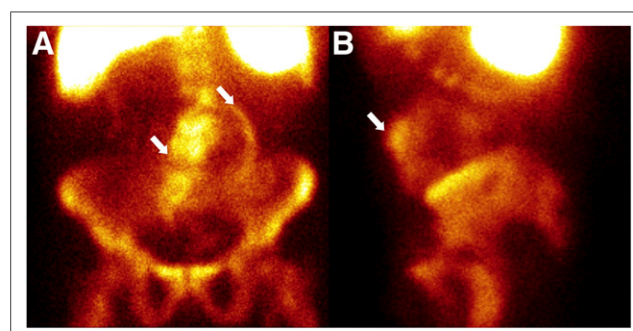


FIGURE 3. Anterior (A) and left lateral (B) ^{99m}Tc -labeled white blood cell scintigraphy planar images of abdomen demonstrating increased uptake (arrows) in vascular stent and in wall of native aorta

Images were compared with corresponding CT images after administration of intravenous and oral contrast material (Figs. 1 and 2). A whole-body study (not shown) showed no additional remote sites of infection.

DISCUSSION

Scintigraphic visualization of infection in the native aorta itself has not been previously reported to our knowledge. In this patient, the images clearly indicated abnormal scintigraphic uptake in the native aortic aneurysm. The anterior and left lateral planar views of Figure 3 show increased white cell uptake in a spheric pattern outlining the wall of the native aneurysmal abdominal aorta tracking down into the right iliac artery.

The findings are consistent with native abdominal aortic infection as well as infection of the prosthetic aortic stent. The sites of uptake on SPECT imaging (Figs. 1 and 2) correlated with the sites of previously deployed vascular stents. The increased uptake was clearly seen in the aortic stent extending into the right iliac stent as well as in the native aortic aneurysm wall. Laboratory investigations revealed leukocytosis (white cell count, $13,000 \text{ cm}^3$) and elevated C-reactive protein (230 mg/L). A blood culture grew gram-negative *Bacteroides fragilis* (1), a pathogen previously reported to be associated with infected aortic aneurysm.

Endoluminal prosthetic graft infection is a rare, potentially life-threatening complication after reconstructive vascular surgery (2,3). Standard radiologic imaging may be unreliable in detection of early or low-grade infections (2,3) and demonstrate only secondary anatomic effects of inflammation caused by the graft infection (2,4). The use of $^{99\text{m}}\text{Tc}$ -labeled white blood cell scintigraphy has been shown to be a reliable investigation regardless of the stage (early or late) or severity (low or

high grade) of infection, with reported sensitivity and specificity values over 90% (2,5), and the results have been widely published. Whether multiple reconstructive vascular surgeries or the type of microorganism poses a risk of infection to the native aorta remains uncertain. The principal treatment for stent infection is total excision; however, because of the patient's age and comorbidities he was treated conservatively with antibiotics and, thus, a follow-up scan was not indicated. The patient died 2 wk after the scan.

CONCLUSION

This case shows that $^{99\text{m}}\text{Tc}$ -labeled white blood cell scintigraphy may identify not only the more usual prosthetic stent/graft infection but also infection of the native aorta. When scrutinizing studies for infection of prosthetic material, readers should also carefully examine the native aorta.

DISCLOSURE

No potential conflict of interest relevant to this article was reported.

REFERENCES

1. O'Donnell JA, Asbel L. *Bacteroides fragilis* bacteremia and infected aortic aneurysm presenting as fever of unknown origin: diagnostic delay without routine anaerobic blood cultures. *Clin Infect Dis*. 1999;29:1309–1311.
2. Fiorani P, Speziale F, Rizzo L, et al. Detection of aortic graft infection with leukocytes labeled with technetium $^{99\text{m}}$ -hexamethazime. *J Vasc Surg*. 1993;17:87–95.
3. Mita T, Arita T, Matsunaga N, et al. Complications of endovascular repair for thoracic and abdominal aortic aneurysm: an imaging spectrum. *Radiographics*. 2000;20:1263–1278.
4. Ruf J, Oeser C, Amthauer H. Clinical role of anti-granulocyte MoAb versus radiolabeled white blood cells. *Q J Nucl Med Mol Imaging*. 2010;54:599–616.
5. Liberatore M, Miscuraca M, Calandri E, et al. White blood cell scintigraphy in the diagnosis of infection of endovascular prostheses within the first month after implantation. *Med Sci Monit*. 2006;12:MT5–MT9.



Native Aortic and Prosthetic Vascular Stent Infection on ^{99m}Tc -Labeled White Blood Cell Scintigraphy

Seung Wook Ryu and Kevin C. Allman

J. Nucl. Med. Technol. 2014;42:120-121.

Published online: February 20, 2014.

Doi: 10.2967/jnmt.113.127704

This article and updated information are available at:
<http://tech.snmjournals.org/content/42/2/120>

Information about reproducing figures, tables, or other portions of this article can be found online at:
<http://tech.snmjournals.org/site/misc/permission.xhtml>

Information about subscriptions to JNMT can be found at:
<http://tech.snmjournals.org/site/subscriptions/online.xhtml>

Journal of Nuclear Medicine Technology is published quarterly.
SNMMI | Society of Nuclear Medicine and Molecular Imaging
1850 Samuel Morse Drive, Reston, VA 20190.
(Print ISSN: 0091-4916, Online ISSN: 1535-5675)

© Copyright 2014 SNMMI; all rights reserved.