

An Unusual Case of a Tibial Metastasis as the Clinical Presentation of Bronchogenic Adenocarcinoma

Wei-Jen Shih, Sylvia Magoun, Barbara Lahar, Vickie Stipp and Kelly Gross

Nuclear Medicine and Radiology Services, Veterans Administration and University Medical Centers, Lexington, Kentucky

A patient with initial complaints of leg pain and difficulty walking was found to have a large right tibial metastatic tumor and poorly differentiated adenocarcinoma of the lung. Findings from total-body bone scintigraphy include a large area of increased uptake in the proximal half of the right tibia with a photon-deficient area medially, and focal areas of uptake in a right rib, in the femoral neck and the left ileum. An irregular area of increased uptake in the left lung mass was shown by thoracic bone SPECT. This is an unusual case of a tibial metastasis as the first clinical presentation of bronchogenic adenocarcinoma.

Key Words: lung cancer; bone scintigraphy; metastasis

J Nucl Med Technol 1998; 26:91-93

CASE REPORT

A 68-yr-old man, a smoker with chronic obstructive pulmonary disease (COPD) and hypertension, presented to the orthopedic clinic with several months history of right knee pain without trauma. The radiography of the right knee showed an osteolytic lesion with ill-defined margins in the proximal metaphysis of the medial tibia. This had cortical destruction and breakthrough with an associated soft tissue mass (Fig. 1). The differential diagnosis included neoplastic and infectious processes. Technetium-99m HMDP bone images showed increased uptake in a segment of the right tenth rib posteriorly, a focal area of increased uptake in the left ileum, a small focal area of increased uptake in the right femoral neck, and marked increased uptake in the proximal portion of the right tibia with an irregular photon deficient area in its medial aspect (Fig. 2A). SPECT imaging of the thorax showed a mild and irregular increase in radioactivity in the right posterior lower lung (Fig. 2B). The multiple skeletal lesions most likely were due to metastases from a primary lung carcinoma. CT of the right tibia showed a 5-cm lytic lesion of the medial proximal tibial metaphysis with disruption of the medial cortex and a soft

tissue component extending beyond the confines of bony cortex (Fig. 3). CT of the chest (Fig. 4) showed a large mass in the region of the superior segment of the left lower lung with mediastinal, subcarinal and aortopulmonary enlarged lymph nodes. Multiple hepatic metastases also were noted. CT of the brain was normal. The patient had excision of the right tibial tumor with bone cement placement. Histopathological examination reported poorly differentiated adenocarcinoma. The diagnosis of Stage IV metastatic adenocarcinoma of the lung was made. The patient was scheduled for radiation therapy.

DISCUSSION

The general pattern of distribution of metastatic bone disease is more than 60% of metastases are in axial bones and 40% in the appendicular bones (1). With this pattern, the primary malignancy usually originates from breast or prostate. In lung cancer patients, appendicular bone deposits are more than that of axial bone (54.8% vs. 45.7%) (1). Our patient had

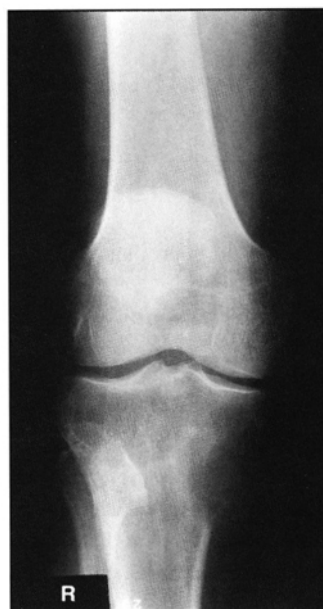

FIGURE 1. An anterior (AP) view of the right knee shows an osteolytic lesion in the proximal metaphysis of the medial tibia.

For correspondence or reprints contact: Wei-Jen Shih, MD, Nuclear Medicine Service, DVA Medical Center, 2250 Leestown Rd., Lexington, KY 40511-1093.

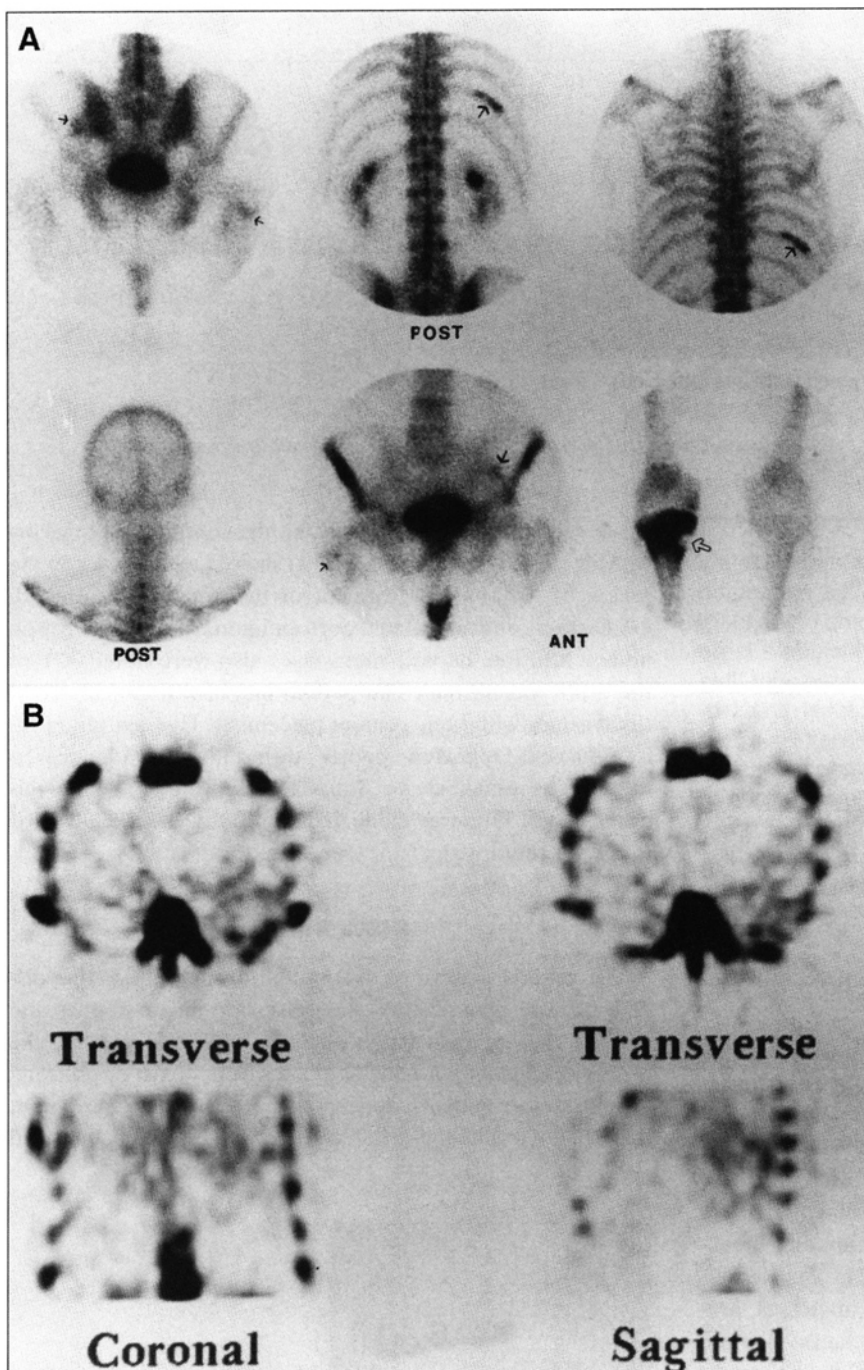


FIGURE 2. (A) Bone images show focal areas of increased uptake (arrows) in the left ileum, in a segment of a right lower rib, a small focal area of uptake in the right femoral neck, and marked increased uptake with a cold area, as indicated by an open arrow, in the right proximal tibia. No abnormal area of increased uptake in the cervical, thoracic and lumbar vertebrae is noted. (B) Technetium-99m HMDP bone SPECT images of the thorax show a faint increase in uptake in the left posterior thorax.

no metastasis to the skull, vertebrae and sacroiliac joint, as described previously (1).

Appendicular (peripheral) bone metastases in two patients with bronchogenic adenocarcinoma has been reported. One patient presented with bilateral knee pain and bone scintigraphy showed bilateral uptake in the patellae and a focal area of uptake in the right rib (2). Another patient had metastases to the finger, pelvic bone and femur (3). Our patient's initial presentation of bronchogenic adenocarcinoma was right knee pain without any history of trauma. Our patient and two previously reported patients with bronchogenic adenocarcinoma presented with peripheral bone metastases with no vertebral

lesions. Our patient's radiographic lytic tibial lesion corresponded with an irregular cold area within the medial aspect of a region of diffusely increased uptake in the proximal half of the right tibia. Bone scintigraphy showed more extensive involvement of the upper half of the right tibia than did plain film.

Bone imaging agent localization in our patient's lung tumor is similar to bone agent localization in massive/multiple hepatic metastases from the colon (4). It has been proposed that tissue necrosis/irreversible ischemia is related to bone agent localization, since diffuse uptake of the bone agent in massive hepatic necrosis has been observed (5). The incidental finding of

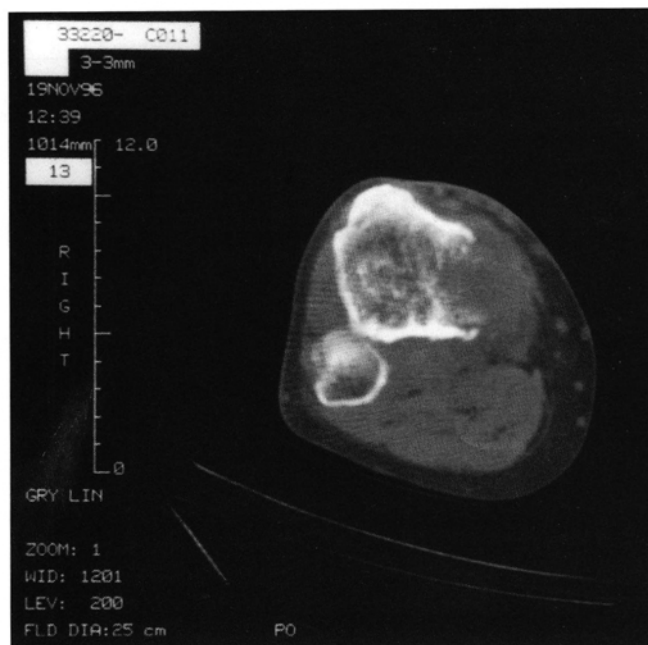


FIGURE 3. CT of the tibia further characterizes the proximal tibial lesion. Cortical breakthrough medullae with an abnormal soft tissue mass extending into the adjacent soft tissue is shown.

increased uptake in the area of a lung mass on bone scintigraphy may be observed and such a finding may reflect rapid growth of tumor cells leading to tumor ischemia/necrosis.

CONCLUSION

A bronchogenic adenocarcinoma patient with a tibial metastasis as the initial clinical presentation had bone imaging agent localization in the lung tumor and prominent skeletal bone metastases. Plain radiographic film and CT of the tibia showed a lytic lesion corresponding to a cold area on the bone scan, but

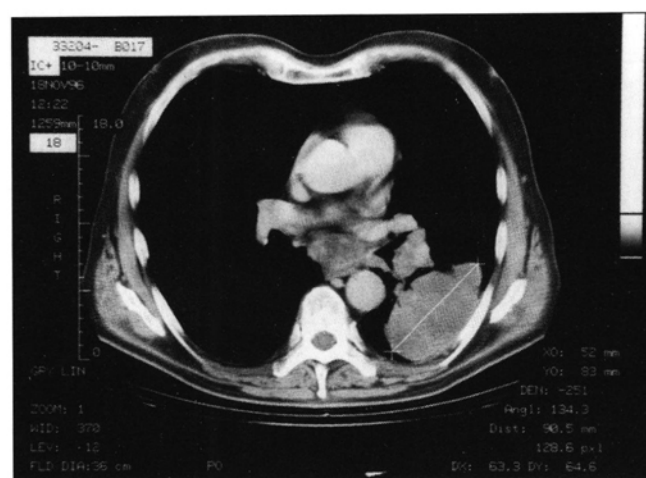


FIGURE 4. CT of the chest shows a large mass lesion in the superior segment of the left lower lobe with mediastinal and hilar adenopathy.

scintigraphic changes showed more extensive involvement of the proximal right tibia. Thus, a peripheral metastasis may be the initial clinical presentation of a bronchogenic carcinoma.

REFERENCES

1. Krishnamurthy GT, Tubis M, Hiss J, Bland WH. Distribution pattern of metastatic bone disease. A need for total body skeletal image. *JAMA* 1977; 237:2504-2506.
2. Pauzner R, Istomin V, Segal-Lieberman G, et al. Bilateral patellar metastases as the clinical presentation of bronchogenic adenocarcinoma. *J Rheumatology* 1996;23:939-941.
3. Knapp D, Abdul-Karim FW. Fine needle aspiration cytology of acrometastasis. A report of two cases. *Acta Cytologica* 1994;38:589-591.
4. Stevens JS, Clark EE. Liver metastasis of colon adenocarcinoma demonstrated on ^{99m}Tc pyrophosphate bone scan. *Clin Nucl Med* 1977;2:270-271.
5. Shih WJ, Coupal J. Diffuse and intense ^{99m}Tc HMDP localization in the liver due to hypoxia secondary to respiratory failure. *Clin Nucl Med* 1994;19:116-120.



An Unusual Case of a Tibial Metastasis as the Clinical Presentation of Bronchogenic Adenocarcinoma

Wei-Jen Shih, Sylvia Magoun, Barbara Lahar, Vickie Stipp and Kelly Gross

J. Nucl. Med. Technol. 1998;26:91-93.

This article and updated information are available at:
<http://tech.snmjournals.org/content/26/2/91>

Information about reproducing figures, tables, or other portions of this article can be found online at:
<http://tech.snmjournals.org/site/misc/permission.xhtml>

Information about subscriptions to JNMT can be found at:
<http://tech.snmjournals.org/site/subscriptions/online.xhtml>

Journal of Nuclear Medicine Technology is published quarterly.
SNMMI | Society of Nuclear Medicine and Molecular Imaging
1850 Samuel Morse Drive, Reston, VA 20190.
(Print ISSN: 0091-4916, Online ISSN: 1535-5675)

© Copyright 1998 SNMMI; all rights reserved.