

## Ictal Perfusion Brain SPECT in Pediatric Patients with Intractable Epilepsy: A Multidisciplinary Approach

Royal T. Davis, S. Ted Treves, Alan B. Packard, Judith B. Farley, Ronald K. Amoling and James S. Ulanski

*Division of Nuclear Medicine, Department of Radiology and Department of Nursing, Children's Hospital, Harvard Medical School, Boston, Massachusetts*

**Objective:** Localizing epileptogenic regions of the brain is important in the diagnosis and treatment of pediatric patients with intractable epilepsy. Ictal perfusion brain SPECT can be used to localize these epileptogenic foci. Ictally, a focal perfusion increase is observed in >90% of the patients, but the radiotracer must be given to the child during the seizure. Since it is not practical to have nuclear medicine personnel waiting for the patient to experience a seizure, a multidisciplinary approach was developed that included nuclear medicine, neurology, nursing and radiation safety.

**Methods:** Six nurses were trained in the procedures necessary to safely administer precalibrated doses of tracer to the patient during seizures. Technetium-99m-bicisate was used for the studies because the 6-hr shelf-life provided a reasonable time frame in which to capture the seizures. Patients were transported to nuclear medicine for imaging 1–3 hr after tracer administration.

**Results:** Between June 1994 and July 1995 we obtained ictal SPECT in 30 children. Focal increases in rCBF were detected in more than 90% of these patients. In contrast, interictal SPECT in the same patients revealed regional decreases in cerebral blood flow in only 50% of these studies.

**Conclusion:** Multidisciplinary cooperation and training allowed consistently successful ictal SPECT in epileptic patients. Ictal SPECT is more sensitive for the localization of epileptogenic foci than interictal SPECT.

**Key Words:** epilepsy; children; multidisciplinary; epileptogenic; ictal; technetium-99m-bicisate; SPECT.

*J Nucl Med Technol 1996; 24:219–222*

Epileptic seizures are frequently accompanied by focal changes in regional cerebral blood flow (rCBF) or metabolism. Brain SPECT using radiopharmaceuticals that reflect rCBF can, therefore, be employed to identify the seizure focus. Changes in rCBF are less pronounced interictally, however, than ictally, and interictal brain SPECT is thus less effective than ictal SPECT for the localization of epileptogenic foci (1,2). Also, if

the tracer is administered soon after seizure activity has ceased, the rCBF does not represent that of the acute ictal event but will instead reflect a more diffuse brain activation pattern (3–8). Immediate post-ictal brain SPECT is not as effective as ictal SPECT in the localization of epileptogenic foci.

To achieve a high yield of ictal SPECT several conditions must be met: (a) the patient must be in an environment where the patient can be carefully monitored to ensure the tracer injection is given during the actual seizure; (b) an intravenous line must be established a priori to permit rapid tracer administration during the seizure; (c) the radiopharmaceutical must be available at the patient's bedside at the appropriate dose; (d) and personnel trained in the administration of radiopharmaceuticals must be in the immediate vicinity of the patient to ensure the tracer is injected as quickly as possible during the seizure.

Pediatric patients with medically intractable epilepsy who are admitted to the neuroscience unit for long-term monitoring are ideal candidates for ictal brain SPECT because they are continuously monitored by electroencephalogram (EEG) and video while in the unit providing confirmation of seizure activity. The neuroscience nursing staff is always present to observe the patients. All that remained to meet all conditions stated above was the availability of an rCBF tracer of adequate stability to keep at the patient's bedside throughout the day, and a procedure for training the nursing staff to administer the tracer. The former requirement was met with <sup>99m</sup>Tc-bicisate (2). For the latter it was necessary to develop a multidisciplinary approach that included nuclear medicine, neurology, nursing and radiation safety. The multidisciplinary team developed specific policies, procedures, training and monitoring programs. This multidisciplinary approach permitted a high yield of localization of epileptogenic foci in patients with refractory epilepsy by ictal perfusion brain SPECT.

### MATERIALS AND METHODS

#### Patients

The study was carried out under a protocol approved by the Children's Hospital Institutional Review Board. In all patients

For correspondence or reprints contact: S. T. Treves, MD, Division of Nuclear Medicine, Children's Hospital, 300 Longwood Ave., Boston, MA 02115.

the indication for the perfusion brain SPECT was for localization of seizure foci. All patients admitted to the neuroscience unit for long-term monitoring (EEG and video) were enrolled in the study. An intravenous line was established early on the day of the scheduled ictal study. Written informed consent was obtained in all cases. Ictal SPECT was obtained in 30 children. Seventeen of the children were boys and 13 were girls (mean age 13.3 yr, range 1 mo to 21 yr). There were 6 additional patients in whom ictal SPECT was not obtained due to a lack of seizure activity during the time when the tracer was available.

### Nursing Protocol

The protocol was jointly developed by the departments of nursing, nuclear medicine, neurology and radiation safety at Children's Hospital. This protocol spelled out procedural details, training requirements, monitoring and appropriate delineation of responsibilities. The protocol was approved by all the participating departments.

### Training of Nurses

With the approval of the directors of nursing and nuclear medicine, six nurses of the neuroscience unit were identified and trained in the safe handling and administration of radiopharmaceuticals. Initial training was provided by the radiation safety officer and consisted of basic radiation safety practices, and dosimetry after which the nurses were provided with radiation dosimeters (film badges). Nurses were then trained by nuclear medicine staff in procedures associated with the injection of  $^{99m}\text{Tc}$ -bicisate. Then each nurse was monitored by nuclear medicine staff for three consecutive radiopharmaceutical injections. After satisfactory completion of this training, privileges for this procedure were granted to the nurses by the director of the division of nuclear medicine. Documentation of competency is maintained by both the RSO and in the employees personnel file. Only trained nurses were allowed to receive and inject  $^{99m}\text{Tc}$ -bicisate.

### Radiopharmaceutical and Doses

Technetium-99m-bicisate (ECD, Neurolite<sup>®</sup>, Dupont Merck Pharmaceuticals, Billerica, MA), was used for this study because the 6-hr shelf-life allows a reasonable time frame in which to capture the ictal event (2). The kit was reconstituted and the radiochemical purity was tested as described in the package insert. The administered dose was 300  $\mu\text{Ci/Kg}$  (11.1 MBq/Kg) with a minimum dose of 5 mCi (185 MBq) and a maximum dose of 20 mCi (740 MBq). Technetium-99m-bicisate is thought to accumulate in the brain by diffusion where it is rapidly metabolized to a polar compound that is retained (9). Stability studies of  $^{99m}\text{Tc}$ -bicisate have demonstrated that there is no decomposition of the complex over a 24-hr period (10).

A physician's order form was designed to include indication, radiopharmaceutical, dose schedule and signatures of the nuclear medicine physician, nuclear medicine technologist and nurse. The dose schedule provided a calibration table of administered dose (mCi/ml) versus time. This sheet accompanied

all prepared and assayed doses of  $^{99m}\text{Tc}$ -bicisate to the patient's bedside. Signatures of both the nuclear medicine physician and the technologist were required before the tracer could be delivered to the nurse in the neuroscience unit (Fig. 1).

The tracer was prepared at 8:00 am on the morning of the scheduled ictal SPECT. The patient's dose (corrected for radioactive decay at 6 hr) was loaded into a syringe and placed in a labeled lead-shielded transport box. The dose was then delivered by a nuclear medicine technologist to the patient's nurse in the neuroscience unit where it was stored in a locked cabinet at the patient's bedside until the time of injection. Traffic in the patient's room was limited and the radioactive material was constantly under surveillance.

### Ictal Injection

When a seizure was observed on EEG or visually with EEG confirmation, the nurse injected the appropriate volume of tracer through the previously established intravenous line and documented the administered amount. The injection volume was determined from the calibrated dose schedule included on the signed physician's order form provided by nuclear medicine and was verified by two trained registered nurses. After successful administration of the radiopharmaceutical, the division of nuclear medicine was notified, and a nuclear medicine technologist collected the lead storage box and associated materials, monitored the area and retrieved all documentation including a radioactive waste release signature from the administering nurse. The nuclear medicine technologist also verified with the EEG technician that the continuous monitoring documentation was marked at the ictal event and the radiopharmaceutical was administered successfully during that ictal event. A copy of this documentation was also provided to the division of nuclear medicine. The nuclear medicine technologist then returned to the division with all documentation, the storage box and all radioactive waste for disposal. Finally, the actual administered dose was verified by the technologist by assaying the syringe in the dose calibrator and correcting for decay.

### SPECT

After cessation of the seizure, the child was transported to nuclear medicine for brain SPECT. Imaging was usually performed between 1 and 3 hr postinjection. Sedation, if indicated, was accomplished according to departmental sedation guidelines (11). Thirteen patients (43%) required sedation. SPECT was obtained with a triple-detector system (MULTISPECT 3<sup>™</sup>, Siemens Gammasonics, Inc. Hoffman Estates, IL) equipped with ultra-high resolution collimators. The studies were recorded on a 128  $\times$  128 matrix, 120 stops, 360° rotation per detector, step and shoot mode with a 1.45 zoom factor. A typical SPECT was obtained in 20 min. Reconstruction was done using a Butterworth filter and Chang's attenuation correction. The three-dimensional image sets were then aligned using a method developed at Children's Hospital. Slices were displayed in the transaxial, coronal and sagittal projections (12).

<b>DOCTOR'S ORDER SHEET</b>	<div style="text-align: center; font-weight: bold; font-size: small;">USE PLATE OR PRINT</div> <div style="font-size: x-small;">PT. NAME: _____</div> <div style="display: flex; justify-content: space-between; font-size: x-small;"> <span>LAST</span> <span>FIRST</span> </div> <div style="font-size: x-small;">DATE: _____</div> <div style="display: flex; justify-content: space-between; font-size: x-small;"> <span>DIV. _____</span> </div> <div style="font-size: x-small;">MEDICAL REC. NO.: _____</div>
-----------------------------	--

DIVISION OF NUCLEAR MEDICINE  
 BRAIN SPECT DATA SHEET

**INDICATIONS:**

( ) Localize epileptogenic focus

Underlying disorder? \_\_\_\_\_

Where is suspected focus? \_\_\_\_\_

Last seizure (date/time/describe): \_\_\_\_\_

\_\_\_\_\_

( ) Other reason: \_\_\_\_\_

**RADIOPHARMACEUTICAL AND DOSE SCHEDULE:**

Tc 99m ECD (NEUROLITE) Prescribed dose \_\_\_\_\_ mCi

NM Attending Physician: \_\_\_\_\_ M.D.

Prepared by: \_\_\_\_\_ CNMT

Time of Injection: \_\_\_\_\_ Patient Weight: \_\_\_\_\_ kgs

Injected by: \_\_\_\_\_ RN Patient Age: \_\_\_\_\_

Witnessed by: \_\_\_\_\_ RN

Problems with injection: Yes \_\_\_\_\_ No \_\_\_\_\_

Injection Site: \_\_\_\_\_

Hour:	Time:	Volume to inject:	Residual Volume:
0-1			
1-2			
2-3			
3-4			
4-5			
5-6			

\*greater than 6 hour, do not use, send back to NM

Radiopharmaceutical and associated materials given to NM: Yes \_\_\_\_\_ No \_\_\_\_\_

Picked up by: \_\_\_\_\_ CNMT or MD

Released by: \_\_\_\_\_ RN

Area Monitoring done by: \_\_\_\_\_ CNMT

FIGURE 1. Physician's order form.

## RESULTS

There were no problems associated with training of the nursing staff or with the subsequent administration of  $^{99m}\text{Tc}$ -bicisate. Furthermore, no radiation safety problems, such as contamination, were encountered.

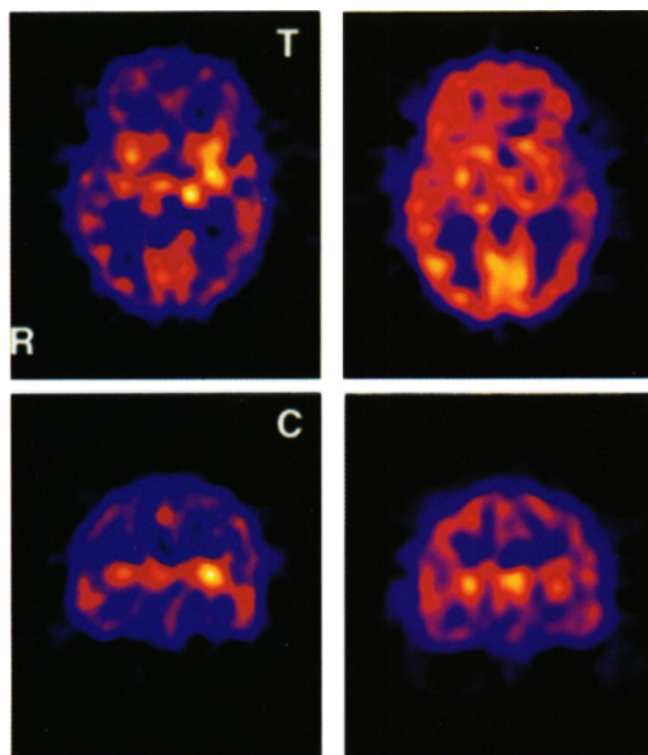
This multidisciplinary approach allowed EEG-confirmed ictal SPECT to be performed in 30 patients during the period of this study. These studies demonstrated focal increase in rCBF in regions of the brain probably associated with epileptogenic activity (Fig. 2). An ictal study was obtained on essentially every patient who experienced a seizure during the period that the dose was present at the patient's bedside. Of the patients in whom ictal SPECT was not obtained, the primary reason was the patient did not experience any EEG-documented seizures during the 6-hr shelf-life of the radiopharmaceutical. There were no cases in which ictal SPECT was not obtained due to unavailability of the radiopharmaceutical.

## CONCLUSION

Multidisciplinary cooperation and training made it possible to obtain EEG-documented ictal SPECT in the majority of

patients with medically refractory epilepsy who were enrolled in the long-term monitoring program at Children's Hospital. This approach eliminated the need to have a nuclear medicine technologist stationed at the patient's bedside awaiting a seizure. The 6-hr shelf life of  $^{99m}\text{Tc}$ -bicisate provided a reasonable period of time in which to inject the tracer during an actual ictal event. After our study was completed a more stable form of  $^{99m}\text{Tc}$ -HMPAO (Ceretek®, Medi-Physics, Inc., Amersham Healthcare, Arlington Heights, IL) with a 4-hr shelf-life became commercially available. Although the new  $^{99m}\text{Tc}$ -HMPAO formulation can be used to inject patients during seizures it has a shorter shelf-life than  $^{99m}\text{Tc}$ -bicisate (shelf-life 6 hr). Therefore, the window of opportunity to capture an ictal event is greater with  $^{99m}\text{Tc}$ -bicisate than with  $^{99m}\text{Tc}$ -HMPAO. There were six cases where ictal SPECT was not successful because of an absence of seizures during the time the tracer was available. Although it was still not possible to obtain an ictal study in every patient, this protocol removes a major obstacle to obtaining these studies.

The availability of ictal SPECT increases the chance that the seizure focus can be identified in patients with refractory



## ICTAL

## INTERICTAL

**FIGURE 2.** Ictal and interictal perfusion brain SPECT. The studies are from a 15-yr old boy with a longstanding seizure disorder presenting with mostly right-sided motor seizures. Selected slices of an ictal SPECT demonstrating intense focal hyperperfusion in the medial portion of the left temporal lobe and adjacent basal ganglia (left). Interictal SPECT shows diffuse hypoperfusion of the entire left cerebral hemisphere (R: right; C: coronal; T: transverse) (right).

epilepsy. In our experience, perfusion abnormalities were observed in more than 90% of the ictal SPECTs, while only approximately 50% demonstrated abnormal rCBF on interictal SPECTs (2). Improved localization of perfusion abnormalities, associated with seizure foci in patients with refractory epilepsy, should be helpful in managing these patients and, when indicated, in planning their neurosurgery.

## ACKNOWLEDGMENTS

The authors thank the staff of the Division of Nuclear Medicine and the Neuroscience Unit at Children's Hospital for their assistance. The kits used for preparation of  $^{99m}\text{Tc}$ -bicisate were supplied by DuPont Merck Pharmaceuticals, North Billerica, MA. This paper was presented in part at the 41st Annual Meeting of the Society of Nuclear Medicine in Orlando, FL in 1994.

## REFERENCES

1. Devous MD Sr, Leroy RF, Homan RW. Single-photon emission computed tomography in epilepsy. *Sem Nucl Med* 1990;20:325-341.
2. Packard AB, Roach P, Davis RT, et al. Ictal and interictal  $^{99m}\text{Tc}$ -bicisate brain SPECT in children with refractory epilepsy. *J Nucl Med*; in press.
3. Davis RT, Farley JA, Bjornson B, et al. A multidisciplinary method for obtaining ictal and interictal perfusion brain SPECT in pediatric patients with intractable epilepsy [Abstract]. *J Nucl Med Technol* 1994;22:112.
4. Harvey AS, Bowe JM, Hopkins IJ, et al. Ictal  $^{99m}\text{Tc}$ -HMPAO single-photon emission computed tomography in children with temporal lobe epilepsy. *Epilepsia* 1993;34:869-877.
5. Harvey AS, Hopkins IJ, Bowe JM, et al. Frontal lobe epilepsy: clinical seizure characteristics and localization with ictal  $^{99m}\text{Tc}$ -HMPAO SPECT. *Neurology* 1993;43:1966-1980.
6. Newton MR, Austin MC, Chan JG, et al. Ictal SPECT using  $^{99m}\text{Tc}$ -HMPAO: methods for rapid preparation and optimal deployment of tracer during spontaneous seizures. *J Nucl Med* 1993;34:666-670.
7. Grunwald F, Menzel C, Pavics L, et al. Ictal and interictal brain SPECT imaging in epilepsy using  $^{99m}\text{Tc}$ -ECD. *J Nucl Med* 1994;35:1896-1901.
8. Marks DA, Katz A, Hoffer P, et al. Localization of extratemporal epileptic foci during ictal single-photon emission computed tomography. *Annals of Neurology* 1992;31:250-255.
9. Leveille J, Demonceau G, De Roo M, et al. Characterization of  $^{99m}\text{Tc}$ -L,L-ECD for brain perfusion imaging, part 2: biodistribution and brain imaging in humans. *J Nucl Med* 1989;30:1902-1910.
10. Walovitch RC, Hill TC, Garrity ST, et al. Characterization of  $^{99m}\text{Tc}$ -L,L-ECD for brain perfusion imaging, part 1: pharmacology of  $^{99m}\text{Tc}$ -ECD in nonhuman primates. *J Nucl Med* 1989;30:1892-901.
11. Burrows P. Pediatric sedation for nuclear medicine procedures. In: Treves ST, ed. *Pediatric nuclear medicine*, 2nd ed. New York, NY: Springer-Verlag; 1995:12-16.
12. Habboush H, Mitchell KD, Mulkern RV, et al. Registration and alignment of three-dimensional images: an interactive visual approach. *Radiology* 1996; 199:573-578.



## **Ictal Perfusion Brain SPECT in Pediatric Patients with Intractable Epilepsy: A Multidisciplinary Approach**

Royal T. Davis, S. Ted Treves, Alan B. Packard, Judith B. Farley, Ronald K. Amoling and James S. Ulanski

*J. Nucl. Med. Technol.* 1996;24:219-222.

---

This article and updated information are available at:  
<http://tech.snmjournals.org/content/24/3/219>

---

Information about reproducing figures, tables, or other portions of this article can be found online at:  
<http://tech.snmjournals.org/site/misc/permission.xhtml>

Information about subscriptions to JNMT can be found at:  
<http://tech.snmjournals.org/site/subscriptions/online.xhtml>

*Journal of Nuclear Medicine Technology* is published quarterly.  
SNMMI | Society of Nuclear Medicine and Molecular Imaging  
1850 Samuel Morse Drive, Reston, VA 20190.  
(Print ISSN: 0091-4916, Online ISSN: 1535-5675)

© Copyright 1996 SNMMI; all rights reserved.