

## **Pyogenic Granuloma mimicking Peripheral Ossifying Fibroma: A Case Report**

**Devang M. Mistry\***, Aanal D Mistry, Ankit H Shah and Mrugank M Bhavsar

*Ahmedabad Dental College and Hospital, India*

### **\*Correspondence Info:**

Dr. Devang Manojkumar Mistry

Ahmedabad Dental College and Hospital, India

E-mail: [drdevdentalcare@gmail.com](mailto:drdevdentalcare@gmail.com)

### **Abstract**

Peripheral ossifying fibroma “a gingival nodule which is composed of a cellular fibroblastic connective tissue stroma which is associated with the formation of randomly dispersed foci of mineralised products, which consists of bone, cementum-like tissue, or a dystrophic calcification. The lesion is considered part of an ossifying fibroma, but that is usually considered to be a gnathic tumor. Pyogenic granuloma (also known as a “Eruptive hemangioma”, “Granulation tissue-type hemangioma”, “Granuloma gravidarum”, “Lobular capillary hemangioma”, “Pregnancy tumor” and “Tumor of pregnancy” is a vascular lesion that occurs on both mucosa and skin, and appears as an overgrowth of tissue due to irritation, physical trauma or hormonal factors. It is often found to involve the gums, the skin and nasal septum, and has also been found far from the head such as in the thigh. This article highlights a peculiar case presentation about both one lesion mimicked the other and how the diagnosis was finally made by ruling out one lesion.

**Keywords:** Differential diagnosis, Histological features, Pyogenic Granuloma, Peripheral ossifying fibroma, Periodontal ligament.

### **1. Introduction**

Fibrous growths of the oral soft tissues are fairly common and include a diverse group of reactive and neoplastic conditions. One such growth is pyogenic granuloma & peripheral ossifying fibroma. Pyogenic granuloma is a solitary, slow growing, sessile nodular mass most commonly seen on maxillary anterior gingival with female predilection. Peripheral ossifying fibroma is typically a solitary, slow growing, sessile or pedunculated nodular reactive gingival lesion that is believed to arise from the cells of periodontal ligament and periosteum. It occurs in the second decade of life and more common in females. It is more common in maxilla than mandible and anterior than posterior region.

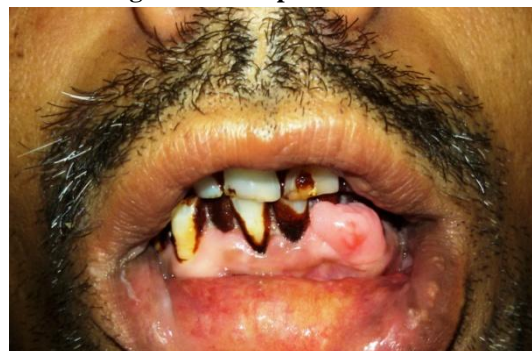
Treatment includes excision down to periosteum to eliminate any local irritants and care must be taken to maintain or re-establish acceptable gingival architecture and periodontal integrity. In this article we present a case report of pyogenic granuloma mimicking peripheral ossifying fibroma.

### **2. Case Report**

A 40 years old male patient, a local resident from Ahmedabad, reported to the department of oral

pathology and microbiology with the chief complaint of gingival growth in the lower anterior region (Figure 1). The patient gave the history of noticing this growth in the gingiva of mandibular anterior tooth region 8 months back. The growth was initially small in size, progressing gradually to attain the present size. The growth was asymptomatic not interfering in any function but bled on brushing the teeth. It was not associated with teeth tenderness or teeth mobility. He gave a history of similar growth occurring at the same site twice before which he got excised in a hospital 2 years and 1 year back respectively. No history of similar growth occurring elsewhere in the oral cavity.

**Figure 1: Pre operative lesion**



## 2.1 Past medical & drug history

No history of systemic disease or infection. No history of any chronic drug use or any drug allergy as well.

### 2.1.1 Dental history

Visited before for extraction of teeth with uneventful healing.

### 2.1.2 Family history

No history of familial, contagious, hereditary disease.

## 2.2 Local examination

Lymph nodes were not palpable. T.M.J examination revealed no abnormality.

### 2.2.1 Examination of the swelling

Extraorally no obvious swelling or gross asymmetry noticed.

### 2.2.2 Intra oral Examination of Soft Tissues

Intraorally a solitary proliferative growth was noticed on the lower labial gingiva i.r.t 32,33. The growth is sessile, fan shaped, erythematous except for the superior most part which is pink, measuring approximately 2.5 cms in its greatest extension. On palpation the growth appeared sessile (no stalk), nontender, soft to firm, bled on provocation and was mobile over the fixed base. There was no mobility of associated tooth noticed. Gingiva appeared generalized erythematous, firm and resilient, scalloped with rounded margins with partial loss of stippling and did not bleed on probing. Also noticed were local deposits of plaque and calculus.

### 2.2.3 Intra oral examination hard tissue

The teeth 46 and 36 are decayed.

## 2.3 Provisional diagnosis: Pyogenic granuloma.

### 2.3.1 Differential diagnosis

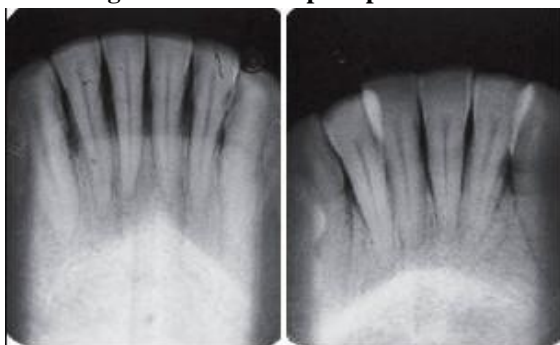- 1)Peripheral ossifying fibroma
- 2)Peripheral giant cell granuloma
- 3)Puberty gingivitis.
- 4)Epulis granulomatosa
- 5)Inflammatory Fibrous Hyperplasia

## 2.4 Investigations

### 2.4.1 Radiographic

IOPA radiograph (Figure 2) I.R.T the tooth 32, 33 revealed normal tooth and its supporting structures with no changes in the periodontium and the periapical region of the tooth.

**Figure 2: Intraoral periapical view**



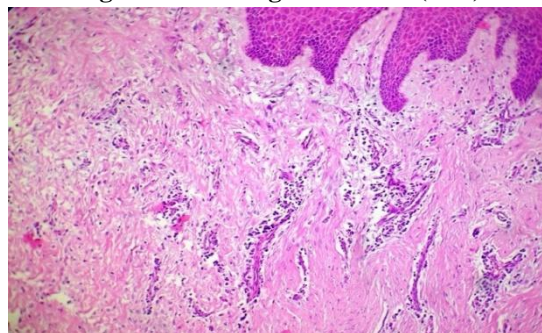
### 2.4.2 Immediate treatment

Excisional biopsy of the lesion was performed.

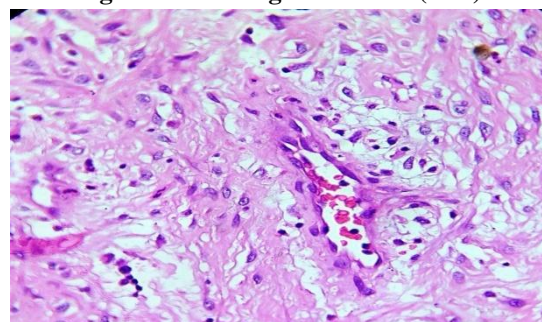
### 2.4.3 Histopathological examination

Submitted section (Figure 3 and 4) shows Parakeratinized stratified squamous epithelium and connective tissue. Few areas show hyperplastic epithelium. Connective tissue appears to be granulation which is composed of proliferating endothelial cells along with small and large RBC's filled blood vessels. Connective tissue also shows budding capillaries and proliferating fibroblasts. Mild chronic inflammatory infiltrate is also seen.

**Figure 3: Histological Section (10X)**



**Figure 4: Histological Section (40X)**



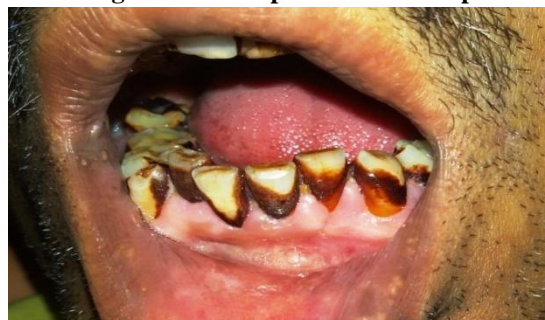**Suggestive of:** Pyogenic granuloma.

## 4.5 Confirmed clinical diagnosis: Pyogenic granuloma.

### 2.6 Follow up

Patient reported back after one month for follow up procedure (Figure 5). Wound healed completely and there were no associated symptoms. He was followed up for 6 months to assure no signs or symptoms of recurrence.

**Figure 5: Post-operative follow up**



### 3. Conclusion

Due to their clinical and histopathological similarities, it is thought that some peripheral ossifying fibromas develop as a pyogenic granuloma, which undergoes fibrous maturation and then ossification. These lesions are often mistaken and removed by superficial incision. It is important to remove lesion completely in order to reduce recurrences, by including subjacent periosteum and periodontal ligament besides their possible causes.

### References

- [1] Eversole LR, Rovin S. Reactive lesions of the gingiva. *J Oral Pathol* 1972; 1:30-8.
- [2] Neville BW, Damm DD, Allen CM, Bouquot JE. Oral and Maxillofacial Pathology. Philadelphia: Saunders, 1995: 374-6.
- [3] Buchner A, Hansen LS. The histomorphologic spectrum of peripheral ossifying fibroma. *Oral Surg Oral Med Oral Pathol* 1989; 63(4):452-61.
- [4] Zhang W, Chen Y, An Z, Geng N, Bao D. Reactive gingival lesions; a retrospective study of 2,439 cases. *Quintessence Int* 2007; 38(2):103-10.
- [5] Shivakumarashankari et.al; Peripheral ossifying fibroma mimicking pyogenic granuloma-A case report. *AJPP* 2014; 1(1):001-006.
- [6] Poon CK, Kwan PC, Chao SY. Giant peripheral ossifying fibroma of the maxilla; report of a case. *J Oral Maxillofac Surg* 1995; 53:695-8.
- [7] Bodner L, Dayan D. Growth Potential of Peripheral ossifying fibroma. *J Clin Periodontol* 1987; 14:551-554.
- [8] Miller CS, Henry RG, Damm DD. Proliferative mass found in gingival. *J Am Dent Assoc* 1990; 121:559-60.
- [9] Carrera GI, Berini AL, Escoda CG. Peripheral ossifying fibroma. Report of a case and review of literature. *Med Oral* 2001; 6:135-41.