

## **Spontaneous Infarction of Fibroadenoma of Breast- A Clinical and Cytohistopathological Study of Three Cases with Brief Review of Literature**

**Radha M<sup>\*</sup>**, Srinivasa Murthy V, Geethamala K and BR Vani

*Department of Pathology, ESIC Medical College and PGIMSR, Rajajinagar, Bangalore, India*

### **\*Correspondence Info:**

Dr. Radha M,  
Post graduate,  
Department of Pathology,  
ESIC Medical College and PGIMSR, Rajajinagar, Bangalore, India  
E-mail: [suni.radha@gmail.com](mailto:suni.radha@gmail.com)

### **Abstract**

Fibroadenoma is the most commonly diagnosed benign tumour in adolescents and young women. It constitute 20 % of all benign breast tumours. Spontaneous infarction in fibroadenoma is rarely seen. We report three such cases of spontaneous infarction of fibroadenoma over varied age groups which posed us with diagnostic dilemma at our every step. The possibility of this entity should be considered while diagnosing the breast lumps.

**Keywords:** Breast, Fibroadenoma, Infarction

### **1. Introduction**

Fibroadenoma is a benign tumour arising from the epithelium and stroma of the terminal duct lobular unit. Secondary changes include hyalinization, calcification, ossification, myxoid and apocrine squamous metaplasia.[1] Infarction is a very rare complication; which occurs during pregnancy, lactation, after fine needle aspiration procedure or trauma. The entity poses a diagnostic dilemma of inflammatory lesions and inflammatory carcinoma breast due to their similarities in clinical manifestation and cytological features.[2]-[4] Herein we report three such cases which posed clinical and diagnostic difficulty and our experience resolving them

### **2. Case report**

#### **2.1 Case 1**

A 20 year unmarried lady presented to surgical outpatient department (OPD) with one month history of painful lump in the left breast, which was gradually increasing in size. On examination there was a tender, ill-defined mass in the left upper and outer quadrant of the breast measuring 4.5X4 cm. The mass was firm on

palpation with redness of skin. There was no history of fever, trauma or prior fine needle aspiration procedure. Nipple discharge, retraction or axillary lymphadenopathy was not seen. Other breast was normal. Clinical diagnosis of acute- mastitis of the breast was considered and patient was started with antibiotics. After a week, patient showed no resolution of symptoms and hence FNA was suggested. Fine needle aspiration of the lump showed extensive areas of haemorrhage, necrosis; few clusters of atypical cells and occasion inflammatory cells. Exact opinion could not be given on FNAC and hence excision biopsy of the lump for histopathological examination (HPE) was suggested. Prior preoperative investigations were within normal limits. Day care surgery with excision of lump was performed. On macroscopic examination of excised lump, the specimen was found to be an encapsulated grey-white mass measuring 4X3.5X3 cms. Cut surface showed a grey-brown area measuring 2X2 cms with small cystic areas and extensive haemorrhage.

On microscopic examination of Haematoxylin and eosin(H&E) stained sections

showed extensive areas of haemorrhage and ischemic necrosis in central area with surrounding cellular fibroblastic stroma enclosing glandular and cystic spaces lined by flattened epithelium. The periphery showed retained outlines of the intralobular pattern along with congested small vessels and areas of haemorrhage. No inflammatory cells or cellular atypia were evident. Histological diagnosis of spontaneous subtotal infarction of fibroadenoma of the left breast was made. Patient remained stable till date.

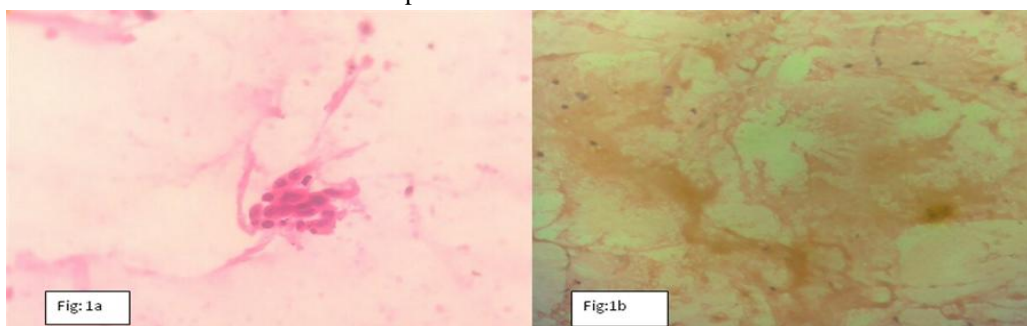
## 2.2 Case 2

22 year female herring from rural area presented to surgical OPD with one month history of painful right breast lump. She neither had a history of pregnancy, lactation nor trauma. Clinical diagnosis of fibroadenoma was made and suggested FNA. Patient underwent FNAC which on repeated aspiration yielded only haemorrhagic material and scant necrosis. No opinion was possible hence asked for excision and HPE for confirmation. Histopathology revealed encapsulated tumour with extensive areas of haemorrhage and ischaemic necrosis. A tiny area of ghost architecture of intracanalicular epithelial

pattern and stromal tissue was noted. No inflammatory cells or cellular atypia was seen. Histological diagnosis of fibroadenoma with total infarction of the breast was made. Patient was lost on follow up.

## 2.3 Case 3

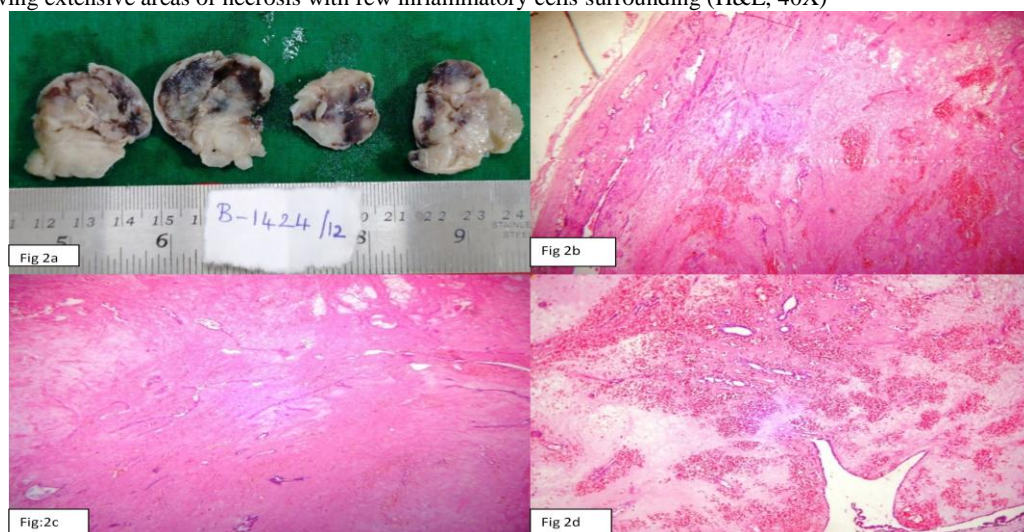
41 year female, home maker presented to surgical OPD with left breast lump with sudden increase in size. On examination irregular lump measuring 4x3 cm and firm to hard in consistency, was found. The other breast was normal. Axillary lymphnodes were not palpable. The clinical diagnosis of carcinoma breast was made and FNA was asked. On FNA, cytology showed few atypical ductal cells and large areas of haemorrhage. A diagnosis of suspicious for carcinoma was reported considering the clinical and age factors. Excision biopsy was asked for HPE confirmation. HPE revealed extensive areas of haemorrhage and focal granulation tissue with surrounding cellular fibroblastic stroma enclosing glands. No inflammatory cells or cellular atypia were evident. Histological diagnosis of spontaneous subtotal infarction of fibroadenoma left breast was made. Patient is stable till date.



**Figure 1: Cytology picture of 1<sup>st</sup> case**

1a: Cluster of atypical cells (H&E, 40X)

1b: Showing extensive areas of necrosis with few inflammatory cells surrounding (H&E, 40X)



**Figure 2: a-Gross cut surface of grey white nodular mass showing a gray-brown area measuring 2x2 cm with tiny cyst and extensive areas of haemorrhage  
b,c,d: H&E section showing extensive areas of hemorrhagic infarction with few viable intracanalicular and pericanalicular ducts at the periphery (4x)**

### 3. Discussion

Fibroadenomas (FAs) are the most common benign tumor of the female breast constituting approximately one-third of all benign breast lesions. They can occur in women of any age, but the peak incidence is seen in second and third decade of life.[1] Spontaneous infarction within fibroadenoma is a rare complication of benign breast tumour. It constitutes the most characteristic example of necrosis of the breast tissue.[2][4]

Delaure and Redon in 1949 were the first to describe spontaneous infarction in fibroadenoma lumps in young females[5]. Infarction within a fibroadenoma of the breast is an uncommon entity, noted in 0.5% to 1.5% of all cases including those seen in pregnant and lactating women[2][5]. In the present study 3 cases of infarction were reported among 373 cases of fibroadenoma over a period of three years accounting to 0.9% which is similar to the other studies.

The most frequent clinical manifestation is a painful breast lump; other presentations which draw the patient attention are lump with irregular margins, fixity to underlying structures, skin tethering, nipple discharge and axillary lymphadenopathy. These features lead to the clinical misdiagnosis of an inflammatory or a neoplastic lesion.[6][9] Similar to the present study, wherein all the three cases presented with painful breast lump and one case was clinically diagnosed as acute mastitis and other as carcinoma breast.

Many authors have put forward the possible theories behind the pathogenesis of infarction of breast like the trauma caused during needling (FNAC) procedure which in turn leading on to thrombosis of vessels and hence infarction. These kinds of post FNAC infarction are also noted in other organs like thyroid, lymphnodes and salivary glands[3][4]. Spontaneous infarction within fibroadenoma occurs frequently during third trimester of pregnancy and lactation. The possible explanation being, during these physiological conditions there may be relative ischemia in hyperplastic tumor tissue. Few authors have hypothesized the possibility of mechanical factors, that fibroadenoma being a mobile tumor undergoing torsion and ischemia.

Also some vascular lesion leading on to the formation of thrombosis may also result in infarction of fibroadenoma. There are some conditions of the breast that can be complicated by infarction, such as intraductal papilloma, phylloides tumor, and sporadic cases occurring in patients who are on anticoagulant drugs.[6][10] In spite of these hypotheses the etiology for infarction remains to be a mystery. In the present

study too, all the three cases had no inciting insults which may result in infarction hence diagnosed as spontaneous infarction.

The commonest investigation followed for breast lumps is FNAC[6][12]. The predominant cytopathological features of infarction in a fibroadenoma are plenty of singly scattered round to oval cells which do not possess any atypical features, many ghost-like epithelial cells in a necrotic background. To the authors' knowledge, extensive search revealed, all cases of spontaneous infarction of fibroadenoma have been misdiagnosed either as carcinoma breast or an inflammation lesion like abscess/mastitis. The necrosis commonly seen in these conditions differ by presence of abundant neutrophils in mastitis.[13]

In malignancy, a confirmed diagnosis should be given only when necrosis and also viable cells with prominent nuclear atypia, nuclear irregularities, prominent nucleoli and mitosis are seen. If in cases of suspicion, guarded report with suggestion of re-aspiration or needle biopsy is a must.[6][12] Another commonest inflammatory lesion is tuberculous granulomatous mastitis in our country but its differentiation is possible by the presence of epithelioid cell granulomas, multinucleated giant cells, lymphocytes and ZN stain of AFB positivity help in successful diagnosis.[6]-[8],[11]-[14]

Other commonest differential being duct ectasia, but clinical presentation of subareolar cord like mass helps in the correct diagnosis.[6][8],[11][12][15] In the present study too, one of the case showed only necrosis and other case revealed few atypical cells which compelled to diagnose as suspicious carcinoma breast. Hence diligent and conscientious search for the viable tissue is required to rule out other differentials and for the confirmed diagnosis of infarction of fibroadenoma[6][8][11][12][15].

Histopathological examination is the confirmatory investigation for infarction of fibroadenoma which shows abundant areas of ischemic necrosis, haemorrhagic areas with partial or no retain of the architecture of the fibroadenoma. There should be no inflammatory cells or atypical cells. In the present study too, two of the cases were diagnosed with subtotal and a single case of total spontaneous infarction of breast was made. Treatment by local excision is adequate for this lesion and under no circumstances should mastectomy be performed without histological proof of malignancy[2]-[4],[6]-[8],[11],[12]

#### 4. Conclusion

We reported three cases over varied age groups who had no etiologic factors aiding infarction; hence they were diagnosed as spontaneous infarction in a fibroadenoma of the breast. It is an uncommon complication within fibroadenoma and poses diagnostic dilemma at every step, hence diligent search and possibility of this entity is a must during the diagnosis of breast lump.

#### References

- [1] Tavassoli FA: Pathology of the Breast, 2<sup>nd</sup> ed. New York, NY, McGraw Hill, 1999, p 571–9.
- [2] Kuo YL, Hsieh CB, Harn HJ, Yu JC, Chen CJ, Liu YC. Spontaneous Infarction of fibroadenoma in a young non-pregnant woman. *J Med Sci* 2001; 21(2):97-100.
- [3] Majmudar B, Rosales-Quintana S. Infarction of breast fibroadenomas during pregnancy. *JAMA*. 1975; 231:963-4.
- [4] Raju GC, Narayansingh V. Infarction of fibroadenoma of the breast. *Journal of the Royal College of Surgeons of Edinburgh* June 1985; 30(3):162-63.
- [5] Delarue J, Redon H. Myocardial fibro-adenoma breast; clinical problem and pathogenesis. *Sem Hop* 1949; 25:2991-6.
- [6] Wadhwa N, Joshi R, Mangal N, Khan NP, Joshi M. Cytopathologic diagnosis of spontaneous infarction of fibroadenoma of the breast. *Turkish Journal of pathology* 2014; 30(3):237-40.
- [7] Kavdia R, Kini U. WCAFTI: Worrisome cytologic alterations following tissue infarction; a mimicker of malignancy in breast cytology. *Diagn Cytopathol*. 2008; 36:586-8.
- [8] Deshpande KM, Deshpande AH, Raut WK, Lele VR, Bobhate SK. Diagnostic difficulties in spontaneous infarction of a fibroadenoma in an adolescent: Case report. *Diagn Cytopathol* 2002; 26:26-8.
- [9] Sabate JM, Clotet M, Torrubia S, Gomez A, Guerrero R, de lasHeras P, Lerma E. Radiologic evaluation of breast disorders related to pregnancy and lactation. *Radiographics*. 2007; 27 Suppl 1: S101-24.
- [10] Toy H, Esen HH, Sonmez FC, Kucukkartallar T. Spontaneous infarction in a fibroadenoma of the breast. *Breast Care (Basel)*.2011; 6:54-55.
- [11] Kamra HT, Gadgil PA, Chaware SA, Kolhe AB, Sakinlawar PW. Cytological correlation of early changes in spontaneously infarcted fibroadenoma-a rare case report. *ecancer* 2012; 6:257.
- [12] Walke V, Ramraje S, Jadhao V, Gupta S. Spontaneous infarction in fibroadenoma, a diagnostic challenge on cytology: Report of two cases. *J Health Spec* 2014; 2:86-8.
- [13] Nemenqani D, Yaqoob N. Fine needle aspiration cytology of inflammatory breast lesions. *J Pak Med Assoc*. 2009; 59:167-70.
- [14] Fadaei-Araghi M, Geranpayeh L, Irani S, Matloob R, KurakiS. Breast tuberculosis: Report of eight cases. *Arch Iran Med*. 2008; 11:463-5.
- [15] Javadzadeh B, Finley J, Williams HJ. Fine needle aspiration cytology of mammary duct ectasia: Report of a case with novel cytologic and immunocytochemical findings. *Acta Cytol*. 2001; 45:1027-31.