

## Research Article

# Study on accessory thenar branches of median nerve in hand: its surgical importance in carpal tunnel syndrome

Raviprasanna K. H<sup>1</sup> and Poornima.G.C<sup>2</sup>

<sup>1</sup>Department of Anatomy, Sree Narayana Institute of Medical Sciences, North Kuthiathode, Chalakka, Ernakulam, Kerala.

<sup>2</sup>Department of Anatomy, Mysore Medical College and Research Institute, Mysore, Karnataka.

### \*Correspondence Info:

Dr. Raviprasanna K. H

Assistant Professor,

Department of Anatomy,

Sree Narayana Institute of Medical Sciences,

North Kuthiathode, Chalakka, Ernakulam, Kerala-683594.

E-mail: [pravi\\_kh81@yahoo.in](mailto:pravi_kh81@yahoo.in)

Phone no- +919496752619

Fax No- 91484-2478093.

### Abstract

**Introduction:** Median nerve enters the palm through the carpal tunnel deep to flexor retinaculum of wrist. The median nerve gives off recurrent motor branch (thenar) just distal to flexor retinaculum to innervate thenar muscles of the hand.

**Objective:** In present study the objective was to study the presence of accessory thenar branches and their side of origin.

**Materials and Methods:** The study included 51 human cadaver hands at the Department of Anatomy, Mysore Medical College & Research Institute, Mysore during 2011-13. These specimens fixed in 10% formalin were finely dissected and variations were noted.

**Results:** Out of 51 specimens, accessory thenar branches were present in 26 specimens (51%) i.e. 12 on right (23.5%) and 14 (27.45%) on left. Level of origin was observed within the retinaculum in 5 specimens (9.8%) on right and 2 specimens (3.9%) on left, distal to retinaculum in 7 specimens (13.7%) on right and 12 specimens (23.5%) on left side. Accessory thenar branch was originating from 1<sup>st</sup> common digital nerve in 5 specimens (9.8%) on right and 1 specimen (1.96%) on left side, from radial proper digital nerve to thumb in 7 specimens (13.72%) on right, 13 specimens (25.49%) on left side.

**Conclusion:** Knowledge of branching patterns & unusual variations helps in proper treatment of disorders of the median nerve. The possibility of multiple thenar innervations must be considered by hand surgeons in preoperative evaluation to reduce the hazards of iatrogenic injury or postsurgical complications.

**Keywords:** Median nerve, Variations, Carpal tunnel, Thenar muscles, Accessory thenar branches.

## 1. Introduction

Anatomic variations of the median nerve are frequent and they are significant for wrist surgery particularly in the treatment of carpal tunnel syndrome. Median nerve enters the palm through the carpal tunnel deep to flexor retinaculum of wrist. Recurrent motor (thenar) branch originates at the distal border of the flexor retinaculum to innervate the thenar group of muscles namely abductor pollicis brevis, flexor pollicis brevis and opponens pollicis.<sup>1</sup> The recurrent motor branch is important as it supplies muscles which are important for grasping, holding, writing, threading needle, wielding a hammer and assessing quality of fabric.<sup>2</sup>

The normal hand function is the balance between the extrinsic and intrinsic muscles. Much of the importance of the hand is dependent on the action of the thumb. Functionally, the thumb is one half of the hand, which acts in the opposite direction to the fingers in grasping any object. The thumb mobility is under the control of long and short muscles. The long flexor tendons of the fingers provide the power of the grip, the short intrinsic muscles of the hand are responsible for adjusting the position and carrying out the finer skilled movements of the digits and specialized motion.<sup>3</sup> The presence of accessory thenar branches is of great importance for hand surgeons in order to maintain the thenar muscle innervation for adequate functions of the whole hand. The present study aims at making the following observations in the specimens, to note the accessory thenar branches of median nerve and its level of origin with respect to flexor retinaculum and site of origin.

## 2. Materials & Methods

The 51 human cadaver specimens were obtained from dissection hall, Department of Anatomy, Mysore Medical College & Research Institute, Mysore during time period of 2011-13. Out of 51 specimens, 26 were of right and 25 were of left side. These specimens were fixed in 10% formalin solution. We excluded those cadaver hands from our study which exhibited previous trauma to the upper limb, fractures, any kind of surgical procedures and pathologies. The dissection was performed as per the Cunningham's manual of practical anatomy.<sup>4</sup> the median nerve was identified in distal forearm between tendons of flexor carpi radialis & palmaris longus. Using blunt dissection accessory thenar branches were traced to their origin from median nerve. Each accessory thenar branch was traced to know the side of origin. The presence of accessory thenar branches and their site of origin were noted.

## 3. Results

Out of 51 specimens, accessory thenar branches were present in 26 specimens (51%) i.e. 12 on right (23.5%) and 14 (27.45%) on left (Table-1). Level of origin was observed within the retinaculum in 5 specimens (9.8%) on right and 2 specimens (3.9%) on left, distal to retinaculum in 7 specimens (13.7%) on right and 12 specimens (23.5%) on left side (Table-2 & Figure-1).

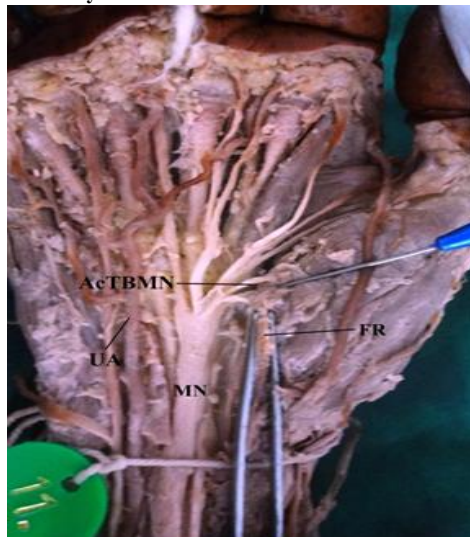
Accessory thenar branch was originating from 1<sup>st</sup> common digital nerve in 5 specimens (9.8%) on right and 1 specimen (1.96%) on left side, from radial proper digital nerve to thumb in 7 specimens (13.72%) on right, 13 specimens (25.49%) on left side (Table-3 & Figure-5).

**Table 1: Presence of accessory thenar branch of median nerve**

Presence of accessory thenar branch of median nerve	Right		Left	
	N	%	N	%
Present	12	23.52	14	27.45
Absent	14	27.45	11	21.56
Total	26	50.97	25	49.01

**Table 2: level of origin of accessory thenar branch of median nerve**

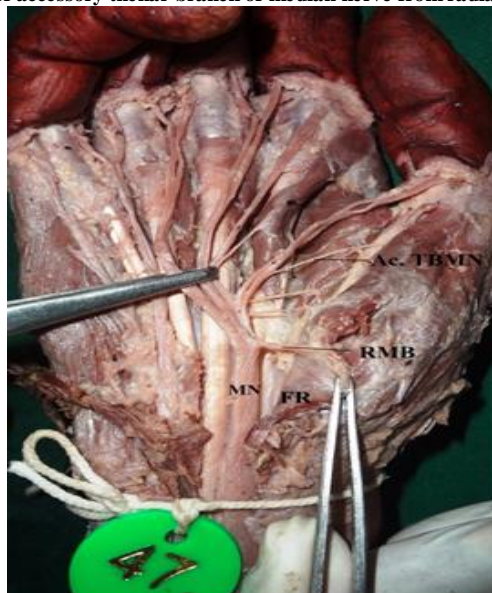
Level of origin of accessory thenar branch of median nerve	Right		Left	
	N	%	N	%
Proximal to flexor retinaculum	Nil	Nil	Nil	Nil
Within the retinaculum	05	9.8	02	3.9
Distal to retinaculum	07	13.7	12	23.5
Total	12	23.5	14	27.4

**Figure-1: Showing the accessory thenar branch of median nerve is within the flexor retinaculum**

MN- Median nerve, FR- Flexor retinaculum, Ac.TBMN- Accessory Thenar branch of Median Nerve, UA- Ulnar artery

**Table 3: Origin of accessory thenar branch of median nerve**

Origin of accessory thenar branch of median nerve	Right		Left	
	N	%	N	%
From the 1 <sup>st</sup> common digital nerve	05	9.8	01	1.96
From the radial proper digital nerve to thumb	07	13.72	13	25.49
Total	12	23.52	14	27.45

**Figure-2: Showing the origin of accessory thenar branch of median nerve from radial proper digital nerve to thumb**

Ac.TBMN- Accessory thenar branch of median nerve, MN- Median Nerve, FR- Flexor Retinaculum, RMB- Recurrent motor branch.

#### 4. Discussion

Presence of accessory thenar branch of median nerve was 7.5% (246 hands) by Lanz<sup>5</sup>, 31.7% (60 hands) by Alizadeh *et al.*<sup>6</sup>, 10.2% (354 hands) by Ahn *et al.*<sup>7</sup>, 8.3% (144 hands) by Mehmet *et al.*<sup>8</sup>, 7.8% (129 hands) by Imamura K<sup>9</sup>, 22.45% (147 hands) by Akio<sup>10</sup>, 34% (50 hands) by Vashistha<sup>11</sup> and 30% (50 hands) by Pushpalatha *et al.*<sup>2</sup> But the percentage is high in present study when compared to others. Knowledge of variable anatomy of the nerve could help to avoid incomplete decompression at operations for carpal tunnel entrapment and injury to the accessory thenar branch of median nerve.

The origin of accessory thenar branch of median nerve was originating proximal to retinaculum in studies done by Lanz<sup>5</sup> (1.62%) and Pushpalatha *et al.*<sup>2</sup> (20%), within retinaculum in studies done by Vashistha<sup>11</sup> (53.12%) and distal to retinaculum in studies done by Lanz<sup>5</sup> (7.3%), Pushpalatha *et al.*<sup>2</sup> (10%) and Vashistha<sup>11</sup> (46.87%). In present study the accessory thenar branch took origin from within the retinaculum in 13.7% and distal to retinaculum in 37.2%. This observation is similar to the study done by Vashistha<sup>11</sup>. Hence the accessory branches to the thenar muscles should be reviewed before undertaking any surgical procedure which will help the patient in getting effective treatment and avoids post-surgical complications.

Accessory thenar branches were originating from first common digital nerve in 40.62% in Vashistha<sup>11</sup>, 25% in Mumford *et al.*<sup>12</sup> and from radial proper digital nerve to thumb 5% in Pushpalatha *et al.*<sup>2</sup>, 59.37% in case of Vashistha<sup>11</sup>, and 50% in Mumford *et al.*<sup>12</sup> In the present study accessory thenar branches originated more from radial proper nerve to thumb than from common digital nerve which correlates with the study of Pushpalatha *et al.*<sup>2</sup>, Vashistha<sup>11</sup> and Mumford *et al.*<sup>12</sup> Knowledge of multiplicity of thenar branches would help in avoiding inadvertent injury and incomplete decompression during carpal tunnel release.

Lanz<sup>5</sup> U in 1977 studied on 246 hands in which the carpal tunnel was explored at operation, 29 variations in the course of median nerve were found. Accessory branches at the distal portion were found in 18 hands, a high division of the median nerve in seven, and accessory branches proximal to the tunnel in four. Based on these findings and including published reports of others, the variations were classified into 4 groups. Group I – variation in the course of recurrent motor branch of median nerve in 46%, Group II – presence of accessory branch in the distal part of carpal tunnel in 7.5% and proximal to retinaculum in 1.6%, Group III – high division or duplication of median nerve in 2.9%, and Group IV – accessory branch proximal to the carpal tunnel in 2.9%. The findings emphasize the importance of approaching the median nerve from the ulnar side when opening the carpal tunnel.

#### 5. Conclusion

Median nerve is called as labourer's nerve and its lesion or injury will cause physical disability affecting work ability of a person. Median nerve is often injured at wrist, accidentally or in an attempted suicide. In such cases, patient will be asked abduct or oppose the thumb against tight resistant, the thenar muscles can be felt to contract if the nerve is intact. Impairment of function affects not only employment but also a wide range of day today tasks like tying laces, putting up buttons and screwing the lids off jars.

Knowledge of branching patterns & unusual variations helps in proper treatment of disorders of the median nerve. The possibility of multiple thenar innervations must be considered by hand surgeons in preoperative evaluation to reduce the hazards of iatrogenic injury or postsurgical complications.

#### Reference

1. Standring S, Ellis H, Healy JC, Johnson D, Williams A, Collins P, *et al.* Fore arm and Hand. In: Gray's Anatomy – The anatomical basis of clinical practice. 40<sup>th</sup> ed. Edinburgh: Churchill Livingstone; 2005. pp. 895-7.
2. Pushpalatha M, Jayanthi KS. Accessory thenar branches of median nerve in hand. *Anatomica Karnataka*. 2007 May; 3(1):8-13.
3. Elsabee S, Mokhtar Z, Hassan A, Biram D. Anatomical study of the arterial and nerve supply of the thenar muscles. I-Nerve. New York, Oxford, Philadelphia, St Louis, Sydney, Toronto, 2005; 889-933.
4. Romanes GJ. The forearm & hand. In: Cunningham's Manual of Practical Anatomy. 15<sup>th</sup> ed. Oxford University Press, 1986.vol.1, p.740104.
5. Lanz U. Anatomical variations of the median nerve in the carpal tunnel. *J Hand Surg Am Jan* 1977; 2(1):44-53.
6. Alizadeh K, Lahiji F, Phalsaphy M. Safety of Carpal Tunnel Release with a short incision a cadaver study. *Acta Orthop Belg* 2006; 72:415-9.
7. Ahn DS, Yoon ES, Koo SH, Park SH. A prospective study of the anatomic variations of the median nerve in the carpal tunnel in Asians. *Ann Plast Surg* 2000; 44:282-7.
8. Alp M, Marur T, Akkin SM, Yalcin L, Demirci S. Ramification pattern of the thenar branch of the median nerve entering the thenar fascia and the distribution of the terminal branches in the thenar musculature. Anatomic Cadaver study in 144 hands. *Clin Anat* 2005; 18(3):195-9.
9. Imamura K. Anatomical variations of the recurrent branch of the median nerve. *J Orthop Traumatol* 2001; 50(1):170-3.
10. Akio M. Variations and Anomalies of the Branching of the Median Nerve Observed on Carpal Tunnel Release. *J. Jap Society Surg Hand* 1998; 15:452-6.
11. Vashistha. K. Variations of median nerve in carpal tunnel and its distribution in hand. *J Anat Soc India* 2011; 60(2):193-8.
12. Mumford J, Morecraft R, Blair W. Anatomy of the thenar branch of the median nerve. *Journal of Hand Surgery* 1987; 12A:361-5.