

## Research Article

# Evaluation of the relevance of touch imprint cytology in the diagnosis of neoplastic lesions of Breast

Saritha Karre<sup>1\*</sup>, Satyanarayana Veeragandham<sup>2</sup>, Raghu Kalahasti<sup>3</sup>, Mahjabeen Salma<sup>4</sup>, Deshpande Ashok Kumar<sup>5</sup> and Sikinder Hayath Mohammed<sup>6</sup>

<sup>1</sup>Assistant Professor, Kamineni Institute of Medical Sciences, Narketpally, Nalgonda.

<sup>2</sup>Head of Department, Department of Pathology, Kamineni Institute of Medical Sciences, Narketpally, Nalgonda.

<sup>3</sup>Associate Professor, Kamineni Institute of Medical Sciences, Narketpally, Nalgonda

<sup>4</sup>Consultant Pathologist, Yashoda Hospitals, Somajiguda, Hyderabad.

Associate Professor, Dr. VRK Women's Medical College, Aziznagar, Telangana.

<sup>5</sup>Associate Professor, Kamineni Institute of Medical Sciences, Narketpally, Nalgonda

<sup>6</sup>Head of Department, Department of Blood Transfusion, Kamineni Institute of Medical Sciences, Narketpally, Nalgonda

### \*Correspondence Info:

Dr. Saritha Karre,  
Assistant Professor,  
Department of Pathology,  
Kamineni Institute of Medical Sciences,  
Narketpally, Nalgonda.  
Email: [dr\\_saritha14@yahoo.co.in](mailto:dr_saritha14@yahoo.co.in)

### Abstract

Imprint cytology (IC) is an easy, quick and inexpensive diagnostic method. IC is an accurate and simple intra operative method for diagnosing breast lesions and also used for various lesions in the body. The present study aims at comparing the touch IC with histological diagnosis, evaluating the accuracy of IC in diagnosis of benign and malignant lesions of breast and to compare the validity of touch IC with Fine needle aspiration cytology (FNAC). This was a descriptive study done in collaboration with Department of General Surgery at Kamineni Institute of Medical Sciences (KIMS) hospital, Narketpally. Fifty cases of breast lesions were evaluated, comprising of benign & malignant lesions. Relevant clinical data were recorded in a proforma. Touch imprints were prepared from all the lesions and stained with rapid Haematoxylin & Eosin (H&E) and routine H&E stains. The imprints were subsequently compared with cytology and histopathology examinations. We observed better accuracy in IC (96%) than FNAC (89%) in correlation with histopathology, better sensitivity in IC (97.3%) than FNAC (93.3%) in correlated well with histopathology, better specificity in IC (92.3%) than FNAC (50%) in correlation with histopathology, Predictive value-97.29%, Negative predictive value-92.3%. All the imprints were well corroborated with FNAC & histopathological diagnosis. Thus, IC provides initial diagnosis to surgeons for immediate clinical and surgical intervention.

**Keywords:** imprint cytology, FNAC, histopathology, benign, malignant

## 1. Introduction

Breast lesions which are more common in the females have gained increasing importance and attained global attention because of increasing mortality and morbidity caused by breast cancer. Clinically, the patients present with a palpable mass, abnormalities in mammography and sometimes with sign of inflammation, nipple discharge<sup>1,2</sup>. Most of the conditions clinically mimic malignancy. Cytology is the study of the morphology of cells that exfoliate naturally and removed by artificial means. Most of the breast lesions including carcinoma are potentially curable, if diagnosed early. For early diagnosis, IC, FNAC and mammography are being used regularly. Some of the diagnostic procedures are preoperative done like mammography, ultrasound, FNA, core needle biopsy. Some diagnostic modalities are used intra operatively like frozen section technique and IC. The diagnosis is to be confirmed by histopathological examination<sup>3-10</sup>. The most important role of diagnostic cytology in the assessment of breast lesions is to make a decision between benign and malignant categories. Observation of normal and abnormal human cells, imprint and exfoliated cells were documented throughout the nineteenth century<sup>11</sup>. Procedures like FNA, core needle biopsy and imprints are useful in sampling of lesions whereas, the use of imaging modalities increases the visualization of lesions<sup>12</sup>.

Breast cytology is generally considered to be a part of initial assessment of breast lesions. It is also used as an adjunct to frozen section in paraffin section histology to assist in reaching a diagnosis<sup>13</sup>. Imprint cytology is a rapid and inexpensive diagnostic procedure which is being used for the diagnosis of lesions at various sites in the body<sup>8,9,10,14</sup>. This procedure has also been applied successfully on breast lesions. It is recommended to use touch preparations to achieve better results<sup>6,13-16</sup>. Cytological examination of surgical specimens has proved to be a valuable learning tool. The low percentages of false positive diagnosis suggest that a diagnosis of malignancy by the imprint method is reliable<sup>17</sup>. Intraoperative evaluation of IC can provide the surgeon with information for immediate clinical and surgical management<sup>18</sup>. Cytological examination of imprint or similar preparations is increasing in popularity among pathologists for intra-operative or peri-operative tissue assessment. Several reports in the literature discuss the use of IC in the evaluation of surgical specimens<sup>19</sup>. Although techniques have varied, it seems evident that many authors recognize the usefulness of such cytological study, when employed with appropriate caution, as an adjunct to gross examination and frozen section<sup>20</sup>. A recent report indicates that the accuracy of diagnosis by the IC method is from 94%-97%, almost same as that from the use of frozen section<sup>20</sup>. Imprint cytology has wide applicability in the rapid diagnosis of tumors of various body organs.

## 2. Material and Methods

This descriptive study on 50 breast neoplastic lesions was conducted at KIMS hospital in collaboration with surgical department to assess the accuracy of IC in breast lesions done in two years. Formalin fixed samples were excluded.

Relevant clinical data regarding age, history and examination was recorded in a proforma. The lesions were identified and cut intra-operatively. Excessive haemorrhagic fluid was washed away. Gross examination of the lesions was recorded. Imprint smears were prepared from the lesion. Imprints were obtained by gently pressing the clean dry glass slides against the cut surface of the lesion and allowed to dry, later fixed in isopropyl alcohol. Touch preparations were stained with rapid H & E. The imprints were examined by pathologists and then the results were informed to the surgeons. After surgery, the specimens were received in the pathology lab, after fixation for 24hrs in formalin grossing were carried out. An automatic tissue processor (Model RH-12 EP Sakura, Fine Technical Co. Ltd., Tokyo, Japan) was used for further processing of tissue blocks. About 17 hours was required for processing by this method. Different concentrations of ethyl alcohol were used for dehydration (70% alcohol for one hour x two changes, 90% alcohol for two hours x two changes and 100% alcohol for two hours x two changes). Clearing in two changes of xylene for one hour each was done. Tissues were impregnated in two changes of paraffin wax with a melting point of 56°C for a period of 3 hours. Embedding of the tissues was done in paraffin wax using L-shaped metallic moulds. These blocks were put in the refrigerator for a period of 4-6 hours. Each block was cut on a rotatory microtome. About 3-4 micro meter thick tissue sections were obtained and placed in a water bath with a temperature of 5°C below the melting point of paraffin wax. Cut ribbons of tissues were placed on albuminized glass slides. About 2-3 sections of the tissue were placed on each glass slide. All the sections and touched smears were stained with H & E.

### 2.1 Rapid haematoxylin & eosin staining procedure

(Adopted from Culling CFA, Dunn WL. Handbook of Histopathologic and Histochemical techniques. 3<sup>rd</sup> Edition page. 210)<sup>21</sup>

1. 95% Ethanol – 2 dips [30s]
2. Distilled water – 5 dips
3. Immersion with agitations – 2 minutes in Harris Haematoxylin.
4. Tap water – 3 dips.
5. Two dips in Lithium Carbonate Solution
6. 3 dips in tap water
7. 10 dips in 1% Eosin.
8. 95% alcohol- 2 changes 5 dips each.
9. Absolute alcohol – 2 changes 5 dips each.
10. Xylene – 2 changes 5 dips each.
11. Mount with DPX or Canada Balsam

Results: Nucleus-purple;cytoplasm-pink

The criteria of *Yiangou, et al* (1996) was for differentiating the benign and malignant breast lesions. The diagnostic classes were as C1–inadequate, C2-benign, C3-atypical probably benign, C4-suspicious probably malignant, C5-malignant<sup>7</sup>. Cytodiagnosis was correlated with histopathological diagnosis, using modified Bloom Richardson grading system<sup>22</sup>. Screening tests were applied. Sensitivity, specificity, positive predictive value, negative predictive value and accuracy of IC were calculated considering histopathology as gold standard.

## 3. Results

Out of 50 histopathological specimens, only 37 patients underwent FNAC procedure. Histopathological correlation was done in 37cases (there were twenty five benign and twelve malignant lesions). Fibroadenoma cases were from a younger age group. All were mobile, encapsulated and with well defined margins. The color was grey white on cut section and surface was nodular. Histologically, mixed patterns were noted. Imprints revealed cohesive clusters of ductal epithelial cells with finger-like projections. Many naked bipolar nuclei were seen. Mild atypia was present. Fibroadenoma with apocrine change was noted. One case of benign phylloides tumor was noted. This was firm in consistency. Microscopically, leaves-like stromal nodules covered by epithelium projecting into the space were noted. Imprints revealed increased number of spindle-shaped stromal cells.

Twelve malignant cases were studied including cases of infiltrating ductal cell carcinoma. 12 cases were found to be of grade II after applying modified Bloom Richardson grading system. Imprints were well correlated with histological diagnosis. All malignant cases were hard on palpation. No special drug history was noted. On cut section, all the lesions were hard with areas of fibrosis. Cut surface was grey white in all cases. Features like pleomorphism, hyperchromatism and mitosis were clearly discernable on touch imprint as well. Lymphocytes were also appreciated in imprints helping diagnosis of medullary carcinoma. Touch imprints were prepared from twenty five benign and twelve malignant lesions. Cytological diagnosis was divided into five classes from C1 to C5. Smears were adequate in all the cases. In benign cases, it was noted that number of cases with fibroadenoma was predominantly more with touch imprints. In malignant lesions, duct cell carcinoma was easily diagnosed by touch imprints. Cytological diagnosis remained the same with H&E. The cytological diagnosis was classified into three categories i.e. negative, suspicious and positive. For practical purposes, cases with suspicious for malignancy were considered, as positive while calculating the results by applying screening tests. (All the results are shown in Table 1-8and photomicrographs Fig 1-3).

**Table 1: Distribution of benign and malignant neoplastic lesions on histopathology**

Lesions	Number of cases	Percentage
Benign	35	70.00
Malignant	15	30.00
Total	50	100.00

**Table 2: Distribution of benign neoplastic lesions on touch imprint cytology**

Diagnosis	No. of cases	C1	C2	C3	C4	C5
Fibroadenoma	34 (97.15%)	0	30 (85.72%)	4 (11.43%)	0	0
Benign phyllodes tumor	1 (2.85%)	0	1 (2.85%)	0	0	0
Total	35 (100.00%)	0	31 (88.57%)	4 (11.43%)	0	0

Criteria of *Yiangou C. et al*<sup>7</sup> (C1-inadequate;C2-benign;C3-atypical probably benign;C4-suspicious probably malignant;C5-malignant)

**Table 3: Distribution of malignant neoplastic lesions on touch imprint cytology**

Diagnosis	No. of cases	C1	C2	C3	C4	C5
IDC	14 (93.34%)	0	0	0	0	14 (93.34%)
Medullary Carcinoma	1 (6.66%)	0	0	0	0	1 (6.66%)
Total	15 (100.00%)	0	0	0	0	15 (100.00%)

**Table 4: Comparison of imprint and histopathological diagnosis of neoplastic lesions**

Lesions	Imprint	Histopathology
Benign		
1.Fibroadenoma	34	30
2.Fibroadenoma with apocrine change		4
3.Phyllodes	1	1
Malignant		
1.IDC	14	14
2.Medullary carcinoma	1	1

**Table 5: Comparison of FNAC, Imprint and Histopathological diagnosis of benign neoplastic lesions**

Lesions	FNAC	Lesions	Imprint	Lesions	Histopathology
1.Fibroadenoma	12 (48%)	Fibroadenoma	10 (40%)	Fibroadenoma	10 (40%)
		Infiltrating duct cell carcinoma	1 (4%)	Infiltrating duct cell carcinoma	1 (4%)
		Phyllodes	1 (4%)	Phyllodes	1 (4%)
2.Fibroadenoma with atypia	5 (20%)	Fibroadenoma	4 (16%)	Fibroadenoma	4 (16%)
		Infiltrating duct cell carcinoma	1 (4%)	Infiltrating duct cell carcinoma	1 (4%)
3.Fibroadenoma with apocrine change	2 (8%)	Epitheliosis	1 (4%)	Fibroadenoma with epitheliosis	1 (4%)
		Fibroadenoma	1 (4%)	Fibroadenoma	1 (4%)
4.Fibroadenoma with cystic change	1 (4%)	Fibroadenoma	1 (4%)	Fibroadenoma	1 (4%)
5.Fibroadenoma with ductal epitheliosis	4 (16%)	Fibroadenoma	3 (12%)	Fibroadenoma	3 (12%)
		Fibroadenoma with focal ductal hyperplasia	1 (4%)	Fibroadenoma with focal ductal hyperplasia	1 (4%)
6.Fibroadenosis	1 (4%)	Fibroadenoma	1 (4%)	Fibroadenoma	1 (4%)
Total	25(100%)		25(100%)		25 (100%)

**Table 6: Comparison of FNAC, Imprint and Histopathological diagnosis of malignant neoplastic lesions**

Lesions	FNAC	Lesions	Imprint	Lesions	Histopathology
Duct cell carcinoma	10 (83.34%)	Infiltrating duct cell carcinoma	10 (83.34%)	Infiltrating duct cell carcinoma	10 (83.34%)
Infiltrating duct cell carcinoma	2 (16.66%)	Infiltrating duct cell carcinoma	2 (16.66%)	Infiltrating duct cell carcinoma	2 (16.66%)
Total	12 (100%)		12 (100%)		12 (100%)

**Table 7: Validity and Accuracy of Imprint cytology in diagnosis of neoplastic lesions of breast (Histopathological examination taken as gold standard)**

Imprint Cytology Test Results	Neoplastic lesions of breast based on histopathological diagnosis		Total
	Positive	Negative	
Test Positive	36	1	37 (74%)
Test Negative	1	12	13 (26%)
Total	37 (74%)	13 (26%)	100%)

Sensitivity=97.3%; Specificity =92.3%; Accuracy =96%; PPV =97.29%; NPV =92.3%

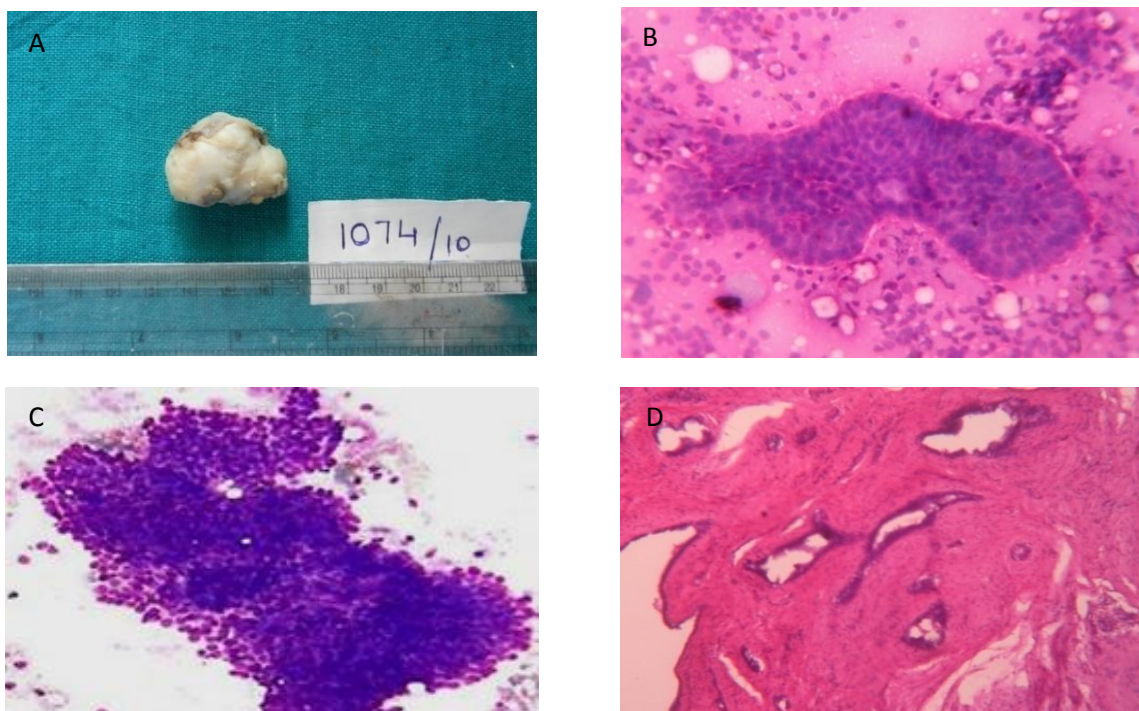
**Table 8: Validity and Accuracy of FNAC in diagnosis of neoplastic lesions of breast (Histopathological examination taken as gold standard)**

FNAC Test Results	Neoplastic lesions of breast based on histopathological diagnosis		Total
	Positive	Negative	
Test Positive	31	2	33 (89%)
Test Negative	2	2	4 (11%)
Total	33(89%)	4(11%)	37(100%)

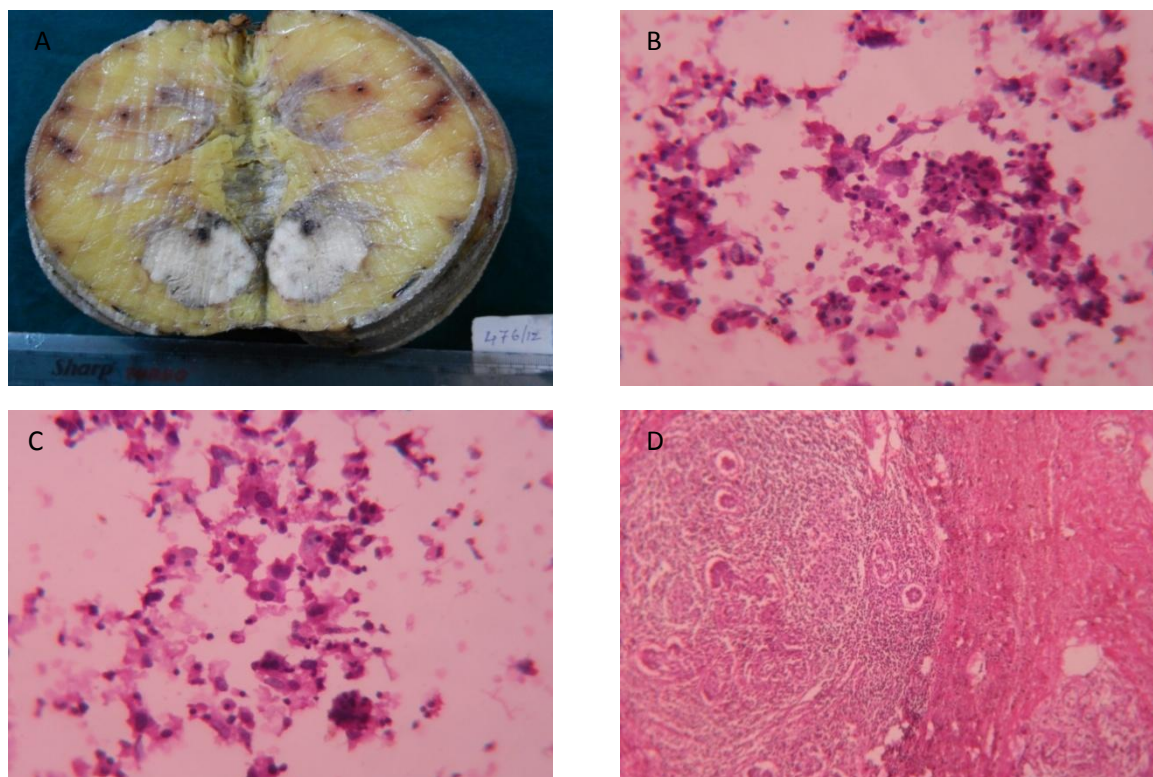
Sensitivity=93.3%; Specificity =50%; Accuracy =89%; PPV =93%; NPV =50%



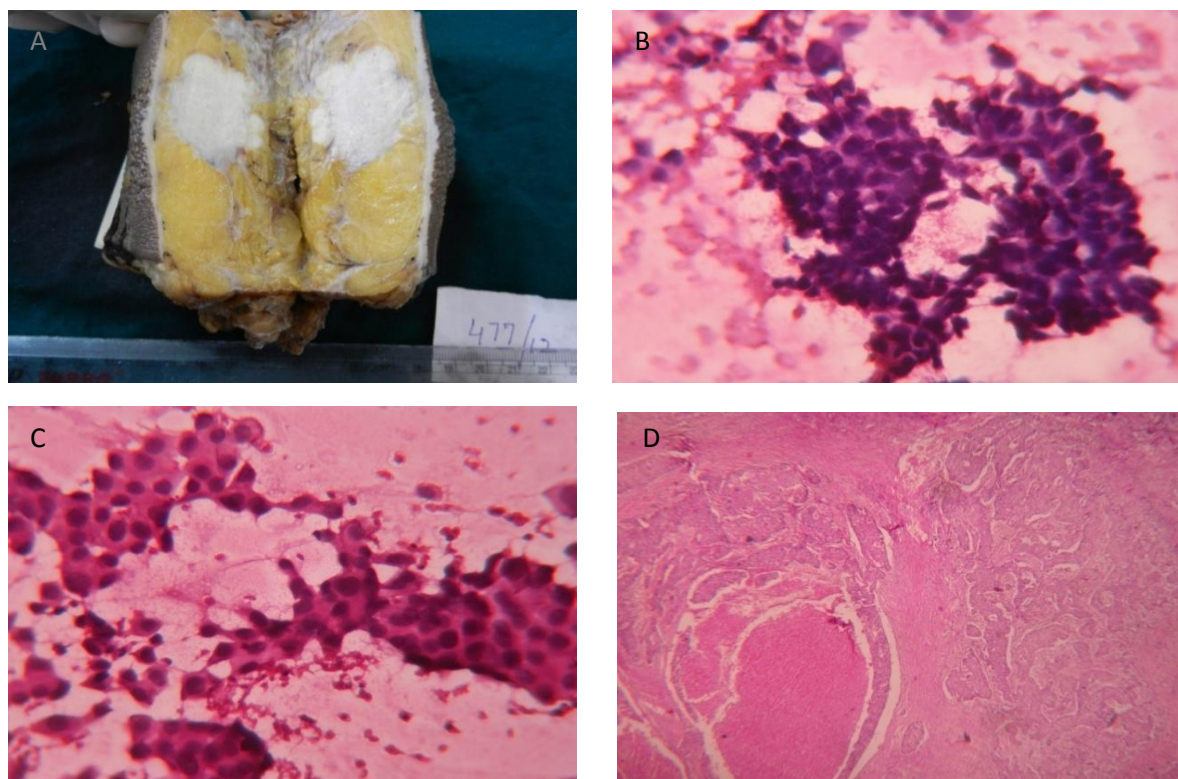
**Fig. 1:** A-Gross picture Fibroadenoma after surgery, B-Photomicrograph of touch imprint of Fibroadenoma (H&E, 10x) showing cohesive ductal epithelial cell cluster in bimodal pattern and bipolar stromal cells in background. C-FNAC shows dispersion of cells among tight sheets of epithelial cells (H&E, 40x). D-Histopathology shows ductal epithelial cells and stroma (H&E, 10x).



**Fig. 2:** A-Gross picture Carcinoma Breast after surgery. B-photomicrograph of touch imprint of medullary carcinoma (H&E, 40x) showing large number of lymphoid cells in between individual tumor cells. C-Touch imprints of medullary carcinoma: loose cluster of pleomorphic ductal epithelial cells (H&E, 40x). D-Histopathology shows tumor tissue with pushing margins and marked lymphocytic infiltrate (H&E, 10x).



**Fig. 3:** A-Gross picture Carcinoma Breast after surgery. B-photomicrograph of touch imprint of duct cell carcinoma (H&E, 40x) showing loose clusters of pleomorphic and hyperchromatic ductal epithelial cells. C-FNAC showing loose cluster of pleomorphic cells (H&E, 40x). D-histopathology shows ductal epithelial cells in comedo-pattern with tumor cells exhibiting vesicular nucleus, hyperchromasia, coarse chromatin and prominent nucleoli (H&E, 10x).



#### 4. Discussion

Imprint cytology is known since 1927. It was first reported by *Dudgeon & Patrick*<sup>23</sup>. But recently it has achieved recognition as an adjunct to frozen section for the intra-operative diagnosis. Intra-operative IC is practically easy, rapid & inexpensive.

The commonly encountered Fibroadenoma, Phylloides tumors, Infiltrating duct cell carcinomas are easy to diagnose by IC. *Suen et al*<sup>17</sup> has documented 95.8% diagnostic accuracy with 10% false negativity and no false positive cases among 473 breast lesions analysed for IC. *Veneti et al*<sup>18</sup> studied 351 breast lesions for IC with 98.31% accuracy, 97.1% sensitivity and 99.4% specificity. In our study, on IC no benign lesions were reported as malignant and none of the malignancies were scored as benign. Among the benign lesions, fibroadenoma cases predominated and in malignant lesions, duct cell carcinoma cases were higher in touch imprint cytology. As imprint preparation gives better cellularity, the results of our study were supported by the study conducted by *Veneti et al* and co workers as they recommended the same.

Rapid Imprint cytological examination of resected tissue has been shown to be a useful adjunct to the use of frozen section as well as an efficient alternate method for reporting fine-needle aspirates<sup>19</sup>. *Tung-Kwang Lee*<sup>20</sup> observed 88.7% with 7.8% false negativity and 3.4% false positivity among 115 cases of breast lesions analysed. *Hemalatha et al*<sup>24</sup> studied 799 breast lesions for IC with 96.7% accuracy and 3.25% false negativity. *Akhtar et al*<sup>25</sup> observed 78% specificity with 89% positive predictive value and 89% accuracy. *Singh et al*<sup>26</sup> studied 70 cases of Breast lumps. Imprints were stained with toluidine blue or rapid H&E staining & correlated imprint diagnosis with paraffin sections. They found the imprints cytodiagnosis as simple, reliable & quick method, in places where frozen section facilities are not available. Imprint cytodiagnosis when considered along with clinical findings & gross appearance of excised mass may give cent percent correct results.

In the present study 96% diagnostic accuracy is observed among 50 breast lesions with 2% false negativity and 2% false positivity, 97.3% sensitivity and 92.3% specificity was observed in diagnosing neoplasm of breast. 2% false negativity is due to epitheliosis on imprints which was diagnosed as malignant neoplasm on histopathology. Our analysis is correlated well with all the above mentioned studies.

In cases studied on lumpectomy margins, *Klimberg et al*<sup>27</sup> supported this method with sensitivity and specificity 100%. *Creager et al*<sup>27</sup> observed accuracy to be 85%. *Cox CE* and co-workers also have similar views<sup>29</sup>. In cases of early breast cancer, *Saarela et al*<sup>30</sup> did not suggest IC as a method of assessing lumpectomy margins. In re-excision specimens, for predicting residual cancer, they had a view that histological margins are the misleading factor. To minimize the risk of residual cancer, they suggested wide excision or mastectomy in the management of multifocal and non-palpable tumor. The present study has not taken lumpectomy margins into consideration.

In benign lesions, counseling and proper treatment plan is suggested to reduce patient anxiety, but this was not recommended by *March et al*<sup>31</sup>. IC did not provide information about depth of the infiltration but provides information about histological patterns of the tumor as observed by *Lee*<sup>32</sup>. We observed lymphocytes in case of medullary carcinoma which goes in the favor of conclusion put forth by *Lee*.

The evaluation of breast lesions in outpatient department by Core Needle Biopsy for IC is recommended as it is a single day procedure. As IC provides the surgeon with information regarding immediate surgical management, this is recommended.

#### 5. Conclusion

In the present study we observed better Accuracy in IC (96%) than FNAC (89%) in correlation with histopathology. Accordingly, the results show better Sensitivity in IC (97.3%) than FNAC (93.3%) in correlation with histopathology and better Specificity in IC (92.3%) than FNAC (50%) in correlation with histopathology with Positive predictive value - 97.29% and Negative predictive value - 92.3%. Therefore, IC is a easy, rapid, inexpensive and diagnostic procedure which is being used for the diagnosis of lesions of various sites in the body. IC is an accurate and simple intra-operative method for diagnosing breast lesions which provides prompt information about histological patterns of the tumors. Thus, IC provides initial diagnosis to surgeons for immediate clinical and surgical intervention. Therefore, IC is suggested to be a part of pathologist's repertoire.



## References

1. Lester SC. The breast. In: Kumar V, Abbas A K, Fausto N. Robbins and Cotran Pathologic basis of disease. 7<sup>th</sup> ed. Philadelphia: Saunders 2004; 1119-54.
2. Lakhana NK, Khalid F. Morphology of breast lumps: a retrospective study. *J Pak Inst Med Sci* 2002; 13: 631-34.
3. Mansoor I, Zahrani I. Analysis of inconclusive breast FNA by triple test. *J Pak Med Assoc* 2002; 52: 25-28.
4. Bedard YC, Pollet AF. Breast fine needle aspiration. *Am J Clin Pathol* 1999; 111: 523-27.
5. Scheiden R, Sand J, Tanous AM, Knolle U, Capesius C, Wagnon MCH, et al . Accuracy of frozen section diagnosis of breast lesions after introduction of a national programme in mammographic screening. *Histopathology* 2001; 39: 74-84.
6. Oneson RH, Minke AJ, Silverberg SG. Intraoperative pathologic consultation. *Am J Surg Pathol* 1989; 13: 237-43.
7. Yiangou C, Davis J, Liuni N, Barrett NK, Sinnott HD. Diagnostic role of cytology in screen detected breast cancer. *Br J Surg* 1996; 83: 816-19.
8. Rathil SL, Alam SM, Jamal Q. Touch imprints cytology of lymph nodes. *J Coll Physicians Surg Pak* 1997; 7: 203-04.
9. Shidham VB , Asma Z, Rao NR, Chavan A, Machhi J, Almagro U, et al. Intraoperative cytology increases the diagnostic accuracy of frozen sections of various tissues in the parathyroid region. *Am J Clin Pathol* 2002; 118: 895-902.
10. Ademiluyi SA, Akinyanju OO, Mordi VPN. Evaluation of lymph node imprints in rapid diagnosis of lymph node biopsy specimens. *J Clin Pathol* 1986; 39: 688-89.
11. Wied GC. Clinical Cytology: Past, present and future. *Beitr Oncol* 1990; 38: 1-58.
12. Naylor B, Ramzy I. Cytopathology: The past, the present and a glimpse into the new millennium. In: Gray W, Mckee GT. *Diagnostic cytopathology*. 2nd ed. Philadelphia: Churchill Livingstone 2003; 3-13.
13. Howat AJ, Williams RA. Combined scrape cytology and frozen section histology for rapid diagnosis in breast pathology. *Histopathology* 1990; 17: 85-96.
14. Helin HJ, Isola JJ, Helin MJ, Krohn KJE. Imprint cytology in: immunocytochemical analysis of oestrogen and progesterone receptors of breast carcinoma. *J Clin Pathol* 1989; 42: 1043-45.
15. Dutta SK, Chattopadhyaya A, Roy S. Evaluation of fine needle aspiration and imprint cytology in the early diagnosis of breast lesions with histopathological correlation. *J Indian Med Assoc* 2001; 99: 421-23.
16. Albert US, Duda V, Hadji P, Goerke K, Hild F, Bock K, et al. Imprint cytology of core needle biopsy specimens breast lesions . *Acta Cytol* 2000; 44: 57-62.
17. Suen KC, Wood WS, Syed AA, Quenville NF, Clement PB. Role of Imprint cytology in intraoperative diagnosis; value and limitations. *J of Clin Pathol* 1978; 31:328-37.
18. Smaragda V, Lydia LM, Helen T, John X, Panagiotis Anastasiadis. Imprint Cytology-A rapid reliable method of diagnosing breast malignancy. *Acta Cytologica* 1996;40:649-52.
19. Mark OR. Rapid cytologic examination of surgical specimens. *Hum. Pathol* 1984; 15(7):605-14.
20. Tung-Kwang Lee. The value of Imprint cytology in Tumor Diagnosis. *Acta Cytologica* 1982; 26(2):169-171.
21. Culling CFA: Handbook of Histopathological and Histochemical techniques, 3<sup>rd</sup> Ed. London: Butterworth & Co.Publishers;1974.
22. Dunne B, Going JJ. Scoring nuclear pleomorphism in breast cancer. *Histopathology* 2001; 39: 259-65.
23. Dudgeon LS, Patrick CV. A new method for rapid microscopical diagnosis of tumours, with an account of 200 cases so examined. *Br J Surg* 1927; 15: 250-61.
24. Hemalatha AL, Vidyakumari M, Rupashree S. Intraoperative imprint cytodiagnosis of breast lesions. A current prospective. *J of Cytology* 2005; 22(1): 23-27.
25. Akhtar ZM, Qureshi SA, Aziz. Evaluation of Accuracy of Intra Operative Imprint Cytology for Detection of Breast Lesions. *Annals of KEMU* 2010; 16(1): 47-53.
26. Singh Amarjit, BL Bagapal, Sukhdev, Anoop S. Evaluation of cytodiagnosis by Imprint method in Breast Tumours. *Indian J Pathol and Microbiol* 1982; 25: 29-33.
27. Klimberg VS, Westbrook KC, Korourian S. Use of touch preps for diagnosis and evaluation of surgical margins in breast cancer. *Ann Surg Oncol* 1998; 5: 220-26.
28. Creager AJ, Shaw JA, Young PR, Geisinger KR. Intra-operative evaluation of lumpectomy margins by imprint cytology with histologic correlation: a community hospital experience. *Arch Pathol Lab Med* 2002; 126: 846-48.
29. Cox CE, Pendas S, Ku NN, Reintgen DS, Greenberg JS, Nicosia SV. Local recurrence of breast cancer after cytological evaluation of lumpectomy margins. *Am Surg* 1998; 533-38.
30. Saarela AO, Paloneva TK, Rissanen TJ, Kiviniemi HO. Determinants of positive histologic margins and residual tumor after lumpectomy for early breast cancer: a prospective study with special reference to touch preparation cytology. *J Surg Oncol* 1997; 66: 248-53.
31. March DE, Walker MT, Bur M, Coughlin BF, Dziure B, Corenzane RR et al. Touch-preparation cytologic examination of breast core biopsy specimens: accuracy in predicting benign or malignant core histologic results. *Acad Radiol* 1999; 6: 333-38
32. Lee TK. The value of imprint cytology in tumor diagnosis: a retrospective study of 522 cases in northern China. *Acta Cytol* 1982; 26: 169-71.