

## Case Report

### **A unique presentation of parietal notch bone with coexisting multiple wormian bones and complete metopism**

AU Siddiqui<sup>\*1</sup>, Kusum Rajendra Gandhi<sup>2</sup> and Syed Rehan Hafiz Daimi<sup>3</sup>

<sup>1</sup>All India Institute of Medical Sciences(AIIMS), Raipur, Chhattisgarh, India-492099

<sup>2</sup>Rural Medical College of Pravara Institute of Medical Sciences, Loni, Maharashtra, India-413736

<sup>3</sup>College of Medicine, University of Dammam, Kingdom of Saudi Arabia

#### **\*Correspondence Info:**

Dr. AU Siddiqui

Assistant Professor

Department of Anatomy

All India Institute of Medical Sciences (AIIMS), Raipur, Chhattisgarh, India-492099

E-mail: [its\\_meesha@yahoo.com](mailto:its_meesha@yahoo.com)

#### **Abstract**

During routine osteology tutorials for the first year medical students, we came across this skull which presented with various noteworthy findings. In total, 13 sutural bones were observed in the skull, out of which 11 were located at the commonly described lambda. Out of these 11, five were seen on the right side and six were present on the left side. One sutural bone (coronal ossicle) was seen 3.5 cm above the pterion, on the left side of the coronal suture. But, a very rare sutural bone- the parietal notch bone was observed at the posterior aspect of the temporo-parietal suture. This bone was present between the squamous & mastoid parts of the temporal bone and the parietal bone. It was situated 2 cm anterior to the asterion. Another interesting co- finding on the same skull was the presence of a complete metopic suture, which extended from the bregma to the nasion. It was a typical dentate suture. The report bestows an important anatomical insight into the region and has potential relevance for the radiologists and the surgical interventionists working on the area.

**Keywords:** parietal notch bone, wormian bones, metopism, suture

#### **1. Introduction**

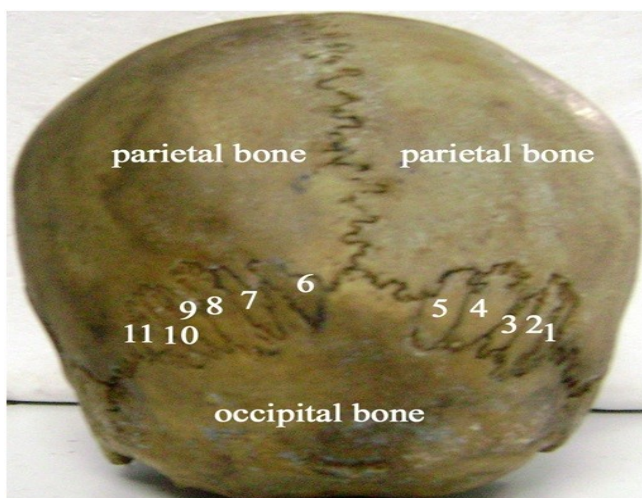
Wormian bones have been described as small irregular ossicles which are present within the cranial sutures and fontanelles. A vast majority of these wormian bones are located in the lambdoid suture (lambda). The second most common site of occurrence is the coronal suture. The first description of the intrasutural bones is attributed to Paracelsus. However, the name 'Wormian bone' is derived from Olaus Worm, a Danish anatomist who described them. Wormian bones are also called as ossa wormiana, intersutural bones and Inca bones/Goethe's ossicle<sup>1</sup>.

Metopic sutures are believed to represent the junctional union of the left and right halves of the frontal bone, extending from the nasion to the bregma. These sutures normally disappear by the age of 6 - 8 years. The term "metopism" is coined for the metopic suture persisting beyond this time. Studies have reported complete metopism extending from the nasion to the coronal suture; or to a point 2 cm anterior to it and incomplete metopic suture as one which may be present anywhere in the upper, middle or lower part of the frontal bone<sup>2</sup>. Metopic suture is many a times mistaken for frontal bone fracture in X ray of the skull<sup>3</sup>.

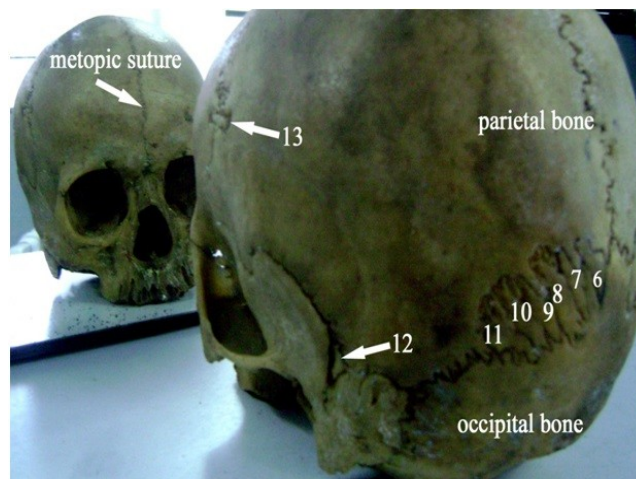
Various workers have reported the presence of wormian bones in skull and studied metopic sutures in detail. But a prominent bone (the parietal notch bone) at the posterior aspect of the temporo-parietal suture (on the left side) coexisting

with a number of lambdoid sutural bones and complete metopism has not been reported yet. Moreover, a distinct sutural bone (coronal ossicle) was also seen in the same skull 3.5 cm above the pterion, in the left side of the coronal suture (Figure 1 and 2).

**Figure 1- Showing 11 wormian bones around lambda (5 on the right and 6 on the left side)**



**Figure 2- Showing parietal notch bone (12) and coronal ossicle (13) along with left sided wormian bones (6 to 11). Also seen with the help of mirror is the complete metopic suture (metopism)**



## 2. Case Report

During routine osteology tutorials for the first year medical students, we came across this skull which presented with various interesting findings. In total, 13 sutural bones were observed in the skull out of which 11 were located at the commonly described lambdoid suture (photograph 1). Out of these 11, five were seen on the right side and six were present on the left side. One sutural bone (coronal ossicle) was seen 3.5 cm above the pterion, on the left side of the coronal suture (photograph 2, numbered 13). But, a very rare sutural bone- the parietal notch bone was observed at the posterior aspect of the temporo-parietal suture (photograph 2-numbered 12). This bone was present between the squamous & mastoid parts of the temporal bone and the parietal bone. It was situated 2 cm anterior to the asterion. Another noteworthy finding on the same skull was the presence of a complete metopic suture (photograph 2), which extended from the bregma to the nasion. It was a typical dentate suture.

## 3. Discussion

As evident from the vast pool of research publications pertaining to the wormian bones, the cause of formation of wormian bones has differed amongst various authors. Many causes have been proposed but none is universally accepted. Some of the commonly described causes include – racial features of certain populations (for eg- description of Inca bone in Peruvian population), consequences of skull deformation, an adaptation to cranial enlargement, metabolic disorders and the presence of autosomal dominant trait<sup>1</sup>.

Jeanty and Silva have quoted Dorsey (1897) who suggested that wormian bones developed as an inherent response to the stressful conditions linked to artificial cranial deformations. In 1965, Bennett suggested that wormian bones were a response to modification of the shape of the head (artificial deformation, short basiocciput length or hydrocephaly). Quoting Parker it was suggested that the number of wormian bones increases with the capacity of the skull, regardless of the cause of enlargement. A similar relationship exists with the total length of sutures: “*The greater the sutural length of a skull, the greater the number of wormian bones*”. He suggests that sutural diastasis induces the formation of ectopic ossification centres. In 1946, Hess proposed that the formation of wormian bones could result from metabolic disorders of the mesoderm and he noted that they also correlated with asymmetry of the skull, bone malformations (occiput, sphenoid), metopism and congenital abnormalities of the central nervous system<sup>1</sup>.

Das *et al* (2005) have quoted Berry reporting the incidence of metopism to be 7-10% in Europeans, 4-5% in Asians, 1% in Africans, 1% in Australians and 4.4-5.5% in Indians. The worldwide incidence of metopism has been

reported to vary between 0-7.4 percent in different groups. Complete metopism may be associated with brachycephaly or dolichocephaly. Moreover it is also reported along with complete absence of frontal sinus, presence of sutural bones, abnormally prominent external occipital protuberance and the occurrence of serrated sutures<sup>2</sup>.

Bilodi *et al* (2003) described the presence of complete metopic sutures in two skulls (out of 51), that extended from nasion to bregma in the midline<sup>3</sup>. Ajmani *et al* (1983) in their study on metopic sutures found a complete metopic suture in seven out of 206 Nigerian skulls (3.4%).<sup>4</sup> Das *et al* reported an incidence of metopism in 3.31% of the 1087 skulls analyzed<sup>5</sup>.

Berry, 1967 analyzed 585 skulls of different races and reported the occurrence of parietal notch bone, coronal ossicle and metopism. The parietal notch is that part of the parietal bone that protrudes between the squamous and mastoid parts of the temporal bone. It may present as a separate ossicle which is termed as the parietal notch bone. The parietal notch bone was present in 7.4% of Egyptian, 6.2% of Nigerian, 2.8% of Palestinian, 7.5% of Indian, 7.8% of Burmese, 10% of North American and 11.3% of South American skulls. Moreover, the coronal ossicle was seen in 2.6% of Egyptian, 3.7% of Palestinian, 1.9% of Indian, 1% in Burmese and 1.9% of South American. The North American skulls had a very high incidence of coronal ossicle (32%), whereas none of the Nigerian skulls reported a coronal ossicle<sup>6</sup>.

Gray's Anatomy mentions that additional ossification centers occur in or near sutures, giving rise to isolated sutural bones (wormian bones). Sutural bones appear in great number in hydrocephalic skulls and have therefore been linked with rapid cranial expansion<sup>7</sup>.

Wilczak and Ousley (2009) suggest that biomechanical forces which are associated with cultural cranial deformation have a tendency to influence the formation of sutural ossicles<sup>8</sup>. O'Loughlin (2004) has hypothesized that wormian bones which were located in posteriorly placed sutures are affected much more by various environmental factors than their anteriorly placed counterparts. Likewise, wormian bones present in the anterior sutures probably are under stronger genetic control<sup>9</sup>. Haniharai and Ishida (2001) gave a hypothesis that apart from mechanical factors, a particular genetic drift and the structure of the population could be the underlying cause for the variations seen at interregional level, thus causing varied incidences of the accessory ossicles<sup>10</sup>.

The presence of parietal notch bone coexisting with a complete metopic suture makes this case unique. Moreover this skull also showed 11 sutural bones at the lambda and one at the coronal suture (coronal ossicle). The occurrence of a sutural bone at this site becomes immensely important to the radiologists, neurosurgeons and ENT specialists. Nonetheless, the presence of a complete metopic suture have a noteworthy role to play in forensic and anthropological studies as it is often confused with fractures or even with sagittal suture. The conglomeration of findings reported in this case might prove as a harbinger for the clinicians to approach the described areas with a meticulous approach.

## References

1. Jeanty P, Silva SR, Turner C. Prenatal diagnosis of wormian bones. *J Ultrasound Med*.2000; 19:863-869.
2. Das S, Suri R, Kapur V. Anatomical observations on osinca and associated cranial deformities. *Folia Morphol*. 2005; 64(2): 118-121.
3. Bilodi AK, Agrawal BK, Mane S, Kumar A. A study of metopic sutures in human skulls. *Kathmandu Univ Med J*.2003; 2(2):96-99.
4. Ajmani ML, Mittal RK, Jain SP. Incidence of the metopic suture in adult Nigerian skulls. *J Anat*.1983; 137:177-183.
5. Das AC, Saxena RC, Beg MAQ. Incidence of metopic sutures in UP subjects. *J Anat Soc India*.1973; 22(3): 140-143.
6. Berry AC, Berry RJ. Epigenetic variation in the human cranium. *J Anat*.1967; 101(2): 361-379.
7. Standring S. *Gray's Anatomy*.40<sup>th</sup> ed. Churchill Livingstone.2008; p 418.
8. Wilczak CA, Ousley SD. Test of the relationship between sutural ossicles and cultural cranial deformation: results from Hawikuh, New Mexico. *Am J Phys Anthropol*. 2009; 139: 483-493.
9. O'Loughlin VD. Effects of different kinds of cranial deformation on the incidence of wormian bones. *Am J Phys Anthropol*. 2004; 123:146-155.
10. Hanihara T, Ishida H. Frequency variations of discrete cranial traits in major human populations. I. Supernumerary ossicle variations. *J Anat*. 2001; 198(6):689-706.