

Case Report

A case of ocular tuberculosis presenting as papillophlebitis

Hossein Mughaddasifar¹, Alireza Ramezani^{1*}, Homayoon Nikkhah¹, Bahram Nasri Razin²¹ Ophthalmic Research Center, Department of Ophthalmology, School of Medicine, Imam Hossein Medical Center, Shahid Beheshti University of Medical Sciences, Tehran, Iran.² Department of Infectious Disease, School of Medicine, Imam Hossein Medical Center, Shahid Beheshti University of Medical Sciences, Tehran, Iran.

Abstract

A 35-year-old lady presented with a history of decreased vision in her right eye from one week before her referral. She did not report any significant systemic disease. Ocular findings were compatible with the diagnosis of central retinal vein occlusion. Systemic laboratory tests were all within normal limits except for Mantoux test (PPD) which was positive, 18 mm induration and 2+ redness. Chest radiography was negative for lung tuberculosis. Fluorescein angiography confirmed the presence of retinal vasculitis. With a probable diagnosis of papillophlebitis secondary to tuberculosis, the patient received a course of anti-tuberculosis medications. The inflammation subsided and vision improved within a 6-months therapy. This was a rare case of presumed ocular tuberculosis with no evidence of systemic infection presenting first as a papillophlebitis.

Key Words: Ocular tuberculosis, Central retinal vein occlusion, Mantoux test, Papillophlebitis.

***Corresponding Author:** Alireza Ramezani, MD. Ophthalmic Research Center, Labbafinejad Medical Centre, Boostan 9 Ave., Pasdaran St. Tehran 16666, Iran. Tel: +98 21 22584733; Fax: +98 21 22562138. Email: arramezani@gmail.com.

Please cite this article as: Mughaddasifar H, Ramezani A, Nikkhah H, Nasri Razin B. A case of ocular tuberculosis presenting as papillophlebitis. *Novel Biomed* 2013;1(3):88-91.

Introduction

Non-ischemic central retinal vein occlusion (CRVO) is characterized by good visual acuity, a mild afferent pupillary defect, and mild visual field changes. Fundoscopy shows mild dilation and tortuosity of all branches of the central retinal vein as well as dot and flame hemorrhages in all quadrants of the retina. Macular edema with decreased visual acuity and mild optic disc swelling may or may not be present.^{1, 2} If disc edema is prominent in younger patients, a combined inflammatory and occlusive mechanism may be present that has been termed papillophlebitis.^{2, 3} It is a condition usually affecting otherwise healthy young adults between 20 and 50 years old and usually

affecting otherwise healthy adults that are younger than typical CRVO cases.⁴

Occurrence of CRVO in a young patient warrants extensive investigation to look for an underlying cause.¹ Retinal vasculitis is one possible underlying pathology.² Ocular tuberculosis presenting first as CRVO is rare. It usually manifests as a granulomatous uveitis.⁵ First presentation of CRVO attributed to tuberculosis is also rare. To the best of our knowledge, there are only 3 reported cases of CRVO associated with tuberculosis in the literature. Two cases were associated with^{6, 7} and one⁸ without underlying pulmonary tuberculosis. In this case report, we intend to report a patient with papillophlebitis mostly secondary to tuberculosis without an underlying pulmonary infection.

Case report

A 35-year-old woman presented to our clinic with a one-week history of sudden and painless blurring vision in her right eye. She did not complain of any systemic ailment and her past medical and family history was negative for any specific disease. Corrected visual acuity was 20/80 and 20/20 in her right and left eyes, respectively. Right relative afferent pupillary defect was slightly present. Anterior segment examination was unremarkable in both eyes. Intraocular pressure was 12 mmHg in both eyes. There was a mild anterior vitritis in the right eye. Right eye funduscopy showed retinal hemorrhages, cotton wool spots, and venous engorgement and dilation in all quadrants as well as swollen optic disc (Figure 1). The left fundus was normal. Clinical diagnosis of non-ischemic CRVO presenting as a papillophlebitis in the right eye of the patient was confirmed also by fluorescein angiography (Figure 2 and 3). Another ancillary ophthalmic test was optical coherence tomography which demonstrated no significant macular thickening (Figure 4).

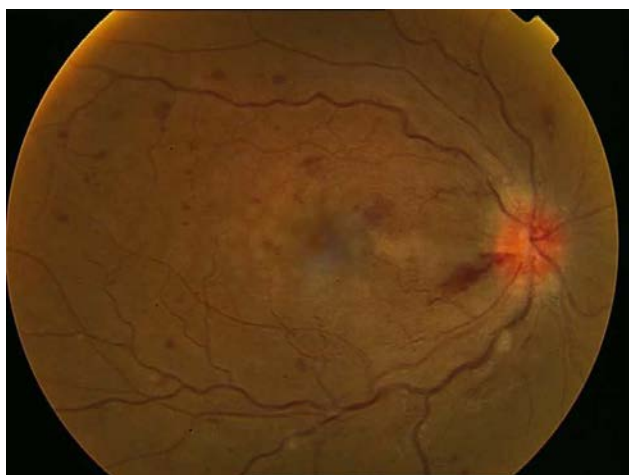

Figure 1: Fundus photograph of the right eye.

Blood investigations including blood cell count, venereal disease research laboratory (VDRL), collagen vascular screen and coagulation profile (hemocystein, antithrombin III activity, and protein C and protein S activity, and IgG anticardiolipin) were normal. The erythrocyte sedimentation rate (ESR) was 11 mm/1st hour. Chest radiography was normal. The Mantoux (or PPD, purified protein derivative) test was positive with 18 mm induration and 2+ redness.

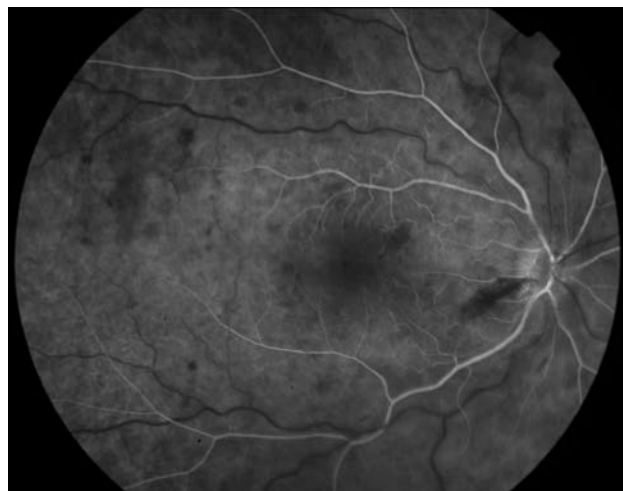

Figure 2: Fluorescein angiography of the right eye, early phase.

A thorough systemic evaluation by infection service of the hospital did not demonstrate any organ involvement with tuberculosis. With the diagnosis of ocular tuberculosis, the patient was given an anti-tuberculosis treatment which consisted of an intensive phase with ethambutol (1 g/day), isoniazid (300mg/day), rifampicin (600 mg/day) and pyrazinamide (1.5 g/day) for 2 months followed by maintenance therapy of isoniazid and ethambutol for 4 months. For 4 weeks after initiation of treatment, fundus abnormalities resolved and vision improved to 20/30.

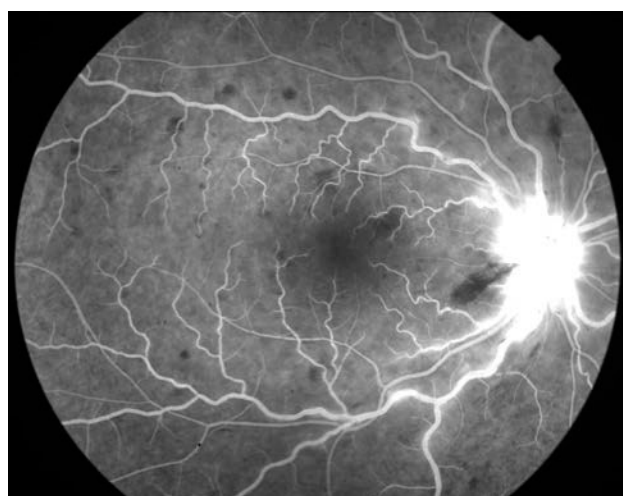


Figure 3: Fluorescein angiography of the right eye, mid phase.

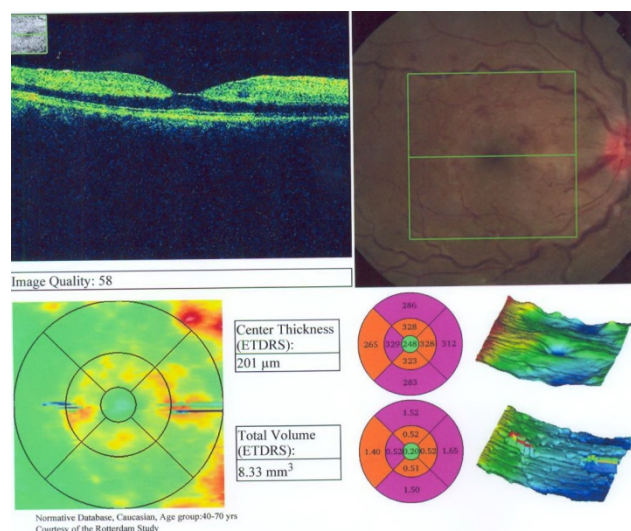


Figure 4: Linear macular OCT of the right eye.

Discussion

Here in, we reported a case with PPD-positive ocular tuberculosis with no sign of a systemic infection presenting first as papillophlebitis. Her right fundus findings were compatible to the reported ophthalmoscopic appearance of papillophlebitis, i.e. unilateral optic disc edema, venous dilatation and variable amounts of hemorrhage on the disc and peripapillary region.

Ocular tuberculosis usually manifests as a granulomatous uveitis. There are always signs of uveitis in cases with retinal vasculitis associated with tuberculosis.⁵ A first presentation of CRVO attributed to tuberculosis is rare. There have only been 2 reported cases of CRVO associated with pulmonary tuberculosis^{6, 7} and one case with no systemic tuberculosis.⁸ Muiz Mahyudin et al reported a case with PCR-positive ocular tuberculosis presenting first as a CRVO in a patient with no signs of a systemic infection and negative CXR and PPD test.⁸ In our case similarly, CXR was negative for tuberculosis and there was no sign of systemic tuberculosis; however, PPD was positive. Due to the good visual acuity of the patient, vitreous tap and PCR analysis was not performed. Since vitreous tap is an invasive procedure, it should be reserved for cases where the involved eye shows worsening of the signs with the use of corticosteroids.⁸

Young patients presenting with CRVO require extensive investigations to rule out any underlying conditions such as hemocystinemia, collagen vascular disorders and blood coagulopathies.⁹ In a study by Gupta et al.¹⁰ on CRVO patients, aged below 40 years, 5 out of 8 patients with ischemic CRVO had an underlying systemic problem.

There is a worldwide resurgence of tuberculosis infection.¹¹ According to Kremer and Besra,¹² approximately one third of the world's population is infected with *M. tuberculosis* and despite the availability of effective chemotherapy, 3.5 million tuberculosis deaths occur each year. In view of this trend, it is perhaps not adequate to stop further tests to confirm presence of a tuberculosis infection when routine tests were normal.

TB can cause a wide variety of ophthalmic findings, ranging from the ocular surface through the optic nerve and central nervous system pathology.¹³ Definite diagnosis of TB requires a finding of mycobacteria in body fluids or tissues. In many cases of ocular TB however, this is not possible and the diagnosis is instead based on indirect evidence.^{13, 14} The positive result of Mantoux test indicates prior exposure to TB but not necessarily an active systemic infection. Failure to demonstrate systemic disease does not exclude the possibility of intraocular infection. In some cases, cultures are negative but a clinical diagnosis of tuberculosis is supported by consistent epidemiologic evidence (history of close contact with an infectious patient), a positive PPD, and a compatible clinical response to treatment.¹⁴ In our case, good response to anti-tuberculosis treatment may be indicative of ocular tuberculosis. Nonetheless, as vitreous tap and PCR examination were not performed, this diagnosis was not absolute.

In this report, we presented a case with papillophlebitis mostly secondary to tuberculosis infection with no other systemic involvement. This report may emphasize the importance of systemic work-up in young patients coming with CRVO. Furthermore, although papillophlebitis is a relatively benign condition, the differential diagnoses include a number of sight-threatening and potentially life threatening disorders which need to be excluded by medical assessment before the ultimate diagnosis is reached..

References

1. Walters RF, Spalton DJ. Central retinal vein occlusion in people aged 40 years or less: a review of 17 patients. *Br J Ophthalmol* 1990;74(1):30-5.
2. Hayreh SS. Optic disc vasculitis. *Br J Ophthalmol* 1972;56(9):652-70.
3. Lonn LI, Hoyt WF. Papillophlebitis: a cause of protracted yet benign optic disc edema. *Eye Ear Nose Throat Mon* 1966;45(10):62 passim.
4. Beaumont PE, Kang HK. Clinical characteristics of retinal venous occlusions occurring at different sites. *Br J Ophthalmol* 2002;86(5):572-80.
5. Tabbara KF. Tuberculosis. *Curr Opin Ophthalmol* 2007;18(6):493-501.
6. Fullerton DG, Shrivastava A, Munavvar M, Jain S, Howells J, Macdowall P. Pulmonary tuberculosis presenting with central retinal vein occlusion. *Br J Ophthalmol* 2007;91(12):1714-5.
7. Fountain JA, Werner RB. Tuberculous retinal vasculitis. *Retina* 1984;4(1):48-50.
8. Mahyudin M, Choo MM, Ramli NM, Omar SS. Ocular Tuberculosis Initially Presenting as Central Retinal Vein Occlusion. *Case Rep Ophthalmol* 2010;1(1):30-5.
9. Lahey JM, Tunc M, Kearney J, Modlinski B, Koo H, Johnson RN, et al. Laboratory evaluation of hypercoagulable states in patients with central retinal vein occlusion who are less than 56 years of age. *Ophthalmology* 2002;109(1):126-31.
10. Gupta A, Agarwal A, Bansal RK, Chugh KS. Ischaemic central retinal vein occlusion in the young. *Eye (Lond)* 1993;7 (Pt 1):138-42.
11. Vermund SH, Yamamoto N. Co-infection with human immunodeficiency virus and tuberculosis in Asia. *Tuberculosis (Edinb)* 2007;87 Suppl 1:S18-25.
12. Kremer L, Besra GS. Re-emergence of tuberculosis: strategies and treatment. *Expert Opin Investig Drugs* 2002;11(2):153-7.
13. Sharma A, Thapa B, Lavaju P. Ocular tuberculosis: an update. *Nepal J Ophthalmol* 2011;3(1):52-67.
14. Bramante CT, Talbot EA, Rathinam SR, Stevens R, Zegans ME. Diagnosis of ocular tuberculosis: a role for new testing modalities? *Int Ophthalmol Clin* 2007;47(3):45-62.