

## Changes in respiratory function in Pembroke Welsh Corgi dogs with degenerative myelopathy

Kanae OYAKE<sup>1)</sup>, Yui KOBATAKE<sup>2)</sup>, Sanae SHIBATA<sup>1,2)</sup>, Hiroki SAKAI<sup>1,2)</sup>, Miyoko SAITO<sup>3)</sup>, Osamu YAMATO<sup>4)</sup>, Kazuya KUSHIDA<sup>4)</sup>, Sadatoshi MAEDA<sup>1,2)</sup> and Hiroaki KAMISHINA<sup>1,2)\*</sup>

<sup>1)</sup>Department of Veterinary Medicine, Faculty of Applied Biological Sciences, Gifu University, 1-1 Yanagido, Gifu 501-1193, Japan

<sup>2)</sup>The United Graduate School of Veterinary Sciences, Gifu University, 1-1 Yanagido, Gifu 501-1193, Japan

<sup>3)</sup>Department of Surgery II, School of Veterinary Medicine, Azabu University, Sagami-hara, Kanagawa 229-8501, Japan

<sup>4)</sup>Laboratory of Clinical Pathology, Department of Veterinary Medicine, Joint Faculty of Veterinary Medicine, Kagoshima University, 1-21-24 Kohrimoto, Kagoshima 890-0065, Japan

(Received 17 December 2015/Accepted 7 April 2016/Published online in J-STAGE 24 April 2016)

**ABSTRACT.** Canine degenerative myelopathy (DM) is characterized by progressive degeneration of the spinal cord. Although atrophic changes in the intercostal muscles were previously reported in the late stage of DM in Pembroke Welsh Corgis (PWCs), changes in respiratory function have not yet been examined. In the present study, we performed an arterial blood gas analysis and measured respiratory movements over progressive disease stages to document changes in respiratory function in DM-affected PWCs. We found that respiratory dysfunction progressed during the later stages of DM and correlated with a change in respiratory movement to the abdominal breathing pattern. These results suggested that hypoventilation occurred due to dysfunctional changes in the intercostal muscles and resulted in hypoxemia in the later stages of DM.

**KEY WORDS:** abdominal breathing pattern, arterial blood gas analysis, canine degenerative myelopathy, hypoventilation, hypoxemia

doi: 10.1292/jvms.15-0521; *J. Vet. Med. Sci.* 78(8): 1323–1327, 2016

Degenerative myelopathy (DM) is characterized by progressive degeneration of the spinal cord and affects selected dog breeds [1, 5, 6]. The etiology of DM has not yet been fully elucidated; however, a previous study reported that DM-affected dogs were homozygous for the *A* allele of a superoxide dismutase 1 (*SOD1*) missense mutation, *SOD1:c.118G > A*, which predicts a p.E40K amino acid substitution [2]. Most of the dogs examined in previous studies were old large breeds [1, 8]. The clinical signs of DM initially appear in the pelvic limbs as spastic upper motor neuron (UMN) paresis and general proprioceptive ataxia, which eventually progress to flaccid tetraplegia and dysphagia [1, 5, 6, 10, 11, 15]. With a longer disease duration, these dogs exhibited signs of respiratory muscle paralysis and were considered to have died from respiratory failure [12, 13]. An increasing number of Pembroke Welsh Corgis (PWCs) in Japan have been found to carry the homozygous *SOD1* mutation and display a typical clinical course [4]. The PWC is smaller than other predisposed large breed dogs, allowing many owners to give appropriate care for a longer period of time [5, 10]. However, the clinical signs of DM in the late stage, especially changes in respiratory function, have not yet been documented in detail.

In the present study, we investigated changes in arterial

blood gas parameters in DM-affected PWCs over progressive disease stages. We also determined whether changes in the thoracic and abdominal movement patterns during breathing reflected a decline in respiratory function with disease progression. We hypothesized that hypoventilation progressively develops in dogs in the later stages of DM due to paralysis of the respiratory muscles, with respiratory patterns mirroring the state of respiratory function.

All cases had been referred to the Animal Medical Center of Gifu University. Informed and written consent was obtained from the owners of the cases at their first visit. We included PWCs that met the following criteria; clinical signs consistent with DM (slowly progressive, non-painful, paraparesis to tetraplegia) [6] unremarkable findings on spinal imaging with non-contrast computed tomography and/or magnetic resonance imaging (MRI), unremarkable findings on cerebrospinal fluid (CSF) analyses (total cell count and cytology) and genetic testing proving homozygosity for the *SOD1* mutation (*c.118G > A* missense). The MRI studies included T1- and T2-weighted sagittal images, T1- and T2-weighted transverse images, and post-contrast T1 sagittal and transverse images of the thoracic and lumbar spinal cords. The disease stage of the DM cases at each visit was classified into 4 clinical stages as previously described [6, 10, 11, 15] with a minor modification. The clinical characteristics of the stages were as follows; Stage1, upper motor neuron paraparesis and general proprioceptive ataxia; Stage2, nonambulatory paraparesis to paraplegia; Stage3, lower motor neuron paraplegia to thoracic limb paresis; and Stage4, lower motor neuron tetraplegia and brain stem signs. In addition to flaccid tetraplegia, PWCs with nonambulatory tetraparesis were grouped into stage 4. At each visit, cases

\*CORRESPONDENCE TO: KAMISHINA, H., Department of Veterinary Medicine, Faculty of Applied Biological Sciences, Gifu University, 1-1 Yanagido, Gifu 501-1193, Japan. e-mail: kamicna@gifu-u.ac.jp

©2016 The Japanese Society of Veterinary Science

This is an open-access article distributed under the terms of the Creative Commons Attribution Non-Commercial No Derivatives (by-nc-nd) License <<http://creativecommons.org/licenses/by-nc-nd/4.0/>>.

received physical examination and complete neurological examination. Periodically, CBC, serum biochemistry and thoracic radiography were performed in some cases to ensure that pulmonary disorders do not underlie respiratory impairment.

Arterial blood specimens were collected from the femoral artery into a heparinized syringe. Samples were immediately analyzed using either GEM®Premier 3000 (IL Janan Co., Ltd., Tokyo, Japan) or i-STAT 300F (Abbott Japan Co., Ltd., Chiba, Japan). Sampling was only undertaken when the dogs showed normal breathing at rest; sampling was suspended if panting continued. To evaluate respiratory function, we focused on the arterial partial pressure of oxygen ( $\text{PaO}_2$ ), arterial partial pressure of carbon dioxide ( $\text{PaCO}_2$ ) and alveolar-arterial (A-a) gradient. The A-a gradient was calculated using the following equation [14]:

$$\text{A-a gradient} = (149.73 - [\text{PaCO}_2/0.8]) - \text{PaO}_2$$

To analyze breathing patterns, dogs were held in a right-lateral recumbency, and at least ten cycles of breathing were videotaped horizontally from the ventral side (Fig. 1). The distance between the dog and video camera was kept constant to 50 cm in all measurements. Three pairs of images at maximal inspiration and expiration were captured from the movies and used to quantify the expansion ratio of the rib cage and abdomen during breathing. Our preliminary study determined 2 points to be measured for thoracic and abdominal movements during which the largest changes in width were observed. The ratios of movement at the maximal inspiratory level against the maximal expiratory level were calculated for the thorax and abdomen, and the mean values were calculated.

Descriptive statistics were analyzed for normality using the Shapiro-Wilk test. Analytes with a normal distribution ( $\text{PaO}_2$ , A-a  $\text{DO}_2$ , and thoracic and abdominal movements) were compared using a one-way ANOVA, followed by the Tukey-Kramer's honestly significant difference test as a post hoc analysis for multiple comparisons. Analytes with a non-normal distribution ( $\text{PaCO}_2$ ) were compared by the Kruskal-Wallis test, followed by the Steel-Dwass test as a post hoc analysis for multiple comparisons. The Pearson product-moment correlation was used to evaluate the relationship between  $\text{PaO}_2$  and thoracic or abdominal movement. The Spearman rank order correlation was used to evaluate the relationship between  $\text{PaCO}_2$  and thoracic or abdominal movement. A  $p$  value  $<0.05$  was considered significant. All statistical analyses were performed by JMP®10 (SAS Institute Inc., Cary, NC, U.S.A.).

A total of 19 PWCs were included in this study. Eleven dogs were male, 8 of which were castrated, and 8 dogs were female, 5 of which were spayed. The age at the first measurement ranged from 9.7 to 13.6 years (median, 11.3 years). Body weight ranged from 8.8 to 17.7 kg (median, 12.9 kg). A summary of information on these dogs is presented in Table 1. To identify changes in respiratory function, an arterial blood gas analysis was performed on 19 PWCs clinically diagnosed with DM (of these, 4 PWCs were histologically diagnosed with DM during the study period).

The oxygenation state was evaluated by measuring

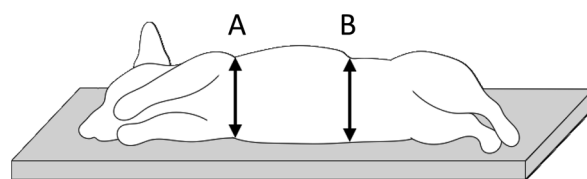


Fig. 1. The position and points measured to determine breathing patterns. Thoracic movement was measured at the vertical line connecting both axillae (A). Abdominal movement was measured at the vertical line passing the caudal edge of the 13th rib (B).

$\text{PaO}_2$ . Hypoxemia was defined as  $\text{PaO}_2$  values lower than 80 mmHg [9]. The oxygenation states of dogs in stages 1 and 2 were considered normal (Fig. 2A). As the disease progressed to the later stages, 8.3% of dogs in stage 3 and 76.9% of dogs in stage 4 were considered to be hypoxemic (Fig. 2A).  $\text{PaO}_2$  values were significantly lower in stage 4 than in the other stages (respectively,  $P < 0.0001$ ). The arterial blood gas analysis also provided information regarding the alveolar ventilation status by measuring  $\text{PaCO}_2$ . Hypercapnia, which suggests hypoventilation, was defined as  $\text{PaCO}_2$  values greater than 45 mmHg [9]. The ventilation status of the dogs in stages 1 and 2 was considered normal (Fig. 2B). With disease progression, 4.2% of dogs in stage 3 and 53.8% of dogs in stage 4 were considered to have developed hypoventilation (Fig. 2B).  $\text{PaCO}_2$  values were significantly higher in stage 4 than in the other stages (stage 1,  $P = 0.0009$ ; stage 2,  $P = 0.0003$ ; and stage 3,  $P = 0.0019$ ). Furthermore, 58.3% of the dogs that were hypoxemic also developed hypoventilation. This result suggested that hypoxemia occurred in DM-affected PWCs due to hypoventilation. The mean values of the A-a gradient were  $21.0 \pm 6.9$  in stage 1,  $20.4 \pm 7.0$  in stage 2,  $21.6 \pm 8.5$  in stage 3 and  $18.3 \pm 7.8$  in stage 4. No significant differences were observed in the A-a gradient values among the 4 stages.

Thoracic and abdominal movements during breathing were quantified in the different stages. Nine PWCs clinically diagnosed with DM (of these, 3 PWCs were histologically diagnosed with DM) were included in this analysis (Table 1). No significant differences were observed in the degrees of thoracic and abdominal movements between stages 1 and 2 (Fig. 2C and 2D). With disease progression, thoracic movement decreased and became significantly lower in stage 4 than in stages 1 ( $P = 0.0023$ ) and 2 ( $P = 0.0011$ ) (Fig. 2C). In contrast, abdominal movement increased in stages 3 and 4; however, a significant difference was only noted between stages 1 and 4 ( $P = 0.0497$ ) (Fig. 2D).

To evaluate whether changes in thoracic and abdominal movements correlated with respiratory impairment, a correlation analysis was performed between thoracic or abdominal movement and  $\text{PaO}_2$  or  $\text{PaCO}_2$  values. The correlation coefficient between thoracic movement and  $\text{PaO}_2$  was 0.7590 ( $P < 0.0001$ ) (Fig. 3A), and  $\text{PaCO}_2$  was  $-0.6583$  ( $P = 0.0006$ ) (Fig. 3B). This result indicated that respiratory impairment progressed as thoracic movement decreased. The correlation coefficient between abdominal movement

Table 1. Dogs examined in the present study

No.	Sex	Age of onset (years)	First measurement		Number of data obtained from each case									
					Arterial blood gas analysis					Analysis, of breathing pattern				
			Age (years)	Body weight (kg)	Stage				Total	Stage				Total
					1	2	3	4		1	2	3	4	
1	M	10.3	10.7	11.5	1	5	2	6	14	0	2	2	5	9
2	MC	9.3	9.7	17.5	1	3	3	3	10	0	1	0	3	4
3	FS	8.8	10.3	13.3	0	1	4	2	7	0	0	2	1	3
4	MC	9.0	10.5	12.5	2	3	2	0	7	0	0	2	0	2
5	MC	8.3	10.5	11.2	0	2	3	0	5					
6	MC	12.5	13.3	17.7	0	2	2	0	4					
7	F	9.6	10.7	9.1	0	3	1	0	4					
8	MC	10.6	11.3	11.2	1	2	1	0	4					
9	FS	11.4	12.0	13.4	1	3	0	0	4	1	0	0	0	1
10	F	10.3	10.4	13.5	1	1	1	0	3	1	0	0	0	1
11	MC	10.9	13.0	15.0	0	0	1	1	2					
12	MC	10.4	11.5	14.0	0	0	2	0	2	0	0	1	0	1
13	F	11.3	11.4	15.0	0	0	2	0	2					
14	FS	12.3	12.8	8.8	1	1	0	0	2	1	0	0	0	1
15	FS	9.0	9.7	11.9	2	0	0	0	2					
16	M	11.3	12.0	15.3	2	0	0	0	2					
17	MC	11.3	13.6	12.9	0	0	0	1	1					
18	FS	10.8	12.0	12.6	0	1	0	0	1					
19	M	10.3	10.3	10.1	1	0	0	0	1	1	0	0	0	1
Total number of data in each stage					13	27	24	13		4	3	7	9	

F, female; FS, female spayed; M, male; MC, male castrated. Dog numbers 1, 2, 3 and 17 underwent necropsy and were histologically diagnosed with DM.

and  $\text{PaO}_2$  was  $-0.6525$  ( $P=0.0007$ ) (Fig. 3C), and  $\text{PaCO}_2$  was  $0.6183$  ( $P=0.0017$ ) (Fig. 3D). This result showed that abdominal movement increased with the progression of respiratory impairment.

DM is a progressive neurodegenerative disease that ultimately leads to respiratory failure and death [12, 13]. However, respiratory dysfunction in DM and its progression have not yet been examined in detail. Therefore, we evaluated changes in respiratory function in DM-affected PWCs. Our results suggested that thoracic movement during breathing declined in the later stages of DM, resulting in hypoxemia due to hypoventilation.

A normal A-a gradient value excluded conditions, such as a true shunt, ventilation/perfusion mismatch and diffusion impairment. A previous study demonstrated that hypoxemic dogs with a normal gradient value developed hypoxemia due to hypoventilation [14]. The A-a gradient value of dogs without cardiopulmonary diseases was previously reported to be  $21.8 \pm 6.4$  [3], and the 95% confidence interval was from 9.0 to 34.6. In the present study, the A-a gradient values of dogs in all stages were within the reported reference range. Therefore, hypoxemia was considered to have occurred due to hypoventilation in DM PWCs.

A previous study on the mechanics of canine inspiratory muscles reported that the diaphragm and intercostal muscles acted synergistically for lung expansion, in which the lung volume during combined diaphragm-intercostal contractions was greater than the sum of the lung volumes produced by two muscles contracting separately [7]. In our study, thoracic

movement declined in stages 3 and 4. This result supported previously reported atrophic changes in the intercostal muscles in stages 3 and 4 in PWCs leading to progressive respiratory impairment [10]. PWCs in stage 3 showed the widest ranges in thoracic movement. This variability may reflect the wide spectrum of functional states of the intercostal muscles of DM cases in stage 3, from almost normal to nearly paralytic states. In our study, thoracic movement negatively correlated with  $\text{PaO}_2$  and positively correlated with  $\text{PaCO}_2$ . These results indicated that the dysfunction in the intercostal muscles produced insufficient thoracic expansion, resulting in hypoventilation and subsequently hypoxemia. In contrast to thoracic movement, abdominal movement increased as DM progressed to the later stages, and respiratory movement consequently changed to the abdominal breathing pattern. This change in the breathing pattern suggested that the diaphragm maintained respiratory function to compensate for decreased thoracic movement. Ultimately, pathological changes develop in the diaphragm, such as paralysis and/or fatigue, and dogs may die from respiratory failure. However, the pathology of the diaphragm and phrenic nerves has not yet been investigated in DM-affected dogs.

No prophylactic or curative treatment currently exists for DM [6]. Therefore, treatments should be aimed to relieve clinical signs and maintain the quality of life of the affected dogs. Since PWCs are more likely to be maintained until the later stages of DM than large breeds [5, 10], it is important to consider appropriate care for the decreased respiratory function. For example, DM-affected dogs in the

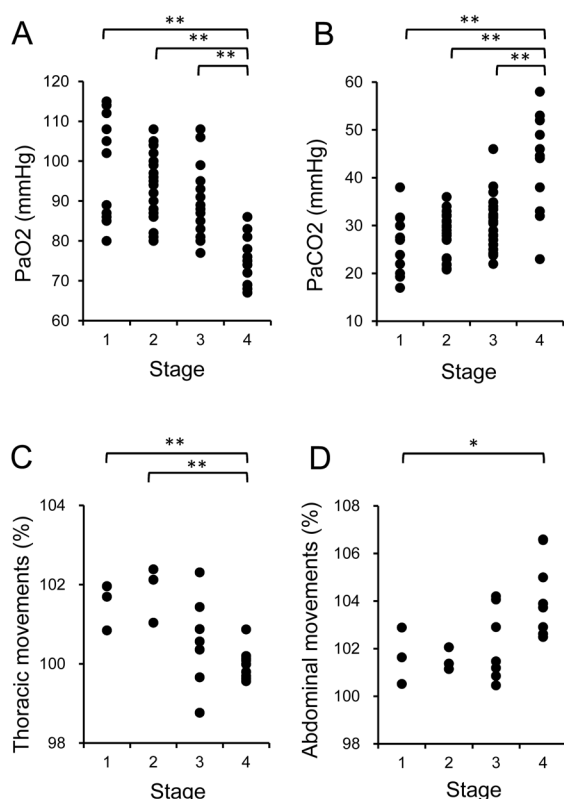


Fig. 2. Respiratory function and breathing patterns. (A, B) States of oxygenation and ventilation in DM. (A)  $\text{PaO}_2$  was significantly lower in stage 4 than in the other stages, with 76.9% of PWCs being hypoxemic. (B)  $\text{PaCO}_2$  was significantly higher in stage 4 than in the other stages, with 53.8% of PWCs developing hypoventilation. (C, D) Thoracic and abdominal movements during breathing. (C) Thoracic movement was more likely to be smaller in the later stages. (D) Abdominal movement was more likely to be larger in the later stages. \*  $P < 0.05$ , \*\*  $P < 0.01$ .

later stages that show an abdominal breathing pattern may not be able to regulate their body temperature by panting, which requires constriction of the intercostal muscles and diaphragm. Therefore, the temperature of the environment in which the dogs are kept needs to be considered in order to avoid panting and maintain maximum respiratory function. The results on longitudinal changes in respiratory function in the present study will assist veterinary practitioners and owners to recognize when and how to give appropriate care for DM-affected dogs.

**ACKNOWLEDGMENTS.** We thank Ms. Saeko Asada for her excellent technical assistance. This work was supported by JSPS KAKENHI Grant Number 24380169 and 23580450.

#### REFERENCES

1. Averill, D. R. Jr. 1973. Degenerative myelopathy in the aging German Shepherd dog: clinical and pathologic findings. *J. Am.*

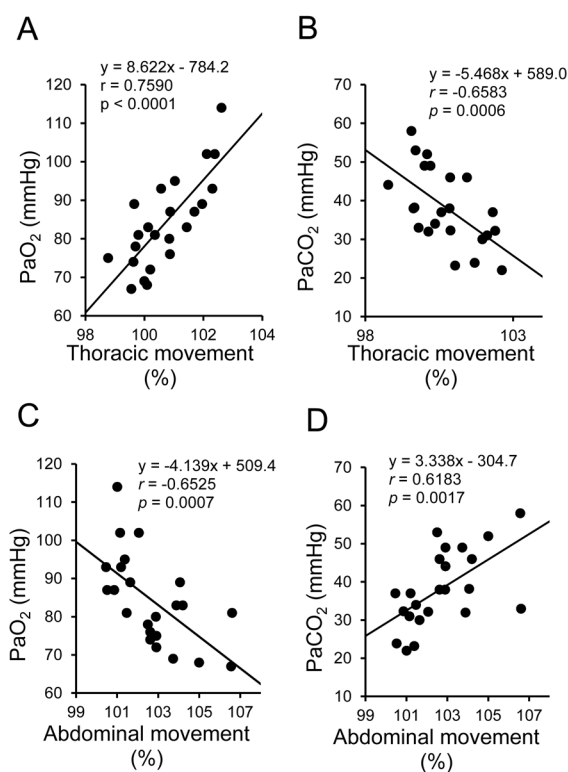


Fig. 3. Relationship between thoracic or abdominal movement and  $\text{PaO}_2$  or  $\text{PaCO}_2$ . Thoracic movement correlated with (A)  $\text{PaO}_2$  and (B)  $\text{PaCO}_2$ . Abdominal movement correlated with (C)  $\text{PaO}_2$  and (D)  $\text{PaCO}_2$ .

- Vet. Med. Assoc.* **162**: 1045–1051. [Medline]
2. Awano, T., Johnson, G. S., Wade, C. M., Katz, M. L., Johnson, G. C., Taylor, J. F., Perloski, M., Biagi, T., Baranowska, I., Long, S., March, P. A., Olby, N. J., Shelton, G. D., Khan, S., O'Brien, D. P., Lindblad-Toh, K. and Coates, J. R. 2009. Genome-wide association analysis reveals a SOD1 mutation in canine degenerative myelopathy that resembles amyotrophic lateral sclerosis. *Proc. Natl. Acad. Sci. U.S.A.* **106**: 2794–2799. [Medline] [CrossRef]
3. Bach, J. F., Rozanski, E. A., Bedenice, D., Chan, D. L., Freeman, L. M., Lofgren, J. L., Oura, T. J. and Hoffman, A. M. 2007. Association of expiratory airway dysfunction with marked obesity in healthy adult dogs. *Am. J. Vet. Res.* **68**: 670–675. [Medline] [CrossRef]
4. Chang, H. S., Kamishina, H., Mizukami, K., Momoi, Y., Katayama, M., Rahman, M. M., Uddin, M. M., Yabuki, A., Kohyama, M. and Yamato, O. 2013. Genotyping assays for the canine degenerative myelopathy-associated c.118G>A (p.E40K) mutation of the SOD1 gene using conventional and real-time PCR methods: a high prevalence in the Pembroke Welsh Corgi breed in Japan. *J. Vet. Med. Sci.* **75**: 795–798. [Medline] [CrossRef]
5. Coates, J. R., March, P. A., Oglesbee, M., Ruaux, C. G., Olby, N. J., Berghaus, R. D., O'Brien, D. P., Keating, J. H., Johnson, G. S. and Williams, D. A. 2007. Clinical characterization of a familial degenerative myelopathy in Pembroke Welsh Corgi dogs. *J. Vet. Intern. Med.* **21**: 1323–1331. [Medline] [CrossRef]
6. Coates, J. R. and Wininger, F. A. 2010. Canine degenerative myelopathy. *Vet. Clin. North Am. Small Anim. Pract.* **40**: 929–950. [Medline] [CrossRef]

7. De Troyer, A. 2005. Interaction between the canine diaphragm and intercostal muscles in lung expansion. *J. Appl. Physiol.* **98**: 795–803. [[Medline](#)] [[CrossRef](#)]
8. Griffiths, I. R. and Duncan, I. D. 1975. Chronic degenerative radiculomyelopathy in the dog. *J. Small Anim. Pract.* **16**: 461–471. [[Medline](#)] [[CrossRef](#)]
9. Malley, W. J. 2005. *Clinical Blood Gases: Assessment and Intervention*, 2nd ed., Elsevier Saunders, St. Louis.
10. Morgan, B. R., Coates, J. R., Johnson, G. C., Bujnak, A. C. and Katz, M. L. 2013. Characterization of intercostal muscle pathology in canine degenerative myelopathy: a disease model for amyotrophic lateral sclerosis. *J. Neurosci. Res.* **91**: 1639–1650. [[Medline](#)] [[CrossRef](#)]
11. Morgan, B. R., Coates, J. R., Johnson, G. C., Shelton, G. D. and Katz, M. L. 2014. Characterization of thoracic motor and sensory neurons and spinal nerve roots in canine degenerative myelopathy, a potential disease model of amyotrophic lateral sclerosis. *J. Neurosci. Res.* **92**: 531–541. [[Medline](#)] [[CrossRef](#)]
12. Ogawa, M., Uchida, K., Park, E. S., Kamishina, H., Sasaki, J., Chang, H. S., Yamato, O. and Nakayama, H. 2011. Immunohistochemical observation of canine degenerative myelopathy in two Pembroke Welsh Corgi dogs. *J. Vet. Med. Sci.* **73**: 1275–1279. [[Medline](#)] [[CrossRef](#)]
13. Ogawa, M., Uchida, K., Yamato, O., Inaba, M., Uddin, M. M. and Nakayama, H. 2014. Neuronal loss and decreased GLT-1 expression observed in the spinal cord of Pembroke Welsh Corgi dogs with canine degenerative myelopathy. *Vet. Pathol.* **51**: 591–602. [[Medline](#)] [[CrossRef](#)]
14. Proulx, J. 1999. Respiratory monitoring: arterial blood gas analysis, pulse oximetry, and end-tidal carbon dioxide analysis. *Clin. Tech. Small Anim. Pract.* **14**: 227–230. [[Medline](#)] [[CrossRef](#)]
15. Shelton, G. D., Johnson, G. C., O'Brien, D. P., Katz, M. L., Pessayre, J. P., Chang, B. J., Mizisin, A. P. and Coates, J. R. 2012. Degenerative myelopathy associated with a missense mutation in the superoxide dismutase 1 (SOD1) gene progresses to peripheral neuropathy in Pembroke Welsh corgis and boxers. *J. Neurol. Sci.* **318**: 55–64. [[Medline](#)] [[CrossRef](#)]