

Two Cases of Ectopic Adrenocorticotrophic Hormone Syndrome with Olfactory Neuroblastoma and Literature Review

BO KYUNG KOO[†], JEE HYUN AN[†], KI HYUN JEON, SUNG HEE CHOI, YOUNG MIN CHO*, HAK CHUL JANG, JIN-HAENG CHUNG**, CHOL HEE LEE*** AND SOO LIM

Department of Internal Medicine, Seoul National University College of Medicine, Seoul National University Bundang Hospital, 300, Gumi-dong, Bundang-gu, Seongnam-city, South Korea

**Department of Internal Medicine, Seoul National University College of Medicine, 28, Yongon-dong, Chongno-gu, Seoul, South Korea*

***Department of Pathology, Seoul National University College of Medicine, 300, Gumi-dong, Bundang-gu, Seongnam-city, South Korea*

****Department of Otorhinolaryngology-Head and Neck Surgery, Seoul National University College of Medicine, 300, Gumi-dong, Bundang-gu, Seongnam-city, South Korea*

†Bo Kyung Koo and Jee Hyun An are equally contributed to this journal.

Abstract. Olfactory neuroblastomas are rare, slow-growing malignant tumors, usually diagnosed at advanced stages. Ectopic adrenocorticotrophic hormone (ACTH) syndrome caused by an olfactory neuroblastoma is extremely rare. We reported two Korean women who suffered from ectopic ACTH syndrome (EAS) caused by olfactory neuroblastomas. The first patient was a 66-year-old woman who had been diagnosed as olfactory neuroblastoma and refused the management two years before and the second patient was a 37-year-old woman on chemotherapy for olfactory neuroblastoma. In the first case, she presented the Cushingoid appearance with systemic edema and her tumor was removed surgically. ACTH secretion by the tissue was confirmed by immunohistochemistry. By contrast, the second patient presented as severe pneumonia caused by cytomegalovirus and was treated with anti-viral agent followed by chemotherapy and radiotherapy, and her residual mass remained. However, after treatment, both patients' plasma ACTH and cortisol levels returned to normal without any adrenolytic therapy. Considering the causative tumors of EAS can be rarely cured and EAS increases the susceptibility to infections, it is prudent to suppress any hypercortisolemia initially, apart from treating the causal malignancy.

Key words: Olfactory neuroblastoma, Ectopic ACTH syndrome

(Endocrine Journal 55: 469–475, 2008)

ECTOPIC adrenocorticotrophic hormone (ACTH) secretion is the cause of 10%–18% of cases of Cushing's syndrome [1–4]. The most common malignancy to produce ectopic ACTH syndrome (EAS) as a paraneoplastic syndrome is small cell lung cancer, which accounts for as much as 50% of the causal tumors of EAS [1, 5, 6]. Carcinoids and pancreatic neuroendocrine tumors are also known to be common causes of EAS;

less frequently, breast cancer [7], colon cancer [8, 9] and prostate cancer [10] are reported to be causative.

EAS caused by an olfactory neuroblastoma is extremely rare: there have been only five such cases reported [11–15]. Olfactory neuroblastoma is a rare malignant tumor, which is slowly growing and diagnosed at advanced stages in most cases [16, 17]. We report here one definite case and one possible case of ACTH-dependent Cushing's syndrome associated with olfactory neuroblastoma.

Case 1

A 66-year-old Korean woman presented with systemic edema and general fatigue. The patient had been

Received: July 31, 2007

Accepted: March 20, 2008

Correspondence to: Soo LIM, M.D., M.P.H., Ph.D., Department of Internal Medicine, Seoul National University College of Medicine, Seoul National University Bundang Hospital, 300, Gumi-dong, Bundang-gu, Seongnam-city, 463-707 South Korea

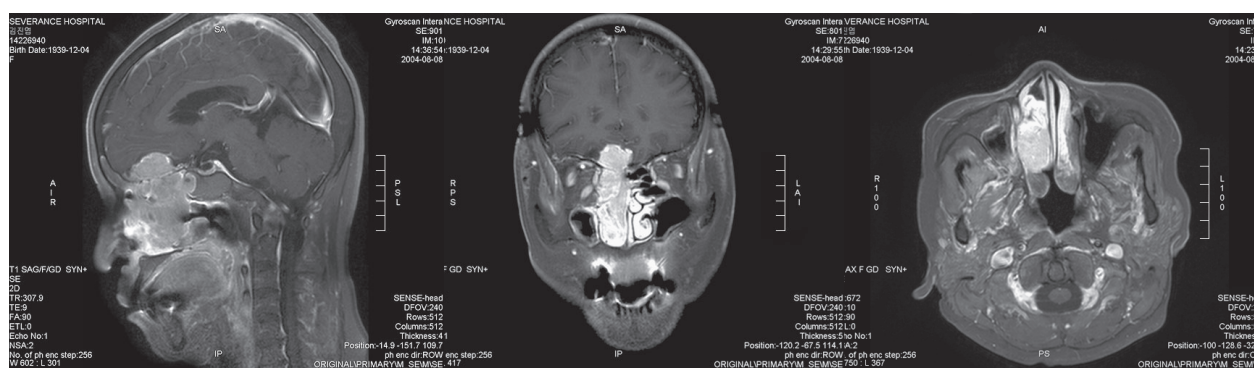


Fig. 1. Magnetic resonance images of head and neck (T1 gadolinium) for Patient 1.

Tumor involved the right nasal cavity, the right ethmoid sinus, the right sphenoid sinus and the right frontal skull base. There was no pituitary lesion.

diagnosed as an olfactory neuroblastoma two years before, but she had refused curative operation and haven a foreign body-sensation in the right nasal cavity and rhinorrhea since that time. The patient had Cushingoid appearance at the presentation: moon face, central obesity, thin skin with purpura and hirsutism. Her blood pressure was 160/90 mmHg. A laboratory examination revealed hypokalemia (2.6 mmol/L) with metabolic alkalosis (pH 7.529, HCO_3^- 41.8 mEq/L). Hyperglycemia was detected for the first time in her life: fasting plasma glucose was 237 mg/dL and the hemoglobin A1c level was 7.9%.

Head and neck magnetic resonance imaging (MRI) scans showed that the tumor had slightly increased in size in the right nasal cavity, the right ethmoid sinus, the right sphenoid sinus and the right frontal skull base over the two years; however, there was no pituitary lesion (Fig. 1).

The patient's plasma ACTH concentration was 862 pg/mL and the cortisol concentration was 65.3 $\mu\text{g/dL}$, which were measured by immunoradiometric assay (Cis Bio International, Gif/Yvette, France). The cortisol level was not suppressed by a low-dose dexamethasone suppression test (LDDST; 2 mg dexamethasone per day for 48 h): plasma cortisol level was 57.6 $\mu\text{g/dL}$ and 24 h urine cortisol level was 5045.2 $\mu\text{g/dL}$ after the LDDST. The patient's cortisol level was not suppressed neither by a high-dose dexamethasone suppression test (HDDST; 8 mg dexamethasone per day for 48 h): plasma cortisol level was 52.0 $\mu\text{g/dL}$ and 24 h urine cortisol level was 4399.5 $\mu\text{g/dL}$ after HDDST. A corticotropin-releasing hormone (CRH) stimulation test using 100 μg ovine CRH was performed and plasma ACTH and cortisol levels did not rise over 2 h

(42% decrease in ACTH level and 4.7% increase in cortisol level), which suggested that her Cushing's syndrome was more likely to arise from EAS than from Cushing's disease. Chest computer tomography (CT) and abdominal CT were performed to find out the causative tumor, however, there was no abnormality except for focal atelectasis of the right upper lobe and left lower lobe of the lung without any changes for two years and the hyperplasia of both adrenal glands without any focal mass (figures not shown).

Using whole-body ^{18}F -fluoro-2-deoxy-glucose positron emission tomography (^{18}F -FDG PET) scanning, hypermetabolic lesions were observed involving the right nasal cavity, the right ethmoid sinus, the right sphenoid sinus, the right frontal skull base (standardized uptake value, SUV, 1.4–2.0), both adrenal glands (SUV right 3.5, left 3.2), and the right upper lobe of the lung (SUV 1.9). However, these data provided no further information to rule out the possibility of a pulmonary lesion as the source of the ACTH. Dual-energy X-ray absorptiometry (DXA) bone densitometry revealed osteoporosis: a T-score of -3.3 at L1–L4 spine.

Adrenolytic therapy (ketoconazole 600–1200 mg/day) was commenced three weeks before the planned operation and the patient's plasma cortisol level decreased from 62.3 $\mu\text{g/dL}$ to 27.6 $\mu\text{g/dL}$. Hyperglycemia was controlled with insulin and hypokalemia was corrected with oral potassium replacement. Antihypertensive treatment and calcium and vitamin D replacement for osteoporosis were started. After the patient reached medical stabilization, ketoconazole was discontinued just before surgery. Craniotomy, tumor removal and skull base reconstruction were performed. The nasal cavity mass measured about $3 \times 1.6 \times 0.9$

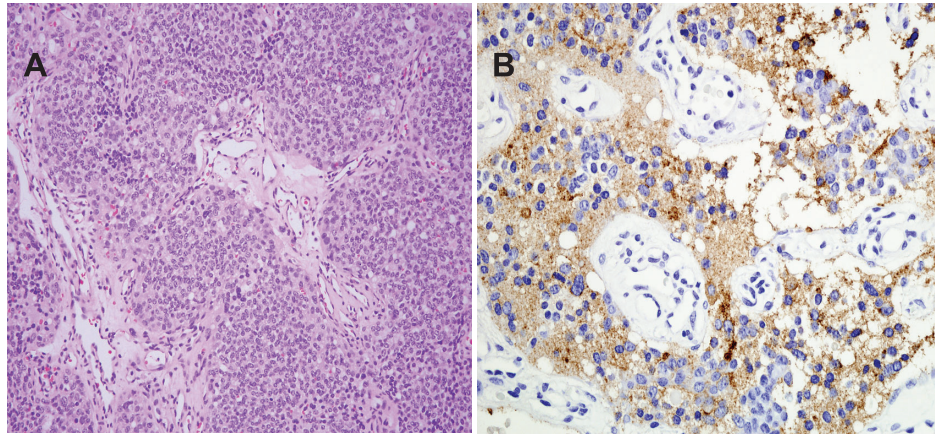


Fig. 2. Histology of the olfactory neuroblastoma in Patient 1.

A. Solid nests of tumor cells in the fibrovascular stroma (H & E $\times 100$). B. ACTH immunohistochemical staining. Olfactory neuroblastoma cells show intracytoplasmic immunopositivity of ACTH (immunostaining $\times 400$).

cm. Microscopically, the mass was a cellular tumor composed of uniform small cells with round nuclei, scanty cytoplasm, indistinct nuclear membrane and a richly vascular stroma (Fig. 2A). The diagnosis of olfactory neuroblastoma was supported by immunohistochemical staining for neural markers, including CD56, synaptophysin, chromogranin and S-100. The immunohistochemical study for ACTH was performed by using a monoclonal mouse anti-ACTH antibody (Dako, Glostrup, Denmark) (Fig. 2B). Postoperatively, the patient's plasma ACTH and cortisol levels decreased from 862 pg/mL to 40 pg/mL and from 62.3 $\mu\text{g/dL}$ to 18.9 $\mu\text{g/dL}$, respectively. The Cushingoid appearance disappeared gradually. Adjuvant radiotherapy was performed for eight weeks. The patient is being followed-up for 12 months at an outpatient department without any recurrence of Cushing's syndrome and the plasma ACTH concentration and 24 h urine cortisol value remain within normal range.

Case 2

A 37-year-old Korean woman who had a foreign body sensation in the nasal cavity and rhinorrhea was diagnosed as an olfactory neuroblastoma. She had Cushingoid appearance at the presentation: moon face, central obesity, proximal muscle weakness and hirsutism. Her blood pressure was 150/85 mmHg. As she had Cushingoid features, she was screened to rule out Cushing's syndrome. The laboratory findings revealed that she had high levels of serum ACTH (1362 pg/mL),

cortisol (48.4 $\mu\text{g/dL}$), and 24 h urine cortisol (292 $\mu\text{g/dL}$), which were measured by immunoradiometric assay (Cis Bio International, Gif/Yvette, France). These were not suppressed by LDDST or HDDST: plasma cortisol level was 50.9 $\mu\text{g/dL}$ and 24 h urine cortisol level was 9142 $\mu\text{g/dL}$ after HDDST. To confirm whether her ACTH-dependent Cushing's syndrome was caused by EAS, a small biopsy from her main mass was immunostained for ACTH by using a monoclonal mouse anti-ACTH antibody (Dako, Glostrup, Denmark). However, the result was negative.

For her olfactory neuroblastoma, she was planned to treat with neoadjuvant chemotherapy followed by curative surgery. The patient received two-cycled neoadjuvant chemotherapy: etoposide (100 mg/m^2), ifosfamide (1500 mg/m^2) and cisplatin (80 mg/m^2). After the second round of chemotherapy, the patient experienced respiratory failure caused by cytomegalovirus-associated pneumonia. This was treated with antibiotics, and ketoconazole (800–1200 mg/day) with octreotide (300 $\mu\text{g/day}$ s.c.) was used to suppress the hypercortisolemia (Table 1). The patient's arterial oxygen saturation improved and radiotherapy was started on the nasal cavity mass. On the 25th day in hospital, respiratory failure developed again and the patient's urinary cortisol output was 49.2 $\mu\text{g/day}$. *Pneumocystis jiroveci* was identified in the sputum by immunofluorescence staining and she was treated with trimethoprim-sulfamethoxazole and hydrocortisone. This allowed a resumption of radiotherapy. Immediately after radiotherapy (total dose 5,400 cGy) there was no

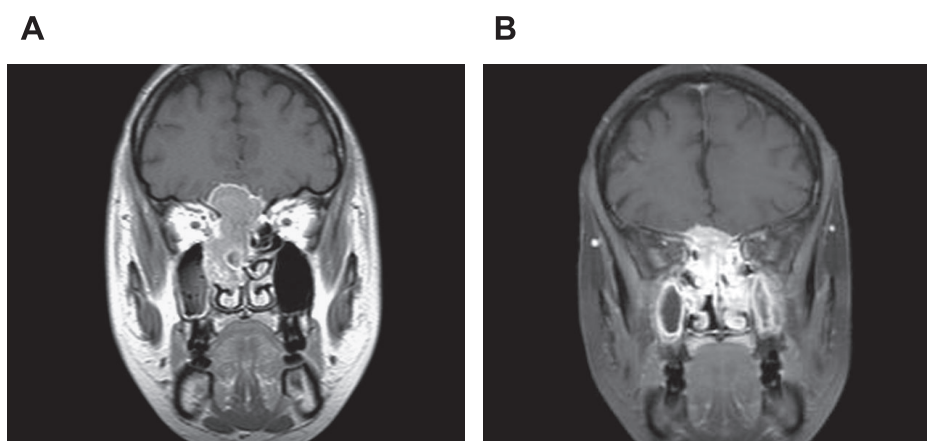
Table 1. Changes in the hormonal values in Patient 2.

Hormone	1 month before ^{b)}	Day 1	Day 3	Day 9	Day 13	Day 17	Day 19	Day 25 ^{c)}	Day 32
Plasma cortisol (5–25 µg/dL)	48.4	83		29	34.7	46.5	57.5	9.8	44.5
Plasma ACTH (0–60 pg/mL)	1362	652		858	621	609	743	213	962
24 h urine cortisol (39–200 µg/day)	292			3626	1461	11238	7074	49.2	3389
Ketoconazole (mg/day) ^{a)}			400		600		1600	1200	
Octreotide (µg/day) ^{a)}				300				450	

^{a)} Administration dose for suppression of endogenous steroidogenesis.

^{b)} Laboratory findings one month before the admission.

^{c)} Fever with hypoxia redeveloped on the 25th day after admission, which turned out to be associated with a *Pneumocystis* infection

**Fig. 3.** Magnetic resonance image of paranasal sinus in Patient 2.

A. The size of the tumor did not change immediately after completion of radiotherapy. B. This image, taken two years later, shows that the mass in the nasal cavity had decreased in size and the maxillary sinus was filled with soft tissue caused by sinusitis.

change in the size of the mass on MRI scans of the paranasal sinus (Fig. 3A). However, four months after radiotherapy, [¹⁸F]-FDG PET for the whole body showed no hypermetabolic lesion. The patient refused surgery for the olfactory neuroblastoma following radiotherapy and has taken regular check-ups for two years from that time. A paranasal sinus MRI scan taken two years after radiotherapy revealed that the size of the mass has decreased (Fig. 3B). The plasma ACTH concentration and 24 h urine cortisol output remained within normal ranges without any medication (plasma ACTH 32 pg/mL and 24 h urine cortisol 27 µg/day).

Discussion

The first patient had EAS associated with an untreated olfactory neuroblastoma, which was diagnosed

preoperatively from the plasma ACTH concentration, HDDST and CRH stimulation tests. Positive immunohistochemical staining for ACTH with the resected tumor mass confirmed the secretion of ACTH from the olfactory neuroblastoma. However, a biopsy from the second patient, diagnosed as ACTH-dependent Cushing's syndrome, failed to show positive staining for ACTH in the olfactory neuroblastoma. CRH stimulation test or inferior petrosal sinus sampling (IPSS) to differentiate between EAS and Cushing's disease was not performed in that case. However, resolution of Cushing's syndrome after radiotherapy on the mass in the nasal cavity and normalization of her plasma ACTH concentration and 24 h urine cortisol without any adrenolytic therapy such as ketoconazole or octreotide suggest that her Cushing's syndrome was caused by the olfactory neuroblastoma. That the mass was negative for ACTH despite the clinical features of

EAS could have several reasons. First, the mass might have secreted CRH rather than ACTH. Neoplasms producing CRH are very rare [5] and the few cases confirmed to produce CRH were reported not to secrete ACTH [5, 18]. According to an interesting case from Ozawa *et al.*, immunohistology and radioimmunoassay demonstrated CRH and a lesser amount of ACTH in the resected thymic carcinoid with Cushing's syndrome [19]. After the patient died, tumor obtained at autopsy contained mainly ACTH and lesser quantities of CRH. Finally, they concluded that the thymic carcinoid initially produced mainly CRH and then transformed to secrete mainly ACTH. This result suggests that endocrine tumors may change their functional phenotype. Saeger *et al.* also showed that CRH without ACTH was demonstrated in several tumors with ectopic Cushing's syndrome from different areas [20]. Furthermore, neither ACTH nor CRH could be found in one case with ectopic Cushing's syndrome [20]. Second, if the mass were secreting proopiomelanocortin (POMC) or other prohormones, clinical features associated with EAS could be present. POMC produced by neoplasms other than pituitary tumors is reported to be processed to smaller-sized ACTH precursors than normal ACTH, which can cause the clinical feature of EAS despite their lower biological activity [21]. Interestingly, one report of an adrenal neuroblastoma producing increased levels of POMC did not show any increased ACTH level [22]. In addition, by Raux Demay *et al.*, an ACTH-producing thymic carcinoid tumor was found to be responsible for the Cushing's syndrome [23]. In this case, human CRH, POMC-mRNA and POMC-related peptides were identified in the tumor extract.

In current study, plasma concentration of ACTH and cortisol were measured by immunoradiometric assay (Cis Bio International, Gif/Yvette, France). This ACTH assay kit is specific for detecting intact ACTH (1-39) and does not detect POMC and pro ACTH. The immunohistochemical study of the specimen was done by using a monoclonal mouse anti-ACTH antibody (Dako, Glostrup, Denmark). This is known not to crossreact with POMC and pro ACTH.

In reviewing the literature for EAS with olfactory neuroblastomas, there have been four possible cases published [12–15]. However, considering ACTH was not detected in the tumor mass, it seems that the oldest case published in 1987 was not the case [13]. Thus, there have been only three cases of adults with patho-

logically proven ectopic ACTH-producing olfactory neuroblastomas to our knowledge [12, 14, 15].

The most important clinical problems in treating patients with ACTH-dependent Cushing's syndrome might be to differentiate between an occult nonpituitary source of ACTH secretion and an ACTH-producing microadenoma [24]. The most accurate method of distinguishing between pituitary and ectopic ACTH secretion is known to be IPSS [25]. However, it is invasive and sometimes leads to confusion. Furthermore, some cases have been reported in which patients with an olfactory neuroblastoma producing the EAS were misdiagnosed as having Cushing's syndrome. This is because a tumor in the ethmoid sinus is located adjacent to the upstream pituitary venous drainage system, which might cause a false positive result [15, 26]. Since 1981, the CRH stimulation test has been used extensively in this differential diagnosis. Between 7% and 14% of patients with Cushing's disease fail to respond to CRH, and by contrast, only 4% of patients with EAS respond to CRH [3]. When comparing the CRH test with the HDDST, the former gives more accurate results when using stringent response criteria (70% vs. 48%) [27]. In a similar study [3], the use of both tests did not improve the diagnostic accuracy. Considering the negative result of immunohistochemical staining for ACTH, the CRH test might have provided more information to differentiate the cause of the ACTH-dependent Cushing's syndrome in our second patient. However, among the reported cases of EAS associated with olfactory neuroblastomas, only two reported the results of CRH stimulation tests and the Japanese case of them, diagnosed as ACTH-producing olfactory neuroblastoma proven by pathology, showed increased ACTH level after CRH stimulation, which might have misled to diagnose as Cushing's disease [15]. Furthermore, in that case, the IPSS showed a high central-to-peripheral ratio of ACTH (2.8).

As hypercortisolemia is known to cause an impairment of cell-mediated immunity regardless of the source: intrinsic or extrinsic [28], presence of an EAS increases the susceptibility to infections, which might increase the rates of morbidity and mortality. According to a study performed in patients with small cell lung cancer — the most common cancer causing EAS — patients with EAS showed significantly higher infection-related mortality rates during chemotherapy than those without EAS [29]. Previously reported patients with EAS associated with olfactory neuroblastomas,

including our two reported here, showed increased susceptibility to infections by unusual organisms that rarely cause infection among immunocompetent hosts. Considering that tumors causing EAS can be cured only rarely [5, 30], therapy to suppress hypercortisolemia must be initiated, apart from treating the causal malignancy.

In these two patients, the olfactory neuroblastomas invaded the sinus cavities and the skull base, but did not have lymph node or other distant metastases, which made both cases Kadish's stage B [16]. Considering the treatment status including operation and radiotherapy in our two patients, the five-year survival expectancy would be 70%–90% and 60%–80%, respectively [17]. When the tumor recurs, the accompanying paraneoplastic syndrome also becomes worse in many cases [31]. Therefore, considering the patients' likely-survival period, tracing the levels of plasma ACTH and

cortisol should be useful in judging the progress of the tumor.

In our second case, her clinical status was very severe and urgent suppression of hypercortisolemia was requested. So we decided to start octreotide with ketoconazole together. In ectopic ACTH syndrome, octreotide or somatostatin has been found to inhibit pathological ACTH secretion in some cases [32–36]. However, it should be considered that the clinical application of octreotide in EAS is unwarranted without the presence of SSTR2 or 5 in tumor tissue.

In conclusion, we report that one definite case and one possible case of olfactory neuroblastoma with ectopic ACTH syndrome. We suggest that olfactory neuroblastomas can cause ectopic ACTH syndrome. As the cure rate of tumors causing ectopic ACTH syndrome is low, it is recommended to suppress hypercortisolemia initially.

References

1. Wajchenberg BL, Mendonca BB, Liberman B, Pereira MA, Carneiro PC, Wakamatsu A, Kirschner MA (1994) Ectopic adrenocorticotrophic hormone syndrome. *Endocr Rev* 15: 752–787.
2. Aniszcwski JP, Young WF, Jr., Thompson GB, Grant CS, van Heerden JA (2001) Cushing syndrome due to ectopic adrenocorticotrophic hormone secretion. *World J Surg* 25: 934–940.
3. Reimondo G, Paccotti P, Minetto M, Termine A, Stura G, Bergui M, Angeli A, Terzolo M (2003) The corticotrophin-releasing hormone test is the most reliable noninvasive method to differentiate pituitary from ectopic ACTH secretion in Cushing's syndrome. *Clin Endocrinol (Oxf)* 58: 718–724.
4. Invitti C, Pecori Giralaldi F, de Martin M, Cavagnini F (1999) Diagnosis and management of Cushing's syndrome: results of an Italian multicentre study. Study Group of the Italian Society of Endocrinology on the Pathophysiology of the Hypothalamic-Pituitary-Adrenal Axis. *J Clin Endocrinol Metab* 84: 440–448.
5. Stewler GJ (2002) Humoral Manifestations of Malignancy. In: K. H. Larsen PR, Melmed S, Polonsky KS Series (eds) *Humoral Manifestations of Malignancy*. Saunders, Philadelphia, 1834–1856.
6. DeLellis RA, Xia L (2003) Paraneoplastic endocrine syndromes: a review. *Endocr Pathol* 14: 303–317.
7. Poddar NK, Saha R, Hedau S, Ray A (2005) Adrenocorticotrophic hormone production in breast cancer. *Indian J Exp Biol* 43: 35–39.
8. Ordi J, Bosch JA, Pigrau C, Tornos J, Ruibal A, Saigi E (1981) [Ectopic ACTH secretion syndrome in a sigmoid neoplasia: an infrequent association]. *Rev Clin Esp* 163: 285–286.
9. Eggenberger C, Brandle M, Galeazzi RL, Spinas GA, Schmid C (1999) [Cushing syndrome due to ectopic ACTH secretion: an uncommon case presentation, diagnosis and therapy]. *Schweiz Med Wochenschr* 129: 890–895.
10. Rickman T, Garmany R, Doherty T, Benson D, Okusa MD (2001) Hypokalemia, metabolic alkalosis, and hypertension: Cushing's syndrome in a patient with metastatic prostate adenocarcinoma. *Am J Kidney Dis* 37: 838–846.
11. Fish SA TE, Iqbal N, *et al.* (2001) Ectopic production of ACTH by olfactory neuroblastoma. The Endocrine Society's 83th Annual Meeting, USA, 15 (Abstract)
12. Yu J, Koch CA, Patsalides A, Chang R, Altemus RM, Nieman LK, Pacak K (2004) Ectopic Cushing's syndrome caused by an esthesioneuroblastoma. *Endocr Pract* 10: 119–124.
13. Reznik M, Melon J, Lambricht M, Kaschten B, Beckers A (1987) [Neuroendocrine tumor of the nasal cavity (esthesioneuroblastoma). Apropos of a case with paraneoplastic Cushing's syndrome]. *Ann Pathol* 7: 137–142.
14. Arnesen MA, Scheithauer BW, Freeman S (1994) Cushing's syndrome secondary to olfactory neuroblastoma. *Ultrastruct Pathol* 18: 61–68.
15. Kanno K, Morokuma Y, Tateno T, Hirano Y, Taki K, Osamura RY, Hirata Y (2005) Olfactory neuroblastoma

- ma causing ectopic ACTH syndrome. *Endocr J* 52: 675–681.
16. Kadish S, Goodman M, Wang CC (1976) Olfactory neuroblastoma. A clinical analysis of 17 cases. *Cancer* 37: 1571–1576.
 17. Dulguerov P, Allal AS, Calcaterra TC (2001) Esthesioneuroblastoma: a meta-analysis and review. *Lancet Oncol* 2: 683–690.
 18. Muller OA, von Werder K (1992) Ectopic production of ACTH and corticotropin-releasing hormone (CRH). *J Steroid Biochem Mol Biol* 43: 403–408.
 19. Ozawa Y, Tomoyasu H, Takeshita A, Shishiba Y, Yamada S, Kovacs K, Matsushita H (1996) Shift from CRH to ACTH production in a thymic carcinoid with Cushing's syndrome. *Horm Res* 45: 264–268.
 20. Saeger W, Reincke M, Scholz GH, Lüdecke DK (1993) [Ectopic ACTH- or CRH-secreting tumors in Cushing's syndrome] *Zentralbl Pathol* 139: 157–163 (abstract).
 21. White A, Gibson S (1998) ACTH precursors: biological significance and clinical relevance. *Clin Endocrinol (Oxf)* 48: 251–255.
 22. Espinasse-Holder M, Defachelles AS, Weill J, De Keyser Y, de Lasalle EM, Nelken B (2000) Paraneoplastic Cushing syndrome due to adrenal neuroblastoma. *Med Pediatr Oncol* 34: 231–233.
 23. Raux Demay MC, Proeschel MF, de Keyser Y, Bertagna X, Luton JP, Girard F (1988) Characterization of human corticotrophin-releasing hormone and pro-opiomelanocortin-related peptides in a thymic carcinoid tumour responsible for Cushing's syndrome. *Clin Endocrinol (Oxf)* 29: 649–657.
 24. Newell-Price J, Trainer P, Besser M, Grossman A (1998) The diagnosis and differential diagnosis of Cushing's syndrome and pseudo-Cushing's states. *Endocr Rev* 19: 647–672.
 25. Oldfield EH, Doppman JL, Nieman LK, Chrousos GP, Miller DL, Katz DA, Cutler GB Jr, Loriaux DL (1991) Petrosal sinus sampling with and without corticotropin-releasing hormone for the differential diagnosis of Cushing's syndrome. *N Engl J Med* 325: 897–905.
 26. Hernandez I, Espinosa-de-los-Monteros AL, Mendoza V, Cheng S, Molina M, Sosa E, Mercado M (2006) Ectopic ACTH-secreting syndrome: a single center experience report with a high prevalence of occult tumor. *Arch Med Res* 37: 976–980.
 27. Wiggam MI, Heaney AP, McIlrath EM, McCance DR, Sheridan B, Hadden DR, Atkinson AB (2000) Bilateral inferior petrosal sinus sampling in the differential diagnosis of adrenocorticotropin-dependent Cushing's syndrome: a comparison with other diagnostic tests. *J Clin Endocrinol Metab* 85: 1525–1532.
 28. Auphan N, DiDonato JA, Rosette C, Helmberg A, Karin M (1995) Immunosuppression by glucocorticoids: inhibition of NF-kappa B activity through induction of I kappa B synthesis. *Science* 270: 286–290.
 29. Delisle L, Boyer MJ, Warr D, Killinger D, Payne D, Yeoh JL, Feld R (1993) Ectopic corticotropin syndrome and small-cell carcinoma of the lung. Clinical features, outcome, and complications. *Arch Intern Med* 153: 746–752.
 30. Orth DN (1995) Cushing's syndrome. *N Engl J Med* 332: 791–803.
 31. You XJ, Draf W, Bockmuhl U (2003) [Management of esthesioneuroblastoma of the Fulda surgical concept]. *Zhonghua Er Bi Yan Hou Ke Za Zhi* 38: 206–209.
 32. Hearn PR, Reynolds CL, Johansen K, Woodhouse NJ (1998) Lung carcinoid with Cushing's syndrome: control of serum ACTH and cortisol levels using SMS 201-995 (sandostatin). *Clin Endocrinol (Oxf)* 28: 181–185.
 33. Bertagna X, Favrod-Coune C, Escourolle H, Beuzeboc P, Christoforov B, Girard F, Luton JP (1989) Suppression of ectopic adrenocorticotropin secretion by the long-acting somatostatin analog octreotide. *J Clin Endocrinol Metab* 68: 988–991.
 34. De Rosa G, Testa A, Liberale I, Pirroni T, Granone P, Picciocchi A (1993) Successful treatment of ectopic Cushing's syndrome with the long-acting somatostatin analog octreotide. *Exp Clin Endocrinol* 101: 319–325.
 35. de Herder WW, Lamberts SW (1996) Is there a role for somatostatin and its analogs in Cushing's syndrome? *Metabolism* 45: 83–85.
 36. Phlipponneau M, Nocaudie M, Epelbaum J, De Keyser Y, Lalau JD, Marchandise X, Bertagna X (1994) Somatostatin analogs for the localization and preoperative treatment of an adrenocorticotropin-secreting bronchial carcinoid tumor. *J Clin Endocrinol Metab* 78: 20–24.