

Evaluation of fast green FCF dye for non-lethal detection of integumental injuries in juvenile Chinook salmon *Oncorhynchus tshawytscha*

Diane G. Elliott*, Carla M. Conway, LynnMarie J. Applegate

US Geological Survey, Western Fisheries Research Center, 6505 Northeast 65th Street, Seattle, Washington 98115, USA

ABSTRACT: A rapid staining procedure for detection of recent skin and fin injuries was tested in juvenile Chinook salmon *Oncorhynchus tshawytscha*. Immersion of anesthetized fish for 1 min in aerated aqueous solutions of the synthetic food dye fast green FCF (Food Green 3) at concentrations of 0.1 to 0.5 % produced consistent and visible staining of integumental injuries. A 0.1 % fast green concentration was satisfactory for visual evaluation of injuries, whereas a 0.5 % concentration was preferable for digital photography. A rinsing procedure comprised of two 30 s rinses in fresh water was most effective for removal of excess stain after exposure of fish. Survival studies in fresh water and seawater and histopathological analyses indicated that short exposures to aqueous solutions of fast green were non-toxic to juvenile Chinook salmon. In comparisons of the gross and microscopic appearance of fish exposed to fast green at various times after injury, the dye was observed only in areas of the body where epidermal disruption was present as determined by scanning electron microscopy. No dye was observed in areas where epidermal integrity had been restored. Further comparisons showed that fast green exposure produced more consistent and intense staining of skin injury sites than a previously published procedure using trypan blue. Because of its relatively low cost, ease of use and the rapid and specific staining of integumental injuries, fast green may find widespread application in fish health and surface injury evaluations.

KEY WORDS: Skin injury detection · Integument · Fast green · Trypan blue · Non-lethal test · Salmonid

—Resale or republication not permitted without written consent of the publisher—

INTRODUCTION

Scale loss (descaling) is a primary criterion used to assess physical damage to salmonid smolts migrating through fish bypass systems at hydroelectric dams, and in fish subjected to handling procedures at dams or hatcheries (US Army Corps of Engineers, Walla Walla District 1985, Kostecki et al. 1987, Ceballos et al. 1992, Gadomski et al. 1994, Congleton et al. 1999). However, evaluation of descaling by gross observation may not provide an accurate representation of the degree of tissue damage or stage of healing in a fish. Damage to the transparent epidermal tissue and mucous layer external to the scales often cannot be discerned by gross observation, and evidence indicates that intact epidermal and mucous layers of skin are important in salmonids and other fish species for preventing the

entry and establishment of pathogens (Sakai 1979, Roberts & Bullock 1980, Crouse-Eisnor et al. 1985, Elliott 1985, Ventura & Grizzle 1987, Kanno et al. 1989, Xu & Rogers 1991, Turnbull et al. 1996, Svendsen & Bøgwald 1997, Quiniou et al. 1998, Martinez et al. 2004). Furthermore, epidermal healing occurs long before scale regeneration becomes apparent by gross inspection. Whereas the closure of small (1 to 5 mm) wounds in salmonid skin by migrating epidermal cells is generally completed within 3 to 24 h depending on water temperature (Anderson & Roberts 1975, Bullock & Roberts 1980, Hickey 1982, Roubal & Bullock 1988), scale regeneration may not be evident for a minimum of 8 to 10 d after wounding (Blair 1942, Anderson & Roberts 1975). Thus, the absence of scales observed on a fish may be indicative of injury that occurred prior to the putative injurious event or process being investi-

*Email: diane_elliott@usgs.gov

gated. Finally, quantification of scale loss in salmonids is not useful for evaluating damage to non-scaled areas such as the fins or head, which can also provide portals for a variety of pathogens (Neish 1977, Schneider & Nicholson 1980, Kanno et al. 1989, Yamamoto et al. 1992, Turnbull et al. 1996, Elliott & Pascho 2001, Martinez et al. 2004).

Histological analysis can reveal injuries not visible by gross observation (Kostecki et al. 1987), but histological procedures are time-consuming, costly, and usually require lethal sampling of fish. Kiryu & Wakabayashi (1999) employed the principle of membrane permeability dye exclusion (Freshney 2000) to rapidly distinguish areas of fish skin containing dead or injured cells with permeable membranes from areas of living cells. Because the healthy epidermis of salmonids and most other teleosts is a living tissue throughout all its layers (Whitaker 1987, Elliott 2000), Kiryu & Wakabayashi (1999) reasoned that a bath exposure of rainbow trout *Oncorhynchus mykiss* to an exclusion dye would reveal sites of injury on the skin surface. A 10 min exposure of the fish to an aqueous solution of 0.05% trypan blue, a commonly used cell viability stain (O'Brien & Gottlieb-Rosenkrantz 1970, Freshney 2000), dyed areas of damaged skin and enabled the authors to detect minute skin injuries with the aid of a microscope. More recently, Noga & Udomkusonsri (2002) showed that exposure of rainbow trout for 3 min to the hydroxanthene dye fluorescein at concentrations as low as 0.1 mg ml⁻¹ could be used as a sensitive method to pinpoint skin ulcers in the fish.

The objective of the present study was to develop a rapid, non-lethal exclusion dye procedure that could be used in conjunction with descaling evaluations for detecting recent skin injuries in salmonids sampled in the field or at facilities such as hydroelectric dams and fish culture operations. Because trypan blue is a confirmed teratogen (Beck 1979, Gulamhusein et al. 1982) and carcinogen (Ford & Becker 1982) in rodents and a possible human carcinogen (International Agency for Research on Cancer 1975), it is not suitable for widespread use outside the laboratory environment. Fluorescein is commonly used to detect ophthalmic lesions in humans and animals, and has also been determined to be non-toxic to hybrid striped bass (*Morone saxatilis* male × *M. chrysops* female) at exposures of up to 0.5 mg ml⁻¹ for 12 min (Noga & Udomkusonsri 2002). Nevertheless, because the identification of areas of skin injury in fish exposed to fluorescein requires examination of the fish in darkness with the aid of an ultraviolet light, it may not be practical for evaluation of skin injury in many field situations. In addition, the fluorescence of fluorescein can be quenched by subsequent exposure to tricaine anesthetic, leading to false-negative reactions (Davis & Ottmar 2006, Davis et al. 2008).

The present study examined the quality of staining produced by short exposures of experimentally skin-injured juvenile Chinook salmon *Oncorhynchus tshawytscha* to fast green FCF, a synthetic food dye (Food Green 3) that has been used as an exclusion dye for viability testing of mammalian cells (Weisenthal et al. 1983, Glavin et al. 1996). Fast green has also been used as a non-lethal marker for individual identification of small arthropods in laboratory and field studies (Smith & Present 1983, Seely & Lutnesky 1998, Atkinson et al. 2004). Preliminary experiments were done to compare fast green staining to trypan blue staining for detection of skin injury sites by gross observation, but further testing was done with fast green only. The toxicity of short exposures to fast green was investigated in experimentally injured and uninjured Chinook salmon smolts held in fresh water and seawater for 6 wk post-exposure. In addition, the gross and microscopic appearance of experimental skin injuries were compared in juvenile Chinook salmon exposed to fast green at various times after injury.

MATERIALS AND METHODS

Experimental fish and study sites. Juvenile fall Chinook salmon obtained as eyed eggs from several sources (Table 1) were used in these experiments. Fish were reared under natural photoperiod to the appropriate age or size for experiments at the Western Fisheries Research Center (WFRC) of the US Geological Survey (USGS), Seattle, WA, where they were maintained in aerated single-pass, sand-filtered, UV-treated Lake Washington water. All freshwater experiments were conducted in this facility. During the experiments, fish were fed to satiation with a commercial semi-moist pelleted diet (BioOregon) 3 d wk⁻¹. Feed was withheld 24 h before experimental manipulations or sampling. Water temperature in experimental tanks was monitored at 1 h intervals using Optic Stowaway temperature loggers (Onset Computer).

Seawater research was performed at the USGS Marrowstone Marine Station (MMS), Nordland, WA. Experimental tanks were supplied with aerated single-pass seawater from Puget Sound that was treated by sand filtration and UV irradiation before use. Water temperature was monitored using Optic Stowaway loggers as described above, and feeding of fish was the same as for freshwater experiments. All experiments with fish were conducted in accordance with institutional, national and international guidelines concerning the use of animals in research.

Preparation of stain solutions. Solutions of fast green FCF (Food Green 3, Color Index #42053, CAS #2353-45-9) and trypan blue (Color Index #23850, CAS

Table 1. *Oncorhynchus tshawytscha*. Sources of juveniles used in the present study

Source	Experiment	Mean fork length \pm SD (mm)	Mean weight \pm SD (g)
Kettle Moraine Springs Hatchery ^a	Comparison of fast green FCF and trypan blue staining	185 \pm 9	66.9 \pm 12.3
Abernathy Salmon Technology Center ^b	Toxicity of fast green FCF	81 \pm 11	6.6 \pm 2.4
	Gross and microscopic appearance of fish exposed to fast green FCF	133 \pm 11	30.2 \pm 7.8
Soos Creek Hatchery ^c	Optimization of fast green FCF staining	103 \pm 12	13.3 \pm 3.6

^aWisconsin Department of Natural Resources, Adell, WI, USA
^bUS Fish and Wildlife Service, Longview, WA, USA
^cWashington Department of Fish and Wildlife, Auburn, WA, USA

#72-57-1) (both obtained from Polysciences) were prepared in deionized tap water. Before use, the temperature of each stain solution was adjusted to within 1°C of the ambient water temperature for the appropriate treatment group. Mean pH values at 12°C were 6.11 and 9.30 for 0.1 % (by weight) fast green and 0.05 % (by weight) trypan blue solutions, respectively.

Skin injury procedure. For the various experiments, descaling injuries encompassing ~10% of the total body surface of each fish were produced. The total surface area (mm²) was first calculated from the mean fork length (FL, mm) according to the formula of Gadomski et al. (1994) for juvenile Chinook salmon:

$$\text{Surface area of fish} = 0.13 \text{ FL}^2 - 207.8$$

The amount of surface area to be descaled on a fish was then calculated for each experimental group.

Fish to be subjected to skin injuries were placed in an anesthetic bath containing 60 mg l⁻¹ tricaine methanesulfonate (MS-222; Argent Chemical Laboratories) buffered to ~pH 6.8 with sodium bicarbonate, until loss of equilibrium was observed. Each anesthetic solution was prepared with water at the same temperature as the corresponding test or control tank. Fish were placed on their sides on a moist paper towel and skin injuries were made using the stirring portion of a plastic stirring stick (Sarstedt) cut to form a blunt end ~3 mm wide. The skin was scraped 5× in a posterior-to-anterior direction to remove epithelium and scales from a given injury location. On a given side of a fish, 2 injuries of equal dimensions were made, one dorsal and the other ventral to the lateral line between the anterior edge of the dorsal fin and the adipose fin. This resulted in injuries to both the darker-pigmented area (upper injury) and the silvery area of the body (lower injury). To descale 10% of the surface area, injuries were made on the right side only or on both sides, depending on the experiment.

Comparison of fast green FCF and trypan blue staining. An experiment was done to compare the effi-

cacy of aqueous solutions of fast green FCF and trypan blue for staining sites of recent skin injury. Initial testing of fast green FCF indicated that aqueous concentrations between 0.05 and 1.0% and staining times between 1 and 10 min produced visible staining of experimental skin injuries in juvenile Chinook salmon at 12°C, and resulted in no mortality of fish held for 96 h after staining. Based on the visibility of the stain and ease of removing excess stain by rinsing, a concentration of 0.1% aqueous fast green FCF was selected for the comparison with trypan blue. The trypan blue concentration selected was 0.05%, which is the same concentration used by Kiryu & Wakabayashi (1999) for staining surface injuries of rainbow trout. At WFRC, a preliminary exposure of juvenile Chinook salmon with experimental skin injuries to 0.05% aqueous trypan blue for 10 min at 12°C resulted in no mortality of fish held for 96 h after staining.

Juvenile Chinook salmon were randomly assigned to test or control groups. Fish in all groups were subjected to descaling injuries totaling 10% of their surface area, then exposed to either trypan blue, fast green, or no dye (control group). Fish were anesthetized and 2 longitudinal injuries ~71 × 3 mm each were made on the right side of each fish according to the procedure previously described. Immediately following the descaling procedure, fish were placed in either fast green FCF or trypan blue dye solution (or water for non-dyed controls) at 12°C. Six fish were exposed to fast green FCF or trypan blue at each selected concentration for 1 or 10 min. Control fish (6 group⁻¹) were exposed to water for 1 or 10 min. After dye or water exposure, fish were removed and placed in clean, fresh, 12°C water for a 1 min rinse. Aeration was supplied to dye baths, control water baths, and rinse water baths. Fish were sacrificed by an overdose of anesthetic (120 mg l⁻¹ MS-222 buffered to pH 6.8 with sodium bicarbonate).

After the staining procedure was completed, fish were distributed by random assignment into individual

numbered trays for stain evaluation by a blind system. Staining efficacy in each injury site (upper and lower) on each fish was evaluated visually by 9 independent observers and given a score of 1 to 4, according to the intensity of the stain (1 = no stain, 2 = faintly stained, 3 = moderately stained, 4 = strong staining). The presence of excess dye that was not adequately rinsed from the skin was also noted, as was the presence of dye in areas other than the intentional injury sites. The non-parametric Mann-Whitney test (2 groups) and Kruskal-Wallis test (multiple groups) were used to compare stain ratings for the various test and control groups. The Friedman test was used to examine the data for differences in stain ratings among observers.

Toxicity of fast green FCF to Chinook salmon smolts. An experiment was performed to determine the toxicity of short-term immersion in fast green to skin-injured and uninjured Chinook salmon smolts held in fresh water or seawater after injury and dye exposure. A total of 3312 fish were randomly separated into 12 test or control groups (Table 2). Each group was distributed equally between 2 replicate 76 l cylindrical tanks at a fish loading density of 6 g l⁻¹.

Fish in descaled groups were anesthetized and 2 longitudinal injuries ~12 × 3 mm each were made on the right side of each fish as previously described, resulting in descaling of 10% of the body surface. Fish in non-descaled groups were anesthetized but not subjected to intentional skin injury. Immediately following the anesthetization and descaling procedures, fish were placed into freshly prepared fast green FCF solution at 0.1 or 0.5 % (or water for non-dyed controls) for 1 or 2 min, then into fresh water for a 1 min rinse. Aeration was supplied to dye and water baths, and the temperature was maintained at 12°C. Behavior of fish (opercular movements or swimming activity) was monitored and recorded. After rinsing, fish were carefully poured back into the appropriate tanks to avoid further skin injury.

Seven days following skin injury and dye procedures, half of the fish (33 tank⁻¹) were removed by repeated dip-netting from each treatment and control group and transferred to the seawater facility (MMS) by truck. Fish were hauled in 114 l plastic containers (Rubbermaid Home Products) with fresh water and oxygenation at a loading density of 60 g l⁻¹. A separate container was used for each test or control group. Upon arrival at the MMS, fish from each group were distributed equally into 2 replicate 255 l tanks (loading density ~2 g l⁻¹) with fresh water (dechlorinated municipal water from Port Townsend, WA). Seawater acclimation was accomplished over 5 d by mixing flows of fresh water and seawater to achieve 1/3 seawater on Day 1, 2/3 seawater on Day 3 and full-strength seawater (30 ppt salinity) on Day 5.

Fish were held in seawater at a temperature of 11 ± 2°C. The remaining fish (33 tank⁻¹, 66 group⁻¹) were held in fresh water at a loading density of ~3 g l⁻¹ and a water temperature of 12 ± 1°C. Fish in both fresh water and seawater were monitored daily for behavioral abnormalities and mortality until the termination of the experiment at 6 wk post-injury. Total mortality among groups was compared using chi-square analysis.

Two fish from each tank were collected for histopathological analysis at 48 h and at 1, 2, 3, and 6 wk after treatment or control procedures. For examination using light microscopy, samples of representative tissues (skin, skeletal muscle, gill, thymus, liver, spleen, kidney, gastrointestinal tract, pancreas, and gonad, if visible) were fixed in Carson's modified Millonig phosphate-buffered formalin (Carson et al. 1973), processed according to standard protocols and embedded in paraffin wax. Sections were cut at 5 µm, stained with hematoxylin and eosin (H&E) and with May-Grünwald Giemsa (pH 6.0; Carson 1997), then examined microscopically for abnormalities. The chi-square test was used to compare the relative proportions of fish that exhibited a particular histopathological abnormality in test and control groups.

Comparison of gross and microscopic appearance of fish exposed to fast green FCF at various times after injury. Juvenile Chinook salmon (n = 60) were randomly separated into 3 cylindrical 76 l tanks at an initial loading density of ~8 g l⁻¹. Water temperature was adjusted to 13°C over a 1 wk period before the experiment began. Descaling injuries of 10% of the total body surface were made on both sides of each fish as previously described. Individual longitudinal injuries were 17 × 3 mm. Fish were replaced in the appropriate tanks until sampling, and were monitored daily for behavioral abnormalities and mortality until the termination of the experiment at 96 h post-injury.

Three fish (1 tank⁻¹) were collected for fast green staining and histological analysis at 0, 3, 6, 12, 18, 24, 36, 48, 72, and 96 h after injury. Fish were anesthetized in 80 mg l⁻¹ buffered MS-222 and placed in freshly prepared 0.1 % fast green FCF solution (or water for non-dyed controls) and dyed for 1 min, then rinsed in fresh water for 1 min. Aeration was supplied to dye and water baths.

Skin injuries were examined grossly for the presence or absence of stain, and the proportion of each injury site that was stained on each fish was recorded on a diagram. Stained areas outside the injury sites were also noted.

Fish were exsanguinated by severing the spinal cord immediately posterior to the opercula. A longitudinal section of skin (~20 × 15 mm) was carefully removed from the right side of each fish dorsal to (and including)

the lateral line. Skin sampled from descaled fish included intact epidermis dorsal and ventral to the uppermost descaled area. Samples were then trimmed to ~5 mm thick and halved vertically. Tissues were fixed for 48 h at 4°C in 2% paraformaldehyde and 2.5% glutaraldehyde in 0.1 M sodium cacodylate buffer (pH 7.5; Millonig 1976), then rinsed (2 rinses at 10 min each and 1 overnight rinse) with 4°C sodium cacodylate buffer and stored at 4°C in this buffer until processing for light or scanning electron microscopy.

For light microscopy, 1 piece of tissue from each fish was further trimmed to 9 (vertical) × 4 (horizontal) × 2 mm (thickness), and then processed and embedded in Technovit 7100 glycol methacrylate (GMA; 2-hydroxyethyl methacrylate; Energy Beam Sciences) according to the manufacturer's instructions. Sections were cut at 3 µm and stained with H&E and with May-Grünwald Giemsa (pH 7.2; Elliott 1985). Sections were examined microscopically for appearance of skin injuries and degree of healing.

For scanning electron microscopy, the remaining tissue from each fish was trimmed to ~13 (vertical) × 10 (horizontal) × 2 mm (thickness) and post-fixed for 1 h in 1% osmium tetroxide in 0.1 M sodium cacodylate buffer (pH 7.5; Powell et al. 1992). Tissues were dehydrated through a graded ethanol series, critical point dried with CO₂ in a DCP-1 critical point dryer (Denton Vacuum), and mounted on 13 mm diameter aluminum specimen mounts (Ted Pella) with Silver Paste Plus (SPI Supplies). Mounted specimens were coated with gold-palladium in an Emitech K550X sputter coater (Emitech Products), then examined with a JEOL 6360LV scanning electron microscope (Japan Electron Optics) at the Northwest Fisheries Science Center, National Marine Fisheries Service, NOAA, Seattle, WA.

Optimization of fast green FCF staining. An experiment was performed to determine optimum staining and rinsing procedures to provide maximum stain intensity within 1 to 2 min as determined by observer scores, combined with a minimum of excess stain diffusing from the injury site onto surrounding healthy tissue after rinsing.

For this experiment, juvenile Chinook salmon ($n = 54$) were randomly assigned to test and control groups. All fish were subjected to descaling injuries totaling 10% of their surface area, and then exposed to either fast green, or no dye (control group). Fish were anesthetized and 2 longitudinal injuries ~20 × 3 mm each were made on the right side of each fish according to the procedure previously described. Immediately following the descaling procedure, fish were placed in either fast green FCF at concentrations of 0.1, 0.3, or 0.5%, or in water for non-dyed controls, at 12°C. Six fish were exposed to fast green FCF at each selected concentration for 1 or 2 min. After dye exposure, fish

were removed and placed in clean, fresh, 12°C water for a 1 min rinse or for two 30 s rinses.

After the staining and rinsing were completed, fish were distributed by random assignment into individual numbered trays for stain evaluation by a blind system. Staining efficacy in each injury site (upper and lower) on each fish was evaluated visually by 5 independent observers and stain intensity was scored as previously described. The presence of excess dye that was not adequately rinsed from the skin was also noted. The Mann-Whitney and Kruskal-Wallis tests were used to compare stain ratings for the various test and control groups.

RESULTS

Comparison of fast green FCF and trypan blue staining of injury sites

Examples of staining of experimental skin injuries by fast green FCF (1 min) and trypan blue (10 min) are shown in Fig. 1. Both 0.1% fast green FCF and 0.05% trypan blue produced highly visible staining of injury sites within 1 min in comparison to the control that was exposed to water only ($p < 0.0001$), but staining was more intense at 10 min than at 1 min for both dyes ($p < 0.0001$). However, incomplete rinsing of fast green from the injury sites was noted for some fish stained for 10 min. Injury sites stained with 0.1% fast green FCF received significantly higher stain intensity scores than those stained with 0.05% trypan blue for both the 1 min ($p < 0.0001$) and 10 min ($p < 0.0002$) staining times. The ratings of stain intensity among observers were more consistent for fast green than for trypan blue at both staining times. The 9 observers detected no difference in injury site stain intensity among fish exposed to 0.1% fast green for either 1 min ($p = 0.52$) or 10 min ($p = 0.41$). In contrast, these observers recorded significant variation in stain intensity among fish exposed to 0.05% trypan blue for either 1 min ($p = 0.0006$) or 10 min ($p < 0.0001$).

For some fish in all stain groups, fast green or trypan blue was observed in small areas of the head, body and fins that had not been intentionally injured (Fig. 1). Based on the location and appearance of the staining, these stained areas were judged to be sites of inadvertent injury caused by netting or other handling.

Toxicity of fast green FCF to Chinook salmon smolts

Among the groups of fish held in fresh water for 6 wk after treatment, mortalities occurred only in the non-descaled control group exposed to water for 2 min, and



Fig. 1. *Oncorhynchus tshawytscha*. Appearance of juveniles exposed to trypan blue or fast green FCF immediately following intentional descaling injury. Top: trypan blue (0.05% aqueous solution for 10 min according to the procedure of Kiryu & Wakabayashi 1999); middle: fast green FCF (0.1% aqueous solution for 1 min); and bottom: fast green FCF (0.5% aqueous solution for 1 min). All fish were given two 30 s rinses in fresh water after dye exposure. Arrows mark staining of sites of unintentional integumental injury

the non-descaled group exposed to 0.1% fast green for 2 min (Table 2). Mortality did not exceed 4% in either group. For the groups of fish transferred and held in seawater, mortality was higher, ranging from 13 to 27% (Table 2). Comparison of the non-dye-exposed control groups in the seawater experiment indicated that the occurrence of mortality was independent of whether the fish were descaled or not ($p = 0.6$). Further comparison of non-descaled groups that were exposed to either no dye or to 0.1% or 0.5% fast green indicated that the occurrence of mortality was independent of the treatment type for both the 1 min ($p = 0.2$) and 2 min ($p = 0.2$) exposure groups. The combined effects of dye exposure and descaling on mortality were also investigated. For the descaled groups exposed for 1 min

Table 2. *Oncorhynchus tshawytscha*. Mortality in groups of descaled (10% descaling injury) and non-descaled Chinook salmon smolts exposed to 0.1 or 0.5% aqueous solutions of fast green FCF for 1 or 2 min at 12°C, subsequently monitored in fresh water ($12 \pm 1^\circ\text{C}$) or acclimated to seawater ($11 \pm 2^\circ\text{C}$) and held for 6 wk following treatment. D: descaled, ND: non-descaled

Descaling injury	Fast green FCF concentration ^a (%)	Fast green exposure time (min)	Mortality: no. dead/total (%)	
			Freshwater	Seawater
D	–	1 ^b	0/120	21/120 (17)
ND	–	1 ^b	0/120	22/121 (18)
D	–	2 ^b	0/120	15/120 (13)
ND	–	2 ^b	5/120 (4)	18/117 (15)
D	0.1	1	0/120	19/118 (16)
ND	0.1	1	0/120	32/120 (27)
D	0.1	2	0/120	32/120 (27)
ND	0.1	2	2/120 (2)	22/114 (19)
D	0.5	1	0/120	22/119 (19)
ND	0.5	1	0/120	32/120 (27)
D	0.5	2	0/120	15/119 (13)
ND	0.5	2	0/120	29/120 (24)

^aAqueous concentration of fast green FCF by weight

^bControl fish were exposed to water only

to no dye or to fast green at 0.1 or 0.5 % concentrations, mortality was independent of treatment ($p = 0.9$). For the descaled groups exposed for 2 min to no dye or to fast green, mortality was higher among fish exposed to 0.1 % fast green than among fish exposed to either no dye or to 0.5 % fast green ($p = 0.004$). However, the group exposed to 0.1 % fast green for 2 min was the only group in the experiment for which mortality differed significantly between tanks ($p = 0.04$). No difference in mortality was observed between the descaled group exposed to no dye and that exposed to 0.5 % fast green for 2 min ($p > 0.9$).

Histopathological analysis of fish in the toxicity experiment revealed degeneration and necrosis of skeletal muscle beneath the descaling injury sites in some fish examined from all groups 48 h after descaling. However, there was no significant difference ($p = 0.57$) in the proportions of fish exhibiting the muscle lesion between control and fast green-exposed groups. Regeneration of skeletal muscle occurred in all groups, and by 6 wk after descaling, muscle regeneration was nearly complete in all fish. Regeneration of the epidermis, dermis and scales in the descaling site also appeared to proceed normally in all groups. No abnormalities associated with fast green dye were observed in other tissues or organs of fish from either the descaled or non-descaled groups.

Comparison of gross and microscopic appearance of fish exposed to fast green FCF at various times after injury

In areas of intentional descaling injury, fast green dye was only observed where epidermal disruption was present as determined by scanning electron microscopy (Table 3, Fig. 2A–C). In areas where empty scale pockets had been covered by migrating epithelial cells and epidermal integrity had been restored, no dye was observed (Fig. 2D–F). This was particularly evident at later time points (≥ 12 h, Table 3). Examination of cross sections of descaling sites by light microscopy confirmed the scanning electron microscopy findings (data not shown). Dye was occasionally observed in areas outside the descaling sites (Table 3, Fig. 3A). These were likely sites of unintentional injury caused by netting or other handling, as indicated by the observation of epidermal disruption by scanning electron microscopy (Fig. 3B,C).

Optimization of fast green FCF staining

In general, the stain intensity ratings for skin-injured fish increased as the fast green concentration in-

Table 3. *Oncorhynchus tshawytscha*. Numbers of fish showing presence of integumental injury (disruption of epidermis as viewed by scanning electron microscopy) and fast green FCF dye in areas of intentional descaling in juveniles that were maintained at 13°C in fresh water and exposed to fast green FCF (0.1% for 1 min) at various times after a 10% descaling injury

Sampling time post-injury (h)	Number of fish (of 3 total)	
	Epidermal injury present	Dye present
0	3	3
3	3	3
6	3	3
12	1	1
18	2	2
24	2	2
36	1	1
48 ^a	2	2
72	1	1
96	0	0

^aInjuries were also observed on 2 fish in areas of the body, head or fins where no intentional injury had been applied. Fast green dye was visible in these areas

creased from 0.1 to 0.3 or 0.5 %, or as the staining time increased from 1 to 2 min. The only staining protocols that resulted in the majority of fish receiving the highest possible stain intensity ratings from all observers combined were: 0.3 % fast green for 2 min, 0.5 % fast green for 1 min, and 0.5 % fast green for 2 min. The overall stain intensity scores were higher ($p = 0.007$) for fish exposed to 0.5 % fast green for 2 min compared with fish exposed to 0.3 % fast green for 2 min. However, no difference in overall stain intensity scores was observed ($p = 0.3$) between fish exposed to 0.5 % fast green for 1 min and those exposed to 0.3 % fast green for 2 min. For most fast green exposure groups, a rinsing procedure comprised of two 30 s rinses (as opposed to a single 1 min rinse) appeared to be effective for greatly reducing or eliminating the presence of excess dye that diffused from the injury sites onto uninjured tissue. The exception was the group exposed to 0.5 % fast green for 2 min; the presence of excess dye was reported for the majority of fish in this group.

DISCUSSION

This study showed that fast green FCF is a useful tool for rapid detection of recent epidermal injury in juvenile Chinook salmon. Fast green exposure produced more consistent and visible staining of integumental injuries than the procedure of trypan blue staining published by Kiryu & Wakabayashi (1999). Because fast green staining allows visual identification of skin injury without the need for ultraviolet illumination, it is

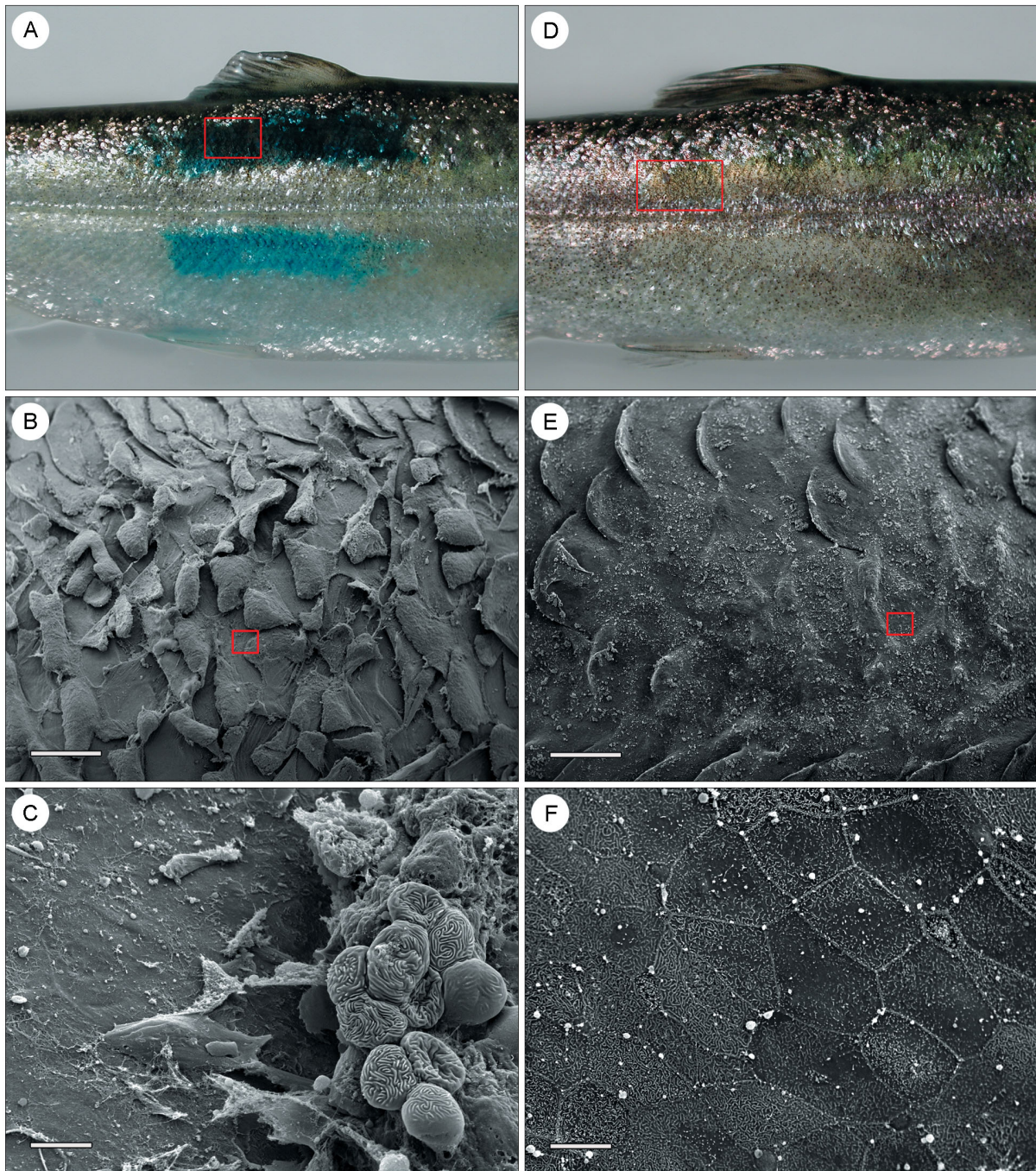


Fig. 2. *Oncorhynchus tshawytscha*. Appearance of juveniles exposed to 0.1% aqueous fast green FCF for 1 min following intentional descaling injury. (A to C) Appearance of descaling site exposed to fast green FCF immediately following injury: (A) gross appearance of descaling site, showing loss of scales and presence of fast green staining; (B) scanning electron micrograph of descaling area delimited by box in (A), showing epidermal disruption and empty scale pockets. Scale bar = 500 μ m; and (C) higher magnification scanning electron micrograph of area delimited by box in (B), showing rounded epithelial cells prior to sloughing (right). Surface microridges are still visible on some cells. Exposed tissue of the dermis (empty scale pocket) is visible at left. Scale bar = 10 μ m. (D to F) Appearance of descaling site exposed to fast green FCF 24 h after injury: (D) gross appearance of descaling site, showing lack of scales but absence of fast green staining; (E) scanning electron micrograph of descaling area delimited by box in (D), showing restoration of epidermal integrity. Sloughing cellular debris is still visible on the epidermal surface. Scale bar = 500 μ m; and (F) higher magnification scanning electron micrograph of area delimited by box in (E), showing individual epithelial cells that have migrated to cover the injury site. Surface microridges are visible on the epithelial cells. Scale bar = 10 μ m

more practical for field use than the fluorescein staining procedure of Noga & Udomkusonsri (2002).

Microscopic analyses demonstrated that fast green only stained areas with epidermal disruption; intact epidermis was not dyed. Similar results were seen in additional experiments (D. G. Elliott & C. M. Conway unpubl.) conducted at lower and higher temperatures (8 and 18°C) and in fish with descaling injuries encompassing larger areas (20 and 30%) of the body surface. In all of these studies, fast green stain was retained by tissues fixed in paraformaldehyde-glutaraldehyde and held in cacodylate buffer, and this facilitated correspondence of dyed areas identified by gross observation with areas of epidermal disruption identified by scanning electron microscopy.

A study of freshwater and seawater survival of experimentally descaled and non-descaled Chinook salmon smolts indicated that fast green did not affect survival or result in histopathological abnormalities in fish when used at effective staining concentrations and exposure times. Nevertheless, it is unknown whether the temporary presence of the dye could increase the vulnerability to predation of fish released directly into the environment shortly after staining. Toxicity of the dye and efficacy of fast green staining should also be tested in other fish species.

During preliminary testing of digital photography for image analysis of stained skin injuries on fish, a need for further optimization of the staining method was noted. The 0.1% fast green concentration used for 1 min exposures during initial studies was adequate for visual inspection and recording of approximate sizes and locations of stained areas on diagrams representing both sides of a fish. However, the staining intensity appeared reduced in digital photographs, making differentiation of stained and non-stained areas by digital methods difficult. Nevertheless, use of higher dye concentrations frequently resulted in continued diffusion of excess stain from injury sites onto adjacent non-injured tissue even after rinsing. The optimization experiment revealed that exposure of fish to 0.5% fast green FCF for 1 min was sufficient to produce maximum stain intensity with minimal excess stain remaining after rinsing. This staining protocol was ideal for capturing accurate digital photographic images of injury sites for subsequent image analysis to measure proportion of wound coverage on a fish. Nevertheless, exposure of fish to fast green FCF concentrations as low as 0.1% for 1 min was sufficient for visual observation and recording of presence, location(s) and approximate extent of integumental injury. Because a single static rinse bath quickly became darkly colored by dye that washed off from the fish, two 30 s rinses in 2 separate freshwater baths were better than a single 1 min rinse for removing excess stain. A flowing water rinse

would be superior to static rinses for elimination of excess dye.

Due to its relatively low cost (~US\$1.50 to 3.00 to stain at least 30 to 40 fish at the 0.1% concentration), ease of use and the rapid and specific staining of

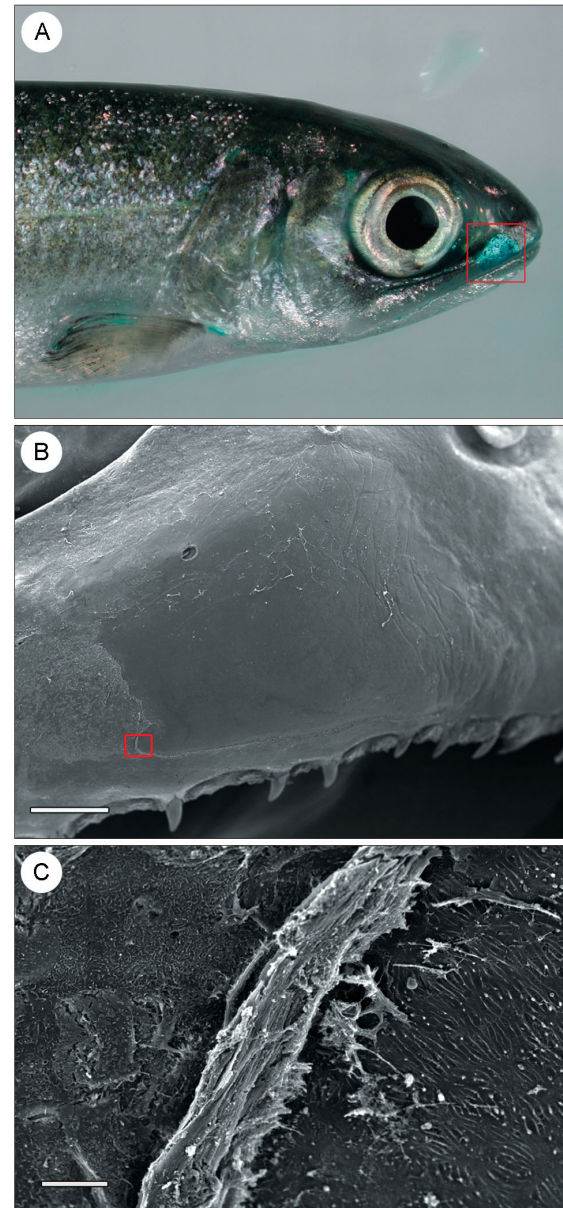


Fig. 3. *Oncorhynchus tshawytscha*. Appearance of juveniles exposed to 0.1% fast green FCF for 1 min, 3 h after intentional descaling injury. (A) Gross appearance of maxilla showing presence of fast green staining in an area of unintentional integumental injury; (B) scanning electron micrograph of area delimited by box in (A), showing disruption of epidermal tissue (scale bar = 500 μ m); and (C) higher magnification scanning electron micrograph of area delimited by box in (B), showing folded and sloughing epidermis (center). Intact epidermis (left) and exposed dermis (right) are also visible. Scale bar = 10 μ m

integumental injuries, fast green may find widespread application in fish health and surface injury evaluations. This dye is currently being used in studies to determine the comparative amounts of integumental injury associated with different fish handling and marking procedures, and to identify procedures or equipment associated with excessive amounts of injury, so that corrective measures can be taken. For some of these studies, digital photography of dye-exposed fish is being combined with computerized image analysis to calculate the total area of integumental damage occurring on individual fish. Briefly, photo-editing software (e.g. Adobe Photoshop 7.0, Adobe Systems) is first used for enhancement and selection of green hues within an appropriate tolerance level to identify areas of fast green staining corresponding to integumental injury in digital photographs of each side of a fish. Then, the bitmap files are transferred to an image analysis program (e.g. Image-Pro Plus, Media Cybernetics) to measure the proportion of green staining coverage, which corresponds to the proportion of surface area that has sustained integumental injuries. Similar analytical procedures have been used with fluorescein dye treatment to quantify surface abrasion in flatfish and roundfish towed in nets (Davis & Ottmar 2006), and provide a more accurate measurement of wound coverage than can be attained by visual scoring methods alone. However, internal injuries such as hemorrhages cannot be detected by surface injury staining with dyes such as fluorescein or fast green, and the depth of integumental wounds is not assessed by current image analysis procedures.

Fast green staining may also be valuable for studies investigating the mechanisms of waterborne transmission of fish pathogens. For example, the dye is being used in research on the role of skin injury in horizontal transmission of the bacterial kidney disease (BKD) agent *Renibacterium salmoninarum*, which is an important cause of morbidity and mortality of Pacific salmon (*Oncorhynchus* spp.) in the Pacific Northwest USA (Fryer & Lannan 1993). Evidence shows that anadromous salmonids infected with the bacterium while in fresh water may die of BKD during downstream migration (Pascho et al. 1993) or after entry into seawater (Banner et al. 1986, Sanders et al. 1992, Elliott et al. 1995). *R. salmoninarum* is shed into water by infected fish (McKibben & Pascho 1999), and can become concentrated in recirculating water systems used for anesthetization of fish for sorting and marking procedures in hatcheries or at hydroelectric dams. Results of one study indicated that transmission of *R. salmoninarum* can be enhanced by coded wire-tag implantation in the snouts of fish (Elliott & Pascho 2001), whereas other studies have shown that *R. salmoninarum* infections can be established via entry

into the skin or eye (Hendricks & Leek 1975, Hoffmann et al. 1984). Nevertheless, the contribution of integumental injury to the success of waterborne transmission of the bacterium is unknown. The first interaction between a pathogenic bacterium and the host involves attachment to a cell or tissue surface at the portal of entry (Mims et al. 2001). Because surface injuries have been reported to be principal sites for adherence of a variety of bacteria on the skin and fins of fish (Schneider & Nicholson 1980, Crouse-Eisnor et al. 1985, Elliott 1985, Ventura & Grizzle 1987, Speare & Mirsalimi 1992, Turnbull et al. 1996, Svendsen & Bøgwald 1997, Martinez et al. 2004), fast green staining of injury sites may facilitate studies of interactions between bacteria and host fish cells, to develop a better understanding of the role of integumental injury and disease pathogenesis.

In using this dye for fish skin injury evaluations, human safety precautions and proper disposal procedures must be observed in accordance with applicable local and national regulations. Fast green FCF (under the name FD&C Green 3) is certified in the USA by the Food and Drug Administration as a color additive for food, drug, and cosmetic use (Center for Food Safety and Applied Nutrition 2008). However, because of uncertainties about human health effects, fast green FCF is not a permitted food additive in the European Union and certain other countries according to European Parliament and Council Directive 94/36/EC (European Commission, Food and Food Safety 2008). Therefore, use of this dye on fish intended for direct human consumption may not be allowed in some countries. Information from studies in which toxicity, teratogenicity, mutagenicity and carcinogenicity of fast green FCF were tested have been summarized (IPCS Inchem 2008, Toxnet 2008); conflicting results have been obtained depending on the test system and methods used for evaluation. Studies on the ecotoxicology of this dye are lacking (Toxnet 2008).

Acknowledgements. This work was partly supported by US Army Corps of Engineers Contract W68SBV83009063 and by the US Geological Survey. We thank C. Stehr and B. Bill, NOAA/Northwest Fisheries Science Center, for electron microscopy consultation; M. W. Davis, NOAA/Hatfield Marine Science Center, and M. K. Purcell, WFRC, for helpful reviews of the manuscript; and B. Egenes, WFRC, for assistance with preparation of the photographic figures. We also thank the following employees and volunteers at WFRC and MMS for technical assistance with this project: S. Alcorn, Y. Arima, D. Chase, N. Elder, C. McKibben, A. Murray, R. Nelson, M. Purcell, J. Rolland, and R. Spinek. The use of trade, firm, or corporation names in this publication is for the information and convenience of the reader. Such use does not constitute an official endorsement or approval by the US Department of Interior or the US Geological Survey of any product or service to the exclusion of others that may be suitable.

LITERATURE CITED

- Anderson CD, Roberts RJ (1975) A comparison of the effects of temperature on wound healing in a tropical and temperate teleost. *J Fish Biol* 7:173–182
- Atkinson TH, King JE, Griffin AJ (2004) Fast green, a non-persistent dye marker for use in studying field populations of subterranean termites (Isoptera: Rhinotermitidae). *Sociobiology* 43:269–278
- Banner CR, Long JJ, Fryer JL, Rohovec JS (1986) Occurrence of salmonid fish infected with *Renibacterium salmoninarum* in the Pacific Ocean. *J Fish Dis* 9:273–275
- Beck F (1979) Trypan blue induced teratogenesis. In: Persaud TVN (ed) *Advances in the study of birth defects*, Vol. 1. Teratogenic mechanisms. University Park Press, Baltimore, MD, p 37–51
- Blair AA (1942) Regeneration of the scales of Atlantic salmon. *J Fish Res Board Can* 5:440–447
- Bullock AM, Roberts RJ (1980) Inhibition of epidermal migration in the skin of rainbow trout *Salmo gairdneri* Richardson in the presence of achromogenic *Aeromonas salmonicida*. *J Fish Dis* 3:517–524
- Carson FL (1997) *Histotechnology: a self-instructional text*. ASCP Press, Chicago, IL, p 106–107
- Carson FL, Martin JH, Lynn JA (1973) Formalin fixation for electron microscopy: a re-evaluation. *Am J Clin Pathol* 59:365–373
- Ceballos JR, Pettit SW, McKern JL (1992) Fish Transportation Oversight Team annual report – FY 1991. Transport operations on the Snake and Columbia rivers. NOAA Technical Memorandum NMFS F/NWR-31. US Department of Commerce, National Oceanic and Atmospheric Administration, National Marine Fisheries Service, Portland, OR
- Center for Food Safety and Applied Nutrition (2008) Summary of color additives listed for use in the United States in food, drugs, cosmetics and medical devices. US Food and Drug Administration, www.cfsan.fda.gov, accessed 26 Dec 2008
- Congleton JL, LaVoie WJ, Schreck CB, Fitzpatrick MS, Elliott DG (1999) Blood chemistry and performance indices for juvenile chinook salmon and steelhead descaled experimentally and during passage through fish bypasses at dams on the Snake River, Washington. In: Barry T, Barton B, MacKinlay D (eds) *Stress in fish*. Proc 3rd Int Congress on the Biology of Fishes, 27–30 Jul 2008, Baltimore, MD. Toxicology Information Response Center, Baltimore, MD, p 71–75
- Crouse-Eisnor RA, Cone DK, Odense PH (1985) Studies on relations of bacteria with skin surface of *Carassius auratus* L. and *Poecilia reticulata*. *J Fish Biol* 27:395–402
- Davis MW, Ottmar ML (2006) Wounding and reflex impairment may be predictors for mortality in discarded or escaped fish. *Fish Res* 82:1–6
- Davis MW, Stephenson J, Noga EJ (2008) The effect of tricaine on use of the fluorescein test for detecting skin and corneal ulcers in fish. *J Aquat Anim Health* 20:86–95
- Elliott DG (1985) A study of the pathogenesis of goldfish ulcer disease caused by atypical *Aeromonas salmonicida*. PhD dissertation, University of Washington, Seattle, WA
- Elliott DG (2000) Integumentary system: microscopic functional anatomy. In: Ostrand GK (ed) *The laboratory fish*. Academic Press, London, p 271–306
- Elliott DG, Pascho RJ (2001) Evidence that coded-wire-tagging procedures can enhance transmission of *Renibacterium salmoninarum* in chinook salmon. *J Aquat Anim Health* 13:181–193
- Elliott DG, Pascho RJ, Palmisano AN (1995) Broodstock segregation for the control of bacterial kidney disease can affect mortality of progeny chinook salmon (*Oncorhynchus tshawytscha*) in seawater. *Aquaculture* 132:133–144
- European Commission, Food and Food Safety (2008) European Parliament and Council Directive 94/36/EC on colours for use in foodstuffs, 30 June 1994. http://ec.europa.eu/food/food/chemicalsafety/additives/index_en.htm, accessed 26 Dec 2008
- Ford RJ, Becker FF (1982) The characterization of trypan blue-induced tumors in Wistar rats. *Am J Pathol* 106:326–331
- Freshney RI (2000) *Culture of animal cells: a manual of basic technique*. Wiley-Liss, New York, p 330–331
- Fryer JL, Lannan CN (1993) The history and current status of *Renibacterium salmoninarum*, the causative agent of bacterial kidney disease in Pacific salmon. *Fish Res* 17:15–33
- Gadomski DM, Mesa MG, Olson TM (1994) Vulnerability to predation and physiological stress responses of experimentally descaled juvenile chinook salmon *Oncorhynchus tshawytscha*. *Environ Biol Fishes* 39:191–199
- Glavin GB, Szabo S, Johnson BR, Xing PL, Morales RE, Plebani M, Nagy L (1996) Isolated rat gastric mucosal cells: optimal conditions for cell harvesting, measures of viability and direct cytoprotection. *J Pharmacol Exp Ther* 276:1174–1179
- Gulamhusein AP, Moore WJ, Gupta M, Beck F (1982) Trypan blue teratogenesis in the rat: further observations in vitro. *Teratology* 26:289–297
- Hendricks JD, Leek SL (1975) Kidney disease postorbital lesions in spring chinook salmon (*Oncorhynchus tshawytscha*). *Trans Am Fish Soc* 104:805–807
- Hickey GM (1982) Wound healing in fish larvae. *J Exp Mar Biol Ecol* 57:149–168
- Hoffmann R, Popp W, van de Graaff S (1984) Atypical BKD predominantly causing ocular and skin lesions. *Bull Eur Assoc Fish Pathol* 4:7–9
- IPCS Inchem (2008) Fast green FCF (WHO food additives series 16, 20, 21). International Programme on Chemical Safety, www.inchem.org, accessed 26 Dec 2008
- International Agency for Research on Cancer (1975) IARC monographs on the evaluation of the carcinogenic risk of chemicals to man, Vol 8. Some aromatic azo compounds. World Health Organization, IARC, Lyon, p 267–278
- Kanno T, Nakai T, Muroga K (1989) Mode of transmission of vibriosis among ayu *Plecoglossus altivelis*. *J Aquat Anim Health* 1:2–6
- Kiryu I, Wakabayashi H (1999) Adherence of suspended particles to the body surface of rainbow trout. *Fish Pathol* 34:177–182
- Kostecki PT, Clifford P, Gloss SP, Carlisle JC (1987) Scale loss and survival in smolts of Atlantic salmon (*Salmo salar*) after turbine passage. *Can J Fish Aquat Sci* 44:210–214
- Martínez JL, Casado A, Enríquez R (2004) Experimental infection of *Flavobacterium psychrophilum* in fins of Atlantic salmon *Salmo salar* revealed by scanning electron microscopy. *Dis Aquat Org* 59:79–84
- McKibben CL, Pascho RJ (1999) Shedding of *Renibacterium salmoninarum* by infected chinook salmon *Oncorhynchus tshawytscha*. *Dis Aquat Org* 38:75–79
- Millonig G (1976) *Laboratory manual of biological electron microscopy*. Mario Saviolo, Vercelli, p 27
- Mims CA, Nash A, Stephen J (2001) *Mims' pathogenesis of infectious disease*, 5th edn. Academic Press, San Diego, CA
- Neish GA (1977) Observations on saprolegniasis of adult sockeye salmon *Oncorhynchus nerka* (Walbaum). *J Fish Biol* 10:513–522

- Noga EJ, Udomkunsri P (2002) Fluorescein: a rapid, sensitive, nonlethal method for detecting skin ulceration in fish. *Vet Pathol* 39:726–731
- O'Brien R, Gottlieb-Rosenkrantz P (1970) An automated method for viability assay of cultured cells. *J Histochem Cytochem* 18:581–589
- Pascho RJ, Elliott DG, Achord S (1993) Monitoring the in-river migration of smolts from two groups of spring chinook salmon *Oncorhynchus tshawytscha* (Walbaum), with different profiles of *Renibacterium salmoninarum* infection. *Aquacult Fish Manag* 24:163–169
- Powell MD, Speare DJ, Burka JF (1992) Fixation of mucus on rainbow trout (*Oncorhynchus mykiss* Walbaum) gills for light and electron microscopy. *J Fish Biol* 41:813–824
- Quiniou SMA, Bigler S, Clem LW, Bly JE (1998) Effects of water temperature on mucous cell distribution in channel catfish epidermis: a factor in winter saprolegniasis. *Fish Shellfish Immunol* 8:1–11
- Roberts RJ, Bullock AM (1980) The skin surface ecosystem of teleost fishes. *Proc R Soc Edinb B* 79:87–91
- Roubal FR, Bullock AM (1988) The mechanism of wound repair in the skin of juvenile Atlantic salmon, *Salmo salar* L., following hydrocortisone implantation. *J Fish Biol* 32:545–555
- Sakai DK (1979) Invasive routes of *Aeromonas salmonicida* subsp. *salmonicida*. *Sci Rep Hokkaido Fish Hatchery* 34:1–6
- Sanders JE, Long JJ, Arakawa CK, Bartholomew JL, Rohovec JS (1992) Prevalence of *Renibacterium salmoninarum* among downstream-migrating salmonids in the Columbia River. *J Aquat Anim Health* 4:72–75
- Schneider R, Nicholson BL (1980) Bacteria associated with fin rot disease in hatchery-reared Atlantic salmon (*Salmo salar*). *Can J Fish Aquat Sci* 37:1505–1513
- Seely CJ, Lutnesky MMF (1998) Odour-induced antipredator behaviour of the water flea *Ceriodaphnia reticulata* in varying predator and prey densities. *Freshw Biol* 40:17–24
- Smith CR, Present TMC (1983) *In vivo* marking of shallow-water and deep-sea amphipods by ingestion of bait mixed with fast green. *Mar Biol* 73:183–192
- Speare DJ, Mirsalimi SM (1992) Pathology of the mucous coat of trout during an erosive bacterial dermatitis: a technical advance in mucous coat stabilization for ultrastructural examination. *J Comp Pathol* 106:201–211
- Svendsen YS, Bøgwald J (1997) Influence of artificial wound and non-intact mucus layer on mortality of Atlantic salmon (*Salmo salar* L.) following a bath challenge with *Vibrio anguillarum* and *Aeromonas salmonicida*. *Fish Shellfish Immunol* 7:317–325
- Toxnet (2008) Fast green FCF. Toxicology Data Network. <http://toxnet.nlm.nih.gov>, accessed 26 Dec 2008
- Turnbull JF, Richards RH, Robertson DA (1996) Gross, histological and scanning electron microscopic appearance of dorsal fin rot in farmed Atlantic salmon, *Salmo salar* L., parr. *J Fish Dis* 19:415–427
- US Army Corps of Engineers, Walla Walla District (1985) Comprehensive report of juvenile salmonid transportation, Parts II and III. US Army Corps of Engineers, North Pacific Division, Portland, OR
- Ventura MT, Grizzle JM (1987) Evaluation of portals of entry of *Aeromonas hydrophila* in channel catfish. *Aquaculture* 65:205–214
- Weisenthal LM, Marsden JA, Dill PL, Macaluso CK (1983) A novel dye exclusion method for testing *in vitro* chemosensitivity of human tumors. *Cancer Res* 43:749–757
- Whitear M (1987) The skin of fishes including cyclostomes: epidermis. In: Bereiter-Hahn J, Matoltsy AG, Richards KS (eds) *Biology of the integument*. Springer-Verlag, Berlin, p 8–38
- Xu D, Rogers WA (1991) Electron microscopy of infection by *Saprolegnia* spp. in channel catfish. *J Aquat Anim Health* 3:63–69
- Yamamoto T, Batts WN, Winton JR (1992) *In vitro* infection of salmonid epidermal tissues by infectious hematopoietic necrosis virus and viral hemorrhagic septicemia virus. *J Aquat Anim Health* 4:231–239

Editorial responsibility: Bernd Sures,
Essen, Germany

Submitted: October 2, 2008; Accepted: January 9, 2009
Proofs received from author(s): March 4, 2009